

Oral valganciclovir in human immunodeficiency virus-positive patients suffering from cytomegalovirus retinitis at a tertiary care hospital in North India

Ashish Markan, Nikita Gupta, Mohit Dogra, Aman Sharma¹, Ramandeep Singh

Purpose: To study clinical efficacy of valganciclovir in cytomegalovirus retinitis (CMVR) in human immunodeficiency virus (HIV)-positive patients in a tertiary care clinic in a developing nation. **Methods:** In a retrospective study, systemic and ocular records of HIV patients suffering from CMVR and treated with valganciclovir, were analyzed. Primary outcome measures were involvement of the other eye, incidence of retinal detachment, systemic involvement, and mortality encountered. Secondary outcome measures included change in BCVA. **Results:** Out of nine patients who were included, two patients developed CMVR in the other eye and only one patient (11.11%) developed retinal detachment during the course of the study. No patient developed any systemic manifestations or had mortality during the course of the study. The change in BCVA was not statistically significant. **Conclusion:** Use of oral valganciclovir showed good outcome and was found to be a better alternative compared to the use of intravitreal ganciclovir in the literature. Introduction of valganciclovir at an affordable price in developing nations can decrease disease burden.

Key words: AIDS, CMV retinitis, developing nation, HIV, systemic therapy, valganciclovir

Cytomegalovirus retinitis (CMVR) is one of the most prevalent opportunistic infections in AIDS patients.^[1,2] Its incidence is decreasing in developed countries with introduction of HAART, but continues to be neglected in developing countries.^[3-5] The mortality rates in HIV patients is directly linked to cytomegalovirus (CMV) viremia.^[3,6,7] Data from developing countries have shown high mortality rates in patients with CMVR.^[8] CMV infection is a cofactor in AIDS progression, CMVR, and CMV viremia. They are powerful predictors of mortality. Due to unaffordability, and unavailability of systemic antiviral therapy in developing countries, CMVR is mainly managed with intravitreal ganciclovir, which requires multiple injections and frequent hospital visits.^[3]

Systemic therapy, which is the mainstay of therapy for CMVR, decreases systemic CMV viremia, and thus reduces the mortality in HIV-infected patients. With introduction of oral valganciclovir, the use of intravenous ganciclovir, and foscarnet has drastically reduced, thereby avoiding long-term hospital admissions, cost of treatment, and other potential side effects related to intravenous therapy.^[9-11]

Due to the limited use of oral valganciclovir for CMVR in developing countries like India, there are no long-term studies evaluating the effect of oral valganciclovir in CMVR eyes. We, in this study, looked at the role of oral valganciclovir therapy in preventing other eye involvement, and also reducing systemic CMV infection, and thereby the mortality in a developing country.

Advanced Eye Centre, ¹Department of Internal Medicine, Postgraduate Institute of Medical Education and Research, Chandigarh, India

Correspondence to: Dr. Ramandeep Singh, Advanced Eye Centre, Postgraduate Institute of Medical Education and Research, Chandigarh - 160 012, India. E-mail: manko095@yahoo.com

Received: 01-Nov-2021

Revision: 14-Jan-2022

Accepted: 25-Feb-2022

Published: 30-Jun-2022

Access this article online

Website:

www.ijo.in

DOI:

10.4103/ijo.IJO_2787_21

Quick Response Code:



Methods

In a retrospective case series, we looked at our uveitis clinic database for CMVR cases, who were referred from the ART clinic and were treated with oral valganciclovir from November 2017 to November 2019. All the patients were on highly active antiretroviral therapy (HAART). The patients were started on a fixed dose regimen (Tenofovir 300 mg, Lamivudine 150 mg, and Efavirenz 300 mg) monopill, given once a day at night time. The study was conducted as per the Declaration of Helsinki. Ethical clearance was obtained from the institutional review board.

We included all the patients suffering from AIDS. These patients were referred from ART clinic of our hospital for treatment of first episode of CMVR, and had a minimum follow-up of three months. Patients were excluded if they were non-compliant with the treatment, had previous history of treated CMVR, or had previously received oral valganciclovir.

Systemic and ocular records of the study patients were collected. Clinical data included age, sex, HIV status, CD4 counts at presentation, any associated comorbidities, and any previous treatment history. Ocular data was recorded at baseline, and last follow up. Ocular data included best-corrected visual acuity (BCVA), intraocular pressure (IOP), presence of relative afferent pupillary defect (RAPD), type of CMVR, laterality, and zone of involvement. Serial fundus photographs

This is an open access journal, and articles are distributed under the terms of the Creative Commons Attribution-NonCommercial-ShareAlike 4.0 License, which allows others to remix, tweak, and build upon the work non-commercially, as long as appropriate credit is given and the new creations are licensed under the identical terms.

For reprints contact: WKHLRPMedknow_reprints@wolterskluwer.com

Cite this article as: Markan A, Gupta N, Dogra M, Sharma A, Singh R. Oral valganciclovir in human immunodeficiency virus-positive patients suffering from cytomegalovirus retinitis at a tertiary care hospital in North India. Indian J Ophthalmol 2022;70:2472-5.

of the eyes were done using FF 450 ^{plus} Fundus Camera with VISUPAC™ Digital Imaging System (Carl Zeiss Meditech, Dublin, CA), and Optos ultra-widefield retinal imaging (Optos, Dunfermline, UK).

CMVR was diagnosed on fundoscopic examination using indirect ophthalmoscopy by an experienced retinal specialist (RS). Among the study patients, the fundus of the eye was typically characterized by irregular zones of granular whitish infiltrates, retinal hemorrhages, areas of retinal opacification, and vascular sheathing. The lesions were categorized either as classic, granular, or frosted branch angiitis variety of CMVR. Zone of involvement was graded as zone 1, 2, and 3.^[12]

The patients were started on oral valganciclovir 900 mg twice a day for three weeks as induction dose. This was followed by 900 mg OD as maintenance dose. Regular monitoring of blood counts, liver function tests, and kidney function tests were performed. CD4 counts were monitored, and valganciclovir was stopped once CD4 counts were more than 100, and lesions were clinically healed. (13) Progression of the disease was also noted during the course of follow up. Progression was defined as a leading edge of retinitis 750 μm from a previously quiescent area of retinitis, or a new area of retinitis consistent with CMV. (16) Patients were also evaluated for development of any extraocular manifestations of CMV in the body.

Primary outcome measures were to look for involvement of the other eye, incidence of retinal detachment, systemic involvement, and mortality during the follow-up period. Secondary outcome measures included change in BCVA during the follow-up period.

Statistical analysis

Categorical variables were measured as percentages, and continuous variables were measured as mean. Paired *t* test (using SPSS software 2003) was applied to compare final visual acuity with the initial presenting visual acuity. *P* < 0.05 was considered statistically significant.

Results

A total of nine patients (12 eyes) were included in our study. Mean age of our patients was 36.11 ± 8.37 years. A majority of patients in our case series were men (*n* = 6, 66.67%). Mean CD4 counts of our patients suffering from HIV were 62.25 ± 34.08. 5 out of 9 patients had co-existent pulmonary tuberculosis and were started on anti-tubercular therapy (ATT).

Six out of nine patients (66.67%) presented with unilateral CMVR, whereas three patients (33.33%) had bilateral disease. Zone 1 and 2 involvement was seen in 66.66% of eyes; 16.66% eyes had only zone 2 involvement, 8.33% eyes had both zone 2 and 3 involvement, and another 8.33% had involvement of all three zones. Optic disc pallor was seen in three eyes (27.27%). Majority of our patients (77.77%) had classic variety of CMVR, whereas remaining 22.22% showed granular lesions [Table 1]. Mean BCVA in the affected eye was log MAR 1.15 ± 1.01 at baseline. Mean IOP in the affected eye was 14 mmHg. Out of three patients who had bilateral disease, two patients had retinal detachment at presentation. One patient had inferior retinal detachment with active CMVR in both the eyes. He underwent pars plana vitrectomy with silicon oil tamponade in both the eyes. The patient was also started on oral valganciclovir. Second patient had inoperable retinal detachment in left eye with no perception of light, and no

Table 1: Salient features of CMVR-affected eyes

	Salient features of CMVR	Percentage of eyes involved (%)
1	Zone 1+2	66.66
	Zone 2	16.66
	Zone 2+3	8.33
	Zone 1+2+3	8.33
2	Classic	77.77
	Granular	22.22
3	Optic nerve involvement	27.27

surgical intervention was done for this eye. The patient was started on oral valganciclovir for active CMVR in the other eye.

Mean follow up of our patients was 9.55 ± 6.59 months. The mean BCVA at the last follow up was log MAR 1.35 ± 1.26 (*P* = 0.228). The change in BCVA was not statistically significant. During follow up, two patients (22.5%) presented with involvement in the other eye. The zone of involvement in the other eye in one patient was predominantly in zone 3, and in the other patient was predominantly in zone 2 and 3, thereby not affecting vision. The latter also developed inferior retinal detachment during the follow-up period and was planned for PPV. Two patients reported episodes of nausea, and diarrhea during the course of the treatment. None of our patients developed any hematological abnormalities. None of the patients reported any evidence of systemic CMV infection or lost to follow-up during the course of the study.

Discussion

This case series highlights our experience with the use of oral valganciclovir in HIV patients suffering from CMVR in a developing world. Due to availability and financial issues, oral valganciclovir has not been used extensively in developing nations. The index study highlights the effectiveness of systemic valganciclovir in managing CMVR.

CMVR is amongst the most common opportunistic infections seen in people infected with HIV. Studies from South East Asia have shown that CMVR is a neglected disease in this part of the world.^[3,8] The management strategy of CMVR in developing countries is still not at par with developed countries. In developed countries, where oral valganciclovir is the mainstay of therapy, intraocular injections of ganciclovir are the mainstay of therapy in developing countries. Table 2 compares the results from various studies treating CMVR,^[10,11,13-17] with present study.

In our study, all patients with CMVR were treated with oral valganciclovir. Fig. 1 shows resolution of active CMVR in a patient treated with oral valganciclovir. Two patients developed CMVR in the fellow eye during the course of treatment. Our results were similar to various studies, which have shown beneficial effects of oral valganciclovir in preventing CMVR in the fellow eye.^[10,11] However, intraocular injection of ganciclovir has not shown any protection in the fellow eye.^[14-16] Hodge *et al.*^[16] demonstrated that 30.4% of patients developed CMVR in the fellow eye during the maintenance phase with intravitreal ganciclovir. Table 2 clearly shows that risk of involvement of other eye with local therapy (9%–30.4%) is much more than with systemic therapy (6%–15%). Secondly, giving intraocular injections of ganciclovir not only requires frequent hospital visits, but also requires a close screening of the other eye at

Table 2: Comparison of results from various studies treating CMVR with our present study

Region	Present study		Martin <i>et al.</i> ^[10]	Murray <i>et al.</i> ^[13]	Lalezari <i>et al.</i> ^[11]	Montero <i>et al.</i> ^[14]	Teoh <i>et al.</i> ^[15]	Hodge <i>et al.</i> ^[16]	Visser <i>et al.</i> ^[17]	Murray <i>et al.</i> ^[13]
	Developing	Developed	Developed	Developing	Developed	Developed	Developed	Developed	Developed	Developing
Mode of treatment	Valganciclovir	Valganciclovir	Valganciclovir	Valganciclovir	Valganciclovir	IVG	IVG	IVG	IVG	IVG
Number of patients	9	80	32	212	12	24	40	90	21	21
Nature of study	Retrospective	Prospective	Retrospective	Prospective	Retrospective	Retrospective	Retrospective	Retrospective	Retrospective	Retrospective
Mean age (years)	36.11±8.37	39±7.6	38 (median)	-	34.7	-	37.5	-	37 (median)	37 (median)
Male %	66.67	90%	59%	91%	91.6%	-	100%	-	48%	48%
Mean CD4	62.25±34.08	58.0±80.8	16 (median)	140 (median)	44.1	-	30±71	-	34 (median)	34 (median)
BL involvement at presentation (%)	33.33	25	31	-	33.3	-	-	75%	48%	48%
Other eye involvement on follow-up (%)	22.5	15	-	6	12.5	17.6%	30.4%	9%	-	-
Retinal detachment on follow-up (%)	11.11	15	-	7	0	12.5	12.5	7.5	-	-
Mean follow-up period	9.55±6.59 months	12.5 months	-	12.4 months (median)	34 months	6.93 months	13.27 months (median)	-	-	-

regular intervals by a trained ophthalmologist. This not only adds up to the cost of treatment, but also requires availability of trained ophthalmologists to perform indirect ophthalmoscopy.

Our patients did not deteriorate, and thus maintained a stable vision after treatment. Our results were similar to a study by Murray *et al.*,^[13] which showed that nearly 60% of eyes treated on oral valganciclovir maintained a stable vision. Lack of improvement in vision in our patients could be attributed to mainly zone 1 involvement in the affected eyes. Our study showed that timely treatment with oral valganciclovir helps maintain stable vision in CMVR eyes.

Though oral valganciclovir is more expensive than an injection of ganciclovir, studies have shown that total cost per day of oral treatment is equivalent to intraocular treatment.^[18] We believe that frequent visits to a tertiary eye care hospital in a developing country like India definitely adds up to the cost of the treatment. Also, with the emergence of the COVID-19 pandemic, lockdown guidelines, and travel restrictions, it is not possible for patients to make biweekly visits to the hospital to get intraocular injections.^[19] Our institute mandates COVID RT-PCR testing before any invasive procedure including intravitreal injections are performed. With change in the medicine practices owing to COVID-19 pandemic, getting repeated COVID testing definitely adds to the cost of treatment as well as the patient’s inconvenience.

Only one patient (11.11%) developed retinal detachment during the course of treatment. Repeated intravitreal injections not only increase the risk of retinal detachment, but also increases the chances of endophthalmitis, cataract, and vitreous hemorrhage.^[17,20]

None of our patients showed progression of the disease on oral therapy during the course of treatment. This is in contrast to intraocular therapy, where the chances of disease progression are high. Hodge *et al.*,^[16] in his series, has shown that 68.4% lesions progressed while on maintenance therapy with intraocular ganciclovir. We believe that systemic control of CMV infection with oral valganciclovir helps prevent the progression of the intraocular infection.

CMV viremia has been shown to correlate with mortality in HIV patients. Systemic CMV has been shown to be the primary cause of death in 1%–19% of patients with AIDS.^[21–23] Systemic therapy not only controls the ocular CMV, but also decreases CMV viremia, thereby decreasing the chances of systemic CMV infections as well as overall mortality in HIV patients. Treatment of CMVR with only local therapy is associated with high mortality rates.^[16] However in our study, patients neither developed any evidence of systemic CMV nor did they die during the course of treatment.

Our study did have some limitations. Firstly, this was a retrospective study. Secondly, we had a very limited sample size. However, this small subset of patients treated only with systemic therapy provides us with encouraging results, and warrants a long-term prospective study with a large sample size. To the best of our knowledge, this is one of the few studies from the developing world that shows long-term follow-up of CMV retinitis patients treated with valganciclovir.

Conclusion

Oral valganciclovir is a better treatment option for CMVR than repeated intraocular ganciclovir injections. Though it

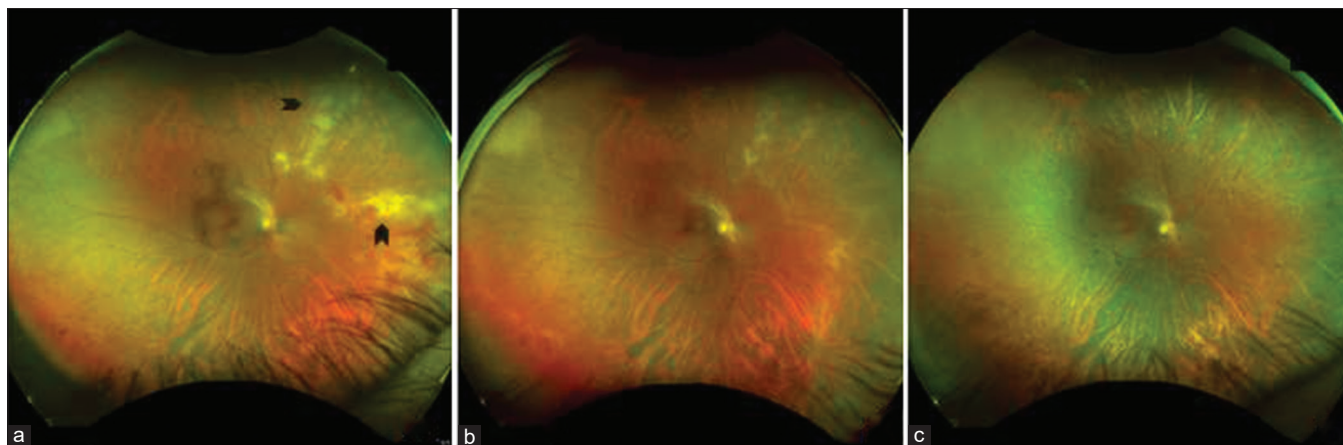


Figure 1: Active CMVR (black arrowheads) at baseline (a). The patient was started on tablet valganciclovir. The lesions healed on follow-up at 3 months (b) and at 6 months (c)

is a standard of care in developed countries, introduction of valganciclovir in developing countries at affordable prices will not only help control the mortality associated with HIV, but will also reduce repeated hospital visits, and lessen the treatment burden on healthcare facilities.

Financial support and sponsorship

Nil.

Conflicts of interest

There are no conflicts of interest.

References

- Jabs DA, Enger C, Bartlett JG. Cytomegalovirus retinitis and acquired immunodeficiency syndrome. *Arch Ophthalmol* 1989;107:75–80.
- Jabs DA, Green WR, Fox R, Polk BF, Bartlett JG. Ocular manifestations of acquired immune deficiency syndrome. *Ophthalmology* 1989;96:1092–9.
- Heiden D, Ford N, Wilson D, Rodriguez WR, Margolis T, Janssens B, *et al.* Cytomegalovirus retinitis: The neglected disease of the AIDS pandemic. *PLoS Med* 2007;4:e334.
- Biswas J, Madhavan HN, George AE, Kumarasamy N, Solomon S. Ocular lesions associated with HIV infection in India: A series of 100 consecutive patients evaluated at a referral center. *Am J Ophthalmol* 2000;129:9–15.
- Jacobson MA, Stanley H, Holtzer C, Margolis TP, Cunningham ET. Natural history and outcome of new AIDS-related cytomegalovirus retinitis diagnosed in the era of highly active antiretroviral therapy. *Clin Infect Dis* 2000;30:231–3.
- Jabs DA, Holbrook JT, Van Natta ML, Clark R, Jacobson MA, Kempen JH, *et al.* Risk factors for mortality in patients with AIDS in the era of highly active antiretroviral therapy. *Ophthalmology* 2005;112:771–9.
- Durier N, Ananworanich J, Apornpong T, Ubolyam S, Kerr SJ, Mahanontharit A, *et al.* Cytomegalovirus viremia in Thai HIV-infected patients on antiretroviral therapy: Prevalence and associated mortality. *Clin Infect Dis* 2013;57:147–55.
- London NJS, Shukla D, Heiden D, Rathinam SR, Arevalo JF, Cunningham ETJ. HIV/AIDS in the developing world. *Int Ophthalmol Clin* 2010;50:201–18.
- Stewart MW. Optimal management of cytomegalovirus retinitis in patients with AIDS. *Clin Ophthalmol* 2010;4:285–99.
- Martin DF, Sierra-Madero J, Walmsley S, Wolitz RA, Macey K, Georgiou P, *et al.* A controlled trial of valganciclovir as induction therapy for cytomegalovirus retinitis. *N Engl J Med* 2002;346:1119–26.
- Lalezari J, Lindley J, Walmsley S, Kuppermann B, Fisher M, Friedberg D, *et al.* A safety study of oral valganciclovir maintenance treatment of cytomegalovirus retinitis. *J Acquir Immune Defic Syndr* 2002;30:392–400.
- Holland GN, Buhles WC Jr, Mastre B, Kaplan HJ. A controlled retrospective study of ganciclovir treatment for cytomegalovirus retinopathy: Use of a Standardized System for the assessment of disease outcome. *Arch Ophthalmol* 1989;107:1759–66.
- Murray J, Hilbig A, Soe TT, Ei WLSS, Soe KP, Ciglenecki I. Treating HIV-associated cytomegalovirus retinitis with oral valganciclovir and intra-ocular ganciclovir by primary HIV clinicians in southern Myanmar: A retrospective analysis of routinely collected data. *BMC Infect Dis* 2020;20:842.
- Montero MC, Pastor M, Buenestado C, Lluch A, Atienza M. Intravitreal ganciclovir for cytomegalovirus retinitis in patients with AIDS. *Ann Pharmacother* 1996;30:717–23.
- Teoh SC, Ou X, Lim TH. Intravitreal ganciclovir maintenance injection for cytomegalovirus retinitis: Efficacy of a low-volume, intermediate-dose regimen. *Ophthalmology* 2012;119:588–95.
- Hodge WG, Lalonde RG, Sampalis J, Deschênes J. Once-weekly intraocular injections of ganciclovir for maintenance therapy of cytomegalovirus retinitis: Clinical and ocular outcome. *J Infect Dis* 1996;174:393–6.
- Visser L. Managing CMV retinitis in the developing World. *Community Eye Health* 2003;16:38–9.
- Mahadevia PJ, Gebo KA, Pettit K, Dunn JP, Covington MT. The epidemiology, treatment patterns, and costs of cytomegalovirus retinitis in the post-haart era among a national managed-care population. *J Acquir Immune Defic Syndr* 2004;36:972–7.
- Gupta V, Rajendran A, Narayanan R, Chawla S, Kumar A, Palanivelu MS, *et al.* Evolving consensus on managing vitreo-retina and uvea practice in post-COVID-19 pandemic era. *Indian J Ophthalmol* 2020;68:962–73.
- Arevalo JF, Garcia RA, Mendoza AJ. High-dose (5000-microg) intravitreal ganciclovir combined with highly active antiretroviral therapy for cytomegalovirus retinitis in HIV-infected patients in Venezuela. *Eur J Ophthalmol* 2005;15:610–8.
- Yust I, Fox Z, Burke M, Johnson A, Turner D, Mocroft A, *et al.* Retinal and extraocular cytomegalovirus end-organ disease in HIV-infected patients in Europe: A EuroSIDA study, 1994–2001. *Eur J Clin Microbiol Infect Dis* 2004;23:5509.
- Pecorella I, Ciardi A, Credendino A, Marasco A, Di Tondo U, Scaravilli F. Ocular, cerebral and systemic interrelationships of cytomegalovirus infection in a postmortem study of AIDS patients. *Eye* 1999;13:781–5.
- Léger F, Vital C, Vital A, Morlat P, Ragnaud JM, Dupon M. Pathologic correlations between ocular and cerebral lesions in 36 AIDS patients. *Clin Neuropathol* 1997;16:45–8.