

Review Article

Nitrogen containing bisphosphonates associated osteonecrosis of the jaws: A review for past 10 year literature

Vijay Kumar¹, Ashish Kumar Shahi²

¹Department of Oral and Maxillofacial Surgery, R. D. Dental Hospital and Research Centre, Patna, Bihar, India, ²Consultant Oral and Maxillofacial Surgeon, Gorakhpur, Uttar Pradesh, India

ABSTRACT

Nitrogen containing bisphosphonate (N-BP) therapy is used extensively to treat osteoporosis and osteolytic bone lesions. Recently, a special form of osteonecrosis limited to the maxillofacial skeleton has been discovered especially within those patients who are receiving either long-term N-BP therapy alone and/or associated with invasive dental procedure. Bisphosphonates accumulate almost exclusively in maxillofacial skeleton owing to high bone turn over remodeling to maintain the mechanical competence. The pathogenesis and why it commonly appears in maxillofacial skeleton and the fixed treatment strategies remains unknown. The aim of this study was to improve the clinician understanding of N-BPs associated osteonecrosis of maxillofacial skeleton by reviewing the past 10 year literature.

Key Words: Nitrogen containing bisphosphonates, osteonecrosis of the jaw, staging and treatment strategies

Received: September 2012

Accepted: May 2013

Address for correspondence:

Dr. Vijay Kumar, R. D. Dental Hospital & Research Centre, Patna, Bihar, India.

E-mail: vijaypraveenmds@gmail.com

INTRODUCTION

Bisphosphonates (BPs) are stable analogs of pyrophosphate, which are naturally occurring modulators of bone metabolism and have been synthesized and used since the 19th century, but their *in-vitro* ability to inhibit the precipitation of calcium phosphate was applied clinically in 1960s. Oral BPs are poorly absorbed by the gastrointestinal tract about 10% and excreted largely unchanged by the kidneys, but if given intravenously nitrogen containing bisphosphonates (N-BPs) about 50% of the drugs goes to the bone.^[1,2] BPs are commonly used to treat certain resorptive bone diseases such as osteoporosis, Paget's disease and hypercalcemia associated with certain malignancies such as multiple myeloma and

bone metastasis from the breast or prostate.^[3,4] Their principal action is to inhibit resorption of bone by inhibiting osteoclast activity and its life-span that leads to modulation of the osteoclast-osteoblast inter relation, which results in an increase in the mineral density of bone and a reduction in serum calcium;^[1] although, other actions such as inhibition of angiogenesis^[5] and anti-human endothelial cell proliferation and to modulate endothelial cell adhesion and migration have also been reported.^[6] BPs has unique pharmacokinetic properties like long retention time in bone; it is possible that beneficial effects on fracture risk may persist for some time after treatment is stopped.^[7] BPs has a high affinity for exposed hydroxyapatite within bone mineral and bone is metabolically inactive. As the process of metabolic bone resorption progresses, previously bound BPs is released and exerts their clinical effect.^[1] However, according to previous literature, all three above mentioned pharmacological action produced by N-BPs becomes more aggressive in the presence of other risk factors (drug related, local, demographic/systemic, genetic and preventive)^[4,8] that finally leads to a rare, but serious clinical condition called

Access this article online



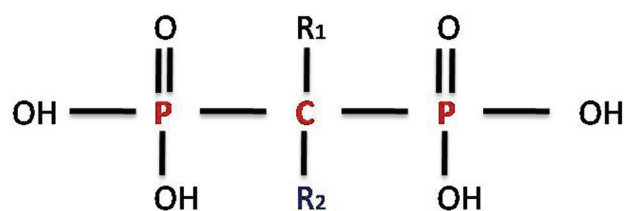
Website: <http://drj.mui.ac.ir>

N-bisphosphonate-related osteonecrosis of the jaw (BRONJ) that was first described by Marx in 2003.^[9]

ETIOPATHOGENESIS OF BRONJ

Chemical structure of BP [Figure 1] has two important entity P-C-P back bone and R₂ side chain that shows a strong affinity for bone mineral and provides potent inhibition of bone turn over both *in-vivo* and *in-vitro* and therapeutic potency of the BPs respectively. Chemically BPs had two sub-divisions, which have a different mechanism of action on osteoclasts based on the presence or absence of a nitrogen side chain on the pyrophosphate group (R₂ side chain). N-BPs had poorly absorbed by gastrointestinal tract as compare to non-N-BPs, owing to this region N-BPs are commonly prepared for IV administration.^[1,4,9]

Bone remodeling is a physiologically coordinated process involving bone formation by osteoblasts and bone resorption by osteoclasts. Imbalance between these two entities may lead to skeletal abnormalities characterized by increases or decreases in bone density.^[10] In contrast to other skeleton, jaw bones (alveolar process and periodontium) have relatively high vascularity, bone turn over and remodeling because of continuous mechanical stress.^[3] Such bone repair and remodeling is greatly enhances by infection and/or trauma.^[11] Non-N-BPs (Tiludronate, Clodronate and Etidronate) is taken up by the osteoclasts and antagonized the cellular energy pathways due to intracellular liberation of methylene that contains toxic analogs of adenosine triphosphate (ATP), which probably inhibit ATP-utilizing enzymes and induce osteoclast apoptosis, whereas N-BPs (Zoledronate, Pamidronate, Alendronateetc..) has a more complex pathway of action where they inhibit the Mevalonate pathway by inhibition of farnesyl-pyrophosphate synthetase leading to prenylation of small GTPase signaling proteins that are essential for osteoclast activity and survival.^[3,6] Thus, there is no osteoclastic resorption of mineral matrix and the resultant release of bone morphogenic protein and insulin-like growth to induced stem cell production of osteoblasts, the osteon becomes a-cellular and necrotic. There is sequential involution of blood vessels leaving the bone avascular. Therefore, any mechanism that leads to the breakdown of the over laying mucosa will expose the necrotic bone, which fails to heal.^[6] According to previous literature, Zoledronate has also been shown to inhibit human endothelial cell to proliferate



PCP Group: Essential for biological activities-binding hydroxyapatite, **R2 Side Chain:** Determines Potency.

Figure 1: Chemical structure of bisphosphonate

and to modulate endothelial cell adhesion and migration.^[1-3,12] Therefore, a possible association was seen between BPs and two rare but serious conditions, namely atypical femoral fracture and osteonecrosis of the jaw (ONJ)^[7] with an incidence of 0.8-12%^[4,8] in IV BPs and 0.01-0.04%^[4] in oral BPs administration. Although the exact Pathophysiology of BPs induced ONJ has not be completely illuminated, but according to previous literature, N-BPs are potent inhibitors of osteoclastic activity, angiogenesis, human endothelial cell to proliferate and to modulate endothelial cell adhesion and migration.^[1,8,13,14] Thus, the net result is that the jaw bone is unable to meet the peak demand for bone repair and remodeling that may finally lead to BRONJ.

Diagnosis, staging and clinical presentation of BRONJ

Exact diagnosis criteria to distinguish BRONJ from other delayed healing conditions (alveolar osteitis, osteoradionecrosis, osteomyelitis etc..) are not known yet today, but according to previous literature patients may be considered to have BRONJ if all of the following four characteristics are present: (1) Current or previous treatment with a BPs, (2) Exposed or necrotic bone in the maxillofacial region that has persisted for more than 8 weeks, (3) No history of radiation therapy to the jaws and (4) No evidence of cancer at the site. Lesions in patients who have not fulfilled above four characteristics should be excluded from the diagnosis of BRONJ.^[1,4,8,15-17]

Radiographic findings of BRONJ are not specific and are found in other conditions such as osteomyelitis, osteoradionecrosis and metastatic bone lesions. According to previous literature most common imaging finding in ONJs is osseous sclerosis. This can vary from subtle thickening of the lamina dura and alveolar crest to attenuated osteopetrosis like sclerosis. Other findings such as Osteolysis, soft-tissue swelling, periosteal new bone formation, periapical

lucencies, oroantral fistula and sequestra, which are likely to correspond with the presence of infection.^[18,19] Its imaging differential diagnosis includes chronic sclerosing osteomyelitis, osteoradionecrosis, bone metastasis and Paget's disease. If osteonecrosis is suspected, different imaging techniques may be performed to confirm the diagnosis and extent of the lesions.^[17]

- Periapical radiograph and *cone-beam computed tomography* (CBCT) reveals generalized thickening of the cortical plate and laminadura, mixed sclerotic and lytic bone destruction involving alveolar bone and basal bone, sequestrum, encroachment on the mandibular canal and maxillary antrum and pathological fracture while thickening of the cortical plate in the affected region was the only radiological findings of CBCT.^[20]
- Computed tomography images reveals sclerotic changes, osteolytic changes, periosteal bone proliferation, sequestration and inferior alveolar canal involvement while contrast enhanced magnetic resonance images reveals intensity changes of the cortical and sub cortical bone structures, contrast enhancement in necrotic bone area, soft-tissue involvement and cervical lymphadenopathy.^[9]
- ⁹⁹Tcm *myocardial perfusion defect* reveals detection of local bone remodeling activity/high bone turn over sites, but the presence of increased uptake was conformed through the *single-photon emission computed tomography* because they provide a high degree of accuracy.^[17]

In past 10 year, some important serological, histopathological and immunohistochemistry findings are obtained that may suggest the appearance of BRONJ in that patient. According to recent literature, angiogenesis suppression may play a significant role in development of BRONJ. On the basis of this evidence, Vincenzi *et al.*^[5] evaluated the role of *vascular endothelial growth factor* (VEGF) as a predictive marker of BRONJ and found decreased VEGF circulating levels at day 7 and 21 after the 1st administration of N-BPs; thus, authors concluded that the anti-angiogenic properties of N-BPs are directly linked to BRONJ pathogenesis and serum VEGF levels could represent an effective early predictive marker. Similarly, morning fasting serum C-terminal telopeptide (CTX) value is less than 100pg/ml in those patients who received/receiving N-BPs representing high risk of BRONJ development,^[9,21,22] but invasive

dental procedure is only indicated if CTX value is greater than 150pg/ml to achieve, uncomplicated healing.^[19,21,23] Tissue biopsy should be performed only if metastatic diseases is suspected. Microscopic evaluation of hard tissues reveals necrotic bone spicules with bacterial colonization and inter aspersed acute and chronic inflammatory cells while soft-tissue evaluation shows proliferating stratified squamous epithelium with arcading rete pegs and neutrophilic exocytosis and adjacent fibrous connective tissue revealed the presence of patches of plasma cells, inter aspersed neutrophils and surgical hemorrhage that was similar to osteomyelitis.^[10,24] Immuno histochemistry reveals increased expression of Human β defensins (hBD)-1,-2,-3, reduced expression of transforming growth factor beta1 and increased Galectin-3 expression in cases of BRONJ.^[25,26] Microbial cultures may provide identification of the pathogens causing secondary infections (*Actinomyces* and other pathogens) which is important for selection of appropriate antibiotics.

Two different staging systems are encountered during preparation of this review. 1st was given by recently published position paper by *American Association of Oral and Maxillofacial Surgeons* (AAOMS) (2009) while 2nd was given by Olutayo *et al.* that was listed in Table 1 and Table 2 respectively.^[4,20] Thus, BRONJ may remain asymptomatic for many weeks or months and may only be recognized clinically by the presence of the exposed bone in the oral cavity. These lesions

Table 1: AAOMS staging for BRONJ on the basis of clinical findings

Staging	Clinical presentation
At risk category	No apparent necrotic bone in patients who have been treated with either oral or IV BPs
Stage 0	No clinical evidence of necrotic bone, but non-specific clinical findings and symptoms
Stage 1	Exposed and necrotic bone in patients who are asymptomatic and have no evidence of infection
Stage 2	Exposed and necrotic bone associated with infection as evidence by pain and erythema in the region of the exposed bone with or without purulent drainage
Stage 3	Exposed and necrotic bone in patients with pain, infection, and one or more of the following Exposed and necrotic bone extending beyond the region of alveolar bone, (i.e., inferior border and ramus in the mandible, maxillary sinus and zygoma in the maxilla) resulting in pathological fracture Extra oral fistula Oral antral/oral nasal communication or Osteolysis extending to the inferior border of the mandible of sinus floor

AAOMS: American Association of Oral and Maxillofacial Surgeons; BRONJ: Bisphosphonates-related osteonecrosis of the jaw; BPs: Bisphosphonate

Table 2: Staging for BRONJ on the basis of clinical and radiologic findings

Stage	Clinical presentation	Radiological findings on the basis of periapical / CBCT
Stage 1	None	Generalized thickening of cortical plate and laminadura, focal area of sclerosis extending from cortical plate
Stage 2	Discomfort, denuded bone in the posterior/lingual mandible	Thickening of cortical plate
Stage 3	Pain, denuded bone involving alveolar bone	Mixed sclerotic and lytic bone destruction involving alveolar bone and basal bone, sequestrum
Stage 4	Denuded bone involving alveolar bone, purulent discharge, numbness, oro-antral fistula	Mixed sclerotic and lytic bone destruction involving alveolar bone and basal bone, sequestrum, encroachment on the mandibular canal and maxillary antrum, pathologic fracture

BRONJ: Bisphosphonates-related osteonecrosis of the jaw; CBCT: Cone-beam computed tomography

are most frequently symptomatic when sites becomes secondary infected or there is a trauma to the soft-tissues through the sharp edges of the exposed bone. Typical signs and symptoms include pain, soft-tissues swelling, paresthesia, suppuration, soft-tissue ulceration, loosening of teeth and drainage that is similar to osteoradionecrosis.^[15,27] According to Lam *et al.*, common orofacial findings associated with BPs associated ONJ are poor wound healing, spontaneous or post-surgical soft-tissue breakdown leading to intra oral bone exposure, bone necrosis and osteomyelitis.^[10] However, in severe cases some additional orofacial finding like intense pain, extensive sequestration of bone and cutaneous draining sinus tracts.^[28,29]

Risk factors of BRONJ

According to recent position paper by AAOMS^[4] and NSW Health Guideline,^[8] risk factors for the development of BPs associated ONJ can be grouped as drug-related, local, demographic/systematic, Genetic and preventive.

1. Drug related risk factors include: Potency of BPs: More potent BPs (Zoledronate > Pamidronate > Oral BPs) have more tendency to developed ONJ. The IV route of administration resulting greater drug exposure to the jaw than the oral route; therefore more tendencies to developed ONJ. Incidence rate of BRONJ in cancer patient is increased 2.7 - 4.2 fold if given IV BPs. Longer duration therapy of BPs may be associated with increased risk of development of ONJ

- Local risk factors include: Dento alveolar surgery like extraction, dental implant placement, periapical surgery, periodontal surgery etc., may associate with osseous injury. BPs therapy in association with dento alveolar surgery has 7 times more likely to develop BRONJ than patients who are not having dentoalveolar surgery. Anatomic location: BRONJ is more common in the mandible than in the maxilla with the ratio of 2:1 and more common in areas with thin mucosa overlaying bony prominences like Tori, Bony exostoses and mylohyoid ridge. Concomitant oral diseases like cancer patients exposed to IV BPs with a history of inflammatory (possibly infective) dental diseases are at a 7 fold increased risk for developing ONJ.
- Demographic and systemic factors:- Age: With each passing decade—there is a 9% increased risk of ONJ in multiple myeloma patients treated with IV BPs, but sex was not statically associated with ONJ. Cancer type: Multiple myeloma >> breast cancer > other cancer and osteopenia/osteoporosis concurrent with cancer are more prone to developed ONJ. Concomitant risk factors: Renal dialysis, low hemoglobin, Obesity, Diabetes, Tobacco users, poor oral hygiene and chemotherapeutic agents such as Cyclophosphamide, erythropoietin and steroids are risk factors, but no increased risk associated with alcohol exposure.
- Genetic risk factors: Like genetic perturbations, i.e., single nucleotide polymorphisms, in the cytochrome P450-2C gene (CYP2C8) gene were associated with an increased risk for ONJ among multiple myeloma patients treated with IV BPs.
- Preventive factors: The AAOMS Task force on BRONJ recommended that patients undergo dental evaluations and receive necessary treatment prior to initiating IV BPs therapy to reduce the incidence of BRONJ.^[30,31] Manipulation of IV BPs dosing may be effective in reducing skeletal related events (SREs) and minimizing BPs associated ONJ.

Management of BRONJ

Management strategies of BRONJ is mostly palliative and empirical (to eliminate clinical symptoms such as pain, infection and minimize the progression of bone necrosis) before microbial culture report.^[21,32] Most authors agreed that management of BRONJ started after advised morning fasting serum CTX test and begins palliative care. If the exposed bone is pain less, treatment started with 0.12% chlorhexidine mouth

rinse, but if patient complains pain and/or clinical evidence of infection, antibiotic therapy should be provided in addition to the 0.12% chlorhexidine.^[4,21] However, invasive dental procedure is indicated only when morning CTX value is greater than 150pg/ml, to achieve, uncomplicated healing.^[18,21,23]

Many treatment modalities are discussed for correction of BRONJ like cover the exposed bone areas with tissue flaps by Marx.^[33] Sequential removal of sequestra (conservative approach) and extensive involvement may necessitate large area of debridement to include segmental mandibulectomy and partial maxillectomy for correction of BRONJ and was reported that most patients with limited regions of exposed bone (except those lesions that are a constant source of infection) have been successfully managed with irrigations and antibiotic therapy while surgical management have not been completely effective in eradication of the BRONJ by Ruggiero *et al.*^[28] Administration of pentoxifylline with α -tocopherol reduces 74% area of bony exposure and symptom control by Epstein *et al.*^[34] Transplantation of intra-lesional autologous bone marrow stem cell with complete response by Cella *et al.*^[35] Mandibular reconstruction with the fibula flap by Nocini *et al.*^[36] and hyperbaric oxygen therapy was beneficial for patients and the outcome is increased with cessation of BPs administration.^[37,38] No fixed treatment protocol was adopted before recent position paper published by AAOMS,(2009) that provide new treatment strategies on the basis of staging of BRONJ:

At risk-Patients who are at risk of developing BRONJ by virtue of the fact that they have been exposed to a BPs do not require any treatment. However, these patients should be informed of the risk of developing BRONJ as well as the signs and symptoms of this diseases process.

Stage 0-Here provide symptomatic treatment and conservatively manage other local factors, such as caries and periodontal disease. Systemic management may include the use of medication for chronic pain and control of infection with antibiotics, when indicated.

Stage 1-These patients benefit from the use of antiseptic mouth washes (chlorhexidine gluconate 0.12%) and/or analgesia is proposed for patients with clinical evidence of BRONJ, but in the absence of any evidence of infection. Here, primary aim is to reduce

the likelihood of further progression of BRONJ and avoid infection of exposed bone, but not any surgical intervention required. However, patient education and review of indications for continued BP therapy is also important.

Stage 2-These patients benefit from the use of oral antimicrobial rinse in combination with antibiotic therapy. In BRONJ most of the isolated microbes have been sensitive to penicillin group because its development is not infectious origin. If patient was allergic to above group then choice of drug is Quinolones, Metronidazole, Clindamycin, Doxycycline and Erythromycin. If microbial cultures show positive evidence of Actinomyces species then antibiotic regimen should be adjusted accordingly. In some refractory cases, patients may require combination antibiotic therapy, long-term antibiotic maintenance or a course of IV antibiotic therapy. Sometimes superficial debridement is indicated to relieve soft-tissue irritation.

Stage 3-These patients benefit from debridement, including resection, in combination with antibiotic therapy, which may offer long-term palliation with resolution of acute infection and pain.

Regardless of the disease stage, mobile segments of bony sequestrum should be removed without exposing uninvolved bone. The extraction of symptomatic teeth within exposed, necrotic bone should be considered since it is unlikely that the extraction will exacerbate the established necrotic process.

CONCLUSION

BPs associated ONJ is a rare, but serious clinical condition caused by anti-osteoclastic, anti-angiogenic and anti-human endothelial cell proliferation effects of BPs, which inhibit bone turnover. They are commonly developed in those patients who are receiving either long term nitrogen containing IV BPs therapy alone or associated with invasive dental procedure. Therefore, proper dental evaluations and receiving necessary treatment prior to initiating IV BPs therapy is recommended.. Manipulation of IV BPs dosing may be effective in reducing SREs and minimizing BPs associated ONJ. CBCT and morning fasting CTX level are the useful assessment tool to predict risk and to make appropriate line of treatment. In cases of established disease management strategies is mostly palliative and empirical.

REFERENCES

1. McLeod NM, Brennan PA, Ruggiero SL. Bisphosphonate osteonecrosis of the jaw: A historical and contemporary review. *Surgeon* 2012;10:36-42.
2. Suzuki BJB, Klemes AB. "Osteoporosis and osteonecrosis of the jaw." American Dental Hygienists Association (ADHA) Special Supplementary issue – March – 2008.
3. Bertoldo F, Santini D, LoCascio V. Bisphosphonates and osteomyelitis of the jaw: A pathogenic puzzle. *Nat Clin Pract Oncol* 2007;4:711-21.
4. AAOMS Position paper on Bisphosphonates-Related Osteonecrosis of the jaw-2009 Update. Approved by the board of Trustees January 2009.
5. Vincenzi B, Napolitano A, Zoccoli A, Iuliani M, Pantano F, Papapietro N, *et al.* Serum VEGF levels as predictive marker of bisphosphonate-related osteonecrosis of the jaw. *J Hematol Oncol* 2012;5:56.
6. Hewitt C, Farah CS. Bisphosphonate-related osteonecrosis of the jaws: A comprehensive review. *J Oral Pathol Med* 2007;36:319-28.
7. Compston JE, Bilezikian JP. Bisphosphonate therapy for osteoporosis: The long and short of it. *J Bone Miner Res* 2012;27:240-2.
8. NSW Health Guideline. "Prevention of osteonecrosis of the jaw (ONJ) on patients with Bisphosphonates therapy". GL2010_010 July 2010.
9. Popovic KS, Kocar M. Imaging findings in bisphosphonate-induced osteonecrosis of the jaws. *Radiol Oncol* 2010;44:215-9.
10. Lam DK, Sándor GK, Holmes HI, Evans AW, Clokie CM. A review of bisphosphonate-associated osteonecrosis of the jaws and its management. *J Can Dent Assoc* 2007;73:417-22.
11. Reid IR. Osteonecrosis of the jaw: Who gets it, and why? *Bone* 2009;44:4-10.
12. AAE Position Statement. "Endodontic implications of bisphosphonates-Associated osteonecrosis of the jaws." Prepared by the AAE special committee on Bisphosphonates 2006 ([www.aae.org/uploadedfiles/publications_and_research/guidelines_and_position_statements/bisphosphonates statement. pdf](http://www.aae.org/uploadedfiles/publications_and_research/guidelines_and_position_statements/bisphosphonates_statement.pdf)).
13. Woo SB, Hellstein JW, Kalmar JR. Narrative corrected review: Bisphosphonates and osteonecrosis of the jaws. *Ann Intern Med* 2006;144:753-61.
14. Borgioli A, Viviani C, Duvina M, Brancato L, Spinelli G, Brandi ML, *et al.* Bisphosphonates-related osteonecrosis of the jaw: Clinical and physiopathological considerations. *Ther Clin Risk Manag* 2009;5:217-27.
15. Carey JJ, Palomo L. Bisphosphonates and osteonecrosis of the jaw: Innocent association or significant risk? *Cleve Clin J Med* 2008;75:871-9.
16. Borromeo GL, Tsao CE, Darby IB, Ebeling PR. A review of the clinical implications of bisphosphonates in dentistry. *Aust Dent J* 2011;56:2-9.
17. Rizzoli R, Burlet N, Cahall D, Delmas PD, Eriksen EF, Felsenberg D, *et al.* Osteonecrosis of the jaw and bisphosphonate treatment for osteoporosis. *Bone* 2008;42:841-7.
18. Kim YG, Lee YD, Suh JH, Jeon SM. Study on bisphosphonates-related osteonecrosis of the jaw (BRONJ): Case report and literature review. *J Korean Assoc Oral Maxillofac Surg* 2010;36:291-302.
19. Chiandussi S, Biasotto M, Dore F, Cavalli F, Cova MA, DiLenarda R. Clinical and diagnostic imaging of bisphosphonate-associated osteonecrosis of the jaws. *Dentomaxillofac Radiol* 2006;35:236-43.
20. Olutayo J, Agbaje JO, Jacobs R, Verhaeghe V, Velde FV, Vinckier F. Bisphosphonate-related osteonecrosis of the jaw bone: Radiological pattern and the potential role of CBCT in early diagnosis. *J Oral Maxillofac Res* 2010;1:E3:1-9.
21. Marx RE, Cillo JE Jr, Ulloa JJ. Oral bisphosphonate-induced osteonecrosis: Risk factors, prediction of risk using serum CTX testing, prevention, and treatment. *J Oral Maxillofac Surg* 2007;65:2397-410.
22. Kwon YD, Kim YR, Choi BJ, Lee DW, Kim DY. Oral bisphosphonate-related osteonecrosis of the jaws: Favorable outcome after bisphosphonate holiday. *Quintessence Int* 2009;40:277-8.
23. Bagán J, Blade J, Cozar JM, Constela M, GarciaSanz R, Gómez Veiga F, *et al.* Recommendations for the prevention, diagnosis, and treatment of osteonecrosis of the jaw (ONJ) in cancer patients treated with bisphosphonates. *Med Oral Patol Oral Cir Bucal* 2007;12:E336-40.
24. Markiewicz MR, Margarone JE, Campbell JH, Aguirre A. Bisphosphonate-associated osteonecrosis of the jaws: A review of current knowledge. *J Am Dent Assoc* 2005;136:1669-74.
25. Stockmann P, Wehrhan F, Schwarz-Furlan S, Stelzle F, Trabert S, Neukam FW, *et al.* Increased human defensin level shintatan inflammatory etiology of bisphosphonate-associated osteonecrosis of the jaw: An immuno histological study. *J Transl Med* 2011;9:135.
26. Wehrhan F, Hyckel P, Guentsch A, Nkenke E, Stockmann P, Schlegel KA, *et al.* Bisphosphonate-associated osteonecrosis of the jaw is linked to suppressed TGFβ1-signaling and increased Galectin-3 expression: A histological study on biopsies. *J Transl Med* 2011;9:102.
27. Melo MD, Obeid G. Osteonecrosis of the maxilla in a patient with a history of bisphosphonate therapy. *J Can Dent Assoc* 2005;71:111-3.
28. Ruggiero SL, Mehrotra B, Rosenberg TJ, Engroff SL. Osteonecrosis of the jaws associated with the use of bisphosphonates: A review of 63 cases. *J Oral Maxillofac Surg* 2004;62:527-34.
29. Marx RE, Sawatari Y, Fortin M, Broumand V. Bisphosphonate-induced exposed bone (osteonecrosis/osteopetrosis) of the jaws: Risk factors, recognition, prevention, and treatment. *J Oral Maxillofac Surg* 2005;63:1567-75.
30. Walter C, Al-Nawas B, Frickhofen N, Gamm H, Beck J, Reinsch L, *et al.* Prevalence of bisphosphonate associated osteonecrosis of the jaws in multiple myeloma patients. *Head Face Med* 2010;6:11.
31. Bagan JV, Jiménez Y, Hernández S, Murillo J, Díaz JM, Poveda R, *et al.* Osteonecrosis of the jaws by intravenous bisphosphonates and osteoradionecrosis: A comparative study. *Med Oral Patol Oral Cir Bucal* 2009;14:e616-9.
32. Shah SA, Aslam A, Mirza AI, Ali S. Bisphosphonate related osteonecrosis of the jaws. *J Ayub Med Coll Abbottabad* 2010;22:214-7.

33. Marx RE. Pamidronate (Aredia) and Zoledronate (Zometa) induced avascular necrosis of the jaws: A growing epidemic. *J Oral Maxillofac Surg* 2003;61:1115-7.
34. Epstein MS, Wicknick FW, Epstein JB, Berenson JR, Gorsky M. Management of bisphosphonate-associated osteonecrosis: Pentoxifylline and tocopherol addition to antimicrobial therapy. An initial case series. *Oral Surg Oral Med Oral Pathol Oral Radiol Endod* 2010;110:593-6.
35. Cella L, Oppici A, Arbasi M, Moretto M, Piepoli M, Vallisa D, *et al.* Autologous bone marrow stem cell intralesional transplantation repairing bisphosphonate related osteonecrosis of the jaw. *Head Face Med* 2011;7:16.
36. Nocini PF, Saia G, Bettini G, Ragazzo M, Blandamura S, Chiarini L, *et al.* Vascularized fibula flap reconstruction of the mandible in bisphosphonates related osteonecrosis. *Eur J Surg Oncol* (2008), Doi:10.1016/j.ejso.2008.05.002 1-7.
37. Freiberger JJ, Padilla-Burgos R, Chhoeu AH, Kraft KH, Boneta O, Moon RE, *et al.* Hyperbaric oxygen treatment and bisphosphonate-induced osteonecrosis of the jaw: A case series. *J Oral Maxillofac Surg* 2007;65:1321-7.
38. Erkan M, Bilgi O, Mutluoğlu M, Uzun G. Bisphosphonate-related osteonecrosis of the jaw in cancer patients and hyperbaric oxygen therapy. *JOP* 2009;10:579-80.

How to cite this article: Kumar V, Shahi AK. Nitrogen containing bisphosphonates associated osteonecrosis of the jaws: A review for past 10 year literature. *Dent Res J* 2014;11:147-53.

Source of Support: Nil. **Conflict of Interest:** None declared.