

Available online at [www.sciencedirect.com](http://www.sciencedirect.com)

ScienceDirect

journal homepage: <http://Elsevier.com/locate/radcr>

## Complications of Therapy

# Perigraft air mimicking infection on CT angiography following open abdominal aortic aneurysm repair

Bradley Trinidad MD\*, Craig Weinkauff MD, PhD, John Hughes MD

Banner University Medical Center-University of Arizona, Tucson, AZ 85724-5072, USA

### ARTICLE INFO

#### Article history:

Received 26 November 2017

Accepted 6 January 2018

Available online 3 February 2018

#### Keywords:

Perigraft air

Aortic graft infection

### ABSTRACT

Aortic graft infection is a feared complication after open abdominal aortic aneurysm repair secondary to its high mortality. Perigraft air is a common finding after open aortic aneurysm repair; however, it is also associated with aortic graft infection. Delineating between graft infection and common postoperative finding is a challenge. This is further complicated by use of hemostatic agents such as Gelfoam, which is also documented to cause perigraft air. Correct diagnosis has crucial implications in management of potential aortic graft infection, which is a vascular emergency. We report a case of perigraft air in a patient status after open aortic aneurysm repair with associated clinical manifestations of infection in whom conservative management and surveillance was selected for treatment. We then discuss the timeline of perigraft air, potential causation, importance of history, and physical examination, and finally, we discuss how specific findings on computed tomography imaging for infection in other areas may be useful in aortic graft infection.

© 2018 the Authors. Published by Elsevier Inc. under copyright license from the University of Washington. This is an open access article under the CC BY-NC-ND license (<http://creativecommons.org/licenses/by-nc-nd/4.0/>).

## Background

After open abdominal aortic aneurysm repair, one of the most feared complications is aortic graft infection. Although rare [1], with a reported incidence of 0.6%–3.0%, aortic graft infections carry mortality rates as high as 20%–40% [2]. In a patient presenting postoperatively with infectious symptomology and imaging findings such as perigraft air, delineating between graft infection and common postoperative findings is challenging [3–6]. Further complicating these cases is the use of hemostatic agents such as absorbable gelatin sponge (Gelfoam, Pfizer), which have also been documented to leave foci of gas [6]. Correct

diagnosis has important implications as graft infection is a true vascular emergency. Presented in the following paragraph is a case of a patient who presented after open aortic aneurysm repair with leukocytosis and imaging findings of perigraft air. The challenge posed was differentiating the causation of these findings, and whether to proceed with graft explantation.

## Case presentation

A 57-year-old man with hypertension and coronary artery disease originally presented with an incidental finding of a small

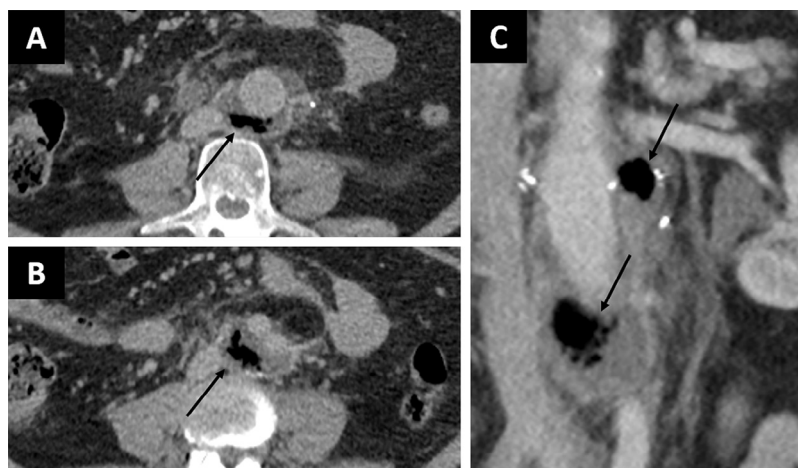
Competing Interests: The authors have declared that no competing interests exist.

\* Corresponding author.

E-mail address: [bradtrinidad@gmail.com](mailto:bradtrinidad@gmail.com) (B. Trinidad).

<https://doi.org/10.1016/j.radcr.2018.01.020>

1930-0433/© 2018 the Authors. Published by Elsevier Inc. under copyright license from the University of Washington. This is an open access article under the CC BY-NC-ND license (<http://creativecommons.org/licenses/by-nc-nd/4.0/>).



**Fig. 1 – Axial (A and B) and coronal (C) views of computed tomography angiography done 3 weeks postoperatively. Arrows point to gas and fluid collections which occurred posteromedial and posterolateral in the proximal and distal portions of the graft.**

infrarenal abdominal aortic aneurysm (AAA) found during workup of nonrelated abdominal pain at an outside hospital. He had also endorsed chronic back pain requiring surgery, a history of kidney stones, and was a current smoker. Ultrasound revealed a 3.7-cm infrarenal fusiform aneurysm. He was lost to follow-up.

Two years later, the patient presented to the emergency room with severe left flank pain, tearing abdominal pain, and nausea. Computed tomography angiography (CTA) revealed a non-ruptured 4.6-cm infrarenal AAA. He was transferred to our facility for higher level of care. Open repair was performed for a symptomatic abdominal aortic aneurysm with an 18-mm bifurcated Dacron (Hemashield) graft. He was released on postoperative day 4 in good condition.

On postoperative day 14, he returned to an outside hospital febrile with severe left-hip and flank pain, and leukocytosis of 14,000. Because of his signs, symptoms, and recent AAA repair, he was transferred back to our facility. CTA revealed pockets of air and fluid along the posterior aspect of the aorta—concerning for possible graft infection.

Other than his initial leukocytosis and fever, he was otherwise asymptomatic. He had no signs of an aortoenteric fistula. His blood cultures and urine cultures were negative. He had no other identifiable infectious etiologies. He was started on broad-spectrum antibiotics on day 1, but these were shortly discontinued due to a clinical picture not consistent with an infectious etiology. He was observed and was afebrile and hemodynamically stable throughout his stay, with normalization of his leukocytosis. A repeat CTA of the abdomen and pelvis 19 days postoperatively revealed continued persistence of periaortic fluid and foci of gas, which radiology remarked being primarily concerning for infection (Fig. 1). However, he remained afebrile and continued to have no leukocytosis and expressed his desires to return home. The decision was made to discharge him with plans for follow-up in clinic.

At follow-up, he continued to feel well without infectious-like symptoms, although he did express continuing chronic back pain. No CTA was performed at that time. A subsequent repeat CTA at 12 weeks postoperatively revealed the periaortic air had

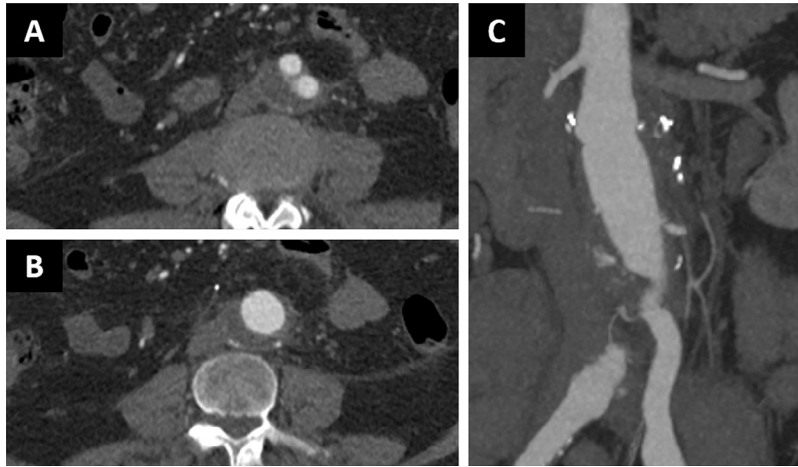
resolved, with some remnant periaortic fluid (Fig. 2). Conservative management was continued and he continues to do clinically well from a vascular perspective.

## Discussion

Aortic graft infections are a rare but ominous complication of open aortic aneurysm repair, with overall mortality reported as high as 40% [2]. Perigraft air is a common finding associated with open aortic aneurysm repair [3–6] and is believed to be a result of air trapping in the periprosthetic space during abdominal closure after open abdominal aortic reconstruction [4]. Perigraft air is also a typical finding seen in aortic graft infection. Its finding has also been linked with the use of bioabsorbable hemostatic agents, such as Gelfoam [7]. The case presented reveals the difficulty in diagnosing aortic graft infection, even with radiological findings suggestive of it.

Postoperative perigraft air found 7 days to 6 weeks postoperatively is considered normal, with findings of air over 6 weeks after surgery suggestive of graft infection [2–4]. Findings later than 2–3 months postoperatively are suggestive of aortoenteric fistula [5]. Although deemed more than likely innocuous in the first few weeks postoperatively, this has not been found in association with clinical findings suspicious for infection. Ball et al. did report a similar case as described previously. In their patient, perigraft air was found on CTA 15 days postoperatively after open aortic aneurysm repair. Their patient presented with 10 days of previous pyrexia of unknown etiology. Similar to the previous case, conservative management was chosen and a follow-up CT scan 6 weeks later revealed the perigraft air had completely resolved [6].

One consideration was Gelfoam placement intraoperatively. Because of the finding of periaortic graft air appearing in the same location as known Gelfoam placement in the posterior aspect of the graft at case conclusion, the possibility of residual thrombin-soaked Gelfoam causing the remnant perigraft air was also discussed. Gelfoam is a water-insoluble



**Fig. 2 – Axial (A and B) and coronal (C) views of computed tomography angiography done 12 weeks postoperatively. Of note, gas is gone and fluid collections are much decreased in size.**

sponge prepared from purified porcine skin gelatin used as a passive topical hemostatic agent. It also provides a mechanical matrix for platelet aggregation [7]. Literature on the role of Gelfoam in radiographical findings after open aortic aneurysm repair is sparse. However, a case report by Black et al. [8] at George Washington University did look at the possible role of Gelfoam in a patient who presented 6 weeks postoperatively after an open ascending aortic aneurysm repair with a 1-week history of night sweats, fever, and chills, whom they suspected of having an abscess at the site of repair. After an extensive workup, including a negative WBC scan and negative exploratory laparotomy, they concluded that the region of extensive absorbable gelatin sponge packing during the initial procedure corresponded to the site of the gas collection demonstrated, and likely the causation of postoperative air. More recently, the role of Gelfoam after neurosurgical procedures has also been studied. One study, looking to identify imaging features of gelatin-thrombin matrix hemostatic after resection of intracranial neoplasms, identified air as a typical finding postoperatively with Gelfoam use [9].

No study has looked at the differentiation of remnant air status after open aortic aneurysm repair; however, Sandrasegaran et al. [10] at Indiana University attempted to differentiate CT findings of Gelfoam from infection or normal finding, albeit after various other intraabdominal surgeries including open hysterectomy, liver transplant, and bowel resection. They found that air caused by Gelfoam tended to present more linearly, with fixed spatial positioning, contrasted to the more random nature of the air foci seen in infection. Air-fluid levels and rim enhancement were also more suggestive of concurrent infection.

It is unclear how the findings of Sandrasegaran et al. could translate in a patient with a finding of periaortic air status after open aortic repair, but some of the basic principles could apply. History and physical examination will continue to be vital in differentiating benign finding from aortic graft infection. However, it is clear that even combined with known infectious clinical findings such as fever or leukocytosis, aortic graft infection is far from certain. There may be a role for identifying specific radiological findings related to aortic graft infection,

but much study still must be done in this regard. Additional imaging studies, such as Fluorodeoxyglucose-PET or WBC-tagged scans, may be of benefit; however, although sensitive, they still lack specificity needed for accurate diagnosis of aortic graft infection [11]. Further, they are quite expensive and are not available in every facility.

## Conclusion

Aortic graft infection is a feared complication of open abdominal aortic aneurysm repair with high mortality. Perigraft air is a known radiographic sign of aortic graft infection; however, it is not specific and may represent a benign postoperative finding. Specific radiological findings associated with infection found on CT in other abdominal disease processes may be relevant in delineating aortic graft infections; however, further work must be done in describing this. Ultimately, clinical suspicion may continue to be our best tool in deciding treatment management of these patients.

## REFERENCES

- [1] O'Conner S, Andrew P, Batt M, Becquemin JP. A systematic review and meta-analysis of treatments for aortic graft infection. *J Vasc Surg* 2006;44(1):38–45.
- [2] Orton D, LeVeon R, Saigh J, Culp W, Fidler J. Aortic prosthetic graft infections: radiologic manifestations and implications for management. *Radiographics* 2000;4:977–93.
- [3] O'Hara PJ, Borkowski GP, Hertzner NR, O'Donovan PB, Brigham SL, Beven EG. Natural history of periprosthetic air on computerized axial tomographic examination of the abdomen following abdominal aortic aneurysm repair. *J Vasc Surg* 1984;1(3):429–33.
- [4] Qvarfordt PG, Reilly LM, Mark AS, Goldstone J, Wall SD, Ehrenfeld WK, et al. Computerized tomographic assessment of graft incorporation after aortic reconstruction. *Am J Surg* 1985;150(2):227–31.
- [5] Kakkos SK, Papadoulas S, Tsolakis IA. Endovascular management of arterioenteric fistulas: a systemic review

- and meta-analysis of the literature. *J Endovasc Ther* 2011;18:66-77.
- [6] Ball E, Morris-Stiff G, Coxon M, Lewis MH. Perigraft air is not always pathological: a case report. *J Med Case Rep* 2007;1:63. doi:10.1186/1752-1947-1-63.
- [7] Guralnick W. Gelfoam absorbable gelatin sponge, prescribing information. New York: Pfizer; 2012.
- [8] Black C, Rockoff S, Alyono D. Sterile mediastinal gas mimicking abscess in aortic aneurysm repair. *Chest* 1992;102(6):1911-13.
- [9] Learned KO, Mohan S, Hyder IZ. Imaging features of a gelatin-thrombin matrix hemostatic agent in the intracranial surgical bed. *AJNR Am J Neuroradiol* 2014;35(4):686-90.
- [10] Sandrasegaran K, Lall C, Rajesh A, Maglinte D. Distinguishing gelatin bioabsorbable sponge and postoperative abdominal abscess on CT. *AJR Am J Roentgenol* 2005;184:475-80. doi:10.2214/ajr.184.2.01840475.
- [11] Keidar Z, Nitecki S. FDG-PET in prosthetic graft infections. *Semin Nucl Med* 2013;43(5):396-402.