

Arthroscopic Repair of Medial Transtendinous Rotator Cuff Tears



Brian J. Kelly, M.D., and Larry D. Field, M.D.

Abstract: Rotator cuff tears are extremely common in the adult population, and medial transtendinous rotator cuff tears, although rare, have recently been reported in the literature. These tears are almost always traumatic, which is a common indication for surgical management. It is necessary to consider these tears as a distinct subset when planning for rotator cuff repair because traditional repair techniques would overtension the tendon, increasing the risk for failure of the repair. The objective of this Technical Note is to describe an arthroscopic repair technique for these tears that avoids overtensioning the rotator cuff while still using repair techniques that are familiar to the arthroscopic shoulder surgeon.

Rotator cuff tears are extremely common in the adult population, and there has been a lot of recent research devoted to determining the best techniques for rotator cuff repair. Most rotator cuff tears occur at the tendon-bone junction, and most of the techniques described for rotator cuff repair assume this general tear pattern. Rotator cuff tears that occur within the tendon but medial to the attachment site on the greater tuberosity are very rare, and there is very little literature regarding how to treat these tears.¹ Partial-thickness intratendinous tears of the supraspinatus tendon have been described, but there were no instances of full-thickness tears in these studies.^{2,3} A study by Cohen et al.⁴ looked at the epidemiology of rotator cuff contusions in professional football players, and the investigators identified one player with an intrasubstance rotator cuff tear on magnetic resonance imaging. A recent study by Walcott et al.¹ was the first to report specifically on transtendinous tears of the rotator cuff.

While the literature on rotator cuff repair techniques is extensive, only the study by Walcott et al. considers a technique to repair transtendinous rotator cuff tears. In their study, they found that all of the rotator cuff tears that fit this pattern occurred after a traumatic injury, with the proposed mechanism being a fall on an abducted arm.¹ A traumatic rotator cuff tear is usually considered to be an indication for surgical management, and techniques to repair these tears are important to have available when these patients are encountered. A medial transtendinous tear has a significant amount of intact lateral tendon remaining on the greater tuberosity, which presents a unique challenge when undertaking an arthroscopic repair. If this portion of the tendon is debrided, the remaining tendon would not be sufficient to repair back to the greater tuberosity without changing the length-tension relationship of the rotator cuff.¹ This is distinct from a tear at the muscle-tendon junction, which does not have sufficient repairable tendon medially, and a tear at the tendon-bone junction, which can be repaired directly to the greater tuberosity (Table 1). The arthroscopic technique we describe here avoids overtensioning the rotator cuff tendons while still using repair techniques that are familiar to the arthroscopic shoulder surgeon.

From the Mississippi Sports Medicine and Orthopaedic Center, Jackson, Mississippi, U.S.A.

The authors report the following potential conflicts of interest or sources of funding: L.D.F. receives support from the Arthroscopy Association of North America. Full ICMJE author disclosure forms are available for this article online, as supplementary material.

Received February 22, 2017; accepted August 8, 2017.

Address correspondence to Brian J. Kelly, M.D., Mississippi Sports Medicine and Orthopaedic Center, 1325 East Fortification Street, Jackson, MS 39202, U.S.A. E-mail: brianjkelly23@gmail.com

© 2017 by the Arthroscopy Association of North America. Published by Elsevier. This is an open access article under the CC BY-NC-ND license (<http://creativecommons.org/licenses/by-nc-nd/4.0/>).

2212-6287/17227

<http://dx.doi.org/10.1016/j.eats.2017.08.026>

Surgical Technique

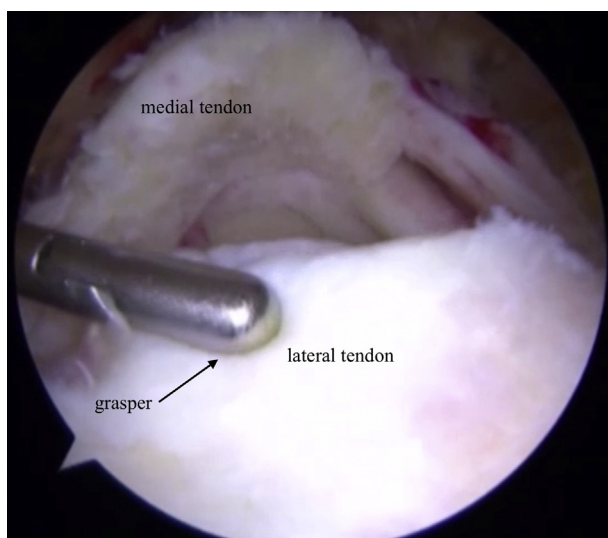
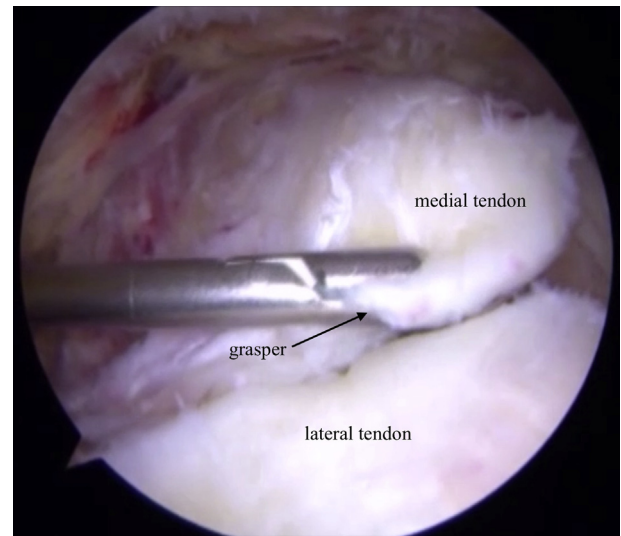
Setup and Initial Evaluation

The authors prefer the beach chair position when treating rotator cuff pathology. A standard posterior portal is established, and a thorough diagnostic arthroscopy is performed to identify any intra-articular

Table 1. Comparison Between Tendon-Bone Junction and Transtendinous Tears

| Tendon-bone Junction Tear | Medial Transtendinous Tear |
|---|--|
| May be acute or chronic | Usually acute |
| May be traumatic or atraumatic | Always traumatic |
| Tendon retracted from greater tuberosity with minimal intact tendon remaining attached to the bone; any remaining tendon is usually poor quality. | Significant portion of lateral tendon remains intact on the greater tuberosity; the tendon is also of sufficient quality to incorporate into a repair. |
| Tendon can often be repaired to directly to the footprint without significantly altering the length-tension relationship of the rotator cuff. | The medial portion of the tendon cannot be repaired directly to the footprint without overextending the repair construct. |

pathology. The rotator cuff is inspected from the articular side, and the medial transtendinous tear can often be identified. The edges of the tear can be debrided some if necessary to help confirm that it is a full-thickness tear, but it is generally more effective to debride the tear from the subacromial working space. The camera is removed from the joint, and the subacromial space is entered from the posterior portal using a blunt trocar to clear bursal adhesions. A lateral portal is established using spinal needle localization to ensure that the lateral edge of the acromion will not interfere with debridement or visualization of the rotator cuff tear. A bursectomy and initial debridement of the rotator cuff tear are carried out, and an acromioplasty and distal clavicle excision may be performed if indicated.

**Fig 1.** Arthroscopic view of the right shoulder in the beach chair position from the lateral portal in the subacromial space showing a significant portion of the lateral tendon that remains attached to the greater tuberosity.**Fig 2.** Arthroscopic view of the right shoulder in the beach chair position from the lateral portal in the subacromial space showing the retracted medial portion of the tendon held in an anatomically reduced position.

Tear Classification

The camera is then moved to the lateral portal to allow better visualization and classification of the rotator cuff tear. A medial transtendinous tear will have a significant portion of the lateral tendon still attached to the greater tuberosity (Fig 1). There will also be a significant portion of the tendon remaining with the retracted medial portion, and this can be reduced to the lateral portion of the tendon to confirm the transtendinous tear pattern (Fig 2). The camera can be moved to the posterior portal to facilitate viewing of the tear pattern and the greater tuberosity, which is hidden from view by the intact lateral tendon when viewing from the lateral portal (Fig 3).

Tear Debridement and Tuberosity Preparation

Accessory anterolateral or posterolateral portals can be established if necessary to gently debride the edges of the tendon, and the repair is carried out (see Video 1). A grasper is used to assist with mobilization of the tendon, but it will be clear that if the medial portion of the tendon is mobilized to the greater tuberosity, there will be too much tension on the repair construct (Fig 4). The area of the supraspinatus footprint that is within the transtendinous tear is prepared using an arthroscopic shaver or burr until bleeding bone is exposed. A 5.5-mm triple-loaded biocomposite suture anchor (Arthrex, Naples, FL) is inserted into the prepared footprint (Fig 5).

Suture Passage and Knot Tying

The sutures are passed in a side-to-side configuration using a retrograde suture retriever (IDEAL suture

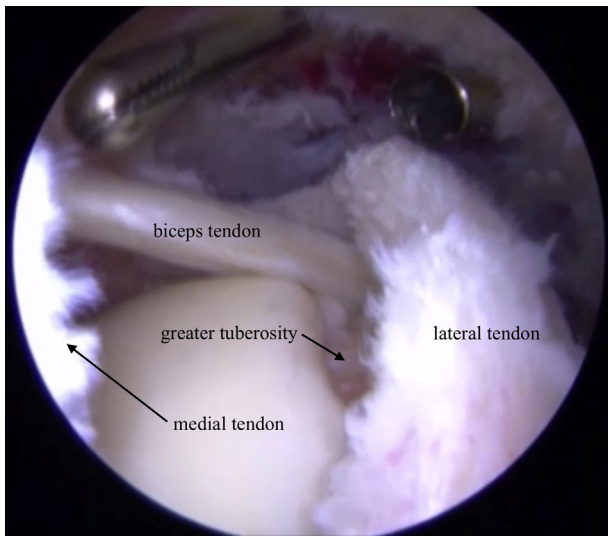


Fig 3. Arthroscopic view of the right shoulder in the beach chair position from the posterior portal in the subacromial space showing how the posterior viewing portal facilitates confirmation of the tear pattern and visualization of the greater tuberosity.

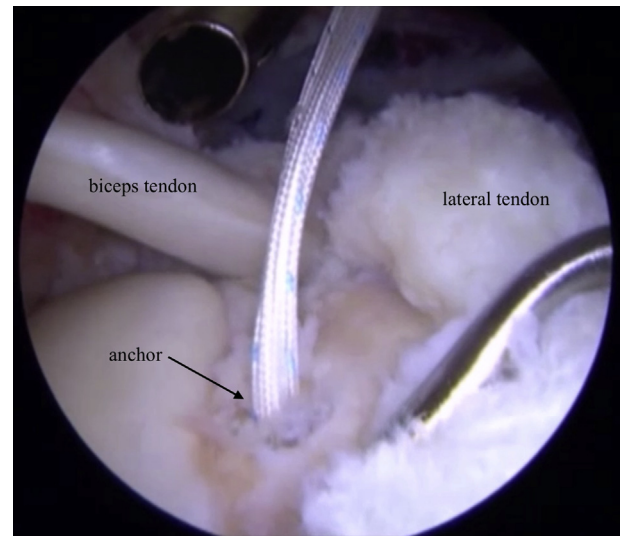


Fig 5. Arthroscopic view of the right shoulder in the beach chair position from the posterior portal in the subacromial space showing a triple-loaded suture anchor placed at the medial edge of the greater tuberosity after footprint preparation has been completed.

passer, Depuy Mitek, Raynham, MA) to pass one limb of each pair of sutures through the medial tendon and one limb through the lateral tendon (Fig 6). Additional free convergence sutures can be passed through the medial and lateral portions of the tendon to strengthen the construct. A tendon grasper is used to manipulate the tendon edges during suture passage and to confirm

that an anatomic reduction will be achieved (Fig 7). The camera is returned to the lateral portal, and a cannula is placed in the posterior portal for suture management. The sutures are then retrieved and tied from posterior to anterior, and an anatomic reduction is achieved (Fig 8). This technique can be modified as necessary by employing multiple suture anchors or additional free convergence sutures depending on the size of the tear.

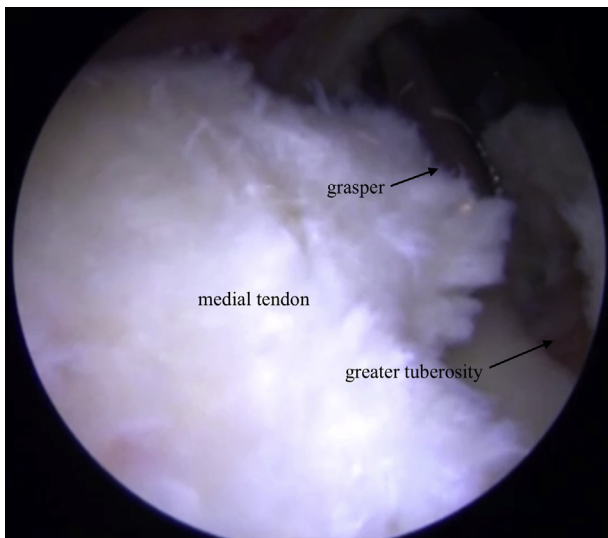


Fig 4. Arthroscopic view of the right shoulder in the beach chair position from the posterior portal in the subacromial space with a tendon grasper attempting to reduce the retracted medial portion of the tendon to the greater tuberosity. It is clear that this would create an overtensioned construct if this portion of the tendon is repaired to the greater tuberosity.

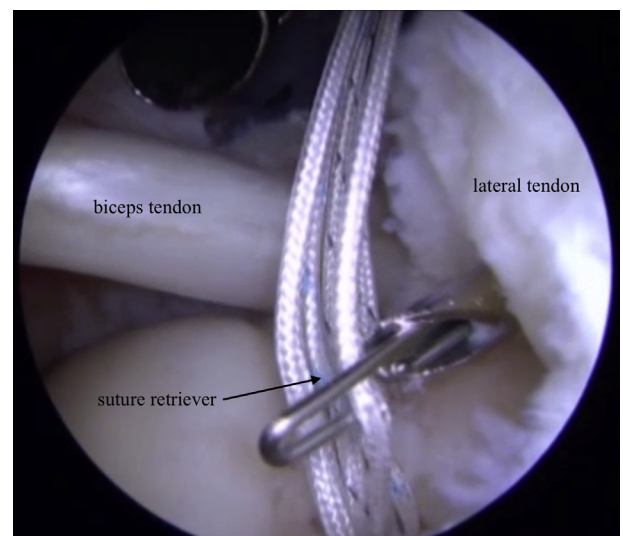


Fig 6. Arthroscopic view of the right shoulder in the beach chair position from the posterior portal in the subacromial space showing a suture being passed through the lateral portion of the tendon using a retrograde suture retriever.

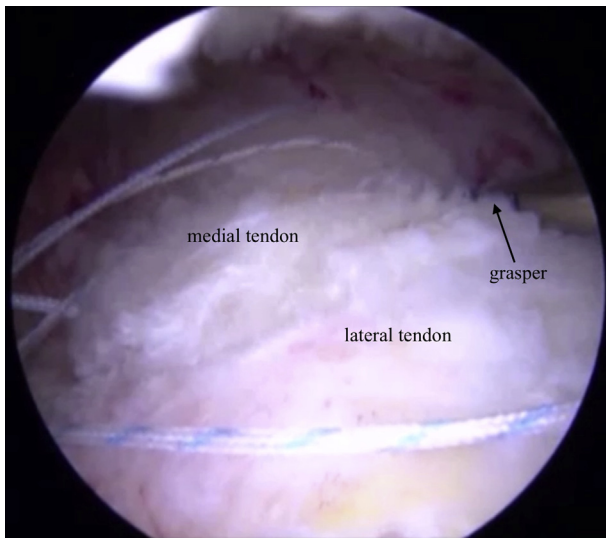


Fig 7. Arthroscopic view of the right shoulder in the beach chair position from the lateral portal in the subacromial space showing the medial portion of the tendon held in an anatomically reduced position by a grasper after all suture passage has been completed.

Discussion

Medial transtendinous rotator cuff tears are rare, but they have been recently identified in a subset of patients who sustained a traumatic injury. Walcott et al.¹ found an incidence of 1.79% of all patients being evaluated for rotator cuff repair in their study, and these patients were all found to have a traumatic mechanism. The proposed mechanism for these tears is a fall onto an abducted arm, forcing the supraspinatus

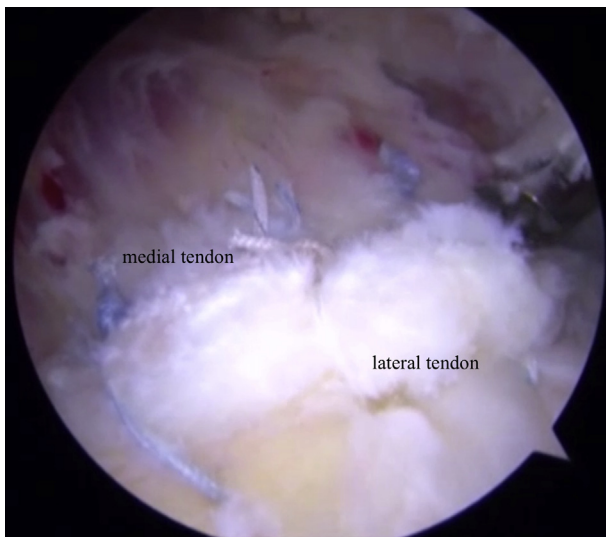


Fig 8. Arthroscopic view of the right shoulder in the beach chair position from the lateral portal in the subacromial space showing the final repair construct. The tendon has been repaired in an anatomic position without over-tensioning the construct.

Table 2. Pearls and Pitfalls of the Technique

| Pearls | Pitfalls |
|---|---|
| Consider the possibility of a medial transtendinous tear in patients who sustain a fall onto an abducted arm, particularly if there is magnetic resonance imaging evidence of an intact lateral tendon footprint. | Confirm that a medial transtendinous tear is present before passing sutures. If there is not enough good-quality tendon laterally on the greater tuberosity, the sutures will pull through. |
| Use a traction suture or tendon grasper to anatomically reduce the tendon while passing sutures to ensure recreation of the native tendon anatomy. | If the suture anchor is not placed at the most medial aspect of the greater tuberosity, there is a risk of over-tensioning the medial tendon. |

into the lateral acromion (Fig 7).¹ Acute traumatic rotator cuff tears have been found by Cofield et al.⁵ to have an incidence of 8%, but 2 recent systematic reviews of traumatic rotator cuff tears did not specifically report on the incidence of transtendinous tears.^{6,7} This tear pattern will likely become more widely recognized now that it has been described in the literature, and there are important technical considerations when treating these patients (Table 2).

It is necessary to consider medial transtendinous tears as a distinct subset when planning for rotator cuff repair because traditional repair techniques would over-tension the tendon back to the greater tuberosity, causing a significant alteration in the length-tension relationship. It has been found that changes in the length-tension relationship that result from over-tensioning the tendon to the greater tuberosity are a risk factor for repair failure medial to the repair construct.^{8,9} By leaving the lateral portion of the tendon attached to the greater tuberosity and using a side-to-side configuration to reapproximate the

Table 3. Advantages and Limitations of the Technique

| Advantages | Limitations |
|---|--|
| The repair can be completed using standard arthroscopic instruments and techniques that are familiar to the arthroscopic shoulder surgeon. | Sutures must be passed through both sides of the tear; this requires a higher level of technical skill when passing sutures, particularly if the surgeon is not accustomed to retrograde suture passage. |
| The technique avoids debriding the good-quality tendon tissue that remains attached to the greater tuberosity. | Sutures are passed side-to-side through both tendon edges, so rip-stop suture configurations or knotless techniques cannot be used. |
| The repair construct does not excessively over-tension the medial tendon or significantly alter the normal length-tension relationship of the rotator cuff. | The suture anchor must still be placed into the greater tuberosity, so there is still a risk of slightly over-tensioning the medial portion of the tendon. |

tendon, the technique described here avoids this potential pitfall.

Walcott et al.¹ were the first to report on the outcomes of medial transtendinous rotator cuff repair. They had an average patient age of 47.9, and all patients were male, had an injury involving their dominant arm, and had a traumatic mechanism. The outcome scores, range of motion, and abduction and external rotation strength improved in all patients; the subjective shoulder value scores improved significantly from 47.8 preoperatively to 96.4 postoperatively, and the postoperative American Shoulder and Elbow Surgeons score was 97.9. There are no long-term outcomes for medial transtendinous rotator cuff repairs in the literature.

While medial transtendinous rotator cuff tears are rare, they represent a subset of tears that shoulder surgeons need to be aware of, particularly when the mechanism is a fall onto an abducted arm. This tear pattern requires a repair technique that addresses a unique set of challenges, particularly avoiding over-tensioning the repair construct by repairing the medial portion of the tendon to the greater tuberosity; the technique also has a unique set of advantages and disadvantages (Table 3). The technique described here is accessible to all arthroscopic shoulder surgeons using familiar equipment, portals, and suture passage techniques to achieve a repair construct that is not over-tensioned and has led to good clinical outcomes.

References

1. Walcott ME, Daniels SD, Sinz NJ, Field LD, Higgins LD. Traumatic full-thickness transtendinous rotator cuff tears: a case series. *J Shoulder Elbow Surg* 2017;26:62-67.
2. Clavert P, Coniat YL, Kempf JF, Walch G. Intratendinous rupture of the supraspinatus: Anatomy and functional results of 24 operative cases. *Eur J Orthop Surg Traumatol* 2016;26:133-138.
3. Park SE, Panchal K, Jeong JJ, et al. Intratendinous rotator cuff tears: Prevalence and clinical and radiological outcomes of arthroscopically confirmed intratendinous tears at midterm follow-up. *Am J Sports Med* 2015;43:415-422.
4. Cohen SB, Towers JD, Bradley JP. Rotator cuff contusions of the shoulder in professional football players: epidemiology and magnetic resonance imaging findings. *Am J Sports Med* 2007;35:442-447.
5. Cofield RH. Rotator cuff disease of the shoulder. *J Bone Joint Surg Am* 1985;67:974-979.
6. Lazarides AL, Alentorn-Geli E, Choi JH, et al. Rotator cuff tears in young patients: a different disease than rotator cuff tears in elderly patients. *J Shoulder Elbow Surg* 2015;24:1834-1843.
7. Mall N, Lee AS, Chahal J, et al. An evidenced-based examination of the epidemiology and outcomes of traumatic rotator cuff tears. *Arthroscopy* 2013;29:366-376.
8. Coleman SH, Fealy S, Ehteshami JR, et al. Chronic rotator cuff injury and repair model in sheep. *J Bone Joint Surg Am* 2003;85:2391-2402.
9. Yamakado K, Katsuo S, Mizuno K, Arakawa H, Hayashi S. Medial-row failure after arthroscopic double-row rotator cuff repair. *Arthroscopy* 2010;26:430-435.