


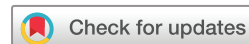When steroids are not enough in immune-related hepatitis: current clinical challenges discussed on the basis of a case report

Dimitrios C Ziogas,¹ Aikaterini Gkoufa,¹ Evangelos Cholongitas,¹ Panagiotis Diamantopoulos,¹ Amalia Anastasopoulou,¹ Paolo Antonio Ascierto ,² Helen Gogas¹

To cite: Ziogas DC, Gkoufa A, Cholongitas E, *et al*. When steroids are not enough in immune-related hepatitis: current clinical challenges discussed on the basis of a case report. *Journal for ImmunoTherapy of Cancer* 2020;**8**:e001322. doi:10.1136/jitc-2020-001322

DCZ and AG contributed equally.

Accepted 12 October 2020



© Author(s) (or their employer(s)) 2020. Re-use permitted under CC BY-NC. No commercial re-use. See rights and permissions. Published by BMJ.

¹First Department of Medicine, National and Kapodistrian University of Athens School of Medicine, Athens, Greece

²Istituto Nazionale Tumori IRCCS Fondazione Pascale, Napoli, Italy

Correspondence to

Professor Helen Gogas;
helgogas@gmail.com

ABSTRACT

Unleashing adaptive immunity via immune checkpoint inhibitors (ICPIs) in many cancer types led to durable antitumor responses and prolonged survivals and also added some new immune-related adverse events (irAEs) to the 'old-fashioned' safety profile of chemotherapy. Among bowel and endocrine irAEs, immune-mediated hepatotoxicity/hepatitis is a less common and far less well-studied toxicity, which, however, could develop into a serious complication, especially when it becomes persistent or refractory to steroids. Its incidence, onset and severity vary widely, depending on the type of underlying treated cancer, the class, the dosage and the duration of immunotherapy as well as the way of its administration (as a single agent or in combination with other ICPI or chemotherapy). In this study, we present a patient with metastatic melanoma who developed severe steroid-resistant ir-hepatitis after treatment with ipilimumab and required triple concurrent immunosuppression with prednisolone, mycophenolate mofetil and tacrolimus in order for his liver toxicity to be resolved. Intrigued by this case, we focused further on melanoma, as the disease-paradigm of immunotherapy in cancer, reviewed the reported incidence of hepatotoxicity among phase III ICPIs-containing trials on melanoma and discussed the main clinical considerations regarding the diagnosis and the management of persistent/steroid-refractory ir-hepatitis. As more clinical experience is gradually gained on this challenging topic, better answers are provided to questions about the appropriate diagnostic workup, the necessity of liver biopsy, the available immunosuppressive options beyond corticosteroids (their combinations and/or their sequence) as well as the correct decision on withdrawing or resuming immunotherapy. Nonetheless, a thorough multidisciplinary discussion is still required to individualize the overall approach in each case after failure of steroids.

INTRODUCTION

Alongside the established clinical benefits, immune-checkpoint inhibitors (ICPIs) have also introduced into oncological practice some distinct immune-mediated toxicities which mimic autoimmune conditions and affect multiple organs, including the

liver.^{1 2} In contrast to bowel and endocrine ICPIs-induced toxicities, hepatotoxicity/hepatitis is a less common and far less well-studied adverse event (AE).^{3 4} Its incidence, onset and severity vary widely, depending on the type of underlying malignancy as well as on the class, the dosage, the duration and mainly the way immunotherapy was administered (as a single agent or in combination with other ICPI or chemotherapy).^{5 6} For instance, in patients with melanoma receiving monotherapy with pembrolizumab, immune-related (ir) hepatitis occurs in 0.8%, including grade 2, 3 or 4 events in 0.1%, 0.5% and 0.1% of cases, respectively,^{7 8} while in those treated with the combination of nivolumab 1 mg/kg and ipilimumab 3 mg/kg, ir-hepatitis is listed as a common ($\geq 1/100$ to $< 1/10$) AE. In this approved antimelanoma immune-combination, liver function tests (LFTs) were detected abnormal in 29.5% of patients, including grade 2, 3 and 4 events in 6.7%, 15.4% and 1.8% of cases, respectively.^{9 10} Without completely understanding the exact pathophysiological mechanism, immune checkpoint inhibition seems to induce hepatic infiltration by activated T cells bringing on the development of primary liver damage. Double anti-PD-1 and anticytotoxic T-lymphocyte antigen 4 (anti-CTLA-4) inhibition may cause an overlapping synergistic effect that enhances the local immune reaction.¹¹ The median time to hepatotoxicity onset is estimated at 3.6 (range: 0.27–21.4) months for pembrolizumab and 1.5 (range: 0.0–30.1) months for the nivolumab/ipilimumab combination while the median time to resolution is estimated at 1.1 (range: 0.03–20.9) months and 1.27 (range: 0.03–26.73) months, respectively.^{1 2 6 12}

No strong randomized evidence exists to guide the management of ir-hepatitis and current recommendations are based on the consensus of European Society for Medical Oncology, American Society of Clinical Oncology, Society for Immunotherapy of Cancer and National Comprehensive Cancer Network experts.^{13–16} Until now, all these oncological societies agree that the two major axes in the therapeutic algorithm are i) the temporary or permanent discontinuation of ICPIs and ii) the immediate delivery of immunosuppressive therapy with corticosteroids playing a cornerstone role. However, if ir-hepatitis is steroid-refractory or requires further immunosuppression to be resolved, the subsequent treatment options are not clearly determined, so a multidisciplinary approach including oncologists, hepatologists and emergency care providers is required.

Herein, we describe a patient with relapsed metastatic melanoma who developed moderate ir-hypophysitis and severe ir-hepatitis simultaneously after ipilimumab administration, yet steroids were not enough in his case as triple immunosuppression was required in order to resolve his hepatotoxicity. Triggered by this case, we reviewed the recorded occurrence of hepatotoxicity in phase III immunotherapy trials on melanoma, recognized the appropriate diagnostic workup, and identified through the literature all ICPI-treated cases with steroid-refractory ir-hepatitis. Based on current evidence on this topic and on our institutional experience, we try to answer when ICPIs should be withdrawn or resumed and which immunosuppressive medications (and their sequence/combination) should support the failure of steroids, proposing an overall approach for patients with ir-hepatitis beyond corticosteroids.

CASE PRESENTATION

A man in his early 70s with a medical history of hypertension (perindopril/amlodipine 5/5mg once daily) and hypothyroidism (T4 75 µg once daily) was diagnosed in January 2018 with a stage IIb cutaneous melanoma (pT3bN0, Breslow 3.65mm, Clark IV, with presence of ulceration and negative sentinel lymph node dissection (SLND)) at his lower back. Ten months later, in November 2018, two new lesions presented in his back, compatible with in-transit metastases of the primary melanoma. After wide resection of both lesions, their histological examination was yet again positive for melanoma with negative SLND. However, the patient refused to receive any adjuvant therapy. Only a month later, in December 2018, a new melanoma relapse was identified, this time with enlarged lymph nodes in the left axilla. Molecular analysis showed no presence of a *BRAF* mutation, so he was started on treatment with nivolumab at 480mg every 4 weeks, in January 2019. After 6 cycles of anti-programmed cell death protein 1 (anti-PD-1) blocking in July 2019, imaging revealed melanoma progression with new lymph nodes in the mediastinum and, therefore, nivolumab was discontinued and ipilimumab, at a dose

of 3mg/kg, was administered as second-line treatment. Before the onset of ipilimumab, his LFTs were normal. A week before his fourth ipilimumab dose, in October 2019, he was admitted to our hospital with generalized weakness and a fever of up to 38.5°C that had started 2 days earlier. Physical examination did not reveal any clinical findings. The white blood cell count was $10.9 \times 10^9/L$, C reactive protein 110mg/L (normal value <5mg/L), erythrocyte sedimentation rate 9mm/hour and serum endocrine parameters were compatible with a moderate hypophysitis, probably induced by ipilimumab (adrenocorticotropic hormone=5pg/mL (10–65pg/mL), cortisol=209.72mmol/L (173.6–505mmol/L), prolactin=8.69ng/mL (7–23ng/mL), follicle stimulation hormone=2.39mIU/mL (3.5–9.2mIU/mL), luteinizing hormone=3mIU/mL (1.9–9.2mIU/mL), testosterone=0.64ng/mL (1.93–7.40ng/mL) and thyroid-stimulating hormone (under T4 treatment)=0.64mU/L (0.27–4.5mU/L)). Blood and urine cultures were negative. At the time of his admission, transaminases and cholestatic enzymes were found significantly elevated (grade 4 elevation of aspartate transaminase (AST): 783IU/L, grade 4 elevation of alanine transaminase (ALT): 1029IU/L, grade 2 elevation of gamma-glutamyl transferase (GGT): 147IU/L, grade 2 elevation of bilirubin: 1.9mg/dL) (figure 1A). Viral causes of hepatitis (eg, hepatitis A, B, C and E viruses, cytomegalovirus, Epstein-Barr and herpes simplex viruses as well as HIV) were excluded and serological assessment for autoimmune hepatic disease, including antinuclear antibodies (ANA), antimitochondrial antibodies (AMA), antismooth muscle antibodies (SMA), antiliver-kidney microsomal antibodies (LKM) and antisoluble liver antigen (SLA), was negative. Besides, during his hospitalization, a whole-body CT scanning ruled out metastatic liver involvement and any other evidence of melanoma progression. Due to the co-existence of immune-mediated hypophysitis, a strong suspicion grew for an immunological origin of hepatitis, so treatment with intravenous methylprednisolone was immediately initiated at a dose of 1mg/kg. Two days later, liver biochemistry continued to worsen, and steroid dose was increased to 2mg/kg (figure 1A). To prevent opportunistic infections, trimethoprim/sulfamethoxazole was also added at a daily dosage of 400/80mg. However, no biochemical response was observed and mycophenolate mofetil (MMF), at a dose of 1000mg intravenously, twice daily, was added as a second immunosuppressive agent 2 days later, together with ursodeoxycholic acid at a dose of 500mg twice daily. Due to a grade 4 thrombocytopenia attributed to MMF, its dose was reduced to 500mg twice daily. Under co-treatment with prednisolone and MMF, no significant improvement of his hepatotoxicity was observed (figure 1A). After a multidisciplinary meeting of medical oncologists, hepatologists and internists, the addition of tacrolimus as a third immunosuppressive agent was decided at a dose of 1.5mg twice daily targeting serum levels between 8 and 10ng/mL. A liver biopsy was considered but was not decided

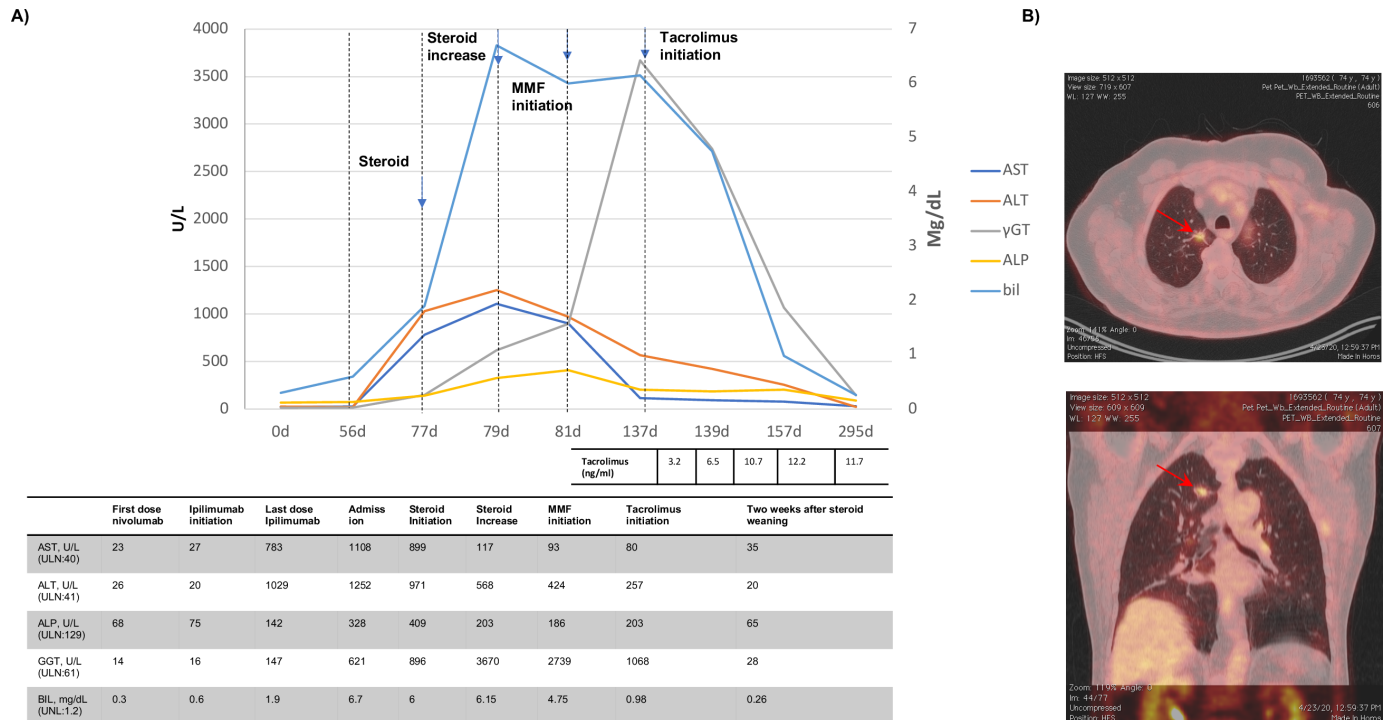


Figure 1 (A) Longitudinal levels of serum ALT, AST, GGT/γGT, ALP and Bil in a patient with melanoma with severe immune checkpoint inhibitor (ICPI)-mediated hepatitis and the immunosuppressive agents used to control this induced hepatotoxicity. ALP, alkaline phosphatase; ALT, alanine aminotransferase; AST, aspartate aminotransferase; Bil, bilirubin; GGT, gamma-glutamyl transferase; ULN, upper normal limit. (B) Fluorodeoxyglucose-positron emission tomography CT (April 2020) revealed abnormal hypermetabolic activity of a solitary lung lesion (maximum standardized uptake value=3.4) with concurrent hyperactive mediastinal lymphadenopathy. Red arrows highlight more clearly the only abnormal hypermetabolic lesion in the lung.

due to weak evidence supporting this intervention as well as increased hemorrhagic risk from the liver dysfunction, the thrombocytopenia and the use of high steroid doses. Just a couple of days after the intensification of his immunosuppression, his liver enzymes showed remarkable improvement and a slow weaning off steroids was initiated. The patient was discharged in December 2019, after 63 days of hospitalization, receiving: i) oral methylprednisolone, equivalent to prednisolone 0.75 mg/kg with the intent to taper it out over a period of 6 weeks, ii) MMF, at 500mg twice daily with the intent to rapidly reduce it (eg, 50%) over a period of 2 weeks due to thrombocytopenia risk and iii) tacrolimus with the intent to keep serum therapeutic levels up to complete normalization of LFTs and steroid weaning. Then, tacrolimus was slowly tapered out (eg, 0.5 mg every week), to avoid an immune flare and was withdrawn 10 weeks after the patient's discharge. At the time of tacrolimus discontinuation, LFTs were normal and no ir-hepatitis relapse was observed 2 weeks later. Endocrine parameters indicative of ir-hypophysitis remained unchanged during the whole period. Despite the hepatitis resolution, immunotherapy was never restarted. Six months after the last infusion of ipilimumab, CT scans in March 2020 detected a new lung lesion in the upper lobe of his right lung. To confirm the origin and the extent of this lesion, he underwent a positron emission tomography/CT scan in April 2020 that showed abnormal hypermetabolic activity of this

lung lesion (maximum standardized uptake value=3.4) with concurrent hyperactive mediastinal lymphadenopathy (figure 1B). Bronchoscopy was performed and tissue biopsy revealed colonization by *Aspergillus* species with no angio-invasive disease (repeated galactomannan blood tests were negative) and in parallel confirmed a concurrent recurrence of his melanoma.

CLINICAL CONSIDERATIONS

How is ir-hepatitis presented and reported in melanoma ICPI-treated patients?

Usually, ir-hepatitis is developed asymptotically with mild elevation of aminotransferases on routine blood testing or with non-specific symptoms (eg, fever, fatigue) and is expressed as a mixed hepatocellular and cholestatic injury.¹⁷ However, in a few cases, if immune-mediated hepatotoxicity remains undiagnosed, untreated or becomes treatment-resistant, it can be worsened with highly increased aminotransferases, obstructive enzymes and serum bilirubin, progressing even to fulminant hepatic failure.^{17,18} The severity of immune-related hepatotoxicity is mainly driven by the elevation of ALT and AST, and do not necessarily require the co-increase of serum bilirubin or obstructive enzymes (eg, alkaline phosphatase (ALP) and GGT).¹⁶ Table 1 summarizes all the phase III trials investigating immunotherapy on patients with melanoma, and presents the rate and the

Table 1 Hepatotoxicity results of phase III trials in patients with melanoma undergoing immunotherapy

| Study | Type of ICPI (dosing schedule) | Cancer setting | AST (n/N, %) | | ALT (n/N, %) | | Hepatitis (n/N, %) | |
|--|--|----------------|---------------|---------------|---------------|--------------|--------------------|-------------|
| | | | All grades | Grades 3–4 | All grades | Grades 3–4 | All grades | Grades 3–4 |
| Eggermont <i>et al</i> (EORTC 18071) ⁶⁴ | Ipilimumab (10 mg/kg every 3 weeks for four doses, then every 3 months for up to 3 years) | Adjuvant | 78/471 (16.5) | 20/471 (4.2) | 102/471 (21) | 25/471 (5) | | |
| Weber <i>et al</i> ⁶⁵ | Nivolumab (3 mg/kg every 2 wks for up to 1 year) | Adjuvant | 25/452 (5.5) | 2/452 (0.4) | 28/452 (6.2) | 5/452 (1.1) | | |
| Tarhini <i>et al</i> (North American Intergroup E1609) ⁶⁶ | Ipilimumab (10 mg/kg every 3 wks for four doses and then every 12 wks for up to 1 year) Ipilimumab (3 mg/kg every 3 wks for four doses, followed by the same dose every 12 wks for up to four additional doses) | Adjuvant | 60/453 (13.2) | 19/453 (4.2) | 66/453 (14.6) | 26/453 (5.7) | | |
| Eggermont <i>et al</i> (KEYNOTE-054) ⁸ | Ipilimumab (10 mg/kg every 3 wks for four doses, followed by the same dose every 12 wks for up to four additional doses) | Adjuvant | 1/131 (0.8) | 0/131 (0) | 2/131 (1.5) | 0/131 (0) | 9/509 (1.8) | 7/502 (1.4) |
| Hodi <i>et al</i> ⁶⁷ | Pembrolizumab (200 mg every 3 wks for up to 1 year) | Metastatic | 66/247 (26.7) | 43/247 (17.4) | 72/247 (29.1) | 51 (20.7) | 4/247 (1.6) | 3/247 (1.2) |
| Robert <i>et al</i> ²¹ | Ipilimumab (3 mg/kg every 3 wks for four doses) Ipilimumab (10 mg/kg plus dacarbazine 850 mg/m ²) | Metastatic | 48/313 (15.3) | 19/313 (6.1) | 55/313 (17.6) | 26/313 (8.3) | 10/313 (3.2) | 8/313 (2.6) |
| Larkin <i>et al</i> (CheckMate067) ^{9,10} | Nivolumab (1 mg/kg every 3 wks)/ ipilimumab (3 mg/kg every 3 wks) for four doses, followed by 3 mg/kg of nivolumab every 2 weeks for cycle three and beyond Ipilimumab (3 mg/kg every 3 wks for four doses) | Metastatic | 11/311 (3.5) | 2/311 (0.6) | 12/311 (3.9) | 5/311 (1.6) | 3/311 (0.9) | 0/311 (0) |
| Robert <i>et al</i> (KEYNOTE-006) ⁷ | Nivolumab (3 mg/kg every 2 wks until PD) Pembrolizumab (200 mg every 3 wks for up to 1 year) | Metastatic | 12/313 (3.8) | 3/313 (1) | 12/313 (3.8) | 4/313 (1.3) | 1/313 (<1) | 1/313 (<1) |
| | Ipilimumab (10 mg/kg every 3 wks for four doses and then every 12 wks) | Metastatic | | | 5/277 (1.8) | | 5/277 (1.8) | 5/277 (1.8) |
| | | Metastatic | | | 3/256 (1.2) | | 3/256 (1.2) | 1/256 (0.4) |

Continued

Table 1 Continued

| Study | Type of ICPI (dosing schedule) | Cancer setting | AST (n/N, %) All grades | AST (n/N, %) Grades 3–4 | ALT (n/N, %) All grades | ALT (n/N, %) Grades 3–4 | Hepatitis (n/N, %) All grades | Hepatitis (n/N, %) Grades 3–4 |
|---|--|---------------------------------|-------------------------|-------------------------|-------------------------|-------------------------|-------------------------------|-------------------------------|
| Weber <i>et al</i> (CheckMate037) ²³ | Nivolumab (3 mg/kg every 2 wks until PD) | Metastatic (previously treated) | | | | | 12/268 (4.5), hepatic TRAEs | 2/268 (0.7), hepatic TRAEs |

ALT, alanine aminotransferase; AST, aspartate aminotransferase; PD, progressive disease; TRAEs, treatment-related adverse events; wk, week.

level of AST/ALT increases as well as the reported ir-hepatitis. In view of these results, hepatotoxicity of any grade (1.2%–32.4% vs 1.8%–6.2%) and of grade ≥ 3 (0.0%–8.0% vs 0.4%–1.8%) occurs at higher rates in patients treated with ipilimumab compared with anti-PD-1 agents.⁸ In confirmation, the large open-label, multicohort, phase Ib KEYNOTE-001 that recruited 655 patients with metastatic melanoma and treated them with pembrolizumab, identified a similar low rate of both grade 1–2 (n=4, 0.6%) and grade 3–4 (n=2, 0.3%) ir-hepatitis with no effect of prior ipilimumab exposure.¹⁹

A meta-analysis synthesized the hepatotoxic risk of ICPIs among 17 phase II and III trials and reported an OR for any grade liver toxicity, 5.01 (95% CI 4.06 to 6.2) for anti-CTLA-4 inhibitors (ipilimumab and tremelimumab), compared with 1.94 (95% CI 1.28 to 2.94) for PD-1 inhibitors (nivolumab and pembrolizumab) and a respective OR for high-grade hepatotoxicity 4.67 (95% CI 3.42 to 6.39) and 1.58 (95% CI 0.66 to 3.78).²⁰ In the same study, a subgroup analysis, according to the type of underlying malignancy, showed statistically significant differences between melanoma and other types of cancer (OR=5.66, 95% CI 4.39 to 7.29 vs OR=2.71, 95% CI 2.04 to 3.29). Ipilimumab-induced hepatitis, identified by liver enzyme disturbances, seems to be dose dependent (reaching a rate of 32.4% at 10 mg/kg vs 18.6% at 3 mg/kg for any grade hepatotoxicity and to 20.7% vs 3.1% for grade ≥ 3) and to affect more frequently patients receiving it in adjuvant versus metastatic setting (any grade: 13.2%–32.4% vs 0.8%–3.9% and grade ≥ 3 : 3.1%–8.0% vs 0%–1.6%, respectively).

As expected, the two highest rates of hepatic enzymes elevations were observed in the studies where ipilimumab was combined with conventional chemotherapy with dacarbazine (grade 3–4 increase of AST: 17.4% and ALT: 20.7%)²¹ and with nivolumab (grade 3–4 increase of AST: 6.1% and ALT: 8.3%).^{9,10} The high rates of ir-hepatic AEs reported for the nivolumab/ipilimumab combination in the phase III CheckMate067 trial^{9,10} are in agreement with the findings of CheckMate069 phase II trial, where grade 3–4 elevation of transaminases occurred in 11% of patients treated with both ICPIs and in none of those treated with ipilimumab alone.²² However, no hepatitis-related death was recorded and severe hepatotoxicity was resolved in almost all cases, after initiation of immunosuppression and discontinuation of immunotherapy. In patients with melanoma treated with nivolumab, prior ipilimumab exposure may influence the expected hepatotoxicity risk. In CheckMate037 (phase III) and in CheckMate172 (phase II) trials, patients with relapsed melanoma on or after ipilimumab were treated with nivolumab, regardless of BRAF status and experienced grade 3–4 hepatic AEs in 0.7% and 2.8%, respectively.^{10,23} In addition to the different histological pattern of induced liver injury, which will be thoroughly discussed in the section of liver biopsy findings, De Martin *et al* also recognized that patients with CTLA-4-associated hepatitis had a longer time to hepatotoxicity onset (14 vs 3 weeks),

were significantly older (69 vs 52 years), compared with those with PD-1/programmed death ligand 1 (PD-L1)-associated hepatitis, but with no gender disparity.²⁴

Which is the diagnostic algorithm of immune-related hepatotoxicity?

Prior to any consideration of immunotherapy, a complete patient medical history is essential, including details on alcohol consumption, concomitant medications and chronic liver conditions, such as hepatitis infections, non-alcoholic fatty liver or autoimmune disease. Based on data from immunotherapy on advanced/metastatic hepatocellular carcinoma, treatment with ICPIs is not contraindicated in patients with pre-existing chronic liver diseases and does not offer to them an increased risk for ir-hepatitis.^{25–27} However, before starting any ICPI, all patients with cancer should be physically examined for any clinical sign of advanced liver disease and baseline assessment with imaging and blood testing is also needed to recognize any hepatic disorder and to evaluate cancer burden and functional liver status. At the onset of immunotherapy, blood testing should be more extensive and should include complete blood count (CBC), liver biochemistries (eg, ALT, AST, ALP, GGT and bilirubin), metabolic and lipid profile, thyroid panel¹³ and serum screening for tuberculosis,²⁸ for viral hepatitis (eg, surface antigen, surface antigen and core antibodies for hepatitis B virus; antibodies against hepatitis C and E viruses, against HIV and cytomegalovirus)²⁹, as well as assessment for autoimmune liver damage, including antibodies of ANA, SMA, AMA, LKM and SLA.³⁰ Before every immunotherapy cycle, main LFTs and CBC should be also repeated. Whenever aminotransferases rise, with or without a concurrent bilirubin elevation, all contributory reasons of liver injury including viral reactivation, autoimmune reaction or alcohol/drug abuse should be reconsidered and the above-mentioned specific diagnostic workup should be repeated. Patients with underlying liver diseases should be monitored more closely and be earlier referred for hepatology consultancy, even as early as the initiation of immunotherapy.

Is liver biopsy mandatory in the era of modern imaging modalities?

According to the recommendations of the European Association for the Study of the Liver, liver biopsy should be considered in cases with severe drug-induced liver injury or refractory hepatotoxicity to standard immunosuppression with corticosteroids, but the decision should be made by a multidisciplinary team.³¹ Given its invasive nature, its significant risks, and its relatively low clinical benefits, this diagnostic procedure should be performed in carefully selected patients.² Indeed, ir-hepatitis does not offer pathognomonic histological findings and liver biopsy may assist only to exclude other causes of liver disease (eg, metastatic involvement or cirrhosis), to identify the type of liver injury, as well as to evaluate the severity of immune-mediated reaction.

In an effort to better characterize the liver injury induced by immunotherapy, De Martin *et al* analyzed 16 liver biopsies of cases with severe ir-hepatitis and noticed that the histological pattern in patients receiving anti-PD-1/PD-L1 agents alone was more heterogeneous compared with patients who received anti-CTLA-4 therapy.²⁴ Histology related to anti-PD-1/PD-L1 inhibitors is characterized by lobular (mostly pan-lobular) inflammation with infiltrating CD4+/CD8+ T cells (in different proportions) and milder portal tract inflammation while it is usually indistinguishable from autoimmune hepatitis.²⁴ On the other hand, histology related to anti-CTLA-4 inhibitors could be separately identified, more often with non-necrotizing granulomas^{17 24} and in some cases with additional sinusoidal histiocytosis and central vein endothelitis.²⁴ Doherty *et al* described three histopathologically distinct cases with steroid-resistant, anti-PD-1-induced hepatotoxicity driven by biliary injury.³² None of these three cases demonstrated the above-mentioned histological characteristics of ir-hepatitis, nor was any significant lymphocytic infiltration evident while variable degrees of duct damage, including vanishing bile duct syndrome, was revealed at the time of liver biopsy. Despite the prolonged and severe course of hepatotoxicity, all three cases showed gradual improvement in LFTs after commencing steroids, and as a matter of fact, one did not require additional immunosuppression to recover ALT/ALP/bilirubin derangements.³²

Encompassing the modern radiological modalities, alternative diagnoses such as progressive hepatic metastasis, cirrhosis, obstruction or cholestasis with elevated bilirubin, GGT and ALP can be sufficiently explored with the help of baseline and subsequent liver imaging, from a simple ultrasound up to MR cholangiopancreatography. Even on CT scans, commonly used to evaluate tumor burden in the liver, severe ir-hepatitis may be depicted with hepatomegaly, peri-portal edema and peri-portal lymphadenopathy while mild ir-hepatitis usually has normal appearance.³³ If abdominal imaging is indicative of underlying cirrhosis, hepatic elastography (in patients without hepatic metastases) could further confirm cirrhotic liver without biopsy.

In general, liver biopsy is unlikely to affect hepatotoxicity management and should be suggested only in cases with significant diagnostic uncertainty. In support of this claim, the large recent retrospective study by Cheung *et al* identified 21 cases with ir-hepatitis among 453 immunotherapy-treated patients with cancer (incidence: 4%), all of whom were diagnosed and managed empirically without liver biopsy.³⁴

When to discontinue and when to resume immunotherapy?

Given that ICPI-treated patients usually have metastatic cancer without many treatment options, the decision to temporarily withhold or permanently discontinue immunotherapy is a reasonable clinical dilemma. For patients with grade 1 hepatotoxicity, ICPIs can be uninterruptedly continued, but ALT/AST, ALP/GGT and bilirubin should

be monitored before every cycle to promptly detect further elevation. For patients with grade 2 hepatotoxicity, ICPIs should be temporarily withheld and LFTs should be tracked closely (eg, every 3–5 days). In this moderate ir-hepatitis, steroids (usually prednisolone at a dose of 0.5–1 mg/kg/day) should be considered, if LFTs remain persistently raised on rechecking. Immunotherapy could be resumed when transaminases are improved to grade 1 or less and after a tapering of steroids. For patients with grade 3 or 4 elevation of liver enzymes, with or without concurrent bilirubin increase, ICPIs should be permanently discontinued.^{13 14} According to the summarized product information, pembrolizumab-induced hepatitis requires permanent immunotherapy discontinuation in only 0.3% of cases while 9% of patients with nivolumab/ipilimumab-induced hepatitis cannot continue their ICPIs combination.

Despite the general assumption that patients who discontinued CTLA-4/PD-1 blockade for severe irAEs will have relatively high rates of recurrent toxicities on immunotherapy resumption, there are many reported cases that resume immunotherapy without hepatotoxicity recurrence.^{5 24 34–36} For instance, De Martin *et al* reintroduced immunotherapy in 3 of 16 patients with ir-hepatitis without recurrence of liver dysfunction²⁴ while Ziemer *et al* reported two cases with metastatic melanoma and ICPI-induced severe liver toxicity, in which immunotherapy was safely and effectively re-introduced with the concomitant administration of budesonide.³⁷ Based on its topical liver-targeted immunosuppressive effect, the authors propose that budesonide could be a potential way to continue ICPIs even in cases where permanent withholding is recommended. Likewise, another recent study reported safe resuming of anti-PD-1 in 21 out of 29 patients (14 out of 19 cases for grade 3–4) with ir-hepatitis during combined anti-CTLA-4 and anti-PD-1 treatment of their metastatic melanoma.⁵ Switching between ICPIs, from a CTLA-4 inhibitor, with high susceptibility to recurrence, toward a PD-1/PD-L1 inhibitor should also be considered. In the study by Cheung *et al*,³⁴ four patients who developed ir-hepatitis after double checkpoint inhibition underwent a rechallenge with immunotherapy when liver function abnormalities had resolved, two patients continued on nivolumab maintenance and another two changed to pembrolizumab with no sign of hepatotoxicity recurrence up to the date of publication.

Are corticosteroids needed in first-line treatment for ir-hepatitis?

As with the majority of other AEs induced by ICPIs, systemic corticosteroids should be considered for first-line treatment of ir-hepatitis.^{13–15} After ruling out other causes, persistent grade 2 liver enzymes elevation for >1 week should be treated with 1 mg/kg/day prednisolone or equivalents, with at least 1 month tapering. In cases with more severe hepatotoxicity (grade ≥ 3), methylprednisolone should be immediately initiated at a dose 1–2 mg/kg/day or an equivalent and on resolution

of hepatotoxicity to less than grade 2, a slow tapering should follow. On receiving systemic corticosteroids, most patients with persistent grade 2 or worse ir-hepatitis will resolve their liver toxicity, with no long-term effects on their prognosis.

Interestingly, two recent reports challenge the necessity of corticosteroids in the management of ir-hepatitis. First, De Martin *et al* noticed the benign course of acute liver injury (grade ≥ 3) induced by immunotherapy in 16 patients with cancer treated with anti-PD-1/PD-L1 and anti-CTLA-4 monoclonal antibodies, in monotherapy or in combination regimens.²⁴ Without receiving any corticosteroid therapy, six of these patients (38%) experienced a spontaneous improvement in LFTs and no severe ir-hepatitis was observed after an immunotherapy rechallenge in two of them. In parallel, Gauci *et al* presented 10 patients with melanoma that experienced ir-hepatitis during their PD-1 and/or CTLA-4 inhibition.³⁵ Hepatotoxicity recovered in all cases but in half of them no steroids were administered and no second-line immunosuppressive treatment was needed for any ir-hepatic AE. It is worth noting that resolution of ir-hepatitis was achieved in 4.7 weeks (median, range 2.0–20.6) for patients who did not receive any additional steroids (n=6, including one patient who was already under steroid treatment for cerebral metastasis) vs 8.6 weeks (median, range 4.3–55.1) in patients who received corticosteroids (n=4).³⁵ No significant difference was observed due to the small number of patients. Both reports by De Martin *et al* and Gauci *et al* concluded that a more patient-oriented management is needed and systemic corticosteroid therapy could be eventually avoided. In accordance, a previous study coming from the Mount Sinai Medical Center reported a spontaneous resolution of ir-hepatitis in six patients (three of them with hepatotoxicity grade 3) after ipilimumab had been temporarily withheld, without administration of any additional immunosuppressive medication, including corticosteroids.³⁸ Moving from the research findings to the market approval of nivolumab/ipilimumab combination, the pharmaceutical summary recognizes that only 46% of patients with melanoma will require high-dose corticosteroid (eg, at least 40 mg prednisone daily or equivalents) to resolve their PD-1/CTLA-4-associated hepatitis. The data above call into question the necessity of steroids in the frontline management of ir-hepatitis and, in any case, suggest that the administration of steroids should be guided by a multidisciplinary decision that takes into account the severity of liver injury. Regarding the exact dose regimen, no trials have directly addressed this issue and the commonly used corticosteroid dose of 1 mg/kg/day prednisolone (or equivalents) is borrowed from the management of other irAEs or from the treatment of autoimmune hepatitis. Recently, Cheung *et al* retrospectively compared two patient cohorts with ir-hepatitis that had been treated either with standard 50–60 mg prednisolone daily or with a higher steroid dose of 1 mg/kg/day.³⁴ The higher prednisolone dose did not shorten the time of ALT recovery despite the fact that the

group receiving this dosing regimen had a lower baseline ALT level than the group receiving the standard steroid dose.³⁴ Looking through the studies on steroid-resistant ir-hepatitis (table 2), high-dose pulse steroids were also tested^{39–41} as a fast-acting immunosuppressive therapy but do not offer any significant benefit in the resolution of hepatotoxicity. It is interesting that in the case described by Nakano *et al*, the other immune-mediated toxicities (eg, skin rash and diarrhea) were rapidly improved by high-dose pulse steroids but not the patient's hepatotoxicity.⁴¹

The response to steroids should be assessed in the first 48–72 hours and if further deterioration of liver function or no improvement is seen, then additional immunosuppressive therapy should be considered. In an effort to reconsider the need and response to steroids, Horvat *et al* estimated that in a cohort of 298 patients with melanoma treated with ipilimumab, 85% experienced an irAE of any type and grade, approximately one-third of them required systemic corticosteroids and almost a third of the latter required further immunosuppression.⁴² It is noteworthy that overall survival and time to ICPI failure were not affected by the occurrence of irAEs or the addition of steroids.⁴²

Which is the optimal management of steroids-refractory ir-hepatitis?

In the rare cases of refractoriness on steroids, many agents have been studied and appear to be effective for treating resistant ir-hepatitis, including MMF (500–1000 mg twice daily),^{24 32 34 39–41 43–48} azathioprine (AZA) (1–2 mg/kg/day),^{49 50} 6-mercaptopurine (6-MP) (1 mg/kg/day),¹⁷ ciclosporin (100 mg twice daily),⁵⁰ antithymocyte globulin (ATG) (doses of 1.5 mg/kg),^{39 43–45} infliximab (5 mg/kg/dose),^{34 46} tacrolimus (targeting blood levels 8–10 ng/mL)^{34 46} and tocilizumab (4 mg/kg/dose)⁵¹ and plasmapheresis.⁴⁷ These therapies, which specifically target T cell subpopulations, are preferred since hepatic infiltration by CD8+ T lymphocytes is the main histopathology finding in ir-hepatitis.

The American Association for the Study of Liver Diseases guidelines recommend AZA as the first-line choice for the treatment of autoimmune hepatitis, and MMF is considered as an alternative therapeutic option for patients who did not previously tolerate or failed to respond to AZA.⁵² Before using AZA or its active metabolite 6-MP, the FDA suggests testing for thiopurine S-methyltransferase (TMPT) genotype or enzyme activity in order to identify patients with decreased TPMT function that are at high risk for developing life-threatening bone marrow suppression. Based on their efficacy against autoimmune hepatitis, both AZA and 6-MP have been used in previous case reports to manage steroid-refractory ir-hepatitis.^{17 49 50} For example, Iwamoto *et al* successfully used AZA in the case of a Japanese man aged 75 years with metastatic melanoma who developed hepatotoxicity after 10 cycles of nivolumab.⁴⁹ No clear evidence exists that AZA is superior to MMF in steroid-refractory ir-hepatitis.⁵³ MMF is a purine antagonist that acts by inhibiting

the proliferation of lymphocytes infiltrating the liver.⁵⁴ Many studies have tested the addition of MMF to steroids after there was no response of hepatotoxicity to the initial immunosuppression and have successfully treated some of these cases.^{32 40 41} Therefore, without randomized evidence, MMF was added to the clinical guidelines as a second-line option for the treatment of steroid-resistant ir-hepatitis,^{15 55} and AZA is considered a legitimate alternative to MMF.

In the literature, only few cases required further immunosuppression due to failure of corticosteroids and MMF, all of which are summarized in table 2. In a large study, this year, including 5762 patients with cancer who received ICPIs (either as single agents or in combination regimens), among 433 cases (8%) experiencing hepatotoxicity of any grade, 67 required steroids, 10 had hepatitis recurrence after steroid tapering and only 2 patients had progressive hepatic injury and required MMF.⁴⁸ Based on that both MMF and tacrolimus (a calcineurin inhibitor) are used as immunosuppressants in liver transplant recipients, the latter also having been tested in steroid-refractory cases with ir-hepatotoxicity.³⁴ Among 21 patients with ir-hepatitis detected by Cheung *et al*, only 3 required a third-line immunosuppressant beyond steroids and MMF and responded after the addition of tacrolimus (one case) and infliximab (two cases).³⁴ In general, infliximab should be avoided for the treatment of ir-hepatitis due to concerns about a rare autoimmune hepatocellular reaction induced by this medication.^{2 14} Last year, Zhang *et al* described a case with prostate adenocarcinoma, treated with ipilimumab and nivolumab combination, which developed hepatotoxicity after exposure to infliximab prescribed to treat ir-colitis.⁵⁶ However, in extraordinary cases where patients co-develop ir-colitis non-responsive to steroids,⁵⁷ or present side effects to other immunosuppressive agents,⁴⁶ infliximab should be considered as an option. More specifically, Corrigan *et al* required to use four of these immunosuppressants (methylprednisolone, MMF, infliximab, tacrolimus) to manage a grade 4 ir-hepatitis after 3 cycles of nivolumab/ipilimumab combination in a woman aged 53 years with metastatic BRAF-mutated melanoma.⁴⁶ In this case, methylprednisolone 200 mg was given once daily for 5 days and then, treatment was escalated with MMF 1 g twice daily, as per recommended guidelines. MMF was discontinued after 7 days due to severe neutropenia while 2 cycles of infliximab were administered 2 weeks apart, with a rapid improvement in bilirubin and ALT.⁴⁶ It is worth mentioning that the patient underwent three percutaneous liver biopsies during her hepatotoxicity management: 1) the initial one (at her diagnosis) showed severe acute lobular hepatitis with absence of fibrosis and predominance of CD3+CD8+ lymphocytes throughout; 2) the second one (after the intolerance to MMF and persistence of high LFTs) showed severe lobular CD3+CD8+ T cells predominant hepatitis with confluent/bridging necrosis and evolving mild peri-portal fibrosis, while 3) the last biopsy (8 weeks after infliximab treatment when ALT and bilirubin were

Table 2 Cases treated with additional immunosuppressive agents for steroid-resistant ir-hepatitis

| Study | Type of cancer | Type and duration of ICPIs | N (age/sex) with ir-hepatitis | Steroids dose and duration (days) | Type and duration of additional immunosuppressive treatments | Time to recovery of liver tests | Management of ICPIs | Outcomes and comments |
|-------------------------------------|---------------------|---|-------------------------------|--|--|--|--|---|
| Chmiel <i>et al</i> ³⁹ | Metastatic melanoma | Ipilimumab (2 doses at 10 mg/kg) | 1 (60/M) | Methylprednisolone intravenous 500 mg/day (9 days) and reduction to oral prednisolone 150 mg/day (steroid-induced psychosis) | MMF 2 g/day for 1 week, ATG (4 doses) in 1 month | 4 weeks from the start of ATG, LFTs normalized without relapse | Withdrawn | Ir-thyroiditis was also diagnosed and treated with L-thyroxin 50 mg/day. Secondary to steroids DM was developed. |
| Ahmed <i>et al</i> ⁴³ | Metastatic melanoma | Ipilimumab (4 doses) | 1 (50/F) | Methylprednisolone on 2 mg/kg (2 days) | Co-administration of MMF (2 g/day and subsequently halved and stopped in 2 weeks) Methylprednisolone (120 mg/day and tapering up to weaning off in 6 weeks) and ATG (2 doses) | 2 weeks | Completed | Liver biopsy was considered unsafe in such an acutely unwell patient. |
| Spánkuch <i>et al</i> ⁴⁴ | Metastatic melanoma | Nivolumab/ipilimumab (3 doses) | 1 (49/F) | Methylprednisolone 100 mg/day (10 days) | MMF 1 g/day for 2 days, Prednisolone 1 g/day for 5 days, ATG with reduced prednisolone to 100 mg/day | After 5 days | Withdrawn and switched to pembrolizumab, when LFTs were normalized | No hepatic recurrence. |
| McGuire <i>et al</i> ⁴⁵ | Metastatic melanoma | Pembrolizumab | 1 (57/F) | Methylprednisolone at 2 mg/kg for 4 days (138 mg/day) followed by oral dexamethasone at equivalent dose | Prednisone at 150 mg and MMF at 1 g/day, ATG (2 doses) in 24 hours | After 162 days | N/A | Multiple abnormalities in CD4+ T cell phenotype were present before melanoma onset, including high multidrug resistance type 1 transporter activity, probably implicated in steroid resistance. |
| Cheung <i>et al</i> ²⁴ | Metastatic melanoma | Nivolumab+ipilimumab | 1 (67/F) | | Prednisolone, MMF, infliximab | | | Co-existed irAEs (colitis, rash, hypoadrenalism). |
| | Metastatic melanoma | Ipilimumab and subsequently pembrolizumab | 1 (76/F) | | Prednisolone, MMF, tacrolimus | | | Co-existed ir-colitis. |

Continued

Table 2 Continued

| Study | Type of cancer | Type and duration of ICPIs | N (age/sex) with grade 3–4 ir-hepatitis | Steroids dose and duration (days) | Type and duration of additional immunosuppressive treatments | Time to recovery of liver tests | Management of ICPIs | Outcomes and comments |
|--|---|--|---|------------------------------------|--|---------------------------------|---------------------|--|
| | Metastatic melanoma | Nivolumab+ipilimumab | 1 (49/F) | | Methylprednisolone, prednisolone, MMF, infliximab | | | All patients were diagnosed and managed empirically without liver biopsy. |
| Huffman <i>et al</i> ⁶⁰ | Metastatic melanoma (previous diagnosis of AIH) | Ipilimumab | 1 (N/A) | Steroids | AZA (1 mg/kg) | No exact date of recovery | Continuation | Hepatitis resolution – death due to PD. |
| | Metastatic melanoma | Ipilimumab | 1 (N/A) | Prednisone (0.5 mg/kg) for 2 weeks | Ciclosporin (100 mg twice daily)+prednisone (1 mg/kg) | After 40 days | Withdrawn | LFTs were normalized and immunosuppressants were discontinued. Died from PD after two other chemotherapeutic lines. |
| Iwamoto <i>et al</i> , ⁴⁹ | Metastatic melanoma | Nivolumab (10 doses) | 1 (75/M) | Methylprednisolone (2 mg/kg/day) | Co-administration of oral AZA (100 mg/day) | After 4 weeks | Withdrawn | Tumor size was increased. The price of AZA at 100 mg/day is approximately seven times lower than that of MMF at 2 g/day. |
| Johncilla <i>et al</i> ¹⁷ | Metastatic melanoma | Ipilimumab | 1 (N/A) | Steroids | 6-MP | N/A | N/A | Recovery from ir-hepatitis. |
| De Martin <i>et al</i> , ²⁴ | Metastatic melanoma | Pembrolizumab (prior exposure)+ipilimumab (1 dose) | 1 (56/F) | Steroids | High-dose steroids (2.5 mg/kg/day)+MMF | No exact date of recovery | | Liver biopsy: pattern of chronic hepatitis with portal fibrosis and severe periportal activity. |

Continued

Table 2 Continued

| Study | Type of cancer | Type and duration of ICPIs | N (age/sex) with grade 3–4 ir-hepatitis | Steroids dose and duration (days) | Type and duration of immunosuppressive treatments | Time to recovery of liver tests | Management of ICPIs | Outcomes and comments |
|------------------------------------|-----------------------------------|---|---|---|---|--|--------------------------------|--|
| Nakano <i>et al</i> ⁴¹ | HNSCC (laryngeal carcinoma) | Nivolumab (14 doses) | 1 (50/M) | Prednisolone (5 mg/day) | Pulse steroid therapy—methylprednisolone (500 mg/day)+MMF (2 g/day) | After 68 days of hospitalization (discharged with oral MMF 1.5 g/day and prednisolone 30 mg/day) | Withdrawn | Liver biopsy: lymphocyte infiltration to Glisson's capsule and piecemeal necrosis, consistent with nivolumab-induced hepatitis HNSCC progression with extensive lymphadenopathy and palliative radiotherapy. Patient died 9.7 months after the hospitalization due to irAEs. |
| Tanaka <i>et al</i> ⁴⁰ | Metastatic melanoma | Nivolumab (11 doses), ipilimumab (1 dose) | 1 (59/M) | Pulse steroid therapy—Methylprednisolone (1000 mg/day)+tapering back to 1 mg/kg/day+empirical ceftazidime | Second pulse steroid therapy—methylprednisolone (1000 mg/day)+MMF (2 g/day) | On day 104, ALT/AST recovered to grade 1 (then dosage of prednisone: 0.5 mg/kg/day and MMF: 1 g/day) | Withdrawn | CT scans at ir-hepatitis diagnosis: no liver but multiple lung metastases. Patients died, few days after the normalization of his LFTs (day 120) due to melanoma progression. |
| Doherty <i>et al</i> ³² | Metastatic melanoma (BRAF-mutant) | Pembrolizumab (1 dose of 2 mg/kg) | 1 (49/F) | Prednisolone (1 mg/kg/day)+UDCA | Prednisolone (1 mg/kg/day)+MMF (2 g/day)+UDCA | Improved No exact date of complete recovery | Changed to BRAF/MEK inhibitors | Liver biopsy: pattern of vanishing bile duct syndrome. MMF stopped due to profound neutropenia. Patient died from progressive intracranial disease (8 months after hepatotoxicity diagnosis). |

Continued

Table 2 Continued

| Study | Type of cancer | Type and duration of ICPIs | N (age/sex) with grade 3–4 ir-hepatitis | Steroids dose and duration (days) | Type and duration of immunosuppressive treatments | Time to recovery of liver tests | Management of ICPIs | Outcomes and comments |
|---|----------------------------|---|---|---|---|---|---------------------|--|
| | Metastatic mesothelioma | Pembrolicumab (1 dose) | 1 (76/M) | Methylprednisolone (2 mg/kg/day) | Prednisolone (1 mg/kg/day)+MMF (1 g/day)+UDCA | Improved No exact date of complete recovery | Withdrawn | Liver biopsy: severe cholestasis and duct injury with evidence of parenchymal loss and regeneration. MMF stopped due to marked lymphopenia. Patient died from progressive disease. |
| Corrigan <i>et al</i> ⁴⁶ | Metastatic melanoma | Nivolumab/ipilimumab (3 doses) | 1 (53/F) | Methylprednisolone (200 mg/day) | MMF (2 g/day) Infliximab (5 mg/kg/dose, 2 doses) Tacrolimus (target trough 3–5 ng/mL) | After 11 weeks | Withdrawn | Three liver biopsies performed, first report of administering four distinct immunosuppressants in order to resolve ir-hepatitis. No PD of melanoma, despite intensified immunosuppression. |
| Stroud <i>et al</i> ⁵¹ | Lung cancer (88.2%) | Nivolumab (4 cycles) | 1 (64 years, median/50% F) | Prednisone (1 mg/kg/day) or equivalents, at time of tocilizumab | Tocilizumab (4 mg/kg/dose, 2 doses) | 4 days, median time of discharge | N/A | Hepatitis resolution. |
| Riveiro-Barciela <i>et al</i> ⁴⁷ | Metastatic vulvar melanoma | Nivolumab (5 cycles) Ipilimumab (2 cycles) | 1 (76/F) | Steroids (2 mg/kg/day) | MMF (1.5 g/day) Plasma exchange (a course of five treatments) | After 2 weeks she was discharged After 6 weeks, LFTs were normalized | Withdrawn | Mild ir-hepatitis already existed after nivolumab and retreatment with ipilimumab was decided. The scheduled liver biopsy was not performed, because of grade 2 hepatic encephalopathy. First report of plasmapheresis as a feasible treatment for ipilimumab-induced hepatitis. |

Continued

Table 2 Continued

| Study | Type of cancer | Type and duration of ICPIs | N (age/sex) with grade 3–4 ir-hepatitis | Steroids dose and duration (days) | Type and duration of additional immunosuppressive treatments | Time to recovery of liver tests | Management of ICPIs | Outcomes and comments |
|----------|---------------------|---|---|--|--|---------------------------------|---------------------|--|
| Our case | Metastatic melanoma | Nivolumab (6 cycles) Ipilimumab (4 cycles) | 1 (73/M) | Intravenous methylprednisolone (1 mg/kg, after 2 days, increased to 2 mg/kg) | MMF (1 g twice daily) Tacrolimus (target trough 8–10 ng/mL) | After 9 weeks | Withdrawn | No biopsy decided. Melanoma relapse with lung metastasis. |

AIH, autoimmune hepatitis; ALT, alanine transaminase; AST, aspartate transaminase; ATG, antithymocyte globulin; AZA, azathioprine; DM, diabetes mellitus; F, female; HNSCC, head and neck squamous cell carcinoma; ICPI, immune checkpoint inhibitor; irAE, immune-related adverse event; LFT, liver function test; M, male; MMF, mycophenolate mofetil; 6-MP, 6-mercaptopurine; N/A, not available; PD, progressive disease; UDCA, ursodeoxycholic acid.

increased yet again) revealed significant improvements in lobular inflammation, but progressive liver fibrosis with bridging and early nodule formation. Even the observed improvement of lobular inflammation, tacrolimus was initiated in order to keep immunosuppression and to gradually taper prednisolone, avoiding an immune flare. Eleven weeks after initial presentation of ir-hepatitis, LFTs recovered completely and despite intensive immunosuppression, 14 months after the last ICPI delivery, she had sustained radiological response, without further immunotherapy.

Ten years ago, when facing the clinical scenario of a patient with melanoma with resistant T cell-mediated fulminant hepatitis after adjuvant ipilimumab treatment for the first time, Chmiel *et al*³⁹ administered ATG (1.5 mg/kg) in order to overcome refractoriness to steroids and MMF. Within 24 hours, liver enzymes were normalized, followed by a suppression of total lymphocyte count and consistent symptoms of cytokine release (eg, fever and rigors). Subsequent ATG infusions over the next couple of weeks maintained lymphocytes at low levels, MMF was ceased over a period of 1 week while prednisolone dose was gradually weaned over the next 6 weeks, with marked improvement in his psychiatric background.³⁹ The addition of ATG as a third-line option had shown similar efficacy in three other patients with melanoma with ir-hepatotoxicity.^{43–45} Spänkuch *et al* reported a metastatic melanoma patient with severe, fulminant nivolumab/ipilimumab-induced hepatitis in whom liver parameters were improved after 5 days of co-administration of ATG and high steroid doses (1 g/day) while previous therapies with prednisolone (2 mg/kg) and MMF had already failed.⁴⁴ Being on steroid tapering, subsequent restaging revealed melanoma progression and immunotherapy with pembrolizumab was decided again with no new hepatic deterioration.⁴⁴ Ahmed *et al* reported the co-administration of three immunosuppressants (MMF, methylprednisolone and ATG) in an Australian woman with metastatic melanoma and ipilimumab-induced hepatitis after initial recurrence on steroids.⁴³ Interestingly, in this case, equine antithymocyte globulin was used instead of rabbit thymoglobulin ATG as the latter was not available on site at that time.⁴³ Finally, McGuire *et al* reported an unusually severe case of hepatitis arising in a patient with cutaneous melanoma after >6 months of uncomplicated adjuvant treatment with an anti-PD-1 agent.⁴⁵ The rapidly developed resistance to the standard dose of methylprednisolone and to steroid pulsing together with MMF forced the addition of ATG to control liver enzymes elevation. Mass cytometry analysis of the patient's blood before melanoma onset revealed multiple abnormalities in CD4+ T cell phenotype, including a subpopulation of CCR4–CCR6– effector/memory CD4+ T cells, expressing intermediate levels of the Th1-related chemokine receptor CXCR3 and abnormally high multidrug resistance type 1 transporter (MDR1) activity.⁴⁵ The expression of MDR1 has been implicated in steroid resistance and may have contributed to the lack of a sustained steroid response.⁵⁸

Circulating CD4+ T cells were profoundly depleted by ATG while CD8+ T cells, B cells, natural killer cells and monocytes were relatively spared.⁴⁵

More revolutionary strategies have also been proposed recently, including plasma exchange for patients with acute liver failure due to ICPI-induced hepatitis.⁴⁷ In this report, the authors describe a case of a woman aged 76 years with metastatic wild-type BRAF vulvar melanoma who initially developed a grade 2 ir-hepatitis due to nivolumab and in the next line of treatment, a grade 4 ipilimumab-induced hepatitis. Steroids were initiated at 2mg/kg/day, and 48 hours later MMF (1.5g/day) was added, but with further deterioration and hepatic encephalopathy. Thus, plasma exchange was tried in a course of five treatments with the patient experiencing a gradual clinical and analytical improvement. In another interesting study, tocilizumab, an anti-interleukin-6 antibody was tested for the management of steroid-refractory irAEs, including hepatitis, showing an overall clinical improvement in nearly 80% of the patients, with half of them requiring just a single dose.⁵¹ In a theoretical context, acetylcysteine may have a role in the recovery of

hepatic damage while ursodeoxycholic acid may have a role in immune-mediated cholestasis.⁵⁹

In order to sort the above-mentioned immunosuppressive options, a proposed therapeutic algorithm for severe (\geq grade 3) ir-hepatitis, resistant to steroids, is presented in [figure 2](#), including the differences among oncology experts' societies. Large immunotherapy trials are not designed to respond with details about how the ICPIs-induced toxicities are treated, keeping precise records of administered immunosuppressants (eg, dose, sequence, etc). In addition, the treatment of developed ir-AEs, including ir-hepatitis, is not usually described when the original trial is published. Thus, the main information for the management of immune-mediated toxicities comes from retrospective studies and case reports. Regarding ir-hepatitis, current data presented in [table 2](#) are limited to establishing the use of any immunosuppressive agent in the treatment of steroid-resistant and MMF-resistant ir-hepatitis and in each case, the decision should be completely personalized. In this respect, we could only highlight the requirements that should be satisfied by the selected agent: i) it should be administered with feasibility

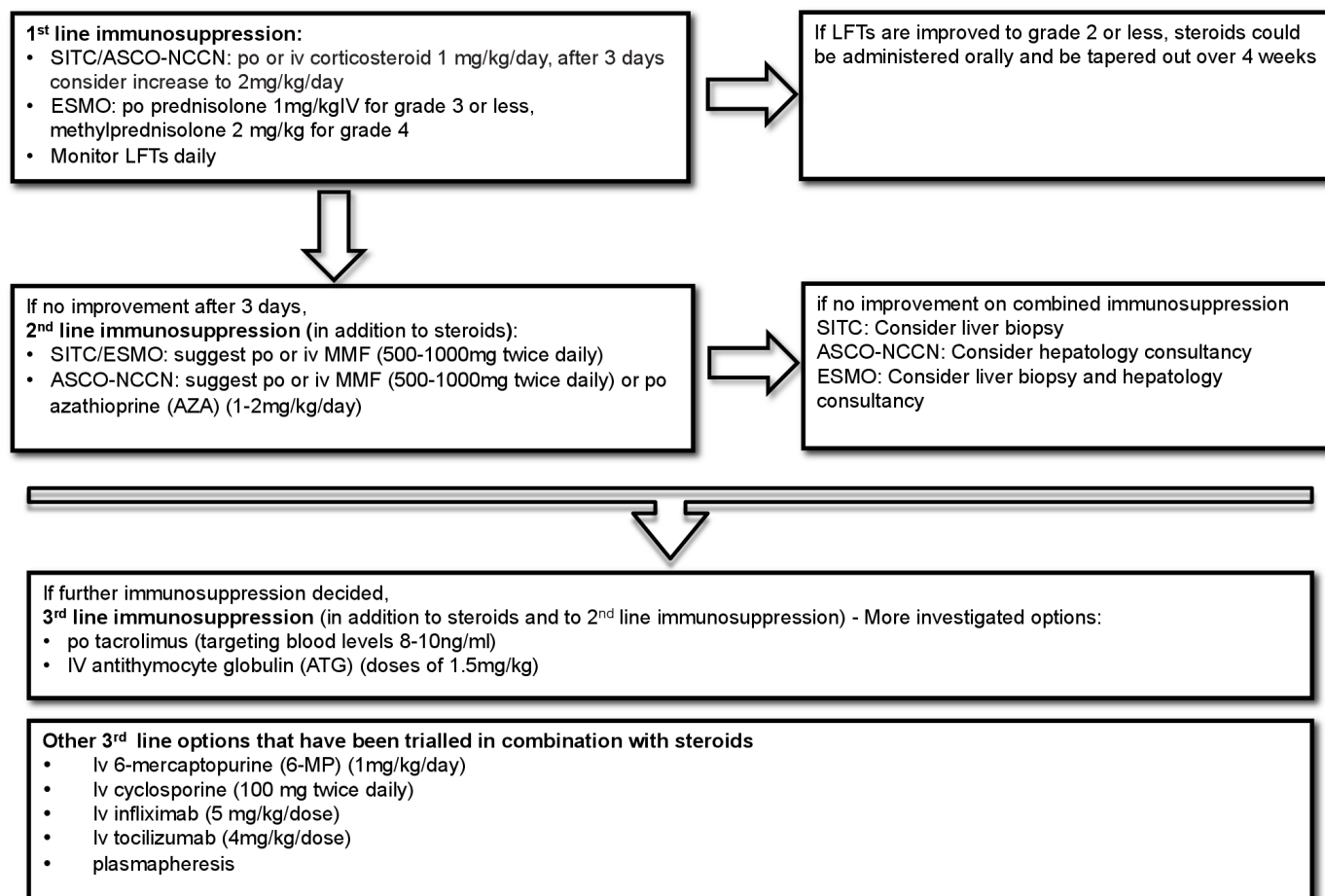


Figure 2 A suggested algorithm for the addition of further immunosuppressive options after steroid failure in ir-hepatitis and the differentiations between oncology societies. ASCO, American Society of Oncology; ESMO, European Society of Oncology; LFTs, liver function tests; MMF, mycophenolate mofetil; NCCN, National Comprehensive Cancer Network; SITC, Society of Immunotherapy of Cancer.

and safety for prolonged duration (>6 weeks), ii) it should keep stable immunosuppression without additional corticosteroids and iii) it should allow for the weaning of steroids and of MMF, as soon as possible, without an immune flare. Based on the experience from the era of organ transplantation and autoimmune hepatitis, tacrolimus seems to surpass the other immunosuppressive agents in the management of immunotherapy-associated hepatotoxicity. It is an oral macrolide antibiotic with a powerful immunosuppressive activity (100–1000 more potent calcineurin inhibitor than ciclosporin),⁶⁰ measurable serum levels and well-tolerated toxicities. At the molecular level, tacrolimus binds to intracellular immunophilins and this complex inhibits the enzyme of calcineurin, which is needed for the cytokine production.⁶⁰ This loss-of-function of the enzyme results in a net inhibitory effect on both B and T cells, making tacrolimus a potential therapeutic option for any immune-mediated reaction. Finally, monitoring serum levels of tacrolimus will allow its prolonged administration and reduce the risk of major dose-dependent AEs (eg, nephrotoxicity and neurotoxicity).

CONCLUSIONS

ICPI-induced hepatotoxicity remains a challenging AE with a little-understood pathogenesis, difficult diagnosis, serious clinical consequences and without an established optimal management yet, especially for refractory or persistent conditions. The current report describes just the second published melanoma case of a grade 4 ir-hepatitis successfully managed after escalation of immunosuppression with the addition of tacrolimus to MMF and steroids. Since such cases are not frequently met in everyday oncological practice, clinicians should be aware of their occurrence and should follow a multidisciplinary approach involving oncology and hepatology consultancy. In general, the involvement of different specialties familiar with melanoma behavior and treatment-related AEs will help to timely capture distinct immune-mediated diagnoses while the experience in both immunotherapeutic and immunosuppressive agents will help to keep the host balance during immunotoxicity management. The early recognition and appropriate treatment of ICPI-induced hepatotoxicity is the main reason of exceptionally low mortality among immunotherapy trials. Apart from melanoma studies where no grade 5 ir-hepatitis reported, the IMpassion130 trial in patients with metastatic triple negative breast cancer treated with nab-paclitaxel and atezolizumab reported one fatal event due to ir-hepatitis⁶¹ and the ATTRACTION-2 trial investigating nivolumab, in heavily pretreated (≥ 2 prior lines, refractory or intolerant to standard therapy) patients with recurrent gastric or gastroesophageal junction adenocarcinoma, reported one death due to treatment-related acute hepatitis.⁶²

Summarizing current evidence, the need of imaging and blood monitoring during immunotherapy is obvious, while the role of liver biopsy is still controversial.

Immunotherapy discontinuation and timely initiation of steroids will usually resolve hepatotoxicity but in resistant cases, intensification of immunosuppression will be required.

The resolution of ir-hepatitis may take up to 3 months while the prolonged use of steroids or other immunosuppressants may decrease the efficacy of resumed immunotherapy and may increase the risk of melanoma relapse or of opportunistic infections, as happened in our case. On a theoretical basis, immunosuppression may lower the antitumor effects of ICPIs, but Horvat *et al* showed that the addition of steroids was not associated with overall survival or shorter time to treatment failure. Immunotherapy rechallenge could be considered when ir-hepatitis improves to less than grade 2, but the correct timing to restart or switch to another type of ICPI is not clearly defined. Regarding the potential risk for opportunistic infections, Del Castillo *et al* noticed a 7.7-fold increased risk of serious infections in patients who received either corticosteroids or infliximab compared with those who did not (13.5% vs 2%).⁶³ Clinicians providing immunosuppressive drugs for the treatment of irAEs should: i) maintain high vigilance for occurrence of symptoms suggestive of infection, ii) consider that steroids may spontaneously improve an underlying fungal infection and iii) prophylactically cover for *Pneumocystis carinii* all patients who are expected to receive prednisone (or equivalent) for >4 weeks. The role of additional antiviral, antibacterial or antifungal prophylaxis in these patients requires further study.

Up to now, the selection among the above-mentioned immunosuppressive agents for the management of ir-hepatitis, their combination and their sequence are not guided by high-level evidence. More data are needed to define the optimal immunosuppression in the treatment of irAEs while taking into account the associated secondary infectious and oncological risks. In each case, the overall approach should be based on an individualized decision, following a thorough multidisciplinary discussion.

Contributors DCZ and AG treated the case and reviewed the literature; DCZ, PD, EC, AA, PAA and HG wrote the manuscript. All authors edited, read and approved the final manuscript.

Funding The authors have not declared a specific grant for this research from any funding agency in the public, commercial or not-for-profit sectors.

Competing interests HG has received grants and personal fees by Roche, BMS, MSD, Novartis and personal fees by Amgen and Pierre Fabre, outside the submitted work. PD has received personal fees from Roche and Novartis, outside the submitted work. PAA has a consultant/advisory role for BMS, Roche-Genentech, MSD, Array, Novartis, Merck Serono, Pierre Fabre, Incyte, NewLink Genetics, Genmab, Medimmune, AstraZeneca, Syndax, SunPharma, Sanofi, Idera, Ultimovacs, Sandoz, Immunocore, 4SC, Alkermes, Italfarmaco, Nektar, Boehringer-Ingelheim and he has also received research funds from BMS, Roche, Array, and travel support from MSD, outside the submitted work.

Patient consent for publication Not required.

Provenance and peer review Not commissioned; externally peer reviewed.

Open access This is an open access article distributed in accordance with the Creative Commons Attribution Non Commercial (CC BY-NC 4.0) license, which permits others to distribute, remix, adapt, build upon this work non-commercially,

and license their derivative works on different terms, provided the original work is properly cited, appropriate credit is given, any changes made indicated, and the use is non-commercial. See <http://creativecommons.org/licenses/by-nc/4.0/>.

ORCID iD

Paolo Antonio Ascierto <http://orcid.org/0000-0002-8322-475X>

REFERENCES

- Spain L, Diem S, Larkin J. Management of toxicities of immune checkpoint inhibitors. *Cancer Treat Rev* 2016;44:51–60.
- Reynolds K, Thomas M, Dougan M. Diagnosis and management of hepatitis in patients on checkpoint blockade. *Oncologist* 2018;23:991–7.
- Nadeau BA, Fecher LA, Owens SR, et al. Liver toxicity with cancer checkpoint inhibitor therapy. *Semin Liver Dis* 2018;38:366–78.
- Lleo A, Rimassa L, Colombo M. Hepatotoxicity of immune check point inhibitors: approach and management. *Dig Liver Dis* 2019;51:1074–8.
- Pollack MH, Betof A, Dearden H, et al. Safety of resuming anti-PD-1 in patients with immune-related adverse events (irAEs) during combined anti-CTLA-4 and anti-PD1 in metastatic melanoma. *Ann Oncol* 2018;29:250–5.
- Peeraphatdit TB, Wang J, Odenwald MA, et al. Hepatotoxicity from immune checkpoint inhibitors: a systematic review and management recommendation. *Hepatology* 2020;72:315–29.
- Robert C, Schachter J, Long GV, et al. Pembrolizumab versus ipilimumab in advanced melanoma. *N Engl J Med* 2015;372:2521–32.
- Eggermont AMM, Blank CU, Mandala M, et al. Adjuvant pembrolizumab versus placebo in resected stage III melanoma. *N Engl J Med* 2018;378:1789–801.
- Larkin J, Chiarion-Sileni V, Gonzalez R, et al. Combined nivolumab and ipilimumab or monotherapy in untreated melanoma. *N Engl J Med* 2015;373:23–34.
- Larkin J, Chiarion-Sileni V, Gonzalez R, et al. Five-Year survival with combined nivolumab and ipilimumab in advanced melanoma. *N Engl J Med* 2019;381:1535–46.
- Affolter T, Llewellyn HP, Bartlett DW, et al. Inhibition of immune checkpoints PD-1, CTLA-4, and IDO1 coordinately induces immune-mediated liver injury in mice. *PLoS One* 2019;14:e0217276.
- Dougan M. Gastrointestinal and hepatic complications of immunotherapy: current management and future perspectives. *Curr Gastroenterol Rep* 2020;22:15.
- Puzanov I, Diab A, Abdallah K, et al. Managing toxicities associated with immune checkpoint inhibitors: consensus recommendations from the Society for immunotherapy of cancer (SITC) toxicity management Working group. *J Immunother Cancer* 2017;5:95.
- Brahmer JR, Lacchetti C, Schneider BJ, et al. Management of immune-related adverse events in patients treated with immune checkpoint inhibitor therapy: American Society of clinical oncology clinical practice guideline. *J Clin Oncol* 2018;36:1714–68.
- Haanen JBAG, Carbone F, Robert C, et al. Management of toxicities from immunotherapy: ESMO clinical practice guidelines for diagnosis, treatment and follow-up. *Ann Oncol* 2018;29:iv264–6.
- Thompson JA, Schneider BJ, Brahmer J, et al. NCCN guidelines insights: management of Immunotherapy-Related toxicities, version 1.2020. *J Natl Compr Canc Netw* 2020;18:230–41.
- Jhonnilla M, Misdraji J, Pratt DS, et al. Ipilimumab-associated hepatitis: clinicopathologic characterization in a series of 11 cases. *Am J Surg Pathol* 2015;39:1075–84.
- Bhave P, Buckle A, Sandhu S, et al. Mortality due to immunotherapy related hepatitis. *J Hepatol* 2018;69:976–8.
- Ribas A, Hamid O, Daud A, et al. Association of pembrolizumab with tumor response and survival among patients with advanced melanoma. *JAMA* 2016;315:1600–9.
- Wang W, Lie P, Guo M, et al. Risk of hepatotoxicity in cancer patients treated with immune checkpoint inhibitors: a systematic review and meta-analysis of published data. *Int J Cancer* 2017;141:1018–28.
- Robert C, Thomas L, Bondarenko I, et al. Ipilimumab plus dacarbazine for previously untreated metastatic melanoma. *N Engl J Med* 2011;364:2517–26.
- Hodi FS, Chesney J, Pavlick AC, et al. Combined nivolumab and ipilimumab versus ipilimumab alone in patients with advanced melanoma: 2-year overall survival outcomes in a multicentre, randomised, controlled, phase 2 trial. *Lancet Oncol* 2016;17:1558–68.
- Weber JS, D'Angelo SP, Minor D, et al. Nivolumab versus chemotherapy in patients with advanced melanoma who progressed after anti-CTLA-4 treatment (CheckMate 037): a randomised, controlled, open-label, phase 3 trial. *Lancet Oncol* 2015;16:375–84.
- De Martin E, Michot J-M, Papouin B, et al. Characterization of liver injury induced by cancer immunotherapy using immune checkpoint inhibitors. *J Hepatol* 2018;68:1181–90.
- Sangro B, Gomez-Martin C, de la Mata M, et al. A clinical trial of CTLA-4 blockade with tremelimumab in patients with hepatocellular carcinoma and chronic hepatitis C. *J Hepatol* 2013;59:81–8.
- El-Khoueiry AB, Sangro B, Yau T, et al. Nivolumab in patients with advanced hepatocellular carcinoma (CheckMate 040): an open-label, non-comparative, phase 1/2 dose escalation and expansion trial. *Lancet* 2017;389:2492–502.
- Zhu AX, Finn RS, Edeline J, et al. Pembrolizumab in patients with advanced hepatocellular carcinoma previously treated with sorafenib (KEYNOTE-224): a non-randomised, open-label phase 2 trial. *Lancet Oncol* 2018;19:940–52.
- Anastasopoulou A, Ziogas DC, Samarkos M, et al. Reactivation of tuberculosis in cancer patients following administration of immune checkpoint inhibitors: current evidence and clinical practice recommendations. *J Immunother Cancer* 2019;7:239.
- Ziogas DC, Kostantinou F, Cholongitas E, et al. Reconsidering the management of patients with cancer with viral hepatitis in the era of immunotherapy. *J Immunother Cancer* 2020;8:e000943.
- Herbst RS, Baas P, Kim D-W, et al. Pembrolizumab versus docetaxel for previously treated, PD-L1-positive, advanced non-small-cell lung cancer (KEYNOTE-010): a randomised controlled trial. *Lancet* 2016;387:1540–50.
- European Association for the Study of the Liver. Electronic address: easloffice@easloffice.eu, Clinical Practice Guideline Panel: Chair, Panel members, et al. EASL clinical practice guidelines: drug-induced liver injury. *J Hepatol* 2019;70:1222–61.
- Doherty GJ, Duckworth AM, Davies SE, et al. Severe steroid-resistant anti-PD1 T-cell checkpoint inhibitor-induced hepatotoxicity driven by biliary injury. *ESMO Open* 2017;2:e000268.
- Alessandrino F, Tirumani SH, Krajewski KM, et al. Imaging of hepatic toxicity of systemic therapy in a tertiary cancer centre: chemotherapy, haematopoietic stem cell transplantation, molecular targeted therapies, and immune checkpoint inhibitors. *Clin Radiol* 2017;72:521–33.
- Cheung V, Gupta T, Payne M, et al. Immunotherapy-related hepatitis: real-world experience from a tertiary centre. *Frontline Gastroenterol* 2019;10:364–71.
- Gauci M-L, Baroudjian B, Zeboulon C, et al. Immune-Related hepatitis with immunotherapy: are corticosteroids always needed? *J Hepatol* 2018;69:548–50.
- Simonaggio A, Michot JM, Voisin AL, et al. Evaluation of Readministration of immune checkpoint inhibitors after immune-related adverse events in patients with cancer. *JAMA Oncol* 2019. doi:10.1001/jamaoncol.2019.1022. [Epub ahead of print: 06 Jun 2019].
- Ziema M, Koukouliti E, Beyer S, et al. Managing immune checkpoint-inhibitor-induced severe autoimmune-like hepatitis by liver-directed topical steroids. *J Hepatol* 2017;66:657–9.
- Bernardo SG, Moskalenko M, Pan M, et al. Elevated rates of transaminitis during ipilimumab therapy for metastatic melanoma. *Melanoma Res* 2013;23:47–54.
- Chmiel KD, Suan D, Liddle C, et al. Resolution of severe ipilimumab-induced hepatitis after antithymocyte globulin therapy. *J Clin Oncol* 2011;29:e237–40.
- Tanaka R, Fujisawa Y, Sae I, et al. Severe hepatitis arising from ipilimumab administration, following melanoma treatment with nivolumab. *Jpn J Clin Oncol* 2017;47:175–8.
- Nakano K, Nishizawa M, Fukuda N, et al. Mycophenolate mofetil as a successful treatment of corticosteroid-resistant immune checkpoint inhibitor-induced hepatitis. *Oxf Med Case Reports* 2020;2020:omaa027.
- Horvat TZ, Adel NG, Dang T-O, et al. Immune-Related adverse events, need for systemic immunosuppression, and effects on survival and time to treatment failure in patients with melanoma treated with ipilimumab at Memorial Sloan Kettering cancer center. *J Clin Oncol* 2015;33:3193–8.
- Ahmed T, Pandey R, Shah B, et al. Resolution of ipilimumab induced severe hepatotoxicity with triple immunosuppressants therapy. *BMJ Case Rep* 2015;2015:bcr2014208102.
- Spänkuch I, Gassenmaier M, Tampouri I, et al. Severe hepatitis under combined immunotherapy: Resolution under corticosteroids plus anti-thymocyte immunoglobulins. *Eur J Cancer* 2017;81:203–5.
- McGuire HM, Shklovskaya E, Edwards J, et al. Anti-PD-1-induced high-grade hepatitis associated with corticosteroid-resistant T cells: a case report. *Cancer Immunol Immunother* 2018;67:563–73.
- Corrigan M, Haydon G, Thompson F, et al. Infiximab for the treatment of refractory immune-related hepatitis secondary to checkpoint inhibitors: a case report. *JHEP Rep* 2019;1:66–9.

- 47 Riveiro-Barciela M, Muñoz-Couselo E, Fernandez-Sojo J, *et al.* Acute liver failure due to immune-mediated hepatitis successfully managed with plasma exchange: new settings call for new treatment strategies? *J Hepatol* 2019;70:564–6.
- 48 Miller ED, Abu-Sbeih H, Styskel B, *et al.* Clinical characteristics and adverse impact of hepatotoxicity due to immune checkpoint inhibitors. *Am J Gastroenterol* 2020;115:251–61.
- 49 Iwamoto K, Ishitsuka Y, Tanaka R, *et al.* Azathioprine combination therapy for steroid-refractory hepatic immune system-related adverse events. *Eur J Dermatol* 2017;27:301–3.
- 50 Huffman BM, Kottschade LA, Kamath PS, *et al.* Hepatotoxicity after immune checkpoint inhibitor therapy in melanoma: natural progression and management. *Am J Clin Oncol* 2018;41:760–5.
- 51 Stroud CR, Hegde A, Cherry C, *et al.* Tocilizumab for the management of immune mediated adverse events secondary to PD-1 blockade. *J Oncol Pharm Pract* 2019;25:551–7.
- 52 Mack CL, Adams D, Assis DN, *et al.* Diagnosis and management of autoimmune hepatitis in adults and children: 2019 practice guidance and guidelines from the American association for the study of liver diseases. *Hepatology* 2020;72:671–722.
- 53 Cheng R, Cooper A, Kench J, *et al.* Ipilimumab-induced toxicities and the gastroenterologist. *J Gastroenterol Hepatol* 2015;30:657–66.
- 54 Heneghan MA, McFarlane IG. Current and novel immunosuppressive therapy for autoimmune hepatitis. *Hepatology* 2002;35:7–13.
- 55 Weber JS, Kähler KC, Hauschild A. Management of immune-related adverse events and kinetics of response with ipilimumab. *J Clin Oncol* 2012;30:2691–7.
- 56 Zhang HC, Luo W, Wang Y. Acute liver injury in the context of immune checkpoint inhibitor-related colitis treated with infliximab. *J Immunother Cancer* 2019;7:47.
- 57 Hellmann MD, Rizvi NA, Goldman JW, *et al.* Nivolumab plus ipilimumab as first-line treatment for advanced non-small-cell lung cancer (CheckMate 012): results of an open-label, phase 1, multicohort study. *Lancet Oncol* 2017;18:31–41.
- 58 Ramesh R, Kozhaya L, McKeivitt K, *et al.* Pro-inflammatory human Th17 cells selectively express P-glycoprotein and are refractory to glucocorticoids. *J Exp Med* 2014;211:89–104.
- 59 Matsubara T, Nishida T, Higaki Y, *et al.* Nivolumab induces sustained liver injury in a patient with malignant melanoma. *Intern Med* 2018;57:1789–92.
- 60 Kobayashi M, Tamura K, Katayama N, *et al.* FK 506 assay past and present--characteristics of FK 506 ELISA. *Transplant Proc* 1991;23:2725–9.
- 61 Schmid P, Rugo HS, Adams S, *et al.* Atezolizumab plus nab-paclitaxel as first-line treatment for unresectable, locally advanced or metastatic triple-negative breast cancer (IMpassion130): updated efficacy results from a randomised, double-blind, placebo-controlled, phase 3 trial. *Lancet Oncol* 2020;21:44–59.
- 62 Kang Y-K, Boku N, Satoh T, *et al.* Nivolumab in patients with advanced gastric or gastro-oesophageal junction cancer refractory to, or intolerant of, at least two previous chemotherapy regimens (ONO-4538-12, ATTRACTION-2): a randomised, double-blind, placebo-controlled, phase 3 trial. *Lancet* 2017;390:2461–71.
- 63 Del Castillo M, Romero FA, Argüello E, *et al.* The spectrum of serious infections among patients receiving immune checkpoint blockade for the treatment of melanoma. *Clin Infect Dis* 2016;63:1490–3.
- 64 Eggermont AMM, Chiarion-Sileni V, Grob J-J, *et al.* Adjuvant ipilimumab versus placebo after complete resection of high-risk stage III melanoma (EORTC 18071): a randomised, double-blind, phase 3 trial. *Lancet Oncol* 2015;16:522–30.
- 65 Weber J, Mandala M, Del Vecchio M, *et al.* Adjuvant nivolumab versus ipilimumab in resected stage III or IV melanoma. *N Engl J Med* 2017;377:1824–35.
- 66 Tarhini AA, Lee SJ, Hodi FS, *et al.* Phase III study of adjuvant ipilimumab (3 or 10 mg/kg) versus high-dose interferon alfa-2b for resected high-risk melanoma: North American intergroup E1609. *J Clin Oncol* 2020;38:567–75.
- 67 Hodi FS, O'Day SJ, McDermott DF, *et al.* Improved survival with ipilimumab in patients with metastatic melanoma. *N Engl J Med* 2010;363:711–23.