

# Right-sided reverse T composite arterial grafting to complete revascularization of the right coronary artery

*Enxerto arterial composto reverso T do lado direito para completar a revascularização da artéria coronária direita*

Mathias H. Aazami<sup>1</sup>, MD; Mohammad Abbasi-Teshnizi<sup>2</sup>, MD; Shahram Amini<sup>3</sup>, MD; Nasim Sadat Lotfinejad<sup>4</sup>, MD

DOI 10.5935/1678-9741.20140069

RBCCV 44205-1603

## Abstract

Complete arterial revascularization for the right coronary artery is underused mainly due to technical issues. Herein we report on a new approach for complete arterial revascularization of arterial revascularization for the right coronary artery branches. Complete arterial revascularization for the right coronary artery revascularization was performed in 8 patients using a reverse T composite arterial graft. None of the patients suffered perioperative myocardial infarction. All patients underwent noninvasive coronary imaging, displaying an early patency rate of 100%. Complete arterial revascularization for the right coronary artery revascularization using a reverse T graft offers a new paradigm with enhanced technical flexibility in performing all arterial myocardial complete revascularizations in selected patients.

**Descriptors:** Coronary Artery Bypass. Coronary Circulation. Internal Mammary-Coronary Artery Anastomosis. Tomography Scanners, X-Ray Computed. Radial Artery.

## Resumo

Revascularização arterial completa para a artéria coronária direita é subutilizada, principalmente devido a problemas técnicos. Nós relatamos uma nova abordagem para a revascularização arterial completa para os ramos da artéria coronária direita. Revascularização arterial completa da artéria coronária direita foi realizada em 8 pacientes usando um enxerto T arterial composto inverso. Nenhum dos pacientes sofreu infarto do miocárdio perioperatório. Todos os pacientes foram submetidos a exame de imagem não invasivo coronária não invasiva, exibindo taxa de patência precoce de 100%. Revascularização arterial completa da artéria coronária direita com enxerto inversa T oferece um novo paradigma com maior flexibilidade técnica na execução todas as revascularizações arteriais completas do miocárdio em pacientes selecionados.

**Descritores:** Ponte de Artéria Coronária. Circulação Coronária. Anastomose de Artéria Torácica Interna-Coronária. Tomógrafos Computadorizados. Artéria Radial.

<sup>1</sup>Cardiac Surgery Department, Cardiac Anesthesia Research Center and Cardiothoracic Surgery and Transplantation Research Center of Imam Reza Hospital, The Mashhad University of Medical Sciences, Mashhad, Iran.

<sup>2</sup>Cardiac Surgery Department of Imam Reza Hospital, The Mashhad University of Medical Sciences, Mashhad, Iran.

<sup>3</sup>Cardiac Surgery Department and Cardiac Anesthesia Research Center of Imam Reza Hospital, The Mashhad University of Medical Sciences, Mashhad, Iran.

<sup>4</sup>Mashhad University of Medical Sciences, Mashhad, Iran.

This study was carried out at Cardiac Surgery Department of Imam Reza Hospital, The Mashhad University of Medical Sciences, Mashhad, Iran.

No financial support.

Correspondence address:

Nasim Sadat Lotfinejad

Faculty of Medicine, Azadi Square, Pardis Campus, Mashhad-Iran

E-mail: nasim.lotfinezhad@gmail.com

Article received on February 28<sup>th</sup>, 2014

Article accepted on May 3<sup>rd</sup>, 2014

Abbreviations, acronyms & symbols	
RCA	Right coronary artery
MDR	Multisite diseased right coronary artery
CCR	Complete RCA revascularisation
CBF	Coronary blood flow
CRTG	Coronaro-coronary reverse T grafting
ICB	Intracoronary bridge
IRTG	In situ reverse T grafting
ITA	Internal thoracic artery
IVS	Interventricular septum
LAD	Left anterior descending artery
LITA	Left internal thoracic artery
MI	Myocardial infarction
RA	Radial artery
RITA	Right internal thoracic artery

## INTRODUCTION

The right coronary artery (RCA) is an important provider of collateral flow to the left coronary system and interventricular septum (IVS)<sup>[1,2]</sup>. In the setting of a multisite diseased right coronary artery (MDR), surgical revascularization is generally confined to its inferoposterior branches. We report on a new approach, attempted at complete arterial revascularization of RCA (CRR) in selected patients. These techniques enable us to achieve double inflow all arterial revascularizations using two arterial composite grafts at their utmost technical aspect.

## METHODS

This study was approved by our institutional ethics committee, and written informed consent was obtained from each patient. This approach is based on constructing a reverse T composite arterial graft placed between the RCA targets along with complete left-sided arterial revascularization. Arterial revascularization is performed using left internal thoracic artery (LITA); right internal thoracic artery (RITA), or radial artery (RA). Bicaval venous cannulation in view of optimal integrated myocardial protection, cold blood intermittent anteretrograde cardioplegia, mild systemic hypothermia, and peri- and postoperative tight glycemia control were used systematically.

An intracoronary bridge (ICB) is constructed between the RCA targets using a segment of free arterial graft (Figure 1A-D). Preprocedural measuring of the grafts' length and ICB on a fully beating heart avoids pitfalls in its final layout; thereby preventing kinking/angulation. An anterolateral or acute marginal branch can be bypassed directly (diameter > 1 mm) or indirectly through RCA segments giving them take-off (Figure 1C). Then ICB is connected to an arterial inflow according to two distinct modes, the choice of which depends on final layouts for left- and right-sided revascularizations in line with availability of the arterial grafts:

- 1) In-situ reverse T grafting (IRTG) using RITA (Figure 2A).
- 2) Coronaro-coronary reverse T grafting (CRTG) (Figures 2B and 2C).

Eight patients with a mean age of 57.13 ± 9.7 years old (female 25%; mean logistic Euroscore: 5.2 ± 5.6%; elective: 75%; mean preoperative left ventricle ejection fraction (LVEF): 45.71 ± 9.32%; diabetes mellitus: 75%) underwent CRR as a part of complete arterial revascularization. 75% of patients had a three vessel or left main disease and had a history of recent myocardial infarction (MI). Two patients underwent previous PTCA with intracoronary stenting (mean stent per patient: 4). An occluded LAD and RCA were noticed in 50% of patients, and RCA was dominant in 6 patients.

## RESULTS

The mean number of total arterial anastomoses (distal/composite/ proximal coronary-coronary) was 7 ± 1.5 per patient. The mean numbers of distal and CRR anastomoses were 4.88 ± 1.26 and 2.25 ± 0.463 per patient respectively. Double internal thoracic arteries (ITAs) and RA were used in 75 and 62.5% of the patients. Six patients had right- and left-sided double composite arterial grafting. CRR was performed as IRTG in 5 and as CRTG in the remaining patients. An ICB was constructed using a segment of RA in 5 patients or ITA in the rest. An anterolateral or acute marginal branch was revascularized in 6 patients directly or via their supporting RCA segment (4 patients).

Fifty percent of patients required extensive LAD reconstruction (endarterectomy, arterial roofing, and On-Lay anastomosis). Two patients needed concomitant releasing of a muscle bridge on LAD (>3 cm). The mean pump and ischemic times were 257 ± 47.7 and 180 ± 47.3 minutes respectively. None of the patients suffered perioperative MI, nor required mechanical/inotropic cardiocirculatory support. 87.5% of patients were extubated within the first 24 hours postoperatively and the mean time of ICU stay was 3.1 ± 1.5 days. None of the patients suffered major cardiocerebral adverse events except one with resolving postoperative neurocognitive dysfunction (preoperative strokes with carotid stenting). The mean LVEF at discharge was 45.71 ± 3.45%. All patients underwent noninvasive coronary imaging within the first four months postoperatively displaying an early patency rate of 100% for the grafts and distal anastomoses.

## DISCUSSION

A double inflow feature of coronary arterial system confers RCA the role of a main provider for collateral flow with regards to the left coronary system and IVS; thereby, federating a salient backup in regulations of coronary blood flow (CBF)<sup>[1,2]</sup>.

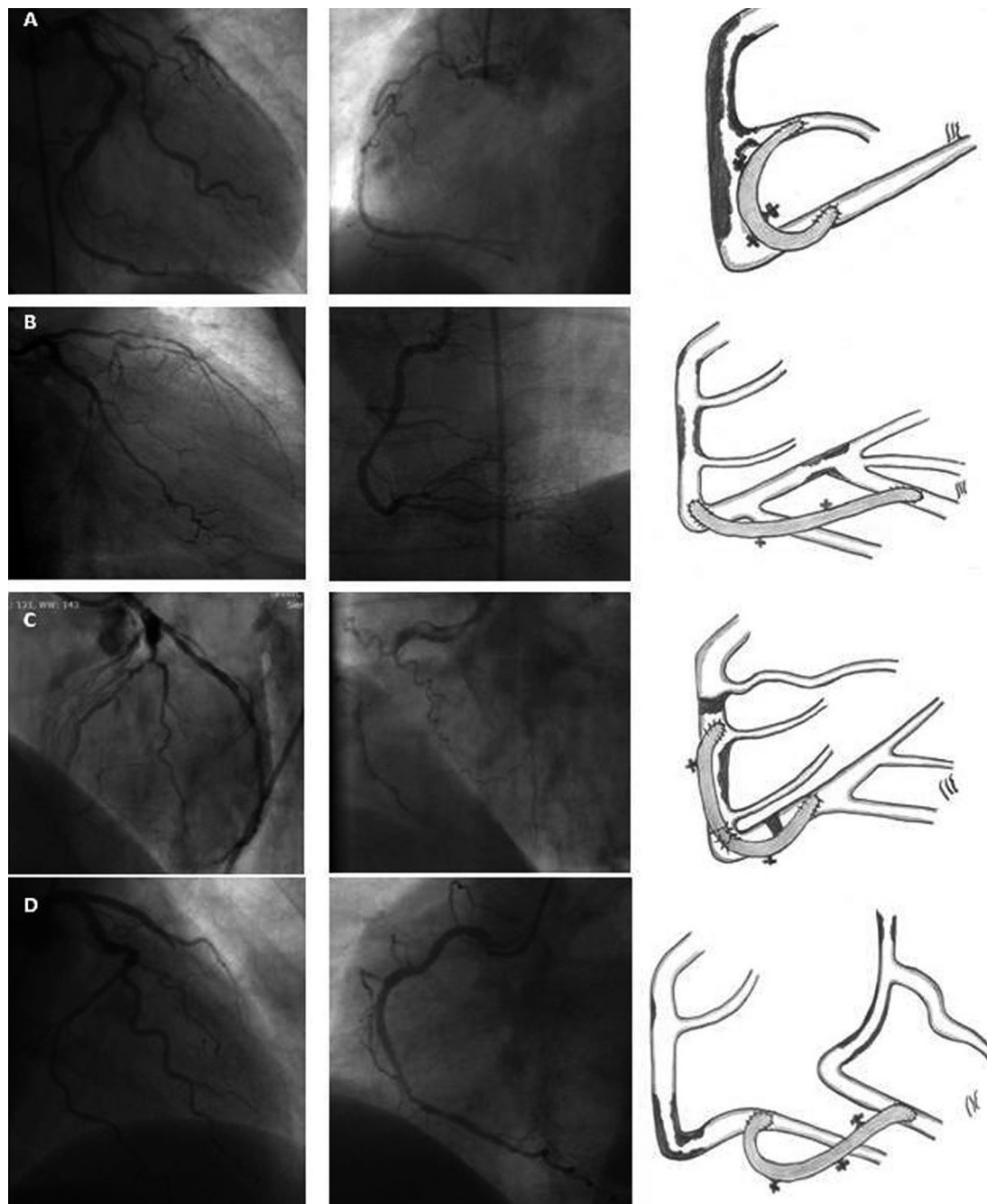


Fig. 1 - The examples of a right-sided intracoronary bridge.

A-I: severe three vessel CAD with an occluded LAD. A-II: Diffuse MDR involving an anterolateral branch (the dashed arrow). A-III: ICB placed between the anterolateral branch and distal RCA. [ICB: radial artery; Inflow mode: IRTG with in situ RITA, see Fig. 2A].

B-I: Left coronary branches with diffuse LAD disease. B-II: a MDR. The dashed arrows show a second anterolateral and acute marginal branches arising from the RCA segment between the two stenoses. B-III: ICB placed between mid and distal RCA. [ICB: radial artery; Inflow mode: ITRG with in situ RITA].

C-I: LAD is nearly occluded; the distal segment of a dominant RCA is filled retrogradely (arrow). C-II: an occluded MDR, a second anterolateral and acute marginal branches are detected (dashed arrows). C-3: ICB providing 3 distal anastomoses. The distal anastomoses for second anterolateral and acute marginal branches are placed on the corresponding RCA segments. [ICB: radial artery; Inflow mode: IRTG with in situ RITA].

D-I: the arrow shows the left posterolateral branch; LAD is occluded. D-II: arrow shows an intrastent stenosis placed in mid RCA. D-III: ICB placed between PDA and left posterolateral branch [ICB: free-LITA; inflow mode: CRTG with free RITA; see Fig. 2B]

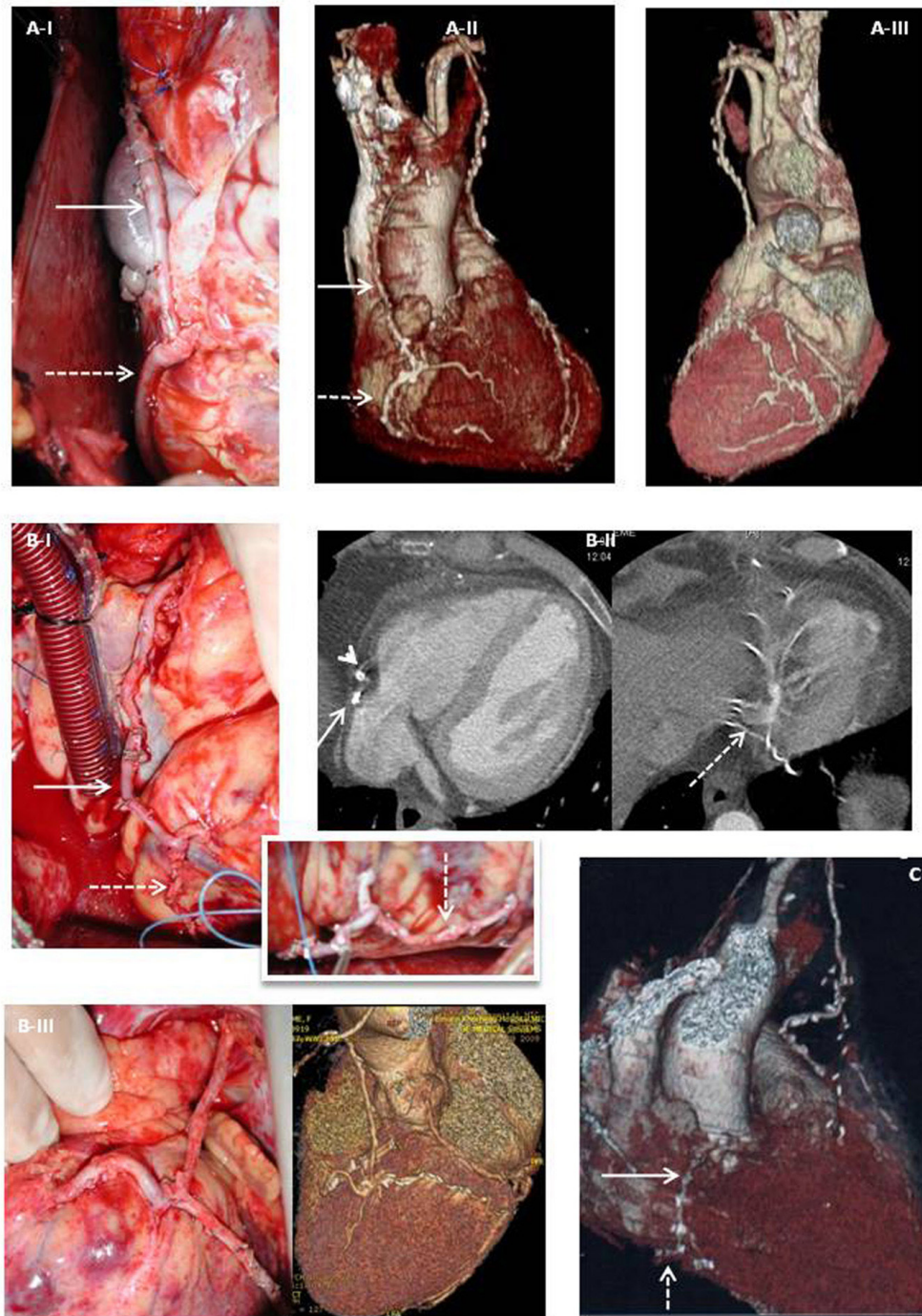


Fig. 2 - The arterial Inflow modes by in situ RITA (IRTG) and coronaro-coronary grafting (CRTG).

A-I: operative view of an ITRG with in situ RITA. A-II: postoperative CT angiography showing the arterial inflow (arrow) and ICB (dashed arrow). A-III: the postoperative CT-angiography of the left-sided composite arterial graft (endarterctomized LAD with extensive arterial roofing). B-I: operative view of CRTG: arrows and dashed arrows show the arterial inflow and ICB respectively. B-II: postoperative CT angiography of CRTG. The head of arrow shows the native RCA with in-stent stenosis. The arrow displays the arterial inflow and ICB at the level of their composite anastomosis. B-III: operative view and postoperative control of the left-sided composite arterial graft. C-I: preoperative coronary angiography displaying an occluded RCA and LAD in a patient with three vessel disease. The arrows show an acute marginal branch and distal RCA. C-II: the post-operative CT angiography showing the patent CRTG (arrow: arterial inflow; dashed arrow: ICB). [ICB: free LITA; Inflow mode: CRTG using radial artery].

Restoring the collateral pathways and functional features of coronary circulation should render the aim of complete revascularization more attainable. Reaching a coronary reserve closer to the normal does support a better myocardial protection and enhances the ability of myocardium to meet an increased demand in CBF. Despite a myriad of all arterial bypassing techniques being successfully reported; yet, controversy exists regarding their functional capacity to restore an aortocoronary reserve close to that of a normal double inflow coronary system. A single inflow feature and increased vulnerability of the arterial grafts facing native competitive flow are still matters of debate<sup>[3-5]</sup>.

In the setting of coronary artery disease with MDR referred to surgical revascularization, bypassing the right coronary system is generally confined to its inferoposterior territory. An inadequate length of arterial grafts, a more complex layout required for sequential bypassing, a small size of an anterolateral or acute marginal branch to host for a distal anastomosis, and severe calcifications are technically the main limiting factors that could compromise graft's patency. In addition, the existence of a differential profile along RCA for native competitive flow (adversely affecting patency of the arterial grafts especially for coronary stenosis less than 90%) arouses the current reluctance for arterial CRR<sup>[2-5]</sup>.

From a technical point of view, using an ICB overcomes the aforementioned technical issues: ICB reduces the number of sequential bypassing, enhances technical flexibility in fashioning sequential anastomoses with proper angulations if required, and remedies the limiting length of arterial grafts. Performing the distal anastomosis on an intermediate segment of RCA supporting an anterolateral or acute marginal branch is an alternative in a case of unsuitable anatomy (Figure 1C). It may be preferable to establish the final layout of ICB operatively, as the pre-operative coronary angiography could lead to over- or underestimation of the total number of targets amenable to revascularization (Figure 1).

Patients with compromising revascularization of LAD or distal RCA (poor runoff, extensive endarterectomy, and arterial reconstruction) incur an exceptionally high risk for perioperative myocardial infarction, therefore restoring some amount of the coronary collateral pathways as a "backup" sounds crucial. Diffuse coronary artery disease severely affects the epicardial arterial network that is in charge of optimizing the diastolic phase of CBF. The latter can be partly compensated for by using an arterial ICB, creating a new functional epicardial arterial network. Our results show a 100 % early patency rate for ICBs placed between different RCA branches with various degrees of stenosis, suggesting a better aptitude of ICB to face the native competitive flow. It can be speculated that ICB acts

as a systolic redistributing circuit between the targets, thereby reducing the amount of systolic reversed flow in its arterial inflow.

Right-sided reverse T grafting should only be performed on carefully selected patients. If any doubts remain about the suitability of target sites for hosting a distal anastomosis, difficulty in dissection for RCA or its branches, and quality of arterial grafts, the patient should not be put on the risk side of the benefit/ risk ratio. It is definitively inadvisable to proceed with such a procedure using the unsuitable distal rest of arterial conduits.

Being technically more demanding with an increased ischemic time can be reproached. The increased ischemic time is related to a greater number of large arterial anastomoses that should be fashioned meticulously. In addition, 50% of patients in the current series needed extensive coronary arterial reconstruction. A safer pump run, meticulous cardioprotection encompassing a protocol for tight glycemic control, and the expected benefits of a double inflow complete revascularization do outweigh the foreseeable and inevitable reluctances<sup>[1,2]</sup>. Bicaval cannulations with right atrial isolation were used in this series as part of integrative myocardial protection. By the time of heart displacement, kinking of vena cava increases venous pressures; therefore, selective drainage of vena cava provides additional organ protection, specially reducing the rate of neurologic and neurocognitive disorders. As the appropriate lengths of all grafts and ICB are measured pre-procedurally on loaded heart, its subsequent unloading with bicaval drainage does not induce errors in estimation. The absence of in-hospital mortality and occurrence of major adverse cardiocerebral events supports the aforementioned perioperative majors and the current techniques, recalling that best myocardial protection is provided by integrated revascularization.

So far, further functional investigations, a larger scale clinical series, and longer-term results are mandatory to support the advocated benefits of CRR using a composite arterial reverse T graft.

Authors' roles & responsibilities	
MHA	Conception and study design, performed procedures and/or experiments, writing of the manuscript or review of its content
MAT	Final approval of manuscript
SA	Final approval of manuscript conception and design of the study
NSL	analysis and/or interpretation of data, carrying out of operations and/or experiments, writing of the manuscript or review of its content

---

REFERENCES

1. Osswald BR, Blackstone EH, Tochtermann U, Schweiger P, Thomas G, Vahl CF, et al. Does the completeness of revascularization affect early survival after coronary artery bypass grafting in elderly patients? *Eur J Cardiothorac Surg.* 2001;20(1):120-5.
2. Gaudino M, Alessandrini F, Glieca F, Luciani N, Cellini C, Pragliola C, et al. Effect of surgical revascularization of a right coronary artery tributary of an infarcted nonischemic territory on the outcome of patients with three-vessel disease: a prospective randomized trial. *J Thorac Cardiovasc Surg.* 2004;127(2):435-9.
3. Yie K, Na CY, Oh SS, Kim JH, Shinn SH, Seo HJ. Angiographic results of the radial artery graft patency according to the degree of native coronary stenosis. *Eur J Cardiothorac Surg.* 2008;33(3):341-8.
4. Nakajima H, Kobayashi J, Tagusari O, Bando K, Niwaya K, Kitamura S. Competitive flow in arterial composite grafts and effect of graft arrangement in off-pump coronary revascularization. *Ann Thorac Surg.* 2004;78(2):481-6.
5. Gaudino M, Alessandrini F, Pragliola C, Cellini C, Glieca F, Luciani N, et al. Effect of target artery location and severity of stenosis on mid-term patency of aorta-anastomosed vs. internal thoracic artery-anastomosed radial artery grafts. *Eur J Cardiothorac Surg.* 2004;25(3):424-8.