

Nasal trumpet as a long-term remedy for obstructive sleep apnea syndrome in a child

SAGE Open Medical Case Reports
Volume 9: 1–4
© The Author(s) 2021
Article reuse guidelines:
sagepub.com/journals-permissions
DOI: 10.1177/2050313X211055303
journals.sagepub.com/home/sco



Tammy Yau¹ , Ruchi Bansal², Kimberly Hardin³,
Craig Senders⁴ and Kiran Nandalike⁵ 

Abstract

We present a case of successful long-term use of nasal trumpet for severe obstructive sleep apnea syndrome in a child with cerebral palsy and complex medical issues. Obstructive sleep apnea syndrome is frequently seen in pediatric patients with cerebral palsy due to their abnormal airway tone and pulmonary vulnerability. Identifying children with cerebral palsy who are at risk for obstructive sleep apnea syndrome is important because its treatment can improve quality of life and seizure control. Although first-line treatment for obstructive sleep apnea syndrome is adenotonsillectomy, children with cerebral palsy are more likely to have residual obstructive sleep apnea syndrome postoperatively. Other options such as positive airway pressure therapy and other upper airway surgeries may pose significant challenges and tolerance issues, as in our patient. As demonstrated in our report, the low rate of complications and ease of use make nasal trumpets a potential long-term treatment option for children with obstructive sleep apnea syndrome who fail or cannot comply with the traditional treatment options.

Keywords

Nasal trumpet, nasopharyngeal airway, obstructive sleep apnea, case report

Date received: 20 August 2021; accepted: 6 October 2021

Introduction

Obstructive sleep apnea syndrome (OSAS) is one of the common forms of sleep-disordered breathing in children with a population prevalence of about 2%–5%.¹ OSAS is characterized by episodes of partial or complete upper airway closure in sleep with disturbances in sleep architecture and gas exchange during sleep. Untreated OSAS is associated with learning and behavioral problems, cardiovascular complications, and poor growth, and timely intervention can minimize these consequences.^{1,2} OSAS frequently affects children with cerebral palsy (CP).³ Adenotonsillectomy, the first-line therapy for OSAS in pediatric patients, is not always curative in children with CP as given multiple underlying risk factors including airway hypotonia.⁴ Children with CP are also at higher risk for respiratory complications post adenotonsillectomy.⁵ Other options including positive airway pressure therapy or other upper airway surgeries pose challenges and intolerance in children with CP. We present a case of a pediatric patient with CP and severe OSAS that was successfully treated with use of a nasal trumpet.

Case presentation

Patient was born at an outside institution at 34 weeks gestation and over time diagnosed with Borjeson-Forsman-Lehman syndrome with multiple congenital anomalies including a cleft palate, cerebral palsy and global developmental delay, partial epilepsy, septo-optic dysplasia, sensorineural hearing loss, multicystic dysplastic kidney, growth

¹Department of Pediatrics, University of California Davis Health, Sacramento, CA, USA

²Department of Pulmonary and Critical Care Medicine, Delano Regional Medical Center, Delano, CA, USA

³Department of Pulmonary and Critical Care Medicine, University of California Davis Health, Sacramento, CA, USA

⁴Department of Otolaryngology, University of California Davis Health, Sacramento, CA, USA

⁵Division of Pulmonary Medicine, Department of Pediatrics, University of California Davis Health, Sacramento, CA, USA

Corresponding Author:

Kiran Nandalike, Division of Pulmonary Medicine, Department of Pediatrics, University of California Davis Health, 2516 Stockton Boulevard, Sacramento, CA 95817, USA.
Email: knandalike@ucdavis.edu



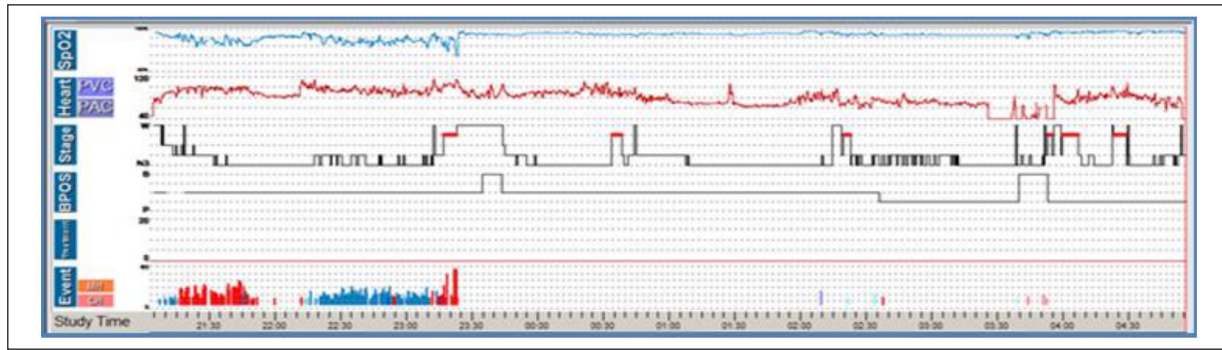


Figure 1. An overnight summary of PSG showing severe OSAS during the first 2 hours of the study, followed by placement of nasal trumpet with significant improvement in PSG findings post trumpet placement.

hormone deficiency, mitral valve regurgitation and gastroesophageal reflux disease. She underwent cleft palate repair at age of 12 months and a gastrostomy tube placement around 15 months. During these hospitalizations, she was noted to have snoring and sleep-related hypoxemia. A polysomnogram (PSG) performed at 15 months of age, the details of which are unavailable, was reported as severe OSAS with severe desaturations. A sleep endoscopy was performed, which was notable for pharyngolaryngomalacia without adenotonsillar hypertrophy. A nasal trumpet was introduced as a short-term measure since she was medically too fragile for any other surgical procedures. She was successfully using the nasal trumpet for OSAS when she was referred to our Otolaryngology and cleft clinic at the age of 2.5 years. Her OSAS symptoms progressed over time, and she underwent adenotonsillectomy and uvulopalatopharyngoplasty, at the age of 4 years. Uvulopalatopharyngoplasty was performed, in addition to adenotonsillectomy, due to severe oropharyngeal crowding and in anticipation of high failure rate with adenotonsillectomy alone. PSGs were not performed either prior to or after the procedure since these were not routinely performed for young children at our Institution during that time. The postoperative course was complicated by postoperative respiratory infections and prolonged recovery in the pediatric intensive care unit. Initially, OSAS improved but symptoms slowly returned, and she resumed using the nasal trumpet. Other standard second-line management options such as nasal continuous positive airway pressure (CPAP) therapy and tracheostomy were offered, but the mother refused these options given patient's intolerance of facial devices and the history of prolonged postsurgical recovery, respectively. At age 8, patient had a sleep study without nasal trumpet, which showed Apnea–Hypopnea Index (AHI) of 4.1 events per hour so was recommended to continue using the trumpet. She continued to use the trumpet at night for several years with intermittent issues with adherence and occasional skin breakdown from trumpet taping. She was referred to our sleep clinic at age 12 for further investigation and management of OSAS. A split night PSG with and without the trumpet was obtained and scored per the standard

criteria.⁶ Baseline study showed severe OSAS with AHI 81.7 events/hour and minimum oxygen saturation (SpO_2) of 68%. There was remarkable improvement with the nasal trumpet with residual AHI of 1.5 events/hour and minimum SpO_2 of 89% (Figure 1).

An awake nasal laryngoscopy was performed in clinic without the nasal trumpet that showed redundant pharyngeal tissue with significant nasopharyngeal and oropharyngeal crowding (Figure 2(a)). Repeat laryngoscopy with the trumpet showed open hypopharynx with the trumpet tip just above the epiglottis, completely bypassing the obstructed segment (Figure 2(b)).

Parents were reassured with the study findings and she was recommended to continue using the flexible nasopharyngeal 18 French trumpet. Skin adhesive options were provided to decrease skin breakdown and improve adherence, and the child, now a young adult, continues to use nasal trumpet to date with good control of her OSAS.

Discussion

This report demonstrates the efficacy and tolerance of nasal trumpet as a treatment for OSAS in a pediatric patient with cerebral palsy, cleft palate, and a rare genetic disease who was not a candidate for CPAP or upper airway surgeries.

Pediatric OSAS is characterized by symptoms as daytime sleepiness or hyperactivity, snoring, obstructed breathing, and at least one of the PSG finding of one or more obstructive events per hour of sleep or obstructive hypoventilation.⁷ Untreated, OSAS can lead to long-term adverse effects on behavior and cognition, as well as in the regulation of the cardiovascular, metabolic, and autonomic systems and can even lead to sudden death.² OSAS is seen in much higher prevalence in children with cerebral palsy.³ Poor medullary control of breathing, inadequate neuromuscular tone, increased oral secretions, seizures, gastroesophageal reflux, and inability to change posture and protect the airway at night are just some of the many risk factors for OSAS and obstructive hypoventilation during sleep in pediatric patients with cerebral palsy.⁸ OSAS is usually underdiagnosed and

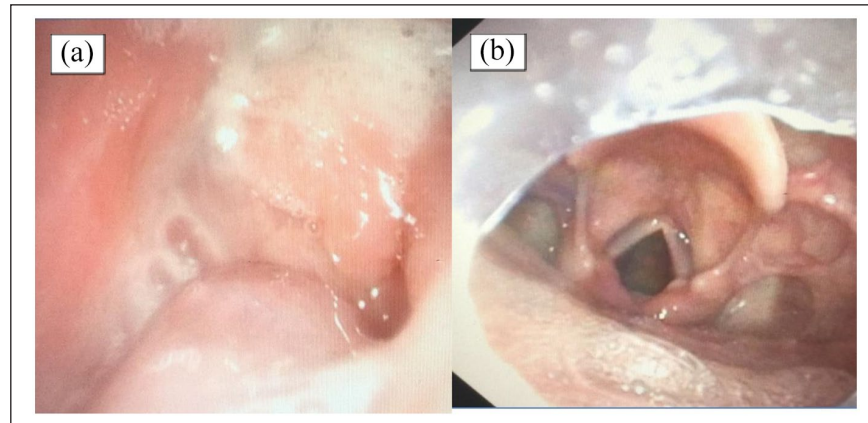


Figure 2. (a) Nasal endoscopy without the nasal trumpet showing redundant pharyngeal tissue. (b) Nasal endoscopy with the nasal trumpet showing open hypopharynx with the tip just above the epiglottis.

undertreated in this patient population. Our patient not only has CP but significant other medical morbidities including Borjeson-Forssman-Lehman syndrome. This is a X-linked genetic disorder, predominantly affecting males, characterized by small genitalia, large ear lobes, moderate mental retardation, and mild obesity. Females have milder manifestations with learning problems and physical features of thickened ear lobes, shortened toes, prominent supraorbital ridges, and deep-set eyes.⁹ Although children with Borjeson-Forssman-Lehman syndrome have risk factors for OSAS such as hypotonia, truncal obesity, and cleft lip and palate, OSAS is not known to be associated with this syndrome.

Effective treatment of OSAS can lead to substantial improvement in daytime functioning and quality of life outcomes in children with CP.¹⁰ According to the American Academy of Pediatric guidelines, adenotonsillectomy is the first-line therapy for OSAS in children with 80% success rate in the general pediatric population.¹ However, adenotonsillectomy has a much lower success rate in children with CP due to multiple risk factors including airway hypotonia which often makes them poor surgical candidates as well.¹¹ Uvulopalatopharyngoplasty and tongue base suspension, in conjunction with adenotonsillectomy, has been successful in some children,¹² but these procedures are invasive and associated with complications needing prolonged hospitalization like in our patient. Children with CP and OSAS are also already at increased risk for postoperative airway complications due to comorbid pulmonary, neurologic, cardiac, and/or craniofacial conditions.⁸ PAP therapy can be successfully implemented, but needs close monitoring, parental participation, and careful mask selection. A full-face CPAP mask can pose challenges of airway aspiration in a developmentally challenged child, and long-term PAP use carries the risks of skin break down and midface development issues.⁴ Tracheostomy is performed on some pediatric patients with severe OSAS, but carries the risks of infection, acute airway obstruction, inability to vocalize, and additional care needs for these families.

A nasopharyngeal airway (NPA), also called a nasal trumpet, is a tube inserted into the nasal passageway to bypass the nasopharyngeal obstruction. NPA is used for treatment of OSAS in some adults with moderate-to-severe OSAS.¹³ It has also been used as a short-term treatment of OSAS in children with syndromic craniosynostosis as well as Pierre Robin Syndrome.^{14,15} Studies in adults, mostly limited to case reports and case series, have shown mixed results with NPA, with some studies reporting significant improvement in AHI with good tolerance to NPA and others reporting poor tolerance to these devices. Also, the data on long-term use are limited. Most of the studies assessed the benefit in the immediate postoperative period or short-term use at home.¹³ For our patient, we have not only demonstrated the efficacy of the device by the objective data such as laryngoscopy and PSG but also shown the successful long-term use without any complications. The commonly reported side effects of nasal trumpet use include poor patient tolerance, nasal mucosal/pharyngeal irritation causing pain or bleeding, and nasopharyngeal incompetence with nasal regurgitation. There are also reports of nasal ulcers or infections such as sinusitis from nasal intubations with an NPA, none of which are experienced by our patient. NPA tube size, shape, and material can be adjusted to improve long-term adherence and comfort. An adjustment period is often needed to build tolerance to the NPA, as would be expected with any other device treatment such as a CPAP machine. The use of a nasopharyngeal airway can be a successful long-term treatment modality in children like the current case where other first-line options have failed or are not feasible and adherence is excellent.

Conclusion

In the current case, we have demonstrated the efficacy of nasal trumpet by laryngoscopy and polysomnography findings. NPA or a nasal trumpet, due to its ease of use and low rate of complications, can be a long-term remedy for OSAS

in children who fail or cannot comply with the traditional treatment options.

Declaration of conflicting interests

The author(s) declared no potential conflicts of interest with respect to the research, authorship, and/or publication of this article.

Ethical approval

Our institution does not require ethical approval for reporting individual cases or case series.

Funding

The author(s) received no financial support for the research, authorship, and/or publication of this article.

Informed consent

Written informed consent was obtained from a legally authorized representative(s) for anonymized patient information to be published in this article.

ORCID iDs

Tammy Yau  <https://orcid.org/0000-0003-3714-4190>

Kiran Nandalike  <https://orcid.org/0000-0002-0176-5617>

References

- Marcus CL, Brooks LJ, Draper KA, et al. Diagnosis and management of childhood obstructive sleep apnea syndrome. *Pediatrics* 2012; 130(3): e714–e755.
- Capdevila OS, Kheirandish-Gozal L, Dayyat E, et al. Pediatric obstructive sleep apnea: complications, management, and long-term outcomes. *Proc Am Thorac Soc* 2008; 5(2): 274–282.
- Garcia J, Wical B, Wical W, et al. Obstructive sleep apnea in children with cerebral palsy and epilepsy. *Dev Med Child Neurol* 2016; 58(10): 1057–1062.
- Tan HL, Kheirandish-Gozal L and Gozal D. Obstructive sleep apnea in children: update on the recognition, treatment and management of persistent disease. *Expert Rev Respir Med* 2016; 10(4): 431–439.
- End C, Propst EJ, Cushing SL, et al. Risks and benefits of adenotonsillectomy in children with cerebral palsy with obstructive sleep apnea: a systematic review. *Laryngoscope*. Epub ahead of print 25 May 2021. DOI: 10.1002/lary.29625.
- Berry RB, Budhiraja R, Gottlieb DJ, et al. Rules for scoring respiratory events in sleep: update of the 2007 AASM Manual for the Scoring of Sleep and Associated Events. Deliberations of the Sleep Apnea Definitions Task Force of the American Academy of Sleep Medicine. *J Clin Sleep Med* 2012; 8(5): 597–619.
- Sateia MJ. International classification of sleep disorders-third edition: highlights and modifications. *Chest* 2014; 146(5): 1387–1394.
- Fitzgerald DA, Follett J and Van Asperen PP. Assessing and managing lung disease and sleep disordered breathing in children with cerebral palsy. *Paediatr Respir Rev* 2009; 10(1): 18–24.
- Gecz J, Turner G, Nelson J, et al. The Borjeson-Forssman-Lehman syndrome (BFLS, MIM #301900). *Eur J Hum Genet* 2006; 14(12): 1233–1237.
- Hsiao KH and Nixon GM. The effect of treatment of obstructive sleep apnea on quality of life in children with cerebral palsy. *Res Dev Disabil* 2008; 29(2): 133–140.
- Katz SL, Monsour A, Barrowman N, et al. Predictors of post-operative respiratory complications in children undergoing adenotonsillectomy. *J Clin Sleep Med* 2020; 16(1): 41–48.
- Kosko JR and Derkay CS. Uvulopalatopharyngoplasty: treatment of obstructive sleep apnea in neurologically impaired pediatric patients. *Int J Pediatr Otorhinolaryngol* 1995; 32(3): 241–246.
- Kumar AR, Guilleminault C, Certal V, et al. Nasopharyngeal airway stenting devices for obstructive sleep apnoea: a systematic review and meta-analysis. *J Laryngol Otol* 2015; 129(1): 2–10.
- Abel F, Bajaj Y, Wyatt M, et al. The successful use of the nasopharyngeal airway in Pierre Robin sequence: an 11-year experience. *Arch Dis Child* 2012; 97(4): 331–334.
- Ahmed J, Marucci D, Cochrane L, et al. The role of the nasopharyngeal airway for obstructive sleep apnea in syndromic craniosynostosis. *J Craniofac Surg* 2008; 19(3): 659–663.