



CASE REPORT

Induction immunotherapy followed by surgery for hilar unicentric Castleman disease

Fumihiko Shoji¹  | Ken Takase² | Yuka Kozuma¹ | Koji Yamazaki¹  | Shigeto Kawauchi³ | Sadanori Takeo¹

¹Department of Thoracic Surgery, Clinical Research Institute, National Hospital Organization Kyushu Medical Center, Fukuoka, Japan

²Department of Hematology, Clinical Research Institute, National Hospital Organization Kyushu Medical Center, Fukuoka, Japan

³Department of Pathology, Clinical Research Institute, National Hospital Organization Kyushu Medical Center, Fukuoka, Japan

Correspondence

Fumihiko Shoji, Department of Thoracic Surgery, Clinical Research Institute, National Hospital Organization Kyushu Medical Center, 1-8-1, Jigyohama, Chuo-ku, Fukuoka 810-8563, Japan.
Email: fumshojifumshoji@gmail.com

Abstract

Castleman disease is a rare disease borne of a B cell lymphoproliferative disorder of uncertain cause. Standard therapy for the unicentric type of Castleman disease localized as a single mass or single lymph-node station is surgical extirpation. Nevertheless, in the thoracic cavity, unresectable cases or cases of incomplete extirpation of the tumor without lung scarring owing to tumor size/location have been noted. In such cases, lung resection (e.g., lobectomy, pneumonectomy) or additional therapy (immunotherapy, chemotherapy, radiotherapy) after resection is required. However, few instances of patients receiving induction immunotherapy or chemotherapy followed by surgery have been reported. Here, we describe a 21-year-old woman with unicentric Castleman disease originating from the left hilum. The tumor seemed to involve/be in contact with the pulmonary vein and bronchus. Tumor location indicated that initial resection was necessary to sacrifice upper and lower pulmonary lobes. To avoid these pulmonary resections, induction therapy followed by surgery was selected. Induction therapy using rituximab was very efficacious. Resection after induction therapy was completed only by tumor extirpation, and resulted in preservation of pulmonary function. Thoracic surgeons might consider induction therapy followed by resection if the tumor is resectable UCAD, but initial resection is needed and sacrifices a large amount of pulmonary function.

KEYWORDS

rituximab, surgery, Unicentric Castleman disease

INTRODUCTION

Castleman disease (CAD) is a rare disease borne of a B cell lymphoproliferative disorder of uncertain cause.¹ The unicentric type of Castleman disease (UCAD) is localized as a single mass or single lymph-node station. UCAD is usually found in the intrathoracic cavity (lung, mediastinum, pleura, chest wall).

Standard therapy for UCAD is surgical extirpation. Unresectable cases or cases of incomplete extirpation of the tumor without lung scarring owing to tumor size/location have been previously recorded. In such cases, lung resection (e.g., lobectomy, pneumonectomy) or additional therapy (immunotherapy, chemotherapy, radiotherapy)

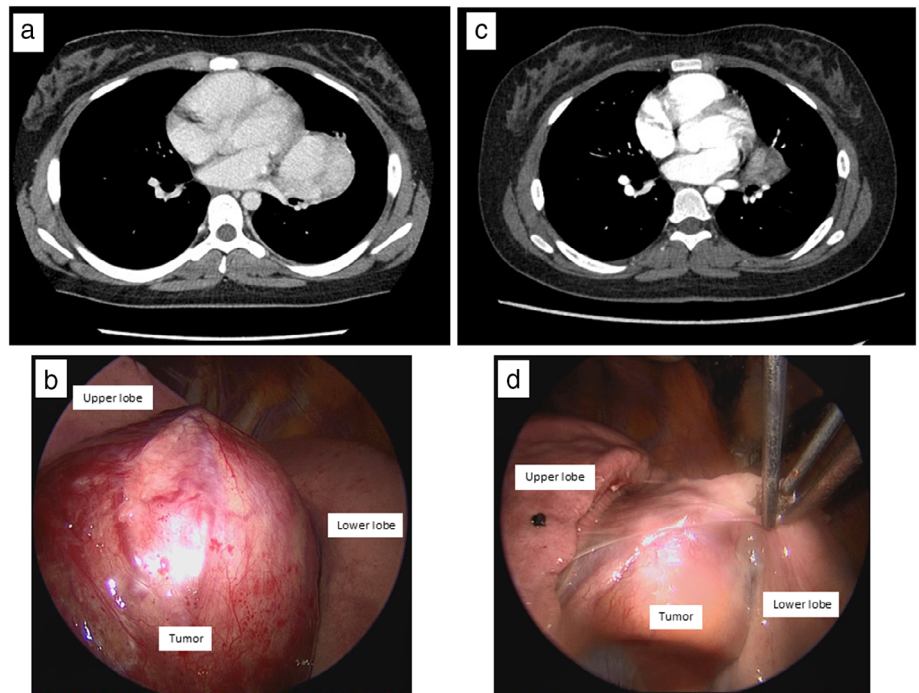
after resection is required. However, few instances of patients receiving induction immunotherapy or chemotherapy followed by surgery have been reported.

Here, we describe a case of hilar UCAD resected completely after induction therapy with rituximab with preservation of lung function.

CASE REPORT

A 21-year-old woman was admitted to our hospital after incidental detection of a left hilar mass on chest radiography. Contrast-enhanced computed tomography (CT) of the chest showed a large mass (61 mm) at the left hilum

FIGURE 1 (a) Chest computed tomography before and (c) after induction immunotherapy with rituximab. The left tumor mass decreased remarkably in size. Intraoperative findings before (b) and after (d) induction immunotherapy with rituximab. The vascular-rich tumor located at the left hilum appeared to be involved in the intralobular space (b). The tumor shrank remarkably (d)



(Figure 1a). This tumor showed high density (i.e., it had many blood vessels). The tumor seemed to involve V4–5, and to retract the inferior pulmonary vein and lingula, and lower bronchus. ^{18}F -fluorodeoxyglucose (FDG) positron emission tomography did not show significant accumulation of FDG except in the hilar tumor (maximum standardized uptake value = 5.87). The patient was a never smoker and had no comorbidities. Physical examination and laboratory data (including serum tumor markers) did not show abnormalities. First, a video-assisted biopsy of the tumor was undertaken to obtain a tissue sample for pathological confirmation. This vascular-rich tumor was at the left hilum and seemed to involve the space between the upper and lower lobes (Figure 1b). Pathological examination revealed some reactive lymph follicles with hyalinized germinal centers and a moderate-to-severe vascular reaction in the enlarged paracortex. Immunohistochemistry revealed a cluster of differentiation (CD)20-positive germinal centers. Based on these findings, we diagnosed this tumor as UCAD, hyaline-vascular type. However, complete resection of the tumor warranted sacrifice of the left lung (at least a left lingular segmentectomy and lower lobectomy). Therefore, we planned induction chemotherapy followed by surgery. The patient was started on rituximab monotherapy (four infusions of 375 mg/m^2 at weekly intervals). The tumor was re-evaluated after four infusions. Radiography and contrast-enhanced CT showed significant remission of the tumor to 35 mm (Figure 1c). The tumor appeared to be separate from the pulmonary vein and bronchus according to three-dimensional CT. Therefore, we believed that we could extirpate the tumor completely without sacrificing the left lung. Thus, video-assisted thoracoscopic resection of the tumor

was carried out. The patient was placed in a right lateral position. A thoracoscope was introduced through the seventh intercostal space on the anterior axillary line. Thoracoscopy revealed neither tumor dissemination nor effusion. Thereafter, an anterolateral thoracotomy measuring 7 cm was undertaken, and the left thoracic cavity was opened through the fifth intercostal space. A remarkably shrunken tumor with mild fibrous adhesions to surrounding tissues was recognized at the left hilum (Figure 1d). First, the intralobular pulmonary artery was exposed but the tumor was left intact. The tumor showed mild adhesion to the lower bronchus (B8), but dissecting this adhesion was simple. After encircling the superior and inferior pulmonary veins, the tumor was meticulously dissected. Finally, tumor extirpation was complete. The total operative time was 240 min and total blood loss was 119 ml. Macroscopic findings showed a yellowish tumor (Figure 2a). Microscopic examination showed the tumor was comprised of numerous large follicular structures and small blood vessels with hyaline walls in the center of the follicles. The appearance was suggestive of CAD of hyaline vascular type without evidence of malignancy (Figure 2b). The surgical margin was free of tumor cells. The patient was discharged on postoperative day-4 and showed no evidence of tumor recurrence at 1-year follow up. We analyzed the change in immunohistochemical expression of B lymphocyte surface antigen (CD20; clone, L26; Nichirei Biosciences) and B cell antigen receptor complex-associated protein alpha chain (CD79-alpha; clone, JCB117; Nichirei Biosciences) as B cell markers in tumors before and after rituximab therapy. As a result, the intensity and extent of expression of CD20 and CD79-alpha was decreased in the tumor after rituximab

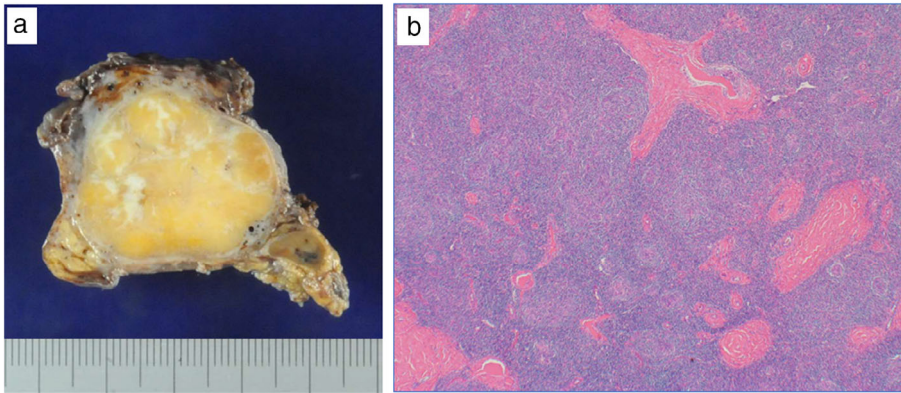


FIGURE 2 (a) Macroscopic and (b) microscopic findings of the tumor. The cross-section of the tumor was yellowish and hard (a). The tumor was composed of numerous large follicular structures and small blood vessels with hyaline walls in the center of the follicles (staining with hematoxylin & eosin) (b)

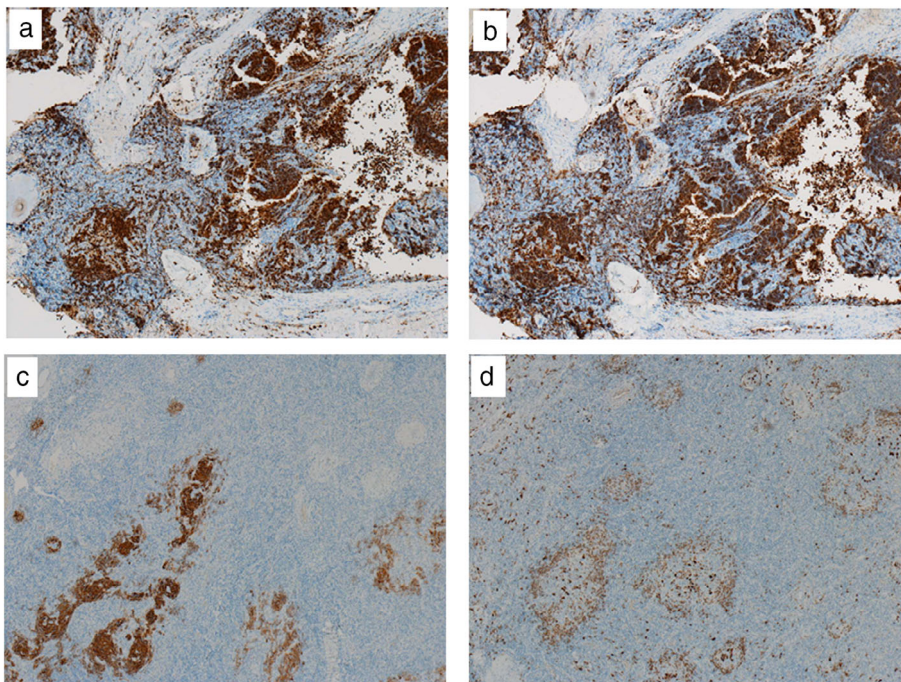


FIGURE 3 Immunohistochemical staining. The intensity and extent of expression of CD20 and CD79-alpha were decreased in the tumor after rituximab therapy ([c] CD20 and [d] CD79-alpha) compared with that before rituximab therapy ([a] CD20 and [b] CD79-alpha)

therapy compared with that before rituximab therapy (Figure 3a–d).

DISCUSSION

CAD is a rare lymphoproliferative disease, first described by Benjamin Castleman in the 1950s. CAD is divided into two types: UCAD and multicentric CAD (MCAD). “Gold standard” therapy for UCAD is complete resection. Moreover, the differential diagnosis of the various subtypes of MCAD such as PC neoplasm polyneuropathy, organomegaly, endocrinopathy, monoclonal plasma cell disorder, skin changes-associated MCAD, idiopathic MCAD and Human herpes virus-8 (HHV8) associated MCAD have previously been reported.^{1,2} Thus, an excisional lymph node biopsy including not a core or fine-needle biopsy is required to confirm the definite pathological diagnosis of CAD.³ We also selected a video-assisted excisional biopsy of the tumor

to obtain a sufficient tissue sample for pathological confirmation. Talat et al.⁴ concluded that complete resection was the only significant predictor of mortality in CAD patients. However, in cases of an unresectable mass or dangerous tumor location, tumor reduction by administration of corticosteroids, immunotherapy (e.g., rituximab, siltuximab, tocilizumab or anakinra), chemotherapy (e.g., etoposide, cladribine or cyclophosphamide), or radiotherapy should be considered.¹ National Comprehensive Cancer Network (NCCN) guidelines recommend unresectable UCAD to be treated by radiotherapy or rituximab with/without prednisone with/without cyclophosphamide or embolization and, thereafter, complete resection is done, if possible.⁵ Boutboul et al.⁶ retrospectively evaluated the treatment and outcome of 71 UCAD patients. Thirty-three of 71 UCAD patients (46.5%) were diagnosed with unresectable disease. Nineteen of 33 UCAD patients (57.6%) received reduction chemotherapy or immunotherapy. As a result, seven of 19 UCAD patients (36.8%) underwent resection. Although our patient

did not have unresectable UCAD, initial complete resection involved left lingular segmentectomy and lower lobectomy. Considering the tumor characteristics and patient age, we attempted induction therapy followed by surgery to preserve pulmonary function as much as possible based on NCCN guidelines for treatment of surgically unresectable UCAD. Among several agents for treatment of CAD, rituximab (a humanized monoclonal antibody to CD20) has been widely used and has shown significant activity in patients with multicentric CAD.⁷ According to NCCN guidelines, we also selected rituximab monotherapy for our patient as a regimen of induction therapy. Our immunohistochemical results (the intensity and extent of expression of CD20 and CD79-alpha) indicated that rituximab therapy was very efficacious. Thus, this tumor decreased remarkably in size upon induction therapy. Thereafter, complete resection was feasible and successful to avoid loss of pulmonary function. In conclusion, optimal treatment of UCAD is complete resection. Thoracic surgeons might consider induction therapy followed by resection if the tumor is resectable UCAD, but initial resection is needed and sacrifices a large amount of pulmonary function.

ACKNOWLEDGMENT

We thank Arshad Makhdum, PhD, from Edanz Group (www.edanzediting.com/ac) for editing a draft of this manuscript.

CONFLICT OF INTEREST

The authors declare that they have no competing interests.

ORCID

Fumihito Shoji  <https://orcid.org/0000-0002-0636-8696>

Koji Yamazaki  <https://orcid.org/0000-0003-2025-6268>

REFERENCES

1. Dispenzieri A, Fajgenbaum DC. Overview of Castleman disease. *Blood*. 2020;135:1353–64.
2. Yildiz J, Bagci M, Sayin S, Kaya A, Yilmaz F, Ekinci O, et al. The clinicopathological features and survival of Castleman disease: a multicenter Turkish study. *Eur Rev Med Pharmacol Sci*. 2022;26:1131–7.
3. Carbone A, Borok M, Damania B, Gloghini A, Polizzotto MN, Jayanthan RK, et al. Castleman disease. *Nat Rev Dis Primers*. 2021;7:84.
4. Talat N, Belgaumkar AP, Schulte KM. Surgery in Castleman's disease: a systematic review of 404 published cases. *Ann Surg*. 2012;255:677–84.
5. National Comprehensive Cancer Network. NCCN Clinical Practice Guidelines in Oncology: B-Cell Lymphomas. Version 1.2020. Published January 22, 2020.
6. Boutboul D, Fadlallah J, Chawki S, Fieschi C, Malphettes M, Dossier A, et al. Treatment and outcome of Unicentric Castleman disease: a retrospective analysis of 71 cases. *Br J Haematol*. 2019;186:269–73.
7. Chan KL, Lade S, Prince HM, Harrison SJ. Update and new approaches in the treatment of Castleman disease. *J Blood Med*. 2016;7:145–58.

How to cite this article: Shoji F, Takase K, Kozuma Y, Yamazaki K, Kawauchi S, Takeo S. Induction immunotherapy followed by surgery for hilar unicentric Castleman disease. *Thorac Cancer*. 2022;13(11):1722–5. <https://doi.org/10.1111/1759-7714.14424>