

case report

An unusual case of genital filariasis of the testicular tunics in an Italian patient

Alessia Fassari, Andrea Polistena, Giorgio De Toma, Enrico Fiori

From the Department of Surgery Pietro Valdoni, Umberto I Policlinico, Roma, Italy

Correspondence: Dr. Andrea Polistena · Department of Surgery Pietro Valdoni, Umberto I Policlinico, Roma, Italy · apolis74@yahoo.it · ORCID: <https://orcid.org/0000-0002-1319-1147>

Citation: Fassari A, Polistena A, De Toma G, Fiori E. An unusual case of genital filariasis of the testicular tunics in an Italian patient. *Ann Saudi Med* 2021; 41(3): 186-189. DOI: 10.5144/0256-4947.2021.186

Received: December 23, 2020

Accepted: March 6, 2021

Published: June 3, 2021

Copyright: Copyright © 2021, Annals of Saudi Medicine, Saudi Arabia. This is an open access article under the Creative Commons Attribution-NonCommercial-NoDerivatives 4.0 International License (CC BY-NC-ND). The details of which can be accessed at <http://creativecommons.org/licenses/by-nc-nd/4.0/>

Funding: None.

At least 27 million men present with urogenital manifestations of genital filariasis (GF). Although there is a large burden of GF in residents in endemic regions, infection in short-term travellers and in non-endemic areas is rare. We report the case of a 75-year-old Italian man referred to our institution for a testicular discomfort. Clinical examination and ultrasound detected a mass of 40×18 mm in the scrotum without signs of varicocele, hydrocele and testicular or epididymal abnormalities. After ineffective medical treatment, the patient underwent surgical excision. Histology demonstrated filarial granuloma with thick cuticles pathognomonic of an adult worm in the testicular tunics. Surgery has a fundamental role in localized cases of GF to remove nematodes from the fibrotic nodules. The present manuscript describes a singular case of GF observed in Italy in a non-immigrant patient with evidence of remnants of an adult worm in the testicular tunics.

SIMILAR CASES PUBLISHED: 11

Lymphatic filariasis (LF) is caused by infection of parasites classified as nematodes of the *Filarioidea* family. There are three types of filarial worms causing LF: *Wuchereria bancrofti*, which accounts for over 90% of the global burden, *Brugia malayi* and *Brugia timori*. LF affects about 120 million people in at least 83 countries throughout the tropics and subtropics. Its distribution extends from Latin America, across central Africa, Southern Asia and into the Pacific Islands.¹ At present, an estimated 43 million people in endemic areas suffer from sequelae of LF in the form of lymphedema and urogenital disorders. The number of cases of LF reported in non-endemic countries in the past 30 years has been very modest and the acquisition of filariasis by individuals who do not have a relevant travel history is extremely rare.²⁻⁵ At least 27 million men suffer from urogenital manifestations of genital filariasis (GF), presenting testicular hydrocele, lymph scrotum and dilation of the scrotal lymphatic vessels. *Wuchereria bancrofti* is the only lymphatic filarial parasite that specifically induces genital diseases.⁶⁻⁹ In Italy, some reports¹⁰⁻¹¹ have described the involvement of the genital area in cases of *Dirofilariasis* (i.e. *Dirofilaria repens*), which in rare cases presents with nodules in the subcutaneous tissues. A similar condition has also been reported in animals in Italy.¹²⁻¹⁴ A previous case of GF in Italy was described in an immigrant patient presenting with acute scrotal pain.¹⁵ In an era of massive immigration, observation of GF is likely to become more frequent in Western countries. Despite hydrocele being the most common presentation of GF, the discovery of filarial granuloma with cuticles specific to an adult worm in the testicular tunics, is a specific sign of the disease, which is rare in non-endemic areas.

CASE

A 75-year-old Italian man was referred to our institution in February 2020 with a 2-month history of testicular discomfort. At clinical examination, a nodular mass in the scrotum measuring about 4 cm was detected. His past medical history was unremarkable and no previous travels to regions endemic for filariasis were reported. A urological examination was negative for hydrocele, varicocele, peripheral lymphedema, adenopathy or other abnormalities and no fever or signs of systemic infection were detected. The laboratory tests showed mild eosinophilia with a normal white blood cell count. Ultrasonography (US) detected a 40×18 mm right scrotal isoechoic mass with internal vascularity, edema and light calcifications adherent to the right epididymis (**Figure 1**). No US signs of varicocele, hydrocele, testicular or epididymal abnormalities were detected. At US examination, the mass was adherent but not apparently originating from the testis or from the epididymis; therefore, a neoplasm was not primarily suspected and for this reason a fine needle aspiration (FNA) was not considered. Antibiotic therapy (doxycycline 200 mg daily) was administered for one week after which a mild reduction of the scrotal mass volume was observed (20×16 mm vs 40×18mm). The primary differential diagnosis was a local infection; alternatively a large inflamed granuloma was suspected. The patient's condition was closely followed but since the clinical condition persisted, a surgical approach was considered after 4 weeks. The mass was removed by scrotal incision and isolation with sharp dissection from the epididymis, which was adherent but not infiltrated (**Figure 2**). An intraoperative pathological examination excluded the presence of neoplastic features. The final histology showed fibroadipose tissue with chronic inflammatory eosinophilic infiltration, macrophages and isolated giant cells, associated with the presence of thick cuticles pathognomonic of a filarial worm (**Figure 3**). Albendazole 800 mg daily was administered for 3 weeks to complete the treatment. The patient healed after this treatment. At current follow up the patient is doing well with no signs of recurrence.

DISCUSSION

A review of the scientific literature shows that the number of cases of LF infection reported in non-endemic countries in the past 30 years is quite modest.^{1,2} The acquisition of insect-transmitted tropical diseases by individuals who do not have a relevant travel history is extremely rare.³ Moreover, while hydrocele with an associated epididymo-orchitis is the most common presentation of GF, the discovery of an adult worm in the

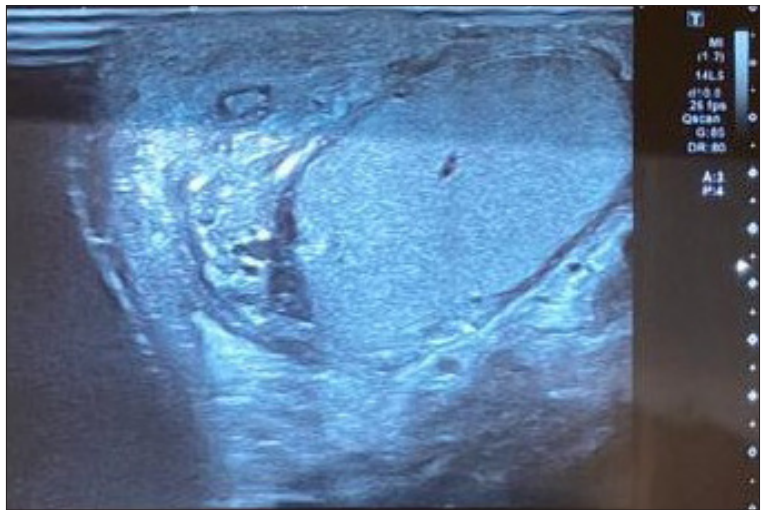


Figure 1. Scrotal ultrasound showing a 40×18 mm right scrotal isoechoic mass with internal vascularity, edema and light calcifications embedded just above the epididymis.

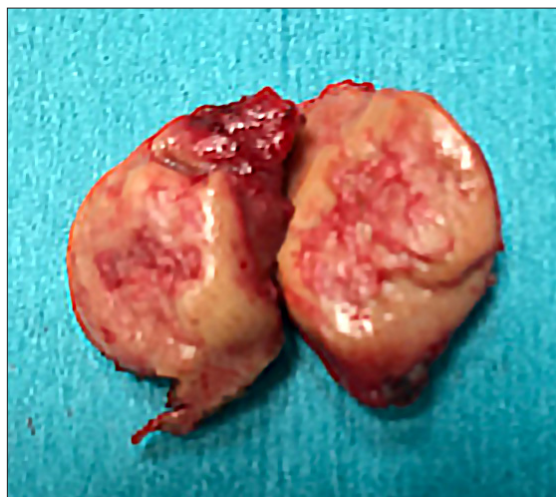

Figure 2. The gross specimen measuring 25×20×15 mm.

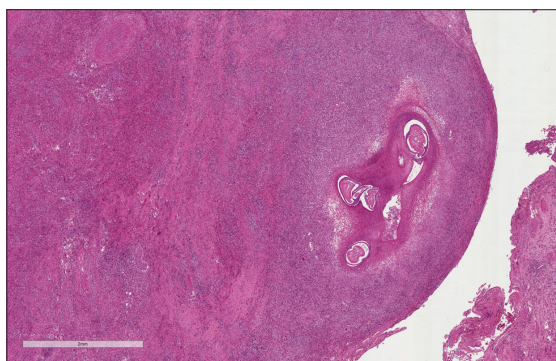


Figure 3. Histology after H&E staining (5×) showing fibroadipose tissue with chronic inflammatory eosinophilic infiltration, macrophages and isolated giant cells, associated with the presence of thick cuticles pathognomonic of a filarial worm.

testicular tunics is extremely rare in non-endemic areas. The cause of human filariasis in non-endemic areas, as in the reported case, might be ascribed to local mosquito species becoming vectors for human infection from an animal reservoir, for example dogs or autochthonous cattle.^{3,13-14} The disease may be manifested in the genitourinary organs in an acute (lymphangitis, epididymitis, orchitis, abscess) or chronic form (elephantiasis, hydrocele, calcifications of tunica vaginalis). The acute phase may appear in a milder form with only moderate pain in the genital area, with no systemic symptoms and only slight inflammation of the cord and epididymis. The chronic phase is the result of permanent obstruction of lymphatic vessels resulting in a hydrocele of the tunica vaginalis.¹⁶ GF lesions occur in the stage of early established filarial infection. After migration outside the bloodstream, microfilariae may produce granulomas that contain an abundance of eosinophilic cells, macrophages, occasional giant cells and zones of necrosis of a variable extent. Clinically, it presents as a tender, well-circumscribed, firm nodule close to the epididymis. As observed in the present report, a preoperative diagnosis of GF with testis involvement was difficult due to the extreme rarity of the disease in non-endemic areas and the lack of specific clinical and US features. Parasitic infections are often known to produce mild to moderate eosinophilia but this was not considered under the circumstances in our patient until a final histology was available. US is an ideal non-invasive tool to detect adult worms residing in the scrotal lymphatic vessels. The "filarial dance sign" caused by undulating movements of adult worms

during scrotal US may be diagnostic but it may also be absent, as in our case.¹⁷ The role of FNA is questionable even though it is used for differential diagnosis in countries where the prevalence of genital tuberculosis and filariasis is high, whereas in non-endemic areas it is not advisable for the risk of disease dissemination when malignancy may be suspected.¹⁷ There is no consensus on management methods for the different urogenital manifestations. Doxycycline treatment can serve as an effective treatment to halt or ameliorate lower stages of GF and diethylcarbamazine citrate is thought to be the anthelmintic treatment of choice for LF.¹⁸ Diethylcarbamazine is not registered in Italy; thus the medical treatment of acute LF is usually based on a high initial dose of ivermectin together with corticosteroid and chlorpheniramine followed by albendazole for 3-4 weeks.¹⁹ Drug treatment has been suggested even in the treatment of mild edema, but the benefit appears to be inconsistent and the drugs take a long time to act. Surgical intervention is usually considered after medical management has failed and is required to remove nematodes in fibrotic nodules.²⁰ Urogenital surgery is considered by WHO to be a critical aspect in controlling filarial morbidity, with the aim of minimizing infertility produced by the effects of this disease and to improve the aesthetic of affected young adults.²¹⁻²³ In the presented case surgery was carried out only for local symptoms and disease control as well as obtaining diagnosis but it must be highlighted that in non-endemic countries GF should be considered as a differential diagnosis when a scrotal mass with the above reported features is present.

REFERENCES

1. Global programme to eliminate lymphatic filariasis: progress report, 2018. *Weekly Epidemiological record*, No 41, 11 October 2019. <https://www.who.int/publications/i/item/who-wer9441-457-472>.
2. Local Burden of Disease 2019 Neglected Tropical Diseases Collaborators. The global distribution of lymphatic filariasis, 2000-18: a geospatial analysis. *Lancet Glob Health*. 2020;8(9):e1186-e1194. doi:10.1016/S2214-109X(20)30286-2.
3. Jones RT. Non-endemic cases of lymphatic filariasis. *Trop Med Int Health* 2014;19(11):1377-1383. <https://doi.org/10.1111/tmi.12376>.
4. Karim MJ, Haq R, Mablesen HE, Sultan Mahmood ASM, Rahman M, Chowdhury SM, Rahman AKMF, Hafiz I, Betts H, Mackenzie C, Taylor MJ, Kelly-Hope LA. Developing the first national database and map of lymphatic filariasis clinical cases in Bangladesh: Another step closer to the elimination goals. *PLoS Negl Trop Dis*. 2019 Jul 15;13(7):e0007542. doi: 10.1371/journal.pntd.0007542.
5. Vishwanath T, Nagpal A, Ghate S, Sharma A. Scrotal Lymphangiectasia with Penile Elephantiasis in Underlying Lymphatic Filariasis-Challenging the Diagnostic Mind! A Case Report. *Dermatopathology (Basel)*. 2021 Jan 1;8(1):10-16. doi: 10.3390/dermatopathology8010002.
6. Zulfiqar H, Malik A. Bancroftian Filariasis. 2020 Sep 8. In: *StatPearls [Internet]*. Treasure Island (FL): StatPearls Publishing; 2020 Jan-. PMID: 31613462.
7. Batirel A, Regmi SK, Singh P, Mert A, Konety BR, Kumar R. Urological infections in the developing world: an increasing problem in developed countries. *World J Urol*. 2020 Nov;38(11):2681-2691. doi: 10.1007/s00345-020-03120-3.
8. Vashisht D, Oberoi B, Venugopal R, Baveja S. Acute scrotum: Hansen's disease versus filariasis. *Int J Mycobacteriol*. 2018 Apr-Jun;7(2):195-197. doi: 10.4103/ijmy.ijmy_60_18.
9. Pani SP, Kumaraswami V, Das LK. Epidemiology of lymphatic filariasis with special reference to urogenital-manifestations. *Indian J Urol* 2005;21:44-9.
10. Fini M, Perrone A, Vagliani G, Andreini C, Salvi G, Misuriello G, Di Silverio A. A case of human dirofilariasis (*D. repens*) of the spermatic cord. *Minerva Urol Nefrol*. 1992 Apr-Jun;44(2):129-31. Italian. PMID: 1411862.
11. Pampiglione S, Fioravanti ML, Piccolotti D, Pizzicannella G, Reale D. Human dirofilariasis in Italy: a new case in the spermatic cord. *Parassitologia*. 2002 Jun;44(1-2):93-6. PMID: 12404815.
12. Cancrini G, Favia G, Giannetto S, Merulla R, Russo R, Ubaldino V, Tringali R, Pietrobelli M, Del Nero L. Nine more cases of human infections by *Dirofilaria repens* diagnosed in Italy by morphology and recombinant DNA technology. *Parassitologia*. 1998 Dec;40(4):461-6. PMID: 10645559.
13. Napoli E, Bono V, Gaglio G, Giannetto S, Zanghi A, Otranto D, Brianti E. Unusual localization of *Dirofilaria repens* (Spirurida: Onchocercidae) infection in the testicle of a dog. *Comp Immunol Microbiol Infect Dis*. 2019;66:101326. doi: 10.1016/j.cimid.2019.06.007.
14. Galuppi R, Militerno G, Bassi P, Nanni A, Testoni S, Tampieri MP, Gentile A. Evidence for bovine parafilariosis in Italy: first isolation of *Parafilaria bovicola* (Tubangui, 1934) from autochthonous cattle. *Vet Parasitol*. 2012 Feb 28;184(1):88-91. doi: 10.1016/j.vetpar.2011.08.005.
15. Di Tonno F, Mazzariol C, Piazza N, Murer B. Filariasis: an emergent cause of acute scrotal pain. *Urologia*. 2010;77(2):147-9. PMID: 20890873.
16. Richens J. Genital manifestations of tropical diseases. *Sex Transm Infect* 2004 Feb;80(1):12-7. doi: 10.1136/sti.2003.004093.
17. Barreto SG, Rodrigues J, Pinto RG. Filarial granuloma of the testicular tunic mimicking a testicular neoplasm: a case report. *J Med Case Reports* 2008;2:321. doi: 10.1186/1752-1947-2-321.
18. Rajasekaram S, Anuradha R, Manokaran G, Bethunaickan R. An overview of lymphatic filariasis lymphedema. *Lymphology*. 2017;50(4):164-182. PMID: 30248721.
19. Sgrelli A, De Socio GVL, Papili R, D'Annibale ML, Baldelli F. Loa loa filariasis in Italy: review of the literature with a clinical report. *Le Infezioni in Medicina* 2011;3:147-151.
20. Betts H, Martindale S, Chiphwanya J, Mkwanda SZ, Matipula DE, Ndhlovu P, Mackenzie C, Taylor MJ, Kelly-Hope LA. Significant improvement in quality of life following surgery for hydrocoele caused by lymphatic filariasis in Malawi: A prospective cohort study. *PLoS Negl Trop Dis*. 2020 May 8;14(5):e0008314. doi: 10.1371/journal.pntd.0008314.
21. Lim KH, Speare R, Thomas G, Graves P. Surgical Treatment of Genital Manifestations of Lymphatic Filariasis: A Systematic Review. *World J Surg*. 2015;39(12):2885-99. doi: 10.1007/s00268-015-3220-4.
22. Kumar KL, Manokaran G. Genital Lymphedema: A New Technique Of Correction Surgery. *Lymphology*. 2015;48(3):153-6. PMID: 26939162.
23. Singh V, Sinha RJ, Sankhwar SN, Kumar V. Reconstructive surgery for penoscrotal filarial lymphedema: a decade of experience and follow-up. *Urology*. 2011 May;77(5):1228-31. doi: 10.1016/j.urol.2010.10.026. Epub 2011 Jan 22. PMID: 21256561.