

# Subacute perimyocarditis in a young patient with COVID-19 infection

Jose V. Monmeneu  \*<sup>1</sup>, Eloy Dominguez Mafe  <sup>2</sup>, Jorge Andres Soler<sup>3</sup> , Bruno Ventura Perez  <sup>2</sup>, Javier Solsona Caravaca  <sup>2</sup>, Ricardo Broseta Torres<sup>4</sup>, Pilar García-Gonzalez<sup>1</sup>, Laura Higuera Ortega  <sup>1</sup>, Maria P. Lopez-Lereu  <sup>1</sup>, and Alicia M. Maceira  <sup>1</sup>

Received 17 April 2020; first decision 22 April 2020; accepted 12 May 2020; online publish-ahead-of-print 23 May 2020

<sup>1</sup>Cardiovascular Unit, ASCIRES Biomedical Group, Valencia, Spain; <sup>2</sup>Department of Cardiology, General Hospital, Castellon, Spain; <sup>3</sup>Department of Internal Medicine, General Hospital, Castellon, Spain; and <sup>4</sup>Radiology Unit, ASCIRES Biomedical Group, Valencia, Spain

A 43-year-old male patient with unremarkable past medical history was admitted to the Infectious Diseases Unit for suspected respiratory infection by COVID-19. On arrival, the patient reported fever that started 14 days before and persisted for 10 days, dry cough, and haemoptoic sputum. Nasopharyngeal swabs were immediately obtained, confirming COVID-19 positivity.

On admission, he had a heart rate of 77 b.p.m., blood pressure of 135/80 mmHg, temperature of 36.8°C, and SpO<sub>2</sub> of 91%.

Chest X-ray (Panel A) revealed a diffuse interstitial pattern with opacities in both lungs.

ECG (Panel B) showed sinus rhythm with minimal ST-segment elevation and extensive repolarization abnormalities.

Urgent portable transthoracic echocardiogram showed a left ventricle of normal dimensions with mild hypertrophy and overall hypokinesia, with LVEF 50–55%. A mild hyper-refringence pattern was also observed at the lateral wall of the left ventricle.

Laboratory results were: high-sensitivity troponin T curve of 29–24–24–18–15 ng/L (<14 ng/L) (Supplementary material online), NT-proBNP 456 pg/mL (<125 pg/mL), ferritin 1060 ng/mL (<300 ng/mL), D-dimer 790 ng/mL (<500 ng/mL), C-reactive protein 14 mg/L (<10 mg/L), leucocyte count  $4.03 \times 10^3/\mu\text{L}$  ( $> 4.8 \times 10^3/\mu\text{L}$ ), 83% neutrophils (<70%), and lymphocytes  $0.42 \times 10^3/\mu\text{L}$  ( $>0.9 \times 10^3/\mu\text{L}$ ), 10.4% (>19%).

Based on these findings, a cardiac magnetic resonance (CMR) study was requested to rule out the presence of acute myocarditis.

CMR at 1.5 T was performed 15 days after admission; right pulmonary condensation along with associated pleural effusion was seen in the multislice anatomical sequences (Supplementary material online). A left ventricle of normal volume with concentric hypertrophy

and mild depressed systolic function (LVEF 53%) secondary to diffuse hypokinesia was observed (Supplementary material online, Videos S1–S4). Global longitudinal strain was decreased (Supplementary material online). Myocardial oedema with a predominant subepicardial pattern was seen in the lateral, anterior, inferior, and apical segments on T2 short tau inversion recovery (Panels C and D) and T2 mapping sequences (Panels E and F; average, 60 ms; mid-septum, 53 ms; lateral wall, 67 ms, reference value ~50 ms), determining wall pseudo-hypertrophy. Pericardial oedema without associated effusion was also observed. Native T1 and extracellular volume (ECV) both were increased in relation to the acute inflammatory process (native T1, Panels G and H: average, 1110 ms; mid-septum, 1047 ms; lateral wall, 1204 ms, reference value ~950 ms. ECV, Panels I and J: average, 33%; mid-septum, 29%; lateral wall, 39%; reference value ~24%). Late gadolinium sequences showed extensive, patchy intramyocardial/subepicardial enhancement affecting the entire lateral, anterior, inferior, and apical septal walls and the pericardium (Panels K–M).

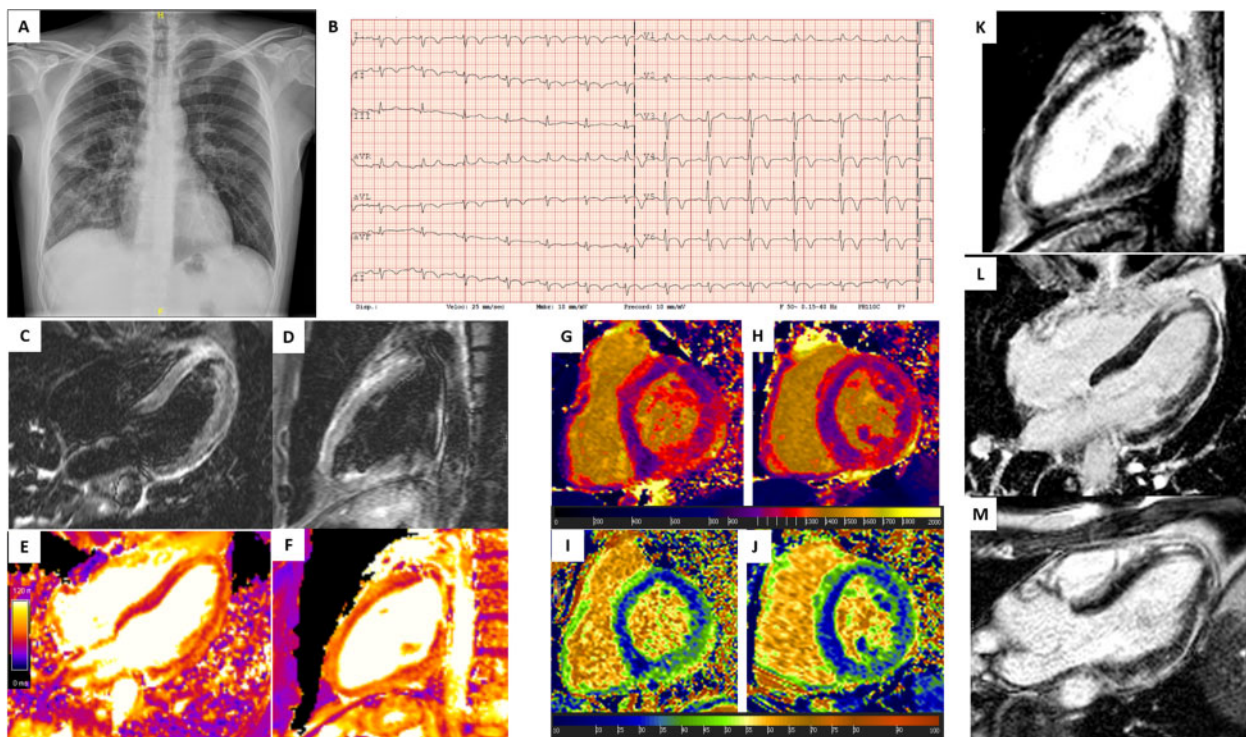
Viral serology by immunochromatography performed 15 days after onset of symptoms yielded IgM-negative and IgG-positive coronavirus 2019-nCoV. In conclusion, the final diagnosis was subacute perimyocarditis with mild systolic dysfunction associated with respiratory infection caused by COVID-19 (>15 days from the onset of symptoms). Hydroxychloroquine and azithromycin were administered but discontinued 2 days later due to QT interval prolongation. Bisoprolol, tocilizumab, and methylprednisolone were administered thereafter. During the hospital stay, the patient had no arrhythmias, chest pain, dyspnoea, dizziness, or palpitations at any time. The patient was discharged 8 days after hospital admission. After hospital discharge, a control CMR is scheduled to take place in ~1 month.

\*Corresponding author. Tel: +34 96 340 40 77, Fax: +34 96 340 06 40, Email: [jmonmeneu@eres.com](mailto:jmonmeneu@eres.com)

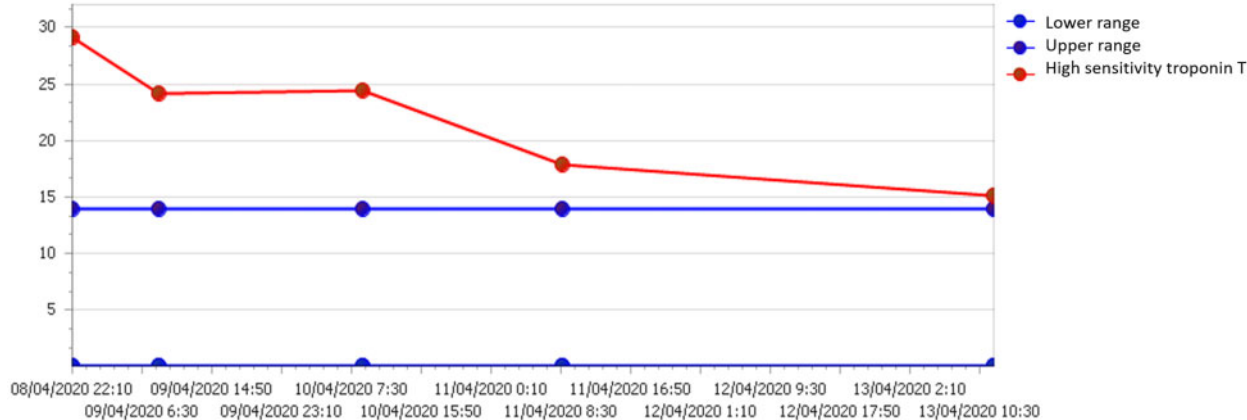
Handling Editor: Inga Voges

© The Author(s) 2020. Published by Oxford University Press on behalf of the European Society of Cardiology.

This is an Open Access article distributed under the terms of the Creative Commons Attribution Non-Commercial License (<http://creativecommons.org/licenses/by-nc/4.0/>), which permits non-commercial re-use, distribution, and reproduction in any medium, provided the original work is properly cited. For commercial re-use, please contact [journals.permissions@oup.com](mailto:journals.permissions@oup.com)



**Figure 1** (A) Chest X-ray showing a diffuse interstitial pattern with opacities in both lungs. (B) Electrocardiogram showing sinus rhythm with minimal ST segment elevation and extensive repolarization abnormalities. (C and D) T2 short tau inversion recovery long-axis four- and two-chamber views, showing regional oedema of the lateral, anterior, inferior, and apical left ventricle predominantly, with subepicardial involvement. (E and F) T2 mapping long-axis images showing high values of T2 on average and predominantly in the lateral, anterior, inferior, and apical segments. (G–J) T1 native (above) and ECV (below) images reveal high values of T1 native and ECV. K–M Contrast-enhanced cardiac magnetic resonance long-axis imaging shows patchy intramyocardial/subepicardial enhancement affecting the entire lateral, anterior, inferior, and apical septal walls, and the pericardium.



**Figure 2** Time course of the high-sensitivity troponin T curve.

This case provides further evidence obtained with CMR of extensive myocardial inflammatory involvement secondary to SARS-CoV-2 infection that has been described in some patients but the mechanism of which is currently not fully understood.

The patient gave us his consent to publish the case. This form is available upon request.

Panel A. Chest X-ray showing a diffuse interstitial pattern with opacities in both lungs.

Panel B. Electrocardiogram showing sinus rhythm with minimal ST segment elevation and extensive repolarization abnormalities.

Panels C and D. T2 short tau inversion recovery long-axis four- and two-chamber views, showing regional oedema of the lateral,

anterior, inferior, and apical left ventricle predominantly, with subepicardial involvement.

Panels E and F. T2 mapping long-axis images showing high values of T2 on average and predominantly in the lateral, anterior, inferior, and apical segments.

Panels G–J. T1 native (above) and ECV (below) images reveal high values of T1 native and ECV.

Panels K–M. Contrast-enhanced cardiac magnetic resonance long-axis imaging shows patchy intramyocardial/subepicardial enhancement affecting the entire lateral, anterior, inferior, and apical septal walls, and the pericardium.

Panels N and O. Coronal half-Fourier acquisition single-shot turbo spin-echo (HASTE) image (left) and axial steady-state free precession (SSFP) image (right) showing right pulmonary condensation along with associated pleural effusion.

Panels P–S. Strain analysis with a feature-tracking software (Circle CVI42<sup>®</sup>). From long-axis two- and four-chamber SSFP cine images, the longitudinal strain curve is derived. Both global values are impaired.

Video S1–S4 Two-chamber (S1), four-chamber (S2), three-chamber (S3), and short-axis (S4) cine images using SSFP showing a mild diffuse hypokinesia.

[Supplementary material](#) is available at *European Heart Journal Case Reports* online.