

# The sentinel node concept in prostate cancer: Present reality and future prospects

M. Egawa, M. Fukuda, H. Takashima, T. Misaki, K. Kinuya<sup>1</sup>, S. Terahata<sup>2</sup>

Departments of Urology, <sup>1</sup>Nuclear Medicine, <sup>2</sup>Clinical Pathology, Tonami General Hospital, Tonami, Japan

## ABSTRACT

A sentinel node (SN) is defined as the first site where cancer cells are carried by lymph flow from a tumor. If this definition (SN concept) correctly reflects the clinical reality, intraoperative SN biopsy would facilitate precise nodal staging. In malignant melanoma, a prolonged survival has been evidenced by a large-scale randomized controlled study. On the contrary, research on SN concept in deeply located cancers including prostate cancer, is still investigative, and no concrete data from clinical trials are yet available. Since 1993, several investigators have demonstrated that the SN concept could be applied in prostate cancer patients as well with high accuracy. Although promising and technically feasible in pre-clinical settings, many hurdles remain to be cleared before clinical application can be recommended. This review addresses the current status and related issues of the SN concept in prostate cancer, and discusses the future directions.

**Key words:** Lymph node dissection, prostatic neoplasm, sentinel node

## INTRODUCTION

When resecting malignant foci surgeons must always take into account the presence of invisible micrometastases so as to achieve the best possible prophylactic and systematic lymph node (LN) dissection. However, the more extensive the LN dissection the greater becomes the degree of surgical invasiveness, resulting in increasing organ functional impairment postoperatively. It would be ideal to be able to differentiate beforehand cases requiring and not requiring LN dissection, although the precision of currently available diagnostic imaging modalities is not yet sufficient for this purpose.<sup>[1]</sup> As one approach to help overcome this problem the clinical application of the sentinel node (SN) concept has been attracting increasing attention. This concept was first proposed in the early 1990s,<sup>[2]</sup> and as is well known, has been widely applied internationally especially for breast cancer<sup>[3]</sup> and malignant melanoma.<sup>[4]</sup> On the other hand, in the case of malignancies situated deep within the body, like prostate cancer, the applicability of the SN concept is still in the investigative stage with no firm conclusion yet reached as to its validity.<sup>[5,6]</sup>

SN is defined as the first LN to receive lymph flow from

---

For correspondence: Dr. Egawa M,  
Department of Urology, Tonami General Hospital, 1-61  
Shintomi-cho, Tonami939-1395, Japan.  
E-mail: egawa@p1.coralnet.or.jp

a tumor. The SN concept is based on the assumption that metastases would first develop in this SN. In other words, if no metastasis is present in this SN, metastases can be judged to be absent in other LN, and gratuitous LN dissection can be omitted thereby reducing surgical invasiveness. Conversely, when metastasis is present in the SN, the LN dissection can be extended facilitating a switch to a more radical surgical method. In this way, SN navigation surgery (SNNS) can be used to determine the indications for radical surgery according to the presence/absence of SN metastases and decide the extent of the LN dissection required, but in prostate cancer this is still limited to the basic science or clinical research stage and has in general not yet been applied clinically. This review first discusses the various issues related to LN dissection in prostate cancer, then, notes the basic research results validating the SN concept, and finally outlines the results of recent clinical research and future prospects.

## VARIOUS ISSUES RELATED TO LN DISSECTION IN PROSTATE CANCER

In contrast to numerous other malignancies, in prostate cancer various issues remain to be resolved regarding LN dissection.

### *The extent of dissection*

Usually, in any kind of malignancy the extent of LN dissection is determined by the state of the primary lesion (or regardless of its state), with the presence/absence of LN metastases diagnosed based on the pathological results of the

dissected LN. If this definition is not clarified comparisons of the results of studies on LN metastases conducted by different surgeons at different institutions will be problematic. When commencing research on LN in prostate cancer this is the first issue that has to be confronted. Even if a study specifies 'limited dissection', 'standard dissection', and 'extended dissection', in practice in many cases it will be impossible to know the actual extent of the dissection. Moreover, in some papers the extent of the dissection is not specified at all.

#### *The staging significance of lymph node dissection*

Since metastatic LNs of prostate cancer are not markedly enlarged and are usually microscopic in nature, the usefulness of diagnostic imaging in detecting them is low. Recently, modalities such as Positron Emission Tomography-Computerized Tomography (PET-CT) are being used, but their diagnostic rate of clinically localized prostate cancer is unfavorable.<sup>[7]</sup> Accordingly, although extending the range of the dissection would theoretically facilitate a more accurate diagnosis of LN metastases, the burden of complications such as edema of the lower extremities and lymphorrhea might be increased.<sup>[8,9]</sup> On the other hand, if according to nomograms such as Partin Tables<sup>[10]</sup> and Kattan nomogram<sup>[11]</sup> the probability of LN metastases is below a given level, omission of LN dissection at the time of radical prostatectomy (RPx) may also be a reasonable option at present.<sup>[12]</sup>

However, in studies in which extended LN dissection was performed for clinically localized cancer, metastases limited to beyond the range of standard dissection were found at high rates, namely 35%<sup>[13]</sup> and 19%<sup>[14]</sup> of metastasis-positive cases. Moreover, discrepancies in the histological findings are occasionally noted between biopsy specimens and totally resected specimens, with underestimation of the pathological stage becoming a problem when nomograms are used.<sup>[15]</sup>

#### *Therapeutic significance of lymph node dissection*

Bhatta-Dar *et al.*, performed RPx in 336 patients with low-risk prostate cancer (with dissection 140 cases/without dissection 196 cases) and retrospectively noted no difference in the six-year biochemical recurrence-free survival rate between the two groups.<sup>[16]</sup> In the study of Salomon *et al.*, in which 43 cases receiving perineal RPx without dissection and 25 cases undergoing retropubic RPx with dissection were compared, no difference in the five-year recurrence rate was found either, although the numbers were small.<sup>[17]</sup>

On the other hand, Bader *et al.*, who performed extended dissection in 367 patients with prostate cancer, reported that in the 40% of cases with only a single pelvic LN metastasis no biochemical recurrence was detected during a 45-month follow-up.<sup>[18]</sup> Similarly, Han *et al.* and Daneshmand *et al.*, reported that in patients with LN metastases biochemical non-recurrence rates of 15% and 21% at  $\geq 10$  years respectively

were observed.<sup>[19,20]</sup> In this way, it is clear that no consensus has yet been reached with respect to the therapeutic significance of pelvic LN dissection in prostate cancer.

#### *Significance of SN in prostate cancer*

In prostate cancer, not only the significance of the dissection itself but also the optimal method to achieve it have yet to be resolved, especially since it is difficult to accurately grasp the presence/absence of metastases. For example, even if the nomograms are used, the original data reflect the pathological results of only some of the intrapelvic LN, precluding the making of accurate predictions. Also, it is self-evident that the more limited the extent of the dissection is the less accurate will the diagnosis of metastases be.

In this context, it is very important to validate the SN concept as verified by extended dissection. If like in breast cancer and malignant melanoma the SN concept is validated, accurate information about the LN will be obtainable by biopsy of the SN alone. Moreover, based on the information on the state of LN metastases provided by the SN biopsy, SNNS can be performed to determine the appropriateness of radical treatment. In cases negative for LN metastases in which a long-term course can be anticipated, prostatectomy or radiotherapy can be applied, whereas in cases found to be metastasis-positive conservative treatment such as hormone therapy can be resorted to so as to spare the patient gratuitous invasiveness.

#### *Validation of the SN concept in prostate cancer*

Since the 1999 report of Wawroschek *et al.*, several groups have published papers regarding validation of the SN concept.<sup>[5,21-25]</sup> The largest scale study was that of Wawroschek *et al.*, in which the results of 1055 cases were analyzed.<sup>[6]</sup> Of these, LN metastases were found in 207 cases (19.6%), with false negative results (non-SN metastases found in the absence of SN metastases) noted in only 2/207 cases (1%). In 131/207 cases (63.3%), metastases were found beyond the range of routine dissection (external iliac LN + obturator LN). Other groups including our own have obtained similar results in smaller scale investigations [Table 1]. Techniques to validate the SN concept are outlined below.

#### *Tracers and their method of administration*

Tracers used in this context include Technetium (Tc)-labeled colloid, which is a radioisotope, and dyes. Dyes are seldom used alone and in most cases are used in combination with radioisotopes. Since dyes are taken up by lymph flow almost immediately after injection into the tissues, intraoperative observation under direct vision is required. When LNs are destroyed by surgical manipulations, the dye will flow out of the LN making accurate identification of the SN impossible. In surface cancers such as breast cancer and malignant melanoma this dye method is extremely useful, whereas in prostate cancer identification of the SN

**Table 1: Contemporary series of lymphatic mapping and SN validation studies**

Series	Approach	Tracer	Extent of dissection	No. of SN	SN identification rate	Complication	False negative
Brenot-Rossi <i>et al.</i> (n=100, 2008)	open	nanocolloid	extended	mean 3	69.4% in 60 MBq tracer 92.9% in 200 MBq tracer	not stated	2%
Weckermann <i>et al.</i> (n=1055, 2007)	open	nanocolloid	SN only ~ extended depending on risk factors	mean 7	97.2%	not stated	0.2%
Fukuda <i>et al.</i> (n=42, 2007)	open	phytate	extended	mean 4.9	97.6%	none	2.4%
Haker <i>et al.</i> (n=20, 2006)	laparoscopic	human albumin	extended	not stated	94.3%	1 neuropraxy 1 deep vein thrombosis	5%
Corvin <i>et al.</i> (n=28, 2006)	laparoscopic	nanocolloid	standard	mean 2.1	92.9%	1 lumphocele none	0%

**Table 2: LN metastasis by method**

	NHT(+)*	NHT(-)
routine H-E No. pts (%)	4 (14.8)	4 (26.7)
step section & IHC No. pts (%)	5 (18.5)	0 (0)
total LN mets No. pts (%)	9 (33.3)	4 (26.7)

\*NHT: neoadjuvant hormone therapy, Figures in parentheses are in percentage

is extremely difficult using this dye. This is because when the peritoneum is not detached from the pelvic floor LN stained with the dye cannot be verified visually. To achieve this, the peritoneum should be detached from the pelvic floor beforehand, although it is difficult to completely avoid damaging the LNs during this procedure. For this reason, use of radioisotopes is indicated for the identification of SN in prostate cancer.

Colloid particle diameter is an important factor determining the speed at which the tracer passes through the LN and the degree of entrapment of the colloid within the LN.<sup>[26]</sup> According to the type of colloid used as well as the timing of SN detection after tracer administration, the number of SN that can be pointed out will vary, and thus the number and distribution of SN will differ according to the type of colloid used and the individual investigator. Tracers are usually injected transrectally to the prostate, with one injection each to the left and right lobes in most cases. The administered dose also differs according to the individual investigator with the total dose usually in the range of about 0.2 cc to 3 cc. Our group injects tracer (<sup>99m</sup>Tc-phytate: 40 MBq/0.1 ml/site) under transrectal ultrasonography 5-6 h prior to surgery into the right and left peripheral zones of the prostate.

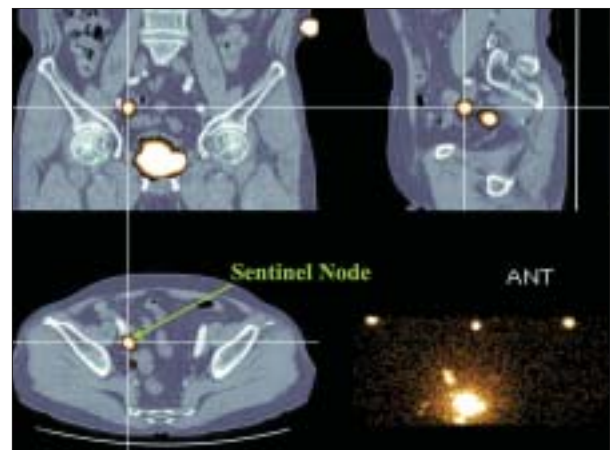
*Identification of SN*

Here, we introduce our SN identification method using <sup>99m</sup>Tc-phytate.<sup>[27]</sup> One hundred and eighty minutes after tracer injection lymphoscintigraphy is performed, and LN in which radioisotopes have been taken up, namely SN, are depicted on the film. The number of SN will vary according

to the time elapsing from the time of tracer injection to imaging, with the optimal time until imaging differing according to the type of colloid used.

Lymphoscintigrams can be displayed as planar images or single photon emission computed tomographs (SPECT), but SPECT imaging is preferable to discern the three-dimensional location of SN. Moreover if CT-SPECT fusion images are prepared the anatomical position of SN will be even better appreciated [Figure 1]. Three sites including the umbilicus are marked on CT and SPECT, and a fusion image is obtained by overlapping the marked sites of the two images on a computer.<sup>[28,29]</sup> At the time of intraoperative probing the information provided by this fusion image facilitates more accurate intraoperative detection of SN, and reduces the operating time for fusion-image supported SN resection.<sup>[30]</sup>

Since validation of the SN concept requires knowledge of the state of not only SN but also non-SN metastases, backup extended dissection is usually performed after SN biopsy. Jeschke *et al.*, perform SN biopsy and extended



**Figure 1:** An SN is clearly indicated at the right external iliac region on CT-SPECT fusion image

dissection laparoscopically, and to avoid the shine-through phenomenon, use a gamma probe that can detect gamma rays from 90 degrees laterally.<sup>[31]</sup> Although a strict learning curve exists, laparoscopic extended pelvic lymphadenectomy is worth performing for validation of the SN concept because this procedure yields an equivalent number of resected LNs with less morbidity.<sup>[32]</sup> Since in most other reports, validation has been performed under laparotomy, we introduce the method adopted by us here.

In short, through a lower abdominal midline incision the LN groups below the aortic bifurcation are located, and the SN is identified with a gamma probe. The gamma probe used intraoperatively is usually a handy type weighing about 200-300 g, which measures gamma rays released from the radionuclide at the tip detector portion [Figure 2]. LN identified by the gamma probe as SN are sampled, after which backup extended dissection is conducted, with the right and left common iliac vessels, external iliac vessels, internal iliac vessels, obturator fossa and presacral LN groups all resected separately. On a back table the LNs are mapped separately, and the SN more accurately identified [Figure 3]. The prostate injected with tracer emits high levels of radioactivity, which interfere with the detection of weak gamma rays from the SN, with this referred to as the shine-through phenomenon. To prevent the occurrence of this phenomenon, the prostate is covered with a lead shield.

#### *Pathologic diagnosis*

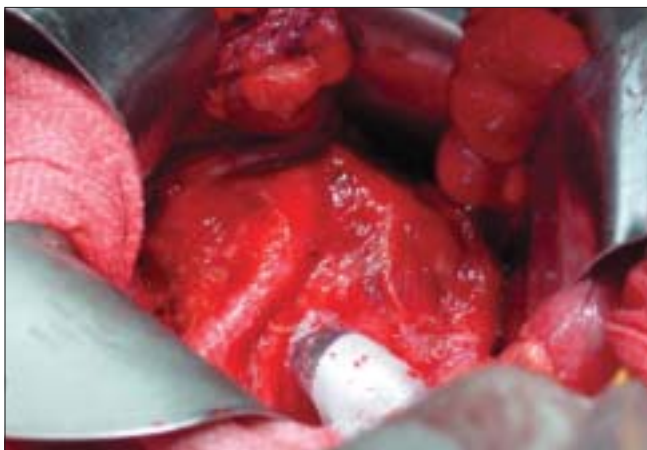The pathologic method used to diagnose resected LN differs with the individual investigator. In Wawroschek *et al.*'s method, the resected SN is cut into 2-mm slices, with five serial sections prepared from each slice. One of these slices is subjected to immunohistochemical staining using anti-cytokeratin antibody, and the remaining slices to routine hematoxylin and eosin staining.<sup>[33]</sup> To achieve a more detailed diagnosis of metastases we prepare serial sections from slices cut at 250 micrometer thickness, and like

Wawroschek *et al.*, perform immunohistochemical and H and E staining. Although the definition of micrometastases and their biological significance remain controversial, it is recognized that the diagnostic efficacy rate can be enhanced by 10-30% by adding immunohistochemical to H and E staining.<sup>[34]</sup>

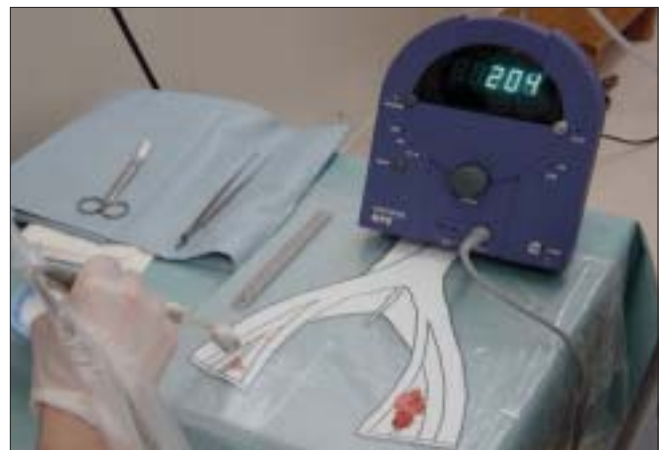## RESULTS

As noted above, the results of the largest scale study conducted by Wawroschek *et al.*, supported the validation of the SN concept in prostate cancer. Since in their study false negative results were limited to only 2/207 cases (1%), the diagnosis of metastases based on SN biopsy can be concluded to be a highly specific investigative method. On the other hand, excluding the two false negative cases, metastases were found in non-SN as well in 42 of 205 cases (20.5%). These findings suggest that SN biopsy alone may be of little therapeutic significance. Our data support the results of Wawroschek *et al.*, and in the approach adopted by us SN biopsy positive cases undergo extended dissection and all metastatic LN are resected.

Hitherto it has been widely recognized that neoadjuvant hormone therapy (NHT) decreases the accuracy of the pathologic diagnosis of RPx specimens. Here we introduce the results obtained from our SN research based on extended dissection and investigation of micrometastases that suggest that NHT similarly interferes with the accuracy of the diagnosis of LN metastases. Extended dissection and LN mapping were conducted in 42 patients with prostate cancer (mean age 67.8 years, mean PSA 25.1 ng/ml) without clinically evident metastases. The mean number of resected LN was 26.3. In the group in which NHT was not administered (n = 15), four cases were diagnosed as metastasis positive by pathologic examination of routinely H and E-stained largest cut sections of resected LN, with this number not increasing when micrometastasis diagnosis



**Figure 2:** A handy type gamma probe is used to detect SNs (*in-vivo* probing)



**Figure 3:** On a back table the LNs are mapped separately, and the SN more accurately identified (*ex-vivo* probing)



was added. On the other hand, in the group in which NHT was given ( $n = 27$ ), four cases were diagnosed as metastasis positive by routine pathologic examination (14.8%), with this number rising by five to a total of nine (33.3%) when micrometastasis diagnosis was added [Table 2]. In other words, these results imply that had NHT been given to the former group, micrometastases would have been overlooked in five cases. Thus, despite the fact that the definition of micrometastasis is unclear and their influence on prognosis is unknown, NHT was shown to decrease the diagnostic efficacy rate of LN metastases.

## FUTURE PROSPECTS

Based on the report of Wawroschek *et al.*, and our own results, if the SN is metastasis-free the patient can be deemed to be more likely negative for LN metastases. In this way, the SN concept can be considered to be valid in prostate cancer as well. In contrast, when metastases are present in the SN, it is thought that not all LN metastases can be resected with SN biopsy alone since in numerous cases affected LN will be located beyond the range of standard dissection, and moreover, metastases may be present in non-SN as well. However, all hitherto conducted research on SN in prostate cancer has been investigative in nature and undertaken at single institutions. In future, to promote research in this field and to aim for widespread clinical application various problems will first have to be overcome. First, multiinstitutional studies will be needed, and at a minimum there will have to be standardization of various influencing factors such as the type of tracer used, length of the period from tracer administration to SN biopsy, and extent of the dissection for the sake of verification. In future, in addition to technical improvements and accumulation of experience, the planning of well-designed collaborative studies and randomized comparative trials will be needed to achieve further advances in research on SN in prostate cancer.

The primary goal of SN research is to be able to make available to patients the least invasive surgical intervention possible. In future, it would be desirable to realize SNNS with a less invasive method. A representative low-invasive method currently applicable is laparoscopic surgery. Our group has adopted endoscopy-assisted minilaparotomy, in which a small 5cm lower abdominal midline incision is made, through which all surgical tools including the endoscope are inserted and SN biopsy and RPx performed.<sup>[35]</sup> To perform SN biopsy through this small hole, it is useful to obtain detailed information beforehand about the anatomical position of the SN from the above-mentioned SPECT-CT fusion image. For SNNS to be widely applied clinically many research issues remain to be addressed, but various technical problems have already been overcome and have facilitated the adoption of less invasive surgical

methods. Further advances in research are awaited in the near future.

## REFERENCES

- Hricak H, Choyke PL, Eberhardt SC, Leibel SA, Scardino PT. Imaging prostate cancer: A multidisciplinary perspective. *Radiology* 2007;243:29-53.
- Morton DL, Wen DR, Wong JH, Economou JS, Cagle LA, Storm FK, *et al.* Technical details of intraoperative lymphatic mapping for early stage melanoma. *Arc Surg* 1992;27:392-9.
- Mabry H, Giuliano AE. Sentinel node mapping for breast cancer: Progress to date and prospects for the future. *Surg Oncol Clin N Am* 2007;16:55-70.
- Morton DL, Thompson JF, Cochran AJ, Mozzillo N, Elashoff R, Essner R, *et al.* Sentinel-node biopsy or nodal observation in melanoma. *N Engl J Med* 2006;355:1307-17.
- Fukuda M, Egawa M, Imao T, Takashima H, Yokoyama K, Namiki M. Detection of micrometastasis by step section and immunohistochemistry in patients with prostate cancer. *J Urol* 2007;177:1313-7.
- Weckermann D, Dorn R, Trefz M, Wagner T, Wawroschek F, Harzmann R. Sentinel lymph node dissection for prostate cancer: Experience with more than 1,000 patients. *J Urol* 2007;177:916-20.
- Hacker A, Jeschke S, Leeb K, Prammer K, Ziegerhofer J, Sega W, *et al.* Detection of pelvic lymph node metastases in patients with clinically localized prostate cancer: comparison of 18F fluorocholine positron emission tomography-computerized tomography and laparoscopic radioisotope-guided sentinel lymph node dissection. *J Urol* 2006;176:2014-9.
- Clark T, Parekh DJ, Cookson MS, Chang SS, Smith ER Jr, Wells N, *et al.* Randomized prospective evaluation of extended versus limited lymph node dissection in patients with clinically localized prostate cancer. *J Urol* 2003;169:145-7.
- Briganti A, Chun FK, Salonia A, Suardi N, Gallina A, Da Pozzo LF, *et al.* Complications and other surgical outcomes associated with extended pelvic lymphadenectomy in men with localized prostate cancer. *Eur Urol* 2006;52:436-44.
- Partin AW, Mangold LA, Lamm DM, Walsh PC, Epstein JI, Pearson JD. Contemporary update of prostate cancer staging nomogram (Partin Tables) for the new millennium. *Urology* 2001;58:843-8.
- Kattan MW, Potters L, Blasko JC, Beyer DC, Fearn P, Cavanagh W, *et al.* Pretreatment nomogram for predicting freedom from recurrence after permanent prostate brachytherapy in prostate cancer. *Urology* 2001;58:393-9.
- Cagiannos I, Karakiewicz P, Eastham JA, Ohori M, Rabbani F, Gerigk C, *et al.* A preoperative nomogram identifying decreased risk of positive pelvic lymph nodes in patients with prostate cancer. *J Urol* 2003;170:1798-803.
- Heidenreich A, Varga Z, von Knobloch R. Extended pelvic lymphadenectomy in patients undergoing radical prostatectomy: High incidence of lymph node metastasis. *J Urol* 2002;167:1681-6.
- Bader P, Burkhard FC, Markwalder R, Studer UE. Is a limited lymph node dissection an adequate staging procedure for prostate cancer? *J Urol* 2002;168:514-8.
- San Francisco IF, De Wolf WC, Rosen S, Upton M, Olumi AF. Extended prostate needle biopsy improves concordance of Gleason grading between prostate needle biopsy and radical prostatectomy. *J Urol* 2003;169:136-40.
- Bhatta-Dar N, Reuther AM, Zippe C, Klein EA. No difference in six-year biochemical failure rates with or without pelvic lymph-node dissection during radical prostatectomy in low risk patients with localized prostate cancer. *Urology* 2004;63:528-31.

17. Salomon L, Hoznek A, Lefrere-Belda MA, Bellot J, Chopin DK, Abbou CC. Nondissection of pelvic lymph-node does not influence the results of perineal radical prostatectomy in selected patients. *Eur Urol* 2000;37:297-300.
18. Bader P, Burkard FC, Markwalder R, Studer UE. Disease progression and survival of patients with positive lymph nodes after radical prostatectomy: Is there a chance for cure? *J Urol* 2003;169:849-54.
19. Han M, Partin AW, Pound CR, Epstein JI, Walsh PC. Long-term biochemical disease-free and cancer-specific survival following anatomical radical retropubic prostatectomy: the 15 year Johns Hopkins experience. *Urol Clin North Am* 2001;28:555-65.
20. Daneshmand S, Quek ML, Stein JP, Lieskovsky G, Cai J, Pinski J, *et al.* Prognosis of patients with lymph node positive prostate cancer following radical prostatectomy: Long-term results. *J Urol* 2004;172:2252-5.
21. Takashima H, Egawa M, Imao T, Fukuda M, Yokoyama K, Namiki M. Validity of sentinel lymph node concept for patients with prostate cancer. *J Urol* 2004;171:2268-71.
22. Wawroschek F, Vogt H, Weckermann D, Wagner T, Harzmann R. The sentinel lymph node concept in prostate cancer - first results of gamma probe-guided sentinel lymph node. *Eur Urol* 1999;36:595-600.
23. Rudoni M, Sacchetti GM, Leva L, Inglese E, Monesi G, Minocci D, *et al.* Recent applications of the sentinel lymph node concept: Preliminary experience in prostate cancer. *Tumori* 2002;88:S16-7.
24. Brenot-Rossi I, Rossi D, Esterni B, Brunelle S, Chuto G, Bastide C. Radioguided sentinel lymph node dissection in patients with localized prostate carcinoma: Influence of the dose of radiolabelled colloid to avoid failure of the procedure. *Eur J Nucl Med Mol Imaging* 2008;35:32-8.
25. Silvia N Jr, Anselmi CE, Anselmi OE, Madke RR, Hunsche A, Souto JS, *et al.* Use of the gamma probe in sentinel lymph node biopsy in patients with prostate cancer. *Nucl Med Commun* 2005;26:1081-6.
26. Strand SE, Persson BR. Quantitative lymphoscintigraphy I: Basic concepts for optimal uptake of radiocolloids in the parasternal lymph nodes in rabbits. *J Nucl Med* 1979;10:1038-46.
27. Yokoyama K, Tonami N, Tsugawa K, Kinami S, Miwa K. Sentinel node detection with radiocolloids. *Jpn J Clin Radiol* 2001;46:1373-81.
28. Kizu H, Takayama T, Fukuda M, Egawa M, Tsushima H, Yamada M, *et al.* Fusion of SPECT and multidetector CT images for accurate localization of pelvic sentinel lymph nodes in prostate cancer patients. *J Nucl Med Technol* 2005;33:78-82.
29. Krengli M, Ballare A, Cannillo B, Rudoni M, Kocjancic E, Loi G, *et al.* Potential advantage of studying the lymphatic drainage by sentinel node technique and SPECT-CT image fusion for pelvic irradiation of prostate cancer. *Int J Radiat Oncol Biol Phys* 2006;66:1100-4.
30. Warncke SH, Mattei A, Fuechsel FG, Z'Brun S, Krause T, Studer UE. Detection rate and operating time required for gamma probe-guided sentinel lymph node resection after injection of technetium-99m nanocolloid into the prostate with and without preoperative imaging. *Eur Urol* 2007;52:126-32.
31. Jeschke S, Nambirajan T, Leeb K, Ziegerhofer J, Sega W, Janetschek G. Detection of early lymph node metastases in prostate cancer by laparoscopic radioguided sentinel lymph node dissection. *J Urol* 2005;173:1943-6.
32. Corvin S, Schilling D, Eichhorn K, Hundt I, Hennenlotter J, Anastasiadis AG, *et al.* Laparoscopic sentinel lymph node dissection--a novel technique for the staging of prostate cancer. *Eur Urol* 2006;49:280-5.
33. Wawroschek F, Wagner T, Hamm M, Weckermann D, Vogt H, Markl B, *et al.* The influence of serial sections, immunohistochemistry, and extension of pelvic lymph node dissection on the lymph node status in clinically localized prostate cancer. *Eur Urol* 2003;43:132-7.
34. Calaluce R, Miedema BW, Yesus YM. Micrometastasis in colorectal carcinoma: A review. *J Surg Oncol* 1998;67:194-202.
35. Egawa M, Imao T, Fukuda M, Takashima H, Kizu H, Yokoyama K, *et al.* Sentinel node navigation surgery using endoscopic minilaparotomy technique for patients with prostate cancer. *Jpn J Endourol ESWL* 2004;17:231-4.

**How to cite this article:** Egawa M, Fukuda M, Takashima H, Misaki T, Kinuya K, Terahata S. The sentinel node concept in prostate cancer: Present reality and future prospects. *Indian J Urol* 2008;24:451-456.

**Source of Support:** Nil, **Conflict of Interest:** None declared.