

Correlation between capillary oxygen saturation and small intestinal wall thickness in the equine colic patient

Elisabeth Mirle, Anna Wogatzki, Robert Kunzmann, Axel M Schoenfelder, Lutz F Litzke

To cite: Mirle E, Wogatzki A, Kunzmann R, *et al.* Correlation between capillary oxygen saturation and small intestinal wall thickness in the equine colic patient. *Veterinary Record Open* 2017;4:e000197. doi:10.1136/vetreco-2016-000197

Received 25 June 2016
 Revised 15 February 2017
 Accepted 17 February 2017

ABSTRACT

The surgical evaluation of haemorrhagic infarcted intestine and the decision for or against bowel resection require a lot of experience and are subjective. The aim of this prospective, clinical study was to examine the correlation between oxygen saturation and small intestinal wall (IW) thickness, using two objective methods. In 22 colicky horses, the blood flow, oxygen saturation and relative amount of haemoglobin were measured intraoperatively via laser Doppler and white light spectroscopy (O2C, oxygen to see, LEA Medizintechnik) at six measuring points (MPs) in small and large intestines. Furthermore, the IW thickness was measured ultrasonographically. Nine of 22 horses had an increased small IW thickness greater than 4 mm (Freeman 2002, Scharner and others 2002, le Jeune and Whitcomb 2014) at measuring point 1 (MP1) (strangulated segment), four horses had a thickened bowel wall at measuring point 3 (MP3) (poststenotic) and one at measuring point 2 (MP2). The oxygen saturation was 0 at MP1 in six horses, at MP3 in two horses and at MP2 (prestenotic) in one. Oxygen saturation and small IW thickness were independent of each other at MP1 and MP2. At MP3, the two parameters were negatively correlated. In summary, it is not possible to draw conclusions about oxygen saturation based on IW thickness.

INTRODUCTION

Ischaemia is a pathologically reduced perfusion and frequently occurs in small intestine strangulation obstruction. According to the literature (Mair and Smith 2005), the survival rate for such patients is 68.9% and therefore lower than for simple obstructions (90.5%). Different studies have shown that 85% of all ischaemic diseases in the small intestine are caused by strangulation obstruction (Freeman and others 2000) and that the survival rate for such obstruction (75.2%) is lower than that for similar problems in the large intestine (89.9%) (Mair and Smith 2005). Oxygen saturation is a major concern in the development of ischaemic diseases. As the oxygenation of tissues decreases, cells start anaerobic glycolysis, which in turn causes inhibition of adenosinetriphosphate (ATP)

production, followed in the final phase by cell death (Blikslager 2010). Due to the structure of their vessels, the tips of the mucosal villi are highly sensitive to decreasing oxygen saturation and begin to degenerate (Blikslager 2010). These alterations occur before haemorrhagic changes of the intestine are visible and can therefore mislead the surgeon. The old adage of 'if in doubt, cut it out' is obsolete, given the increased risk of adhesions, longer duration of anaesthesia and postoperative ileus, combined with higher costs for resections. Methods for detecting ischaemic injury include a viability score (Freeman and others 2014), Doppler ultrasound, fluorescein fluorescence (Freeman and others 1988) and pulse oximetry (Schmotzer and others 1991). It has been proven (Reichert and others 2014) that spectrophotometry is suitable for the evaluation of microcirculation of the small intestine. The oxygen to see (O2C) works with a combination of laser Doppler spectroscopy and white light spectroscopy. The blood flow is calculated out of the laser-detected movements of the erythrocytes and the oxygen saturation and the relative amount of haemoglobin are determined by the oxygen-dependent change in blood colour (KrugKrug 2007). According to the literature (Reichert and others 2014), oxygen saturation of healthy bowel is 81.04% ($\pm 12.62\%$) in the small intestine and 83.44% ($\pm 11.79\%$) in the large intestine. In the jejunum, the relative amount of haemoglobin is 68.41 a.u. (arbitrary units) (± 10.91 a.u.) and the blood flow is 246.1 a.u. (± 73.43 a.u.), similar to the results for the large intestine (haemoglobin 65.81 ± 9.29 a.u.; blood flow 216.27 ± 67.20 a.u.).

Transcutaneous ultrasound has proven to be very specific and sensitive in diagnosing diseases like strangulation obstruction of the small intestine (Scharner and Bankert 2015). A thickness of the small intestinal wall (IW)



CrossMark

Department for Equine Surgery, Justus-Liebig-Universität Gießen, Gießen, Germany

Correspondence to

Miss Elisabeth Mirle; elisabeth.mirle@vetmed.uni-giessen.de

between 1.8 and 3.75 mm (Reef 1998, Epstein and others 2008, Bithell and others 2010, Scharner and Bankert 2015) is considered to be physiologically normal. The IW consists of four layers: serosa, lamina muscularis, submucosa and mucosa, which are distinguished ultrasonographically by their various echogenicity (Freeman 2003). The serosa and submucosa are hyperechogenic, and the lamina muscularis and mucosa are hypoechogenic (see Fig 1). A wall thickness above 4mm is considered to be pathological (Freeman 2002, Scharner and others 2002, le Jeune and Whitcomb 2014). Gas cavities in the mucosa are associated with a highly damaged IW and a poor prognosis (Freeman and others 2014). A thickened IW can be caused by the formation of oedema, infiltrative and proliferative diseases and enteritis as well as ileus (Sanchez 2010). The authors hypothesised that a decreased oxygen saturation is positively correlated with an increased IW thickness greater than 4mm (Freeman 2002, Scharner and others 2002, le Jeune and Whitcomb 2014) in the strangulated segment of an ileus in the small intestine.

MATERIALS AND METHODS

Study design

Before data collection, study design, parameters and hypothesis were defined and agreed in collaboration with the Working Group for Biomathematics and Data Processing of the Department of Veterinary Medicine at Justus-Liebig University Gießen. The study design was reviewed by the named animal welfare and care officer of the Justus-Liebig-University Gießen. There was no need for ethical approval for this study in accordance with animal law.

Horses

Measurements were taken from 22 horses, which were referred for laparotomy due to colic. Intraoperatively, all

horses were diagnosed with an ileus in the small intestine and a macroscopically altered bowel. Age ranged from 4 to 21 years (mean±SD: 16.2±5.3 years) and body-weight (BW) ranged from 260 to 660 kg (mean±SD: 486.4±98.8 kg). The group consisted of 11 warmbloods and 11 ponies (with a maximum height of 1.48 m); these comprised nine mares, 12 geldings and one stallion.

Anaesthesia

Xylazine^(c) (0.5–1.1 mg/kg BW, intravenous) and butorphanol^(d) (0.05 mg/kg BW, intravenous) were used for premedication and ketamine^(e) (2.2 mg/kg BW, intravenous) and diazepam^(f) (0.1 mg/kg BW, intravenous) were used for induction of general anaesthesia. To maintain anaesthesia, the authors used active ventilation with a mixture of isoflurane^(g) and pure oxygen in addition to an intravenous balanced xylazine infusion (1 mg/kg/hour). Horses were positioned in dorsal recumbency. Perioperatively, horses received Ringer's lactate and, if necessary, dobutamine^(h) for circulatory support and to maintain mean arterial pressure above 70 mm Hg. Blood pressure was controlled invasively in arteria facialis.

O2C probe

The flat probe contains two light sources and two detectors for measuring the scattered light. It works with a white light source in a wavelength range of 500–630 nm and a laser light source at 830 nm. The penetration depth of both is approximately 2.5 mm.

Measurements

Measurements were performed antimesenterically at six defined points immediately after diagnosis, with surgical lights turned off. The most damaged bowel segment macroscopically was defined by the surgeon and determined as the strangulated segment (measuring point 1, MP1), measuring point 2 (MP2) was 50 cm orally from MP1 and measuring point 3 (MP3) was 50 cm aborally from MP1. If the ileus was localised in the ileum, MP3 was excluded and measurements were continued with measuring point 4–measuring point 6 (MP4–MP6) in the large intestine. MP4 was located at the corpus caeci, MP5 at the flexura pelvina and MP6 in the middle of the colon descendens, which could be lifted out of the abdominal cavity. Oxygen saturation, relative blood flow and the relative amount of haemoglobin were determined using a sterile probe of the O2C (see Fig 1) (Fig 3). All measurements were taken within a period of four breaths or ≥30 s. Data were recorded every 50 ms and displayed every 2 s (see Fig 2). The thickness of the IW was determined using a sterile cover for a rectal probe operating at 8.4 MHz using the ultrasound scanner SSA-780A manufactured by Toshiba⁽ⁱ⁾ directly on the bowel. The authors used contact gel as a kind of standoff distance.

Statistics

The design of procedure, as well as analysis and evaluation of data took place under the supervision of the Working Group for Biomathematics and Data Processing of the

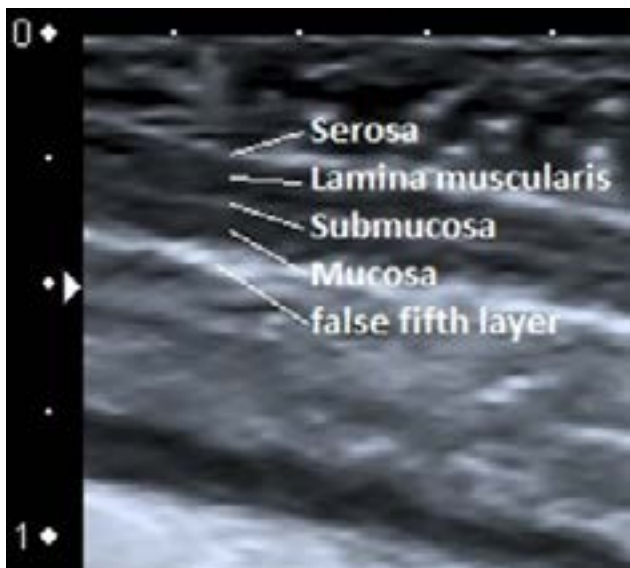

FIG 1: Intestinal wall of the jejunum (measuring point 3 (MP3)) with distinguishable single layers

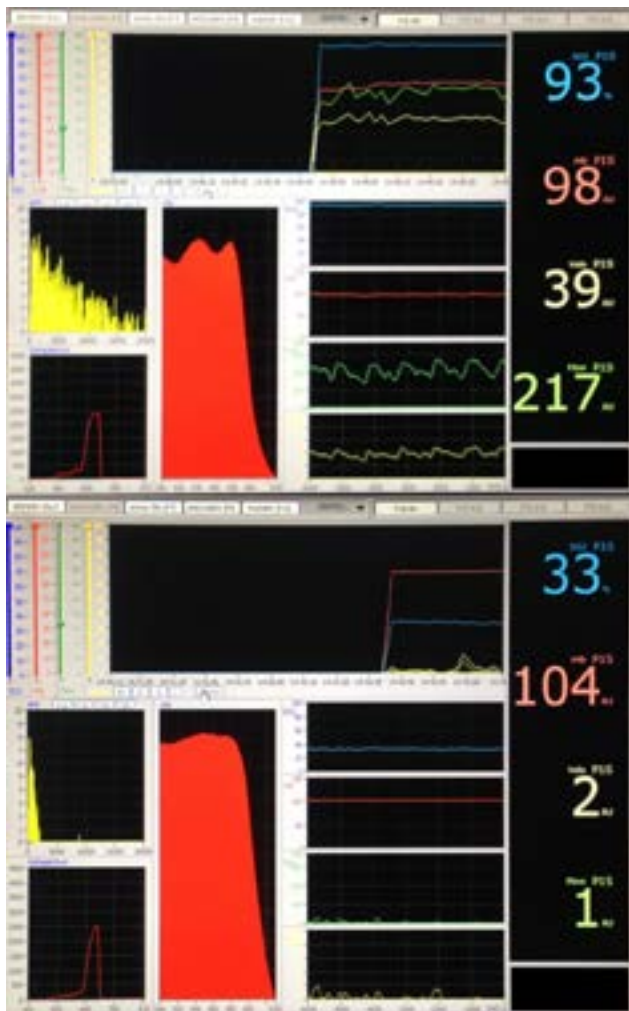


FIG 2: Screen of the oxygen to see (O2C); top: measurement of a macroscopically healthy bowel; below: measurement of a macroscopically injured and discoloured bowel

Department of Veterinary Medicine at the Justus-Liebig University Gießen. The intended sample size was determined using the program 'BiAS^(®)'. The limit for statistical significance was $P \leq 0.05$, with an alpha of 0.05 and a beta of 0.1. For statistical analysis, the median and mean deviation from the median (MD) were determined for every parameter at each MP. The thickness of IW was calculated as the mean (\pm SD) of five measurements in longitudinal and cross-sectional views. The program BMDP^(a) was used for statistical evaluation. The relation between quantitative characteristics was assessed for MP1–MP6 using correlation and regression analysis with the program module 6D/6R^(a) and determination of the partial correlation coefficient (r) and regression line ($y=m \cdot x+b$). The confounding variable 'time since skin incision' was investigated using the partial correlation coefficient (BMDP6R^(a)). A logarithmic transformation of the correlation analysis was performed for the right-skewed distribution of each parameter at MP1–MP3. Therefore, the value 0 was replaced by half of the smallest positive value.

RESULTS

All horses had a macroscopically injured and discoloured small intestine. The colour of the strangulated part ranged from dark pink and red to blue or black (see Fig 3). The bowel was either dilated or the wall was thickened. The prestenotic segment was also dilated; the poststenotic part was mostly empty and macroscopically normal. The average bowel wall thickness at MP1 in all horses was 3.7 mm (± 1.9 mm SD) and the oxygen saturation was 34.5 a.u. (± 67.5 a.u. MD). A thickening of the IW over 4 mm at MP1 was detectable in nine of 22 horses. In these nine horses, the average bowel wall thickness was 5.7 mm (± 1.2 mm), see Fig 4. The parameters of MP1–MP6 are shown in Table 1. Oxygen saturation was 0 in six horses at MP1, two at MP3 and one at MP2. A wall thickness of over 4 mm was found in one horse at MP2 and in four horses at MP3. MP3 was left out in six of 22 horses, due to localisation of ileus in the distal jejunum or ileum. Correlation analysis showed a significant ($P < 0.01$) negative ($r = -0.70$) correlation at MP3 between oxygen saturation and thickening of the IW, see Fig 5. This was also demonstrated in a logarithmic correlation analysis ($P < 0.01$, $r = -0.65$). At MP3, correlation analysis also showed a significant ($P = 0.01$) negative ($r = -0.61$) relationship between blood flow and IW thickness, see Fig 6. No influence of surgical time on parameters was detectable in regression analysis. There was no detectable influence of time on data according to the partial correlation coefficient.

The average duration between first observation of signs of colic, treatment by first veterinarian, transport and referral for laparotomy was 7.1 hours (± 3.5 hours). The mean duration of surgery for all horses was 81 minutes (± 68 minutes). Measurements were finished after skin incision within 35 minutes (± 21 minutes). The full study protocol is available from the lead author.

DISCUSSION

To the authors' knowledge, the present study is the first non-terminal examination of the acute diseased equine gastrointestinal tract using spectrophotometry. According to the manufacturer (T. Derfuß 2015, LEA Medizintechnik, Gießen, oral communication), the most precise measurements with the O2C probe are possible up to a depth of 2.5 mm. Using the duodenum as an example of the small intestine, one study (Kirberger and others 1995) found that the thickness of the individual intestinal layers did not exceed 1 mm in healthy horses. Therefore, it can be concluded that every single layer, including the mucosa, in a normal, not strangulated and thickened bowel can be evaluated using the 2.5 mm probe. Another study (Freeman 2002) showed that oedema mostly occurs in the submucosa and mucosa. Therefore, a complete assessment of the mucosa with the 2.5 mm probe is only partially possible, if the IW has thickened. However, an evaluation of the deep submucosal plexus is possible. On the basis of anatomical connections between the deep and superficial submucosal plexus (Ullrich 1984), it

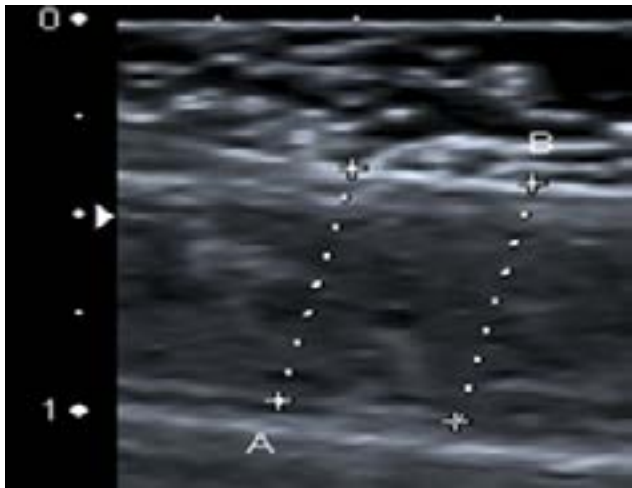


FIG 4: Thickened intestinal wall at measuring point 1 (MP1), 6.8mm

can be concluded that the tissue perfusion in the area surrounding the superficial submucosal plexus and the villi tips is similar to the perfusion in the deep submucosal plexus. The authors consider the interference between the laser and peristalsis and the involuntary movements of the surgeon to be a methodological flaw. Based on authors' own experiences, respiration by the horse has a disruptive influence due to draping of the intestine on the abdominal wall, which moves vertically due to breathing. The operating manual for the O2C points out that movement interferes with laser function. Draping the intestine can cause constriction of the lumen of the vessels, which again can cause decreased flow and venous drainage. This new method (O2C) should be tested in correlation with an ultrasonographic measurement of the small IW in equines. Thickening of the IW

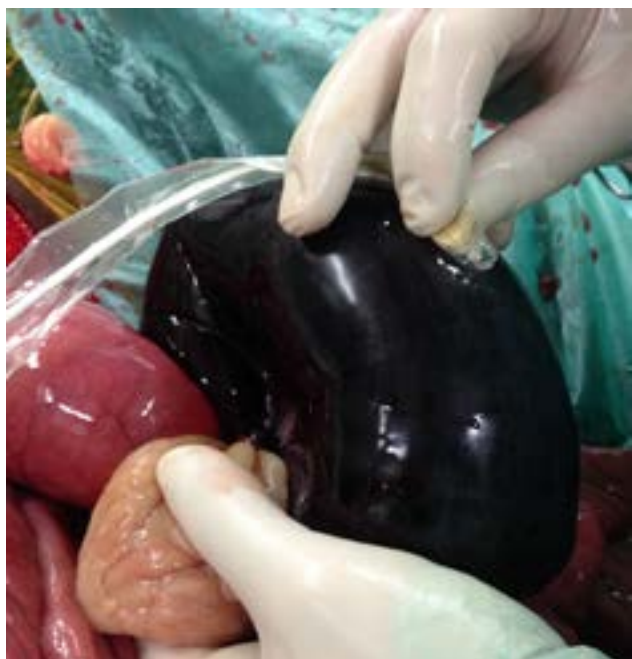

FIG 3: Oxygen to see (O2C) measurements at measuring point 1 (MP1)

due to strangulation obstruction is a common sign in colicky horses. Therefore, ultrasonography of the bowel wall is widely used in the postoperative phase to check for signs of postoperative ileus. As mentioned earlier, direct measurement has the advantage of differentiating between all single layers (see Fig 1). Particular caution is recommended so that the handler of the sonic head does not compress the oedema due to pressure and the tool's own weight.

Despite the above-mentioned difficulties, the results of the two methods were as follows: the oxygen saturation at MP1 was 40.5% ($\pm 25.9\%$ MD) and therefore clearly lower than the previously reported value (Reichert and others 2014) of 81.04% ($\pm 12.62\%$ SD) in healthy horses. This considerably lower level of oxygen saturation in the small intestine can be traced back to the strangulation obstruction and therefore the resulting extravasation of vessels. On the one hand, the high variability in saturation should be discussed in combination with the diagnosis (strangulating lipoma vs obstipation of the ileum); on the other hand, the type of ischaemia (venous vs arteriovenous) should be considered. Venous ischaemia is characterised by collapse of the veins with continuous bleeding in the IW and persisting reduced oxygen supply. Given their thinner walls and lower hydrostatic pressure, the veins collapse first (Blikslager 2003). Strangulation obstruction, which generates enough pressure on vessels to restrict veins and arteries, leads to rapid degeneration of the tissue due to the lack of oxygen supply (Blikslager 2003). Both strangulation obstruction and distension due to intestinal blow up can cause decreased blood flow, followed by lower oxygenation and therefore ischaemic injury in equine intestine (Dabareiner and others 1993, Dabareiner and others 2001). In the large intestine, the oxygen saturation was 90% ($\pm 17.7\%$ MD) and was just above the previously reported value (Blikslager 2003) of 83.44% ($\pm 11.79\%$ SD).

In addition to the oxygen saturation, the O2C is able to measure the microcirculatory blood flow and the relative amount of haemoglobin. The decrease in relative blood flow at MP1 (34.5 a.u. (± 67.5 a.u. MD)) can be attributed to the obstruction of the vessels (Blikslager 2010) and the intraluminal pressure (Dabareiner and others 1993, Dabareiner and others 2001). The high variance is also traceable to various causes of ischaemia mentioned above. The parameter FLOW at MP2–MP6 was unremarkable according to the literature (Reichert and others 2014). Values ranged from 205.5 to 294 a.u., whereas in healthy horses it ranged from 216 to 246 a.u. These results are considered as normal, depending on the individual blood supply of every bowel segment (Ullrich and Pferd 1984) (Ullrich 1984). One study (Dancker and others 2015) showed that intraoperative administration of dobutamine led to a significant increase in blood flow depending on dosage. It should be taken into consideration that dobutamine is used to stabilise the circulation by impact and can influence the data.

TABLE 1: Median or mean of all parameters at each measuring point (MP) (n=22)

MP	Median FLOW (\pm MD)*	Median SO ₂ (\pm MD)*	Median rHb (\pm MD)*	Mean IW (\pm sd)*
MP1 (strangulated segment)	34.5 \pm 67.5	40.5 \pm 25.9	103.5 \pm 25.2	3.7 \pm 1.9
MP2 (prestenotic; 50 cm orally MP1)	248 \pm 102.2	85 \pm 20.4	99 \pm 11.4	1.9 \pm 0.8
MP3 (poststenotic; 50 cm aborally MP1) n=16	205.5 \pm 63.1 [†]	74.5 \pm 21.9 [†]	86.5 \pm 14.3	3.1 \pm 1.9
MP4 (corpus caeci)	294 \pm 86.4	86 \pm 10.7	97 \pm 11.4	1.5 \pm 0.4
MP5 (pelvic flexure)	233 \pm 79.7	90 \pm 17.7	79 \pm 10.9	1.6 \pm 0.5
MP6 (colon descendens)	230 \pm 67.2	88 \pm 15.7	82 \pm 11.8	1.6 \pm 0.4

FLOW, blood flow (a.u.); IW = intestinal wall thickness (mm); MD, mean deviation from the median; MP1, measuring point 1; MP2, measuring point 2; MP3, measuring point 3; MP4, measuring point 4; MP5, measuring point 5; MP6, measuring point 6; rHb, relative amount of haemoglobin (a.u.); SO₂ = oxygen saturation (%).

*Data are rounded to the first figure after the decimal.

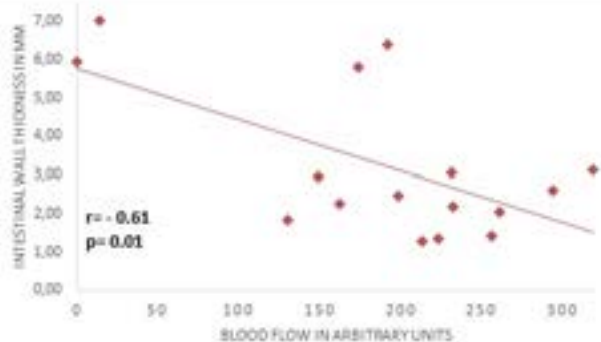
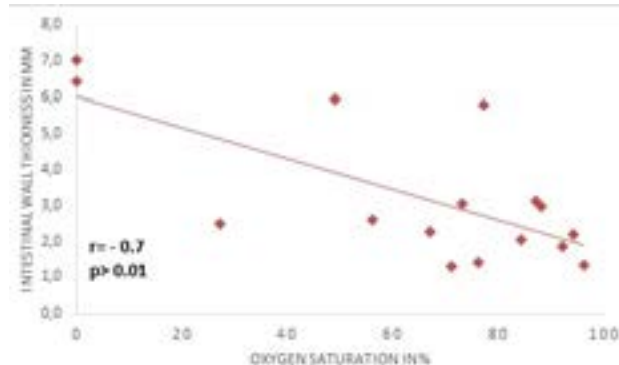
[†]Significantly correlated to increasing intestinal wall thickness.

The relative amount of haemoglobin was clearly higher at each MP than in healthy horses (Reichert and others 2014). At MP1 and MP2, this is a sign of venous stasis due to ileus. Another explanation for increased levels could be the inflammation arising as a result of surgical manipulation. The high level at MP4 could be due to distension and therefore gas drain. It should be noted that measurements at MP1–MP3 were usually performed immediately after diagnosis. MP4–MP6 were measured after draining gas and ingesta from the small intestine in the aboral direction by manual manipulation and in two horses after performing an enterotomy. It is possible that the vessels were slightly compressed due to the draping of the intestine for enterotomy, which would have resulted in a decreased venous drainage.

It is noteworthy that each horse had a macroscopically injured bowel with bleeding into the wall and always a change in the parameters mentioned above. In contrast, only just half of them had a pathological thickening of the IW at MP1. In patients with no thickening of the wall, vessels were occluded by pressure, the so-called arterio-venous ischaemia (Blikslager 2003). In another study, 22.2% of colicky horses with small intestinal strangulation obstruction showed a thickened wall (Beccati and others 2011) in transcutaneous ultrasound. This shows that an evaluation of the thickening of the bowel wall only is not sufficient to draw conclusions regarding its

viability. Thickened IWs are considered a consequence of venous ischaemia and therefore stasis of blood and lymph in the different layers of the IW. Thicknesses of between 2.0 and 7.1 mm (Freeman 2002, Porzuczek and others 2012) have been measured transcutaneously in horses with acute colic. At MP1, the thickest measurement was 7 mm. If oedema occurs because of strangulation obstruction, examples from the literature (Freeman 2002) and authors' own measurements indicate that it is mostly the mucosa and submucosa that become thickened. This development of oedema and massive tissue degeneration is caused by extravasation (see Fig 7). Three of four horses with a bowel wall thickness greater than 4 mm at MP3 had an ileus due to a lipoma pendulans and a considerably decreased oxygen saturation of 0–49%. An explanation for this could be the gravity and duration of the disease. Additionally, the manipulation and stretching by the surgeon during surgery could play a role. In the large intestine, the bowel walls did not exceed 1.6 mm (\pm 0.5 mm MD). Therefore, it can be concluded that an ileus in the small intestine has no ultrasonographically detectable influence on large IW thickness.

Statistical analysis showed a significant correlation between lowered oxygen saturation and thickened IW at MP3 ($P < 0.01$; $r = -0.70$), as well as a correlation between decreasing blood flow and increasing IW


FIG 6: Correlation between blood flow and intestinal wall thickness at measuring point 3 (MP3) ($r = -0.61$; $P = 0.01$)

FIG 5: Correlation between oxygen saturation and thickening of the intestinal wall at measuring point 3 (MP3) ($r = -0.70$; $P = 0.001$)

thickness ($P=0.01$; $r=-0.61$). These two findings support the authors' hypothesis that IW thickening is correlated with decreasing oxygen saturation. In strangulated segments, the authors did not determine whether vessels were occluded using Doppler ultrasound. This could explain why the authors did not find a significant correlation as they did at MP3. In conclusion, the authors would add venous ischaemia as a condition for their hypothesis. The MP3 bowel segment in the present study provides ideal conditions, because of its injuries by surgical manipulation and remaining venous drainage. A limitation of this study is the number of cases (Freeman 2003) containing MP3.

In summary, the authors found that IW thickening and decreasing capillary oxygen saturation are correlated with each other if the arterial vessels were not occluded. The authors recommend measuring capillary oxygen saturation in strangulated small intestine, because this could help surgeons, especially younger and inexperienced ones, to make the right decision regarding resection. To evaluate a strangulated bowel segment, the O2C should be combined with an examination of vascular integrity using, for example, Doppler ultrasound. The O2C proved to be a sensitive examination opportunity. It is easy to integrate in normal surgical procedures and allows an objective evaluation of the bowel in terms of its injury. There was no notable benefit of measuring IW thickening ultrasonographically. The authors got the impression that surgeons can also assess it very well by palpation. Further research, for example, regarding histological changes under decreasing capillary oxygen saturation or experimental set-ups with artificially induced ischaemia may also explain whether oxygenation has a direct influence on outcome in colicky horses.

MANUFACTURERS' DETAILS

- a. Dixon, W.J. (1993) BMDP Statistical Software Manual, Volume 1 and 2, University of California Press, Berkeley, Los Angeles, London.

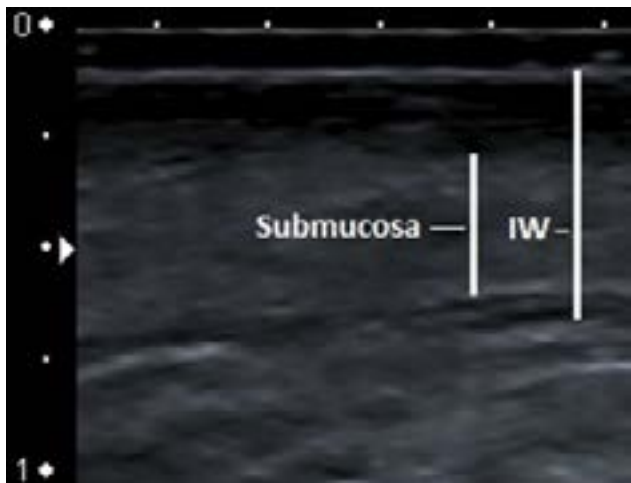


FIG 7: Marked intestinal wall (IW), 5.5 mm and marked submucosa (3 mm)

- b. O2C (oxygen to see), LEA Medizintechnik, Gießen, Germany.
- c. Xylavet, CP-Pharma Handelsgesellschaft mbH, Burgdorf, Germany.
- d. Butorgesic, CP-Pharma Handelsgesellschaft mbH, Burgdorf, Germany.
- e. Ketamin, CP-Pharma Handelsgesellschaft mbH, Burgdorf, Germany.
- f. Diazepam -Lipuro, B. Barun Melsungen AG, Melsungen, Germany.
- g. Isofluran CP, CP-Pharma Handelsgesellschaft mbH, Burgdorf, Germany.
- h. Dobutaminratiopharm (250 mg), Trockensubstanz, Ratiopharm GmbH, Ulm, Germany.
- i. Ultrasound scanner SSA- 780A, Toshiba, Tokyo, Japan.
- j. Ackermann (2010): 'BiAS. für Windows, Biometrische Analyse von Stichproben', Version 9.08. Epsilon-Verlag, Hochheim, Darmstadt.

Acknowledgements The authors are grateful to colleagues at the Department of Equine Surgery for their assistance, especially the surgeons C. Pilz and Dr M. Al Naem.

Contributors This study is a part of the doctoral thesis of EM. EM and RK were responsible for taking and analysing data. AW and LFL are supervisors for the doctoral thesis and were responsible for study design. AMS was the surgeon in charge.

Competing interests None declared.

Provenance and peer review Not commissioned; externally peer reviewed.

Data sharing statement All Data can be requested from the corresponding author.

Open Access This is an Open Access article distributed in accordance with the Creative Commons Attribution Non Commercial (CC BY-NC 4.0) license, which permits others to distribute, remix, adapt, build upon this work non-commercially, and license their derivative works on different terms, provided the original work is properly cited and the use is non-commercial. See: <http://creativecommons.org/licenses/by-nc/4.0/>

© British Veterinary Association (unless otherwise stated in the text of the article) 2017. All rights reserved. No commercial use is permitted unless otherwise expressly granted.

REFERENCES

- Blikslager AT. (2003) Treatment of gastrointestinal ischemic injury. *Vet Clin North Am Equine Pract* 19:715–27
- Krug. (2007) O2C (oxygen to see) Eine kurze Übersicht der Methodik, LEA Medizintechnik GmbH Gießen, 1–4
- Beccati F, Pepe M, Gialletti R, et al (2011) Is there a statistical correlation between ultrasonographic findings and definitive diagnosis in horses with acute abdominal pain? *Equine Veterinary Journal* 43:98–105
- Bithell S, Habershon-Butcher JL, Bowen IM, et al (2010) Repeatability and reproducibility of transabdominal ultrasonographic intestinal wall thickness measurements in thoroughbred horses. *Vet Radiol Ultrasound* 51:647–51
- Blikslager AT. (2010) Pathophysiology of mucosal injury and repair. In: Reed SM, Bayly WM, Sellon DC, *Equine internal medicine*. 3rd edn: Saunders, 794–802
- Dabareiner RM, Sullins KE, Snyder JR. (1993) Evaluation of the microcirculation of the equine small intestine after intraluminal distension and subsequent decompression. *Ajvr* 54:1673–92
- Dabareiner RM, White NA, Donaldson LL. (2001) Effects of intraluminal distension and decompression on microvascular permeability and hemodynamics of the equine jejunum. *Ajvr* 62:225–36
- Dancker C, Hopster K, Rohn K. (2015) Einfluss verschiedener Katecholamine auf die Mikroperfusion und Oxygenierung des



- Gastrointestinaltrakt beim Pferd in Allgemeinanästhesie. *Oral presentation at DVG kongress*. Berlin, Germany
- Epstein K, Short D, Parente E, et al (2008) Gastrointestinal ultrasonography in normal adult ponies. *Vet Radiol Ultrasound* 49:282–6
- Freeman DE, Gentile DG, Richardson DW, et al (1988) Comparison of clinical judgment, doppler ultrasound, and fluorescein fluorescence as methods for predicting intestinal viability in the pony. *Am J Vet Res* 49:895–900
- Freeman DE, Hammock P, Baker GJ, et al (2000) Short- and long-term survival and prevalence of postoperative ileus after small intestinal surgery in the horse. *Equine Vet J* 32:42–51
- Freeman S. (2002) Ultrasonography of the equine abdomen: findings in the colic patient. *In Practice* 24, 262–273
- Freeman S. L. (2003) Diagnostic ultrasonography of the mature equine abdomen. *Equine Veterinary Education* 15, 319–330
- Freeman D. E., Schaeffer D. J., Cleary O. B. (2014) Long-term survival in horses with strangulating obstruction of the small intestine managed without resection. *Equine Vet J* 46, 711–717
- Kirberger RM, Berg JSvanden, Gottschalk RD, et al (1995) Duodenal ultrasonography in the normal adult horse. *Veterinary Radiology & Ultrasound* 36:50–6
- Mair TS, Smith LJ. (2005) Survival and complication rates in 300 horses undergoing surgical treatment of colic. part 1: short-term survival following a single laparotomy. *Equine Vet J* 37:296–302
- Porzuczek A, Kielbowicz Z, Haines G. (2012) The use of percutaneous abdominal ultrasound examination in diagnosing equine small intestinal disorders. *Pol J Vet Sci* 15:759–66
- Reef V. B. (1998) Adult abdominal ultrasonography. In: *Equine Diagnostic Ultrasound*. W.B. Saunders, Philadelphia. Reef. V. B. 273–364
- Reichert C, Kästner SB, Hopster K, et al (2014) Use of micro-lightguide spectrophotometry for evaluation of microcirculation in the small and large intestines of horses without gastrointestinal disease. *Am J Vet Res* 75:990–6
- Sanchez LC. (2010) Examination for disorders of the gastrointestinal tract. In: Reed SM, Bayly WM, Sellon DC, *equine internal medicine*. 3rd edn: Saunders, 782
- Scharner D, Rötting A, Gerlach K, et al (2002) Ultrasonography of the abdomen in the horse with colic. *Clinical Techniques in Equine Practice* 1:118–24
- Scharner D, Bankert J. (2015) Rektale Untersuchung versus sonographische Untersuchung beim Kolikpferd. *Oral presentation at equitana tagung*. Essen, Germany
- Schmotzer W. B., Riebold T. W., Rowe K. E., Scott E. A. (1991) Steady-state response characteristics of a pulse oximeter on equine intestine. *American Journal of Veterinary Research* 52, 619–625
- Ullrich G. (Das Blutgefäß-System des Dünndarmes vom Pferd 1984) . *Korrosionsanatomische, histologische und elektronenmikroskopische Untersuchungen*. Justus Liebig Universität Gießen, Germany.
- le Jeune S., Whitcomb M. B. (2014) Ultrasound of the equine acute abdomen. *Veterinary Clinics of North America: Equine Practice* 30, 353–381