

## Radiographic diagnosis and endovascular treatment of an unruptured superior hypophyseal aneurysm

Wilfredo de Jesus Rojas, BS; Julio N. Sepulveda Acosta, DVM, MD; Eduardo J. Labat, MD; Alejandro Hidalgo, MD, DABR; and Caleb E. Feliciano, MD

A 37-year-old female with a large unruptured superior hypophyseal aneurysm underwent a Guglielmi detachable-coil embolization after proper diagnostic three-dimensional digital subtraction angiography (DSA) of the internal carotid artery. Only a few case reports exist in the scientific literature about this uncommon entity that accounts for 1% of all intracranial aneurysms. We discuss the etiology, prevalence, and incidence of saccular intracranial aneurysms as well as their risk factors, prognosis, and differential diagnosis. We also review the literature on intracranial aneurysm and evaluate its current diagnostic management and therapeutic treatment.

### Case report

A 37-year-old female with a 1.5-month history of headaches was transferred to our institution after suspicious arterial dilation was found during a contrast-enhanced head CT performed at a peripheral hospital. At evaluation, pertinent details of patient history included chronic, intermittent, left-sided headache associated with ipsilateral neck stiffness; palpitations; and sweating. The patient described her headache as 10 out of 10 in intensity in each episode. She denied loss of consciousness, vomiting, seizures, nausea, or visual problems. Comorbidities were remarkable for medically well-controlled high blood pressure. The family history was remarkable for high blood pressure, diabetes mellitus type 2, and chronic heart failure. There was no family history of aneurysm, subarachnoid hemorrhages, connective tissue disorders, or kidney disease. The patient

denied past or present toxic habits, hospitalizations, allergies, or trauma. Physical examination was unremarkable, without focal neurological deficits or nuchal rigidity.

At our institution, a head CT with intravenous contrast using sequential 7-mm axial slices was performed from the skull base to the skull apex. It demonstrated a saccular dilatation of the left internal carotid artery (ICA) just before the origin of the left middle cerebral artery, measuring approximately 11 mm AP x 9.4 mm transverse x 10 mm cranio-caudal (Fig. 1). In view of the previous findings, 4-vessel DSA, with additional 3D reconstructions of the left ICA, was performed.

DSA demonstrated a left superior hypophyseal aneurysm projecting medially with normal cervical, petrous, and cavernous portions of the ICA (Fig. 2). The aneurysm contour was smooth without gross irregularities and measured 11.6 mm, length 10.3 mm, neck 4.5 mm at proximal and distal ICA 4.0 and 3.8 mm, respectively. The ophthalmic artery showed proximal separate origin from the neck of the aneurysm. On the right side, normal arterial anatomy with good filling of the tributaries was found. These findings established a diagnosis of an unruptured left superior hypophyseal aneurysm. Fig. 3 shows a 3D reconstruction of the left ICA, revealing the aneurysm.

Using the Seldinger technique, we performed a one-vessel cerebral DSA, with superselective catheterization of the left superior hypophyseal aneurysm. Embolization was performed with microvention and Guglielmi Detachable Coils (GDC). After angiographic confirmation of the guide catheter position, a microcatheter was inserted into the aneurysm. The aneurysmogram showed that the aneurysm

---

**Citation:** de Jesus Rojas W, Acosta JNS, Labat EJ, Hidalgo A, Feliciano C. Radiographic diagnosis and endovascular treatment of an unruptured superior hypophyseal aneurysm. *Radiology Case Reports*. (Online) 2012;7:620.

**Copyright:** © 2012 The Authors. This is an open-access article distributed under the terms of the Creative Commons Attribution-NonCommercial-NoDerivs 2.5 License, which permits reproduction and distribution, provided the original work is properly cited. Commercial use and derivative works are not permitted.

Mr. de Jesús Rojas, along with Drs. Acosta, Labat, and Hidalgo (Department of Radiological Sciences and Diagnostic Radiology), and Dr. Feliciano (Department of Surgery, Neuroendovascular Surgery Program), are all at the University of Puerto Rico Medical Sciences Campus, San Juan, Puerto Rico. Contact Mr. de Jesús Rojas at [wilfredo.dejesus3@upr.edu](mailto:wilfredo.dejesus3@upr.edu).

**Competing Interests:** The authors have declared that no competing interests exist.

DOI: 10.2484/rcr.v7i2.620

## Radiographic diagnosis and endovascular treatment of an unruptured superior hypophyseal aneurysm

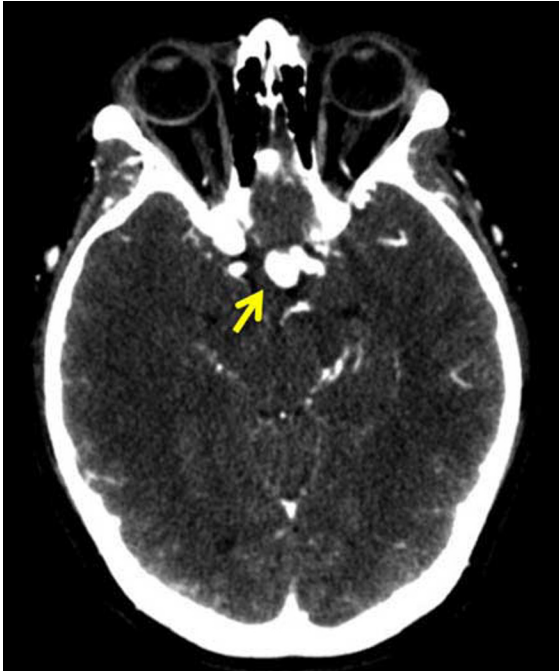

Figure 1. 37-year-old female with an unruptured superior hypophyseal aneurysm. Contrast-enhanced CT showing axial images of the head. A hyperdense region is visualized at the level of the suprasellar cistern (yellow arrow) consistent with an intracerebral aneurysm.

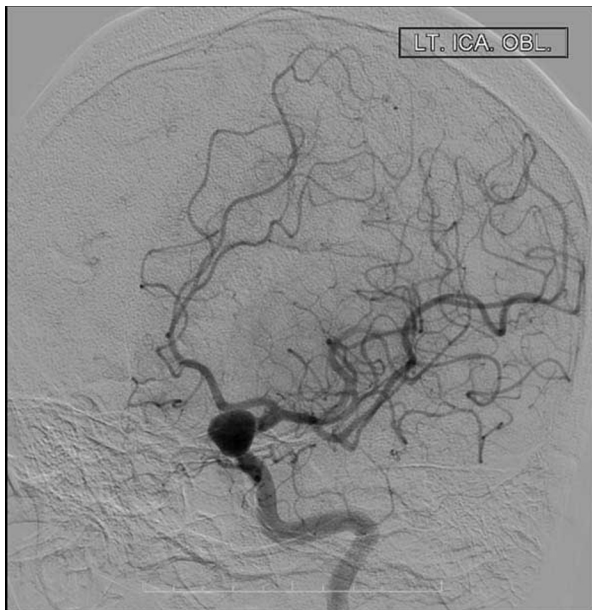

Figure 2. 37-year-old female with an unruptured superior hypophyseal aneurysm. One-vessel cerebral DSA. Left superior hypophyseal aneurysm projecting medially with normal cervical, petrous, cavernous portion of the internal carotid artery.

measured approximately 12x11x12mm; the largest neck diameter was 6mm. This was followed by placement of multiple GDC coils, until complete obliteration of the an-

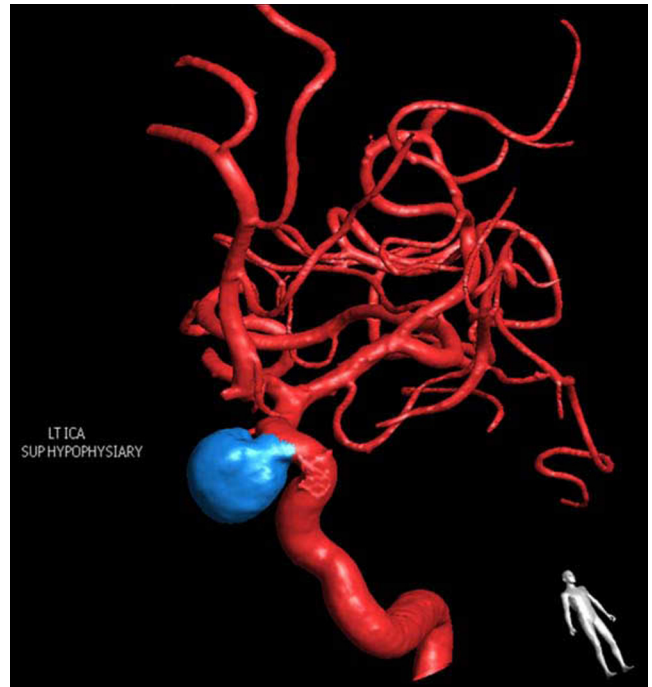

Figure 3. 37-year-old female with an unruptured superior hypophyseal aneurysm. DSA with 3D rotational reconstruction of the left ICA. The blue sacular projection corresponds to a left superior hypophyseal aneurysm.

eurysm was achieved. The patient tolerated the procedure well. A postaneurysm embolization, one-vessel cerebral DSA showed a left superior hypophyseal aneurysm with adequate coil packing and minimal residual neck (Fig. 4B). The patient was placed on clopidogrel and aspirin for anti-coagulation.

### Discussion

Intracranial aneurysms are reasonably common in the general population, and the incidence increases with age (1). Around 1% to 2% of the total population has aneurysms, the majority undetected during life. Individuals older than 30 have a 3.6% to 6% risk of having an unruptured aneurysm (2). Aneurysms are a congenital absence or progressive debilitation of the elastic lamina and tunica media components. Several risk factors promote the potential development of an aneurysm such as alcohol consumption, smoking, high blood pressure, cocaine or amphetamine use, high plasma cholesterol level, use of oral contraception, and the female gender as well as other genetic conditions (3).

An aneurysm may remain asymptomatic or may present with acute-onset, intense headache, suggesting a subarach-

## Radiographic diagnosis and endovascular treatment of an unruptured superior hypophyseal aneurysm

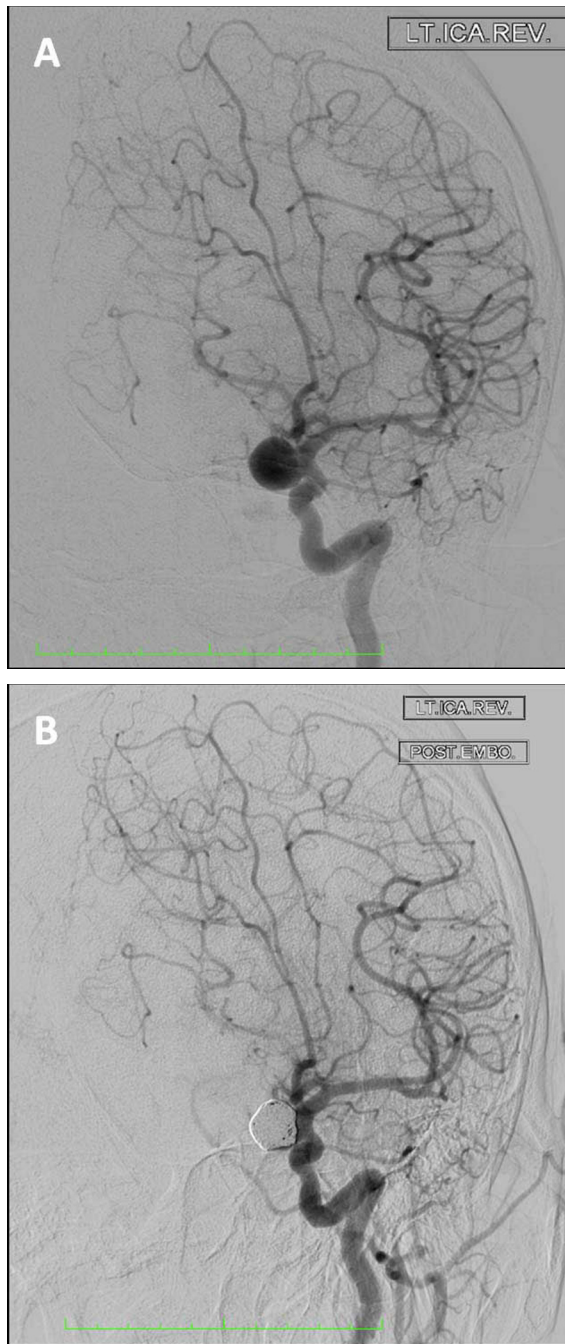


Figure 4. 37-year-old female with an unruptured superior hypophyseal aneurysm. One-vessel cerebral DSA. A. Left superior hypophyseal aneurysm projecting medially with normal cervical, petrous, cavernous portion of the ICA. B. Postprocedure angiogram: Left superior hypophyseal aneurysm with adequate coil packing and minimal residual neck.

noid hemorrhage. The most common locations include the anterior communicating artery (33%), middle cerebral artery (30%), posterior communicating artery (25%), and basilar artery (10%) (4). The least common places are the

ophthalmic artery, posterior inferior cerebellar artery, and the cavernous ICA and its branches.

According to the American College of Radiology Appropriateness Criteria, the initial evaluation for a new-onset headache (considered the worst headache on one's life) includes a noncontrast-enhanced head CT for the evaluation of acute subarachnoid hemorrhage (SAH), intracranial hemorrhage, and mass effect (among others). Evaluation also includes a CTA or MRA, depending on local preference and availability, and when intracranial pathology such as an aneurysm is suspected (5). DSA is considered the gold standard to confirm and provide additional information for the diagnosis and evaluation of an intracranial aneurysm. Selective cerebral arterial injections and multiple projections with the use of a 3D-DSA visualization technique provide outstanding visualization of intravascular lesions. Even though the sensitivity of 3D-DSA is greater than 90% for aneurysms measuring 3mm or greater, it is still an invasive and costly procedure with no optimal use in screening tests (6). In contrast, CTA and MRA are noninvasive modalities that could be used accurately to detect cerebral aneurysms in high-risk groups. When evaluating a contrast-enhanced head CT for aneurysms, findings may show a round, lobulated arterial outpouching usually arising from bifurcations of the circle of Willis, supraclinoid ICA, MCA, or cerebellar arteries, as seen in Fig. 1. If a ruptured aneurysm is suspected, noncontrast-enhanced head CT may demonstrate an effaced Sylvian fissure plus intraparenchymal or subarachnoid hemorrhages adjacent to the site of the aneurysm (not seen in our patient) (7). Aneurysm CT visualization may sometimes show mural calcium depositions. It is known that the sensitivity of multislice CTA is greater than 95% for subarachnoid hemorrhage above 2 mm in diameter (4, 8). In our patient, the CTA detected an aneurysm with the following dimension: 1.1cm AP x 9.4mm transverse x 10mm cranio-caudal.

Taking into consideration the vascular differential diagnosis of an unruptured intracranial saccular aneurysm, we can include vessel loop and vessel infundibulum. A vessel loop sometimes appears visually similar to a true aneurysm, but evaluation of multiple projections provides appropriate visual information that will exclude a true aneurysm. A vessel infundibulum is a conical vessel takeoff with a diameter of less than 3mm, with an artery arising from its apex: most commonly, the posterior communicating artery or anterior choroidal artery.

Our case report presents a patient with a superior hypophyseal saccular aneurysm. The superior hypophyseal aneurysm is an uncommon entity, accounting for 1% of all intracranial aneurysms (9). Superior hypophyseal aneurysms develop at the supraclinoid segment where the perforating vessels that supply the hypophysis and optic chiasm consistently arise from the ICA. Arising medially or inferomedially between the ophthalmic artery and the posterior communicating artery, aneurysms of this location are prone to bleeding at a smaller caliber when compared with other aneurysms with the same diameter. Patients with su-

## Radiographic diagnosis and endovascular treatment of an unruptured superior hypophyseal aneurysm

perior hypophyseal aneurysm are vulnerable to additional intracranial aneurysms. Usually, this type of aneurysm grows medially, with extension to the optic chiasm simulating a suprasellar mass (9).

Management of the vascular lesion depends on its location and size. Treatment options include surgical clippings, endovascular coil embolization, and combinations thereof (10, 11). Taking into consideration the present and past medical history of our patient, interventional endovascular coiling was recommended. The literature establishes that endovascular coiling is associated with significant less mortality and morbidity when compared with neurosurgical clipping in patients who have unruptured intracranial aneurysm (12). A decrease in use of hospital resources and length of hospital stay was observed when compared with neurosurgical clipping. Furthermore, endovascular coiling promotes the one-year survival rate, in contrast with neurosurgical clipping (13).

### References

1. Perry, P. *Saccular aneurysm*. Amirsys, Inc. 2005-2010.
2. White, PM, Wardlaw, JM. Unruptured intracranial aneurysms. *J. Neuroradiol* 2003; 30:336. [\[PubMed\]](#)
3. Wermer, MJ, van der Schaaf, IC, Algra, A, Rinkel, GJ. Risk of rupture of unruptured intracranial aneurysms in relation to patient and aneurysm characteristics: an updated meta-analysis. *Stroke* 2007; 38:1404. [\[PubMed\]](#)
4. Brant, WE, Helms, CA. *Fundamentals of diagnostic radiology*; Lippincott, Williams & Wilkins, 2007.
5. *Headache*. American College of Radiology. ACR Appropriateness Criteria®:2001.
6. Sakamoto, S, Kiura, Y, Shibukawa, M, et al. Subtracted 3D CT angiography for evaluation of internal carotid artery aneurysms: comparison with conventional digital subtraction angiography. *AJNR Am J Neuroradiol* 2006; 27:1332. [\[PubMed\]](#)
7. Perry, P. *Aneurysmal subarachnoid hemorrhage*. Amirsys, Inc. 2005-2010.
8. Kelliny, M, Maeder, P, Binaghi, S, et al. Cerebral aneurysm exclusion by CT angiography based on subarachnoid hemorrhage pattern: a retrospective study. *BMC Neurol* 2011; 11:8. [\[PubMed\]](#)
9. Morris, P. *Practical neuroangiography*, Lippincott Williams & Wilkins, 2007.
10. Roy, D, Raymond, J, Bouthillier, A, et al. Endovascular treatment of ophthalmic segment aneurysms with Guglielmi detachable coils. *AJNR Am J Neuroradiol* 1997; 18:1207. [\[PubMed\]](#)
11. Barami, K, Hernandez, VS, Diaz, FG, Guthikonda, M. Paraclinoid carotid aneurysms: surgical management, complications, and outcome Based on a new classification scheme. *Skull Base* 2003; 13:31. [\[PubMed\]](#)
12. Molyneux, AJ, Kerr, RS, Yu, LM, et al. International subarachnoid aneurysm trial (ISAT) of neurosurgical clipping versus endovascular coiling in 2143 patients with ruptured intracranial aneurysms: a randomised comparison of effects on survival, dependency, seizures, rebleeding, subgroups, and aneurysm occlusion. *Lancet* 2005; 366:809. [\[PubMed\]](#)
13. Higashida, RT, Lahue, BJ, Torbey, MT, et al. Treatment of unruptured intracranial aneurysms: a nationwide assessment of effectiveness. *AJNR Am J Neuroradiol* 2007; 28:146. [\[PubMed\]](#)