

O0037

White matter changes following electroconvulsive therapy for depression: a mega-analysis

J.-B. Belge^{1*}, P. Mulders², L. Van Diermen¹, A. Dols³, M. Oudega³, I. Tendolkar² and P. Van Eijndhoven²

¹University of Antwerp, Collaborative Antwerp Psychiatric Research Institute (capri), Duffel, Belgium; ²Radboud University Medical Center, Donders Institute For Brain, Cognition And Behavior, Centre For Neuroscience, Nijmegen, Netherlands and ³Amsterdam University Medical Center, Amsterdam Neuroscience, Amsterdam, Netherlands
*Corresponding author.

doi: 10.1192/j.eurpsy.2022.237

Introduction: Electroconvulsive therapy (ECT) is proposed to exert an effect on white matter (WM) microstructure, but the limited power of previous studies made it difficult to highlight consistent patterns of change in diffusion metrics.

Objectives: We initiated a multi-site mega-analysis and sought to address whether changes in WM microstructure occur following ECT.

Methods: To this end, diffusion tensor imaging (DTI) data (n=58) from 4 different sites were harmonized before pooling them by using ComBat, a batch-effect correction tool that removes inter-site technical variability, preserves inter-site biological variability and maximizes statistical power. Downstream statistical analyses aimed to quantify changes in Fractional anisotropy (FA), Mean Diffusivity (MD), Radial Diffusivity (RD) and Axial Diffusivity (AD), by employing whole-brain, tract-based spatial statistics (TBSS).

Results: ECT increases FA in the right splenium of the corpus callosum and the left cortico-spinal tract. Both the left superior longitudinal fasciculus and the right inferior fronto-occipital fasciculus showed increases in AD. Increases in MD and RD could be observed in overlapping white matter structures of both hemispheres. Finally, responders showed significantly smaller FA values in the left forceps major and smaller AD values in the right uncinate fasciculus compared with non-responders.

Conclusions: This is the first and largest multi-site mega-analysis to demonstrate that ECT normalizes altered WM microstructure in important brain circuits that are implicated in the pathophysiology of depression. Furthermore, responders appear to present a more decreased WM integrity at baseline, which if replicated could serve as a biomarker for ECT response.

Disclosure: No significant relationships.

Keywords: Diffusion Tensor Imaging; Electroconvulsive therapy; Tract-Based Spatial Statistics; Depression

O0036

N-Methyl-D-Aspartate Receptor availability in First-Episode Psychosis: a multi-modal PET-MR brain imaging study

K. Beck^{1*}, A. Arumham¹, S. Brugger², R. Mccutcheon¹, M. Veronese¹, S. Kaar¹, T. Pillinger¹, J. Stone³ and O. Howes¹

¹Institution of Psychiatry, Psychology & Neuroscience, Department Of Psychosis Studies, United Kingdom, United Kingdom; ²Cardiff University Brain Research Imaging Centre (CUBRIC), School Of

Psychology, HQ, United Kingdom and ³Brighton and Sussex Medical School, University Of Sussex, Brighton, United Kingdom

*Corresponding author.

doi: 10.1192/j.eurpsy.2022.238

Introduction: N-Methyl-D-Aspartate Receptor (NMDAR) hypofunction is hypothesised to underlie psychosis but this has not been tested early in illness.

Objectives: Our aim was to determine if NMDAR availability was lower in patients with first episode psychosis compared to healthy controls.

Methods: To address this, we studied 40 volunteers (21 patients with first episode psychosis and 19 matched healthy controls) using PET imaging with an NMDAR selective ligand, [¹⁸F]GE179, that binds to the ketamine binding site to index its distribution volume ratio (DVR) and volume of distribution (V_T). Striatal glutamatergic indices (glutamate and Glx) were measured simultaneously using magnetic resonance spectroscopy imaging (¹H-MRS).

Results: Hippocampal DVR, but not V_T, was significantly lower in patients relative to controls (p=0.02, Cohen's d=0.81; p=0.15, Cohen's d=0.49), and negatively associated with total (rho=-0.47, p=0.04), depressive (rho=-0.67, p=0.002), and general symptom severity (rho=-0.74, p<0.001). Exploratory analyses found no significant differences in other brain regions (anterior cingulate cortex, thalamus, striatum and temporal cortex). We found an inverse relationship between hippocampal NMDAR availability and striatal glutamate levels in people with first-episode psychosis (rho = -0.74, p <0.001) but not in healthy controls (rho = -0.22, p = 0.44).

Conclusions: These findings are consistent with the NMDAR hypofunction hypothesis and identify the hippocampus as a key locus for relative NMDAR hypofunction, although further studies should test specificity and causality.

Disclosure: No significant relationships.

Keywords: Psychosis; Neuroimaging; NMDAR; Glutamate

O0037

The thalamus and its subregions – a gateway to obsessive-compulsive disorder

C. Weeland^{1*}, C. Vriend¹, Y. Van Der Werf¹, C. Huyser², M. Hillegers³, H. Tiemeier⁴, T. White⁵, N. De Jooe¹, P. Thompson⁶, D. Stein⁷, O. Van Den Heuvel¹ and S. Kasprzak¹

¹Amsterdam UMC, Department Of Anatomy And Neurosciences; Department Of Psychiatry, Amsterdam, Netherlands; ²Academic Center for Child and Adolescent Psychiatry, De Bascule, Amsterdam, Netherlands; ³Erasmus Medical Center, Department Of Child And Adolescent Psychiatry, Rotterdam, Netherlands; ⁴Harvard TH Chan School of Public Health, -, Boston, United States of America; ⁵Erasmus MC, Child And Adolescent Psychiatry And Psychology, Rotterdam, Netherlands; ⁶eImaging Genetics Center, Stevens Institute for Neuroimaging & Informatics, Keck School of Medicine, University of Southern California, -, Los Angeles, United States of America and

⁷University of Cape Town, Dept Of Psychiatry & Neuroscience Institute, Cape Town, South Africa

*Corresponding author.

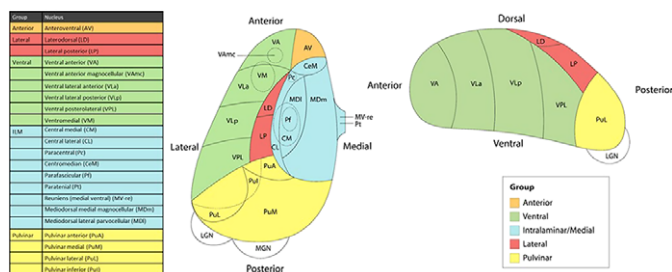
doi: 10.1192/j.eurpsy.2022.239

Introduction: Higher thalamic volume has been found in children with obsessive-compulsive disorder (OCD) and children with clinical-level symptoms within the general population (Boedhoe

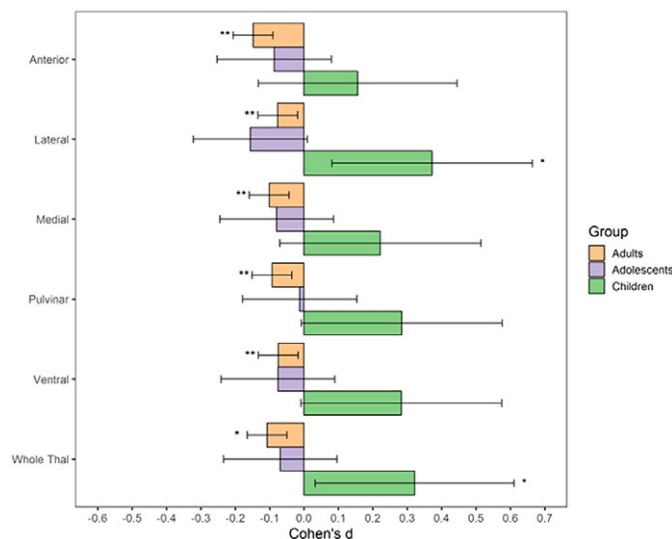
et al. 2017, Weeland et al. 2021a). Functionally distinct thalamic nuclei are an integral part of OCD-relevant brain circuitry.

Objectives: We aimed to study the thalamic nuclei volume in relation to subclinical and clinical OCD across different age ranges. Understanding the role of thalamic nuclei and their associated circuits in pediatric OCD could lead towards treatment strategies specifically targeting these circuits.

Methods: We studied the relationship between thalamic nuclei and obsessive-compulsive symptoms (OCS) in a large sample of school-aged children from the *Generation R Study* (N = 2500) (Weeland et al. 2021b). Using the data from the ENIGMA-OCD working group we conducted mega-analyses to study thalamic subregional volume in OCD across the lifespan in 2,649 OCD patients and 2,774 healthy controls across 29 sites (Weeland et al. 2021c). Thalamic nuclei were grouped into five subregions: anterior, ventral, intralaminar/medial, lateral and pulvinar (Figure 1).



Results: Both children with subclinical and clinical OCD compared with controls show increased volume across multiple thalamic subregions. Adult OCD patients have decreased volume across all subregions (Figure 2), which was mostly driven by medicated and adult-onset patients.



Conclusions: Our results suggests that OCD-related thalamic volume differences are global and not driven by particular subregions and that the direction of effects are driven by both age and medication status.

Disclosure: No significant relationships.

Keywords: OCD; thalamus; Neuroimaging; segmentation

O0038

Obsessive-compulsive Symptoms in Dementia : Scoping Review of Neurobiological and Cognitive Underpinnings

F. Martinho, T. Ferreira*, D. Magalhães, R. Felício and F. Godinho
Hospital Prof Doutor Fernando Fonseca, Mental Health Department, Amadora, Portugal

*Corresponding author.

doi: 10.1192/j.eurpsy.2022.240

Introduction: Obsessive-compulsive symptoms (OCS) have been described in many neurological disorders, including dementia. A meta-analysis by the authors (2021) reported a prevalence of OCS in dementia of approx. 35.8%, and a higher percentage in frontotemporal dementia (FTD) (46.7%). The literature also points that obsessive-compulsive disorder with late-life onset is rare, but those cases are frequently associated with neurologic injury, and some authors suggest a role of cognitive disfunction.

Objectives: Our main goal was to describe the neurobiologic and cognitive underpinnings of OCS in patients with dementia.

Methods: MEDLINE, CENTRAL and PsycNet databases were searched for articles about obsessive-compulsive symptoms in dementia. Search terms included “obsessive”, “compulsive”, “OCD”, “cognitive decline”, “cognitive dysfunction” and “dementia”. Titles, abstracts and full texts were screened independently by 2 reviewers.

Results: Correlations between dysfunction / lesions in various circuits in the context of dementia and OCS were found, such as (1) frontal regions (specially the orbitofrontal cortex) and anterior cingulate cortex (2) fronto-striatal-thalamic circuits (3) temporal structures; (4) cerebellar structures; (5) serotonergic, dopaminergic, and cholinergic neurotransmission. A high proportion of studies concerned FTD. Regarding cognitive mechanisms, there is a focus on the importance subjective concerns about cognitive functioning, which could exacerbate obsessional beliefs and maladaptive responses to intrusions.

Conclusions: The main brain circuits implicated in dementia, specially FTD, and OCS are those involving frontal regions and the fronto-striatal-thalamic circuits, with areas such as the temporal and cerebellar structures also being studied. The correlation between dysfunctional circuits in dementia and OCS could give us new hints about OCD and its treatment.

Disclosure: No significant relationships.

Keywords: frontotemporal dementia; obsessive-compulsive disorder; Obsessive-compulsive symptoms; Dementia

O0039

MDD patients with early life stress deactivate the frontostriatal network during facial emotion recognition paradigm: A functional MRI study

M. Simon^{1*}, S. Nagy², Z. Kürtös³, G. Perlaki², M. Gálber³ and B. Czéh³

¹Medical School, University of Pécs, Pécs, Hungary, Department Of Psychiatry And Psychotherapy, Pécs, Hungary; ²Hungarian Academy of Sciences - University of Pécs, Clinical Neuroscience Mr Research