

doi: 10.5455/aim.2014.22.411-412

ACTA INFORM MED. 2014 DEC 22(6): 411-412

Received: 11 September 2014 • Accepted: 02 December 2014

© AVICENA 2014

Published online: 19/12/2014

Published print: 12/2014

CASE REPORT

Effect Transformation of the Micro Electrode Recording (MER) Data to Fast Fourier Transform (FFT) for the Main Target Nucleus Determination for STN-DBS

Hulagu Kaptan¹, Murat Ayaz², Hakan Ekmekçi³Selçuk University, School of Medicine, Department of Neurosurgery, Konya, Turkey¹Selçuk University, School of Medicine, Department of Biophysics, Konya, Turkey²Selçuk University, School of Medicine, Department of Neurology, Konya, Turkey³

Corresponding author email: Dulagu Kaptan, MD. School of Medicine, Konya, Turkey. E-mail: hulagukaptanyahoo

ABSTRACT

Introduction: Advanced PD stimulation of the STN reduces tremor, rigidity, and bradykinesia. Due to hemorrhagic complications the use of micro electrode recordings during DBS operation was still questioning for some of surgeons. But use micro electrodes were still the best choice for the positioning during surgery of DBS. **Aim:** The aim of the current study was to investigate the effect transformation of the micro electrode recording data to fast fourier transform for the main target nucleus determination. This process needs a multidisciplinary approach from neurosurgery, neurology and specialists on electrophysiology such as biophysics. **Case report:** We present the case of a 63 year-old male with medically intractable PD is focused on behalf of the surgical treatment. Patient had a 4-year history of progressively severe hand tremor on right side. The patient was successfully treated unilaterally with the STN DBS.

Key words: subthalamic nucleus; deep brain stimulation; micro electrode recording; Parkinson's disease; fast fourier transform .

1. INTRODUCTION

Deep Brain Stimulation (DBS) for movement disorders using implantable systems developed by Medtronic (Mundinger et al., 1977) and further advanced and used in 1986 to treat medically refractory tremor in Parkinson Disease (PD) by Benabid (1).

DBS is in principle “reversible lesion” in the target nucleus and does not interfere with the use of other therapies (2). Subthalamic nucleus (STN) is the main target nucleus for DBS in PD. STN stimulation directly improves and reduces off time, thereby reducing dopaminergic medication requirements by approximately 50%; dyskinesias improve as a consequence (3,4).

Unilateral STN DBS is an effective and safe treatment for selected patients with advanced PD. Unilateral STN DBS provides improvement of contralateral motor symptoms of PD as well as quality of life, reduces requirements for medication and unified Parkinson's disease rating scale (UPDRS) score of the patient. This approach of surgical treatment may be associated with a reduced risk and may provide an alternative to bilateral STN DBS for PD, especially in older patients or patients with persistent asymmetry of parkinsonism.(5)

2. BACKGROUND AND PURPOSE

Advanced PD stimulation of the STN reduces tremor, rigidity, and bradykinesia. Due to hemorrhagic complications the use of micro electrode recordings during DBS operation

was still questioning for some of surgeons. But use micro electrodes were still the best choice for the positioning during surgery of DBS. The aim of the current study was to investigate the effect transformation of the micro electrode recording (MER) data to fast fourier transform (FFT) for the main target nucleus determination. This process needs a multidisciplinary approach from neurosurgery, neurology and specialists on electrophysiology such as biophysics.

3. CASE DESCRIPTIONS

We present the case of a 63 year-old male with medically intractable PD is focused on behalf of the surgical treatment. Patient had a 4-year history of progressively severe hand tremor on right side. He was undergone unilateral magnetic resonance imaging targeted, electrophysiologically guided STN DBS, completed with a battery. The patient was successfully treated unilaterally with the STN DBS. The patient is cured totally while the stimulation is carried on operatively. His cured status is tremor-free situation in daily life on following days.

MER data were obtained from superior, lateral and central regions. Imaging were biased 2.3 mm away from precise electrical activity recorded. MER data were then analyzed by means of FFT. With the aid of FFT data we choose the main target among three different centers. These analyzed results were then verified with the outcomes of the macro stimulated clinical evolution (including the neurological examina-

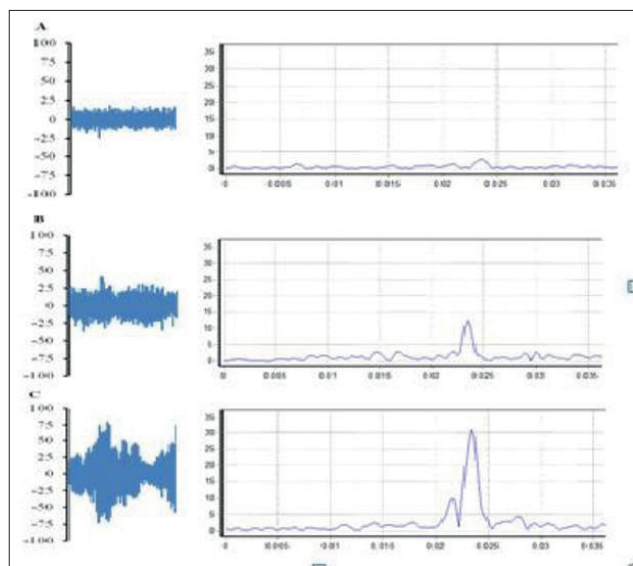


Figure- 1: Microelectrode recordings (MER) of the firing rate of neurons during surgical operation. In figure the main graphics shows the original recordings (blue in colour) while Insets of the each figure represents and FFT transformation of the recording micro electrode data. A shows the both the original and the FFT transformed data of the starting point. B shows the target area which was planned standing on the MRI results. C shows the actual target area depending on the microelectrode recordings.

tion as well). Figure shows the actual MER data (on the left hand side blue in color) and the FFT transformed MER data (on the right hand side) for three different placement of the micro electrode position. A section shows the situation at the starting point where as B shows MRI based calculated main target. C shows the actual target area depending on the FFT transformation. As it was clearly shown that the FFT transformations were a useful tool for the determination of the main target area.

4. DISCUSSION

DBS is a surgical treatment used to treat a number of neurological conditions such as essential tremor, PD and Dystonia. Preparation of this surgery begins several days before in order to reduce the medical therapy. Procedure needs Magnetic Resonance Imaging (MRI) especially the T2 weighted ones for better STN visualization (6).

Intraoperative stimulation is more widely accepted as a tool for use during surgery, the debate is between microstimulation and macrostimulation (7). The correct positioning of the electrodes can be improved by the use of multitrajectory MER to register the characteristic activity patterns of the cells in the different nuclei. Bour et al suggested that if MER is being used, probably less than five channels are necessary and MER could also be started closer than 8 and 12 mm for the MRI based STN target and GPi target, respectively. Finally, Zrinzo et al reported that the incidence of hemorrhage was also significantly lower with an image-guided and verified techniques approach than with MER approach (8,9). A FFT is an algorithm to compute the discrete Fourier transforms (DFT) and its inverse (10). Majority of the cases FFT trans-

formation were useful tool for understanding of the complex behavior of the biological signals. To best our knowledge current study is the first that apply the FFT transformations for understanding the complex behavior of the MER data.

5. CONCLUSION

Our findings suggest that the micro electrode recordings were the indispensable part of the DBS surgery. Application of the FFT to MER data may be used for the decrease in the number of micro electrodes used for the surgery. Additionally use of FFT transformations may also eliminate the macro stimulation and neurological examination phases of the surgery.

This view may in turn results in the decrease in surgery period need further investigation.

CONFLICT OF INTEREST: NONE DECLARED.

REFERENCES

1. Benabid AL, Pollak P, Louveau A, et al. Combined (thalamotomy and stimulation) stereotactic surgery of the VIM thalamic nucleus for bilateral Parkinson disease. *Appl Neurophysiol* 1987;50:344-6
2. Alvarez L, Macias R, Pavón N, et al. Therapeutic efficacy of unilateral subthalamotomy in Parkinson's disease: results in 89 patients followed for up to 36 months. *J Neurol Neurosurg Psychiatr* 2009;80:979-85.
3. Hariz MI, Rehnrcrona S, Quinn NP, et al. Multicentre Advanced Parkinson's Disease Deep Brain Stimulation Group. Multicenter study on deep brain stimulation in Parkinson's disease: an independent assessment of reported adverse events at 4 years. *Mov Disord* 2008;23:416-21
4. Follett KA, Torres-Russotto D. Deep brain stimulation of globus pallidus interna, subthalamic nucleus, and pedunculopontine nucleus for Parkinson's disease: Which target? *Parkinsonism Relat Disord*. 2012 Jan;18 Suppl 1:S165-7.
5. Marconi R, Landi A, Valzania F. Subthalamic nucleus stimulation in Parkinson's disease. *Neurol Sci*. 2008 Dec;29 Suppl 5:S389-91.
6. O'Gorman RL, Shmueli K, Ashkan K et al. Optimal MRI methods for direct stereotactic targeting of the subthalamic nucleus and globus pallidus. *Eur Radiol*. 2011 Jan;21(1):130-6. Epub 2010 Jul 21.
7. Guridi J, Rodríguez-Oroz MC, Clavero P et al. Critical review of the subthalamic stimulation in Parkinson's disease. *Neurocirugia (Astur)*. 2009 Dec;20(6):521-32.
8. Bour LJ, Contarino MF, Foncke EM et al. Long-term experience with intraoperative microrecording during DBS neurosurgery in STN and GPi. *Acta Neurochir (Wien)*. 2010 Dec;152(12):2069-77
9. Zrinzo L, Foltynie T, Limousin P. Reducing hemorrhagic complications in functional neurosurgery: a large case series and systematic literature review. *J Neurosurg*. 2012 Jan;116(1):84-94. Epub 2011 Sep 9.
10. Brenner, N.; Rader, C. A New Principle for Fast Fourier Transformation. *IEEE Acoustics, Speech & Signal Processing*. 1976 24 (3): 264-266.