

Carbimazole induced rhabdomyolysis

Niamh O'Donnell¹, Aisling McCarthy¹ and Ken Thong²

¹Department of Medicine, St Vincent's University Hospital, Dublin, Ireland and ²Department of Endocrinology, University of Western Australia, Perth, Western Australia, Australia

Correspondence
should be addressed
to N O'Donnell
Email
niavodonnell@gmail.com

Summary

Carbimazole is a commonly used antithyroid drug (ATD), which is associated with several well-established side effects. However, Carbimazole-induced rhabdomyolysis is rarely reported in the literature. We report a 27-year-old male who presented with upper limb myalgia and significantly raised creatine kinase elevation, 1-month post commencement of Carbimazole for Graves' disease. Carbimazole was ceased with subsequent clinical and biochemical improvement. Though the pathophysiology remains unclear, we hope to raise awareness regarding this rare adverse effect with a view to promote early recognition and prompt discontinuation of the offending medication caused by a commonly used medication in endocrinology.

Learning points:

- Musculoskeletal complaints can relate to unidentified and untreated hyperthyroidism. However one must be mindful that the treatment for these disorders can too induce myopathies.
- ATD-induced myopathy should be considered when there is a temporal relationship between introduction of ATDs and the onset of symptoms.
- If ATD-induced myopathy is being considered, other causes of myopathy should still be outruled.
- Prompt discontinuation of potentially offending medications may provide resolution of symptoms and avoid significant consequences.

Background

Skeletal muscle constitutes a significant proportion of our body mass and relies on thyroid hormone for optimum development, function, and regeneration (1, 2, 3, 4, 5). Thyroid dysregulation, unsurprisingly, can lead to myopathic symptoms and altered basal muscle metabolism (1, 2, 3, 4, 5, 6). While musculoskeletal complaints are common in thyroid disorders, skeletal muscle is also vulnerable to the circulating ATD used to combat these disorders (1, 2, 4). Cases of ATD-induced myopathy, characterized by proximal muscle weakness (without other cause for myopathy), elevated creatinine kinase, a temporal relationship between the commencement of treatment and symptomatology, and the resolution of symptoms upon withdrawal of the medication have been reported (1, 2, 3, 4). We present a patient with acute onset myopathy

having been recently commenced on Carbimazole for the treatment of newly diagnosed Graves' hyperthyroidism.

Case presentation

A 27-year-old male with a history of Ewing's Sarcoma aged 12, resulting in left-below knee amputation and prosthesis, presented to the outpatient clinic with a 6 month history of fatigue, pruritus, heat intolerance, sweating, and palpitations. He was found to have convincing clinical findings suggestive of hyperthyroidism, including bilateral upper limb fine tremor, lid lag, and retraction, and though there was no evidence of goiter, there was an audible thyroid bruit. Biochemical analysis confirmed a thyrotoxic state with

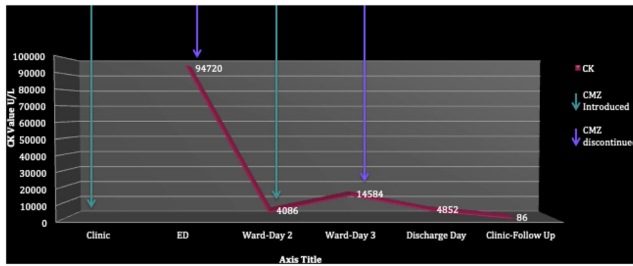


Figure 1
Temporal relationship of CK values to CMZ use.

a TSH < 0.01 (0.40–4.00 mIU/L) and free T4 of 31 (9.0–20.0 pmol/L). Thyroid autoantibodies were requested for his subsequent visit, but a clinical diagnosis of Graves' hyperthyroidism with mild ophthalmopathy was made. Carbimazole (CMZ) was commenced at a dose of 15 mg once daily.

Approximately 1-month post commencement of treatment, our patient presented to the emergency department with a 2-day history of bilateral upper limb myalgia, generalized fatigue, and darkened urine. He denied any trauma or recent augmentation of his usual exercise regimen. The dose of his only regular medication, CMZ, had not been altered since its commencement and he had not self-medicated with any over-the-counter medications/supplements or remedies. He revealed no personal or family history of neuromuscular or autoimmune disorders and reported no rashes, arthralgias, weight loss, anorexia, or fevers.

Physical examination was unchanged from his original presentation in the outpatient clinic. He had subjective bilateral proximal upper limb pain but no demonstrable neurological abnormalities. No cutaneous features of autoimmune conditions such as dermatomyositis or polymyositis were revealed.

The initial concern was the development of rhabdomyolysis, with differentials including exercise-induced and CMZ-induced rhabdomyolysis; however inflammatory, metabolic, endocrine-related, and electrolyte-related myopathies were also considered, prompting the below investigations.

Investigation

Laboratory investigations revealed a markedly elevated creatine phosphokinase (CK) at 94729 (40–250 U/L). There was an associated elevation of liver enzymes AST 1513 (5–35 U/L) and ALT 381 (5–40 U/L). Thyroid function tests revealed ongoing suppression of TSH < 0.01 (0.40–4.00 mIU/L), a free T3 of 6.0 (3.5–6.5 pmol/L), and

a minimally elevated free T4 of 20.6 (9.0–20.0 pmol/L). Full blood picture, kidney profile, and electrolytes including potassium, phosphate, and magnesium were unremarkable. CRP was 10 (<3 mg/L). Urine dipstick was strongly positive for blood and protein; however, unfortunately, urinalysis including the analysis for the presence of myoglobin was not performed. Investigations for other causes of myopathy were unremarkable including normal vitamin D and antinuclear antibodies out ruling and inflammatory myopathies or underlying connective tissue diseases. Other serological tests which may be considered depending on the clinical context would include ANCA titers, hepatitis serology, and cryoglobulins in those with suspected vasculitides.

Treatment

The patient was admitted and received intensive IV hydration, and CMZ was discontinued. This resulted in prompt resolution of symptoms during admission. CK fell from 94720 (40–250 U/L) to 4086 (40–250 U/L) (Fig. 1). CMZ was restarted during his inpatient stay, and CK subsequently rose again to 14584 (40–250 U/L) within 24 h, and thus, it was permanently discontinued.

Outcome and follow-up

Following the discontinuation of CMZ, he remained asymptomatic and CK normalized over the course of the following fortnight. He was commenced on propylthiouracil (PTU) as an outpatient. This transition was unremarkable and repeated CK at his 2 months follow-up remained normal.

Discussion

Musculoskeletal complaints relating to unidentified and untreated thyroid dysfunction are well reported. A significant proportion of those with hypothyroidism develop related myopathy; myalgias, proximal muscle weakness, and elevated muscle enzymes (2, 3, 7). Meanwhile, thyrotoxicosis is associated with a painless myopathy characterized by proximal muscle weakness, typically manifesting early in the disease trajectory, usually associated with normal muscle enzymes and resolving with anti-thyroid treatment (1, 2, 3).

There are, however, few reports illustrating the relationship between ATDs and myopathy, as is demonstrated in our case. Our patient's presentation mirrored those described in the literature, with the



confirmation of a biochemically thyrotoxic state, commencement on an ATD, demonstrable temporal relationship between commencement of the ATD, and the development of features suggestive of myopathy (up to 2 months), and with the resolution of symptomatology after discontinuation of the offending medication. Similar to our case, many cases report uneventful transitions to PTU (2). In contrast to our case, a rechallenge of the offending medicine was not trialed in other reports.

The underlying pathophysiology is not well understood with various mechanisms hypothesized. Some propose that ATDs such as CMZ used for our patient can cause direct toxicity to skeletal myocytes resulting in cell lysis and subsequent CK elevation (1, 2, 8). It is also postulated that the commencement of ATDs can result in swift decrements of thyroid hormone which results in a relative hypothyroid state locally within the muscle itself (1, 2, 3, 8).

Our case illustrated a rare adverse effect for a commonly used ATD. Given the debilitating consequences of CMZ and ATD-induced myopathies and rhabdomyolysis, early detection to ensure prompt withdrawal is essential.

Declaration of interest

The authors declare that there is no conflict of interest that could be perceived as prejudicing the impartiality of the research reported.

Funding

This research did not receive any specific grant from any funding agency in the public, commercial or not-for-profit sector.

Patient consent

Written informed consent has been obtained.

Author contribution statement

N O'Donnell was the treating Resident Medical Officer during the patient's inpatient stay. She prepared the initial draft of the article, co-ordinated with co-authors, and prepared the final manuscript. Co-author A McCarthy was responsible for manuscript review. Co-author K Thong is a consultant endocrinologist who provided clinical care for the patient in both acute and outpatient settings. He was also responsible for manuscript review.

References

- 1 Lim AY, Kek PC & Soh AW. Carbimazole-induced myositis in the treatment of Graves' disease: a complication in genetically susceptible individuals? *Singapore Medical Journal* 2013 **54** e133–e136. (<https://doi.org/10.11622/smedj.2013145>)
- 2 Tsang CC, Hui WS, Lo KM, Yeung JHM & Cheng YL. Anti-thyroid drugs-related myopathy: is carbimazole the real culprit? *International Journal of Endocrinology and Metabolism* 2015 **13** e17570. (<https://doi.org/10.5812/ijem.17570>)
- 3 Bou Khalil R, Abou Salbi M, El Kara N, Azar E, Khoury M, Abdallah G, Hreiki J & Farhat S. Methimazole-induced myositis: a case report and review of the literature. *Endocrinology, Diabetes and Metabolism Case Reports* 2013 **8** 130008. (<https://doi.org/10.1530/EDM-13-0008.3>)
- 4 Smithson J. Drug induced muscle disorders. *Australian Pharmacist* 2009 **28** 1056–1062.
- 5 Salvatore D, Simonides WS, Dentice M, Zavacki AM & Larsen PR. Thyroid hormones and skeletal muscle – new insights and potential implications. *Nature Reviews: Endocrinology* 2013 **4** 206–214.
- 6 Chawla J. Stepwise approach to myopathy in systemic disease. *Frontiers in Neurology* 2011 **2** 49. (<https://doi.org/10.3389/fneur.2011.00049>)
- 7 Anwar S & Rehum GA. Musculoskeletal manifestations of thyroid disease. *Rheumatic Diseases Clinics of North America* 2010 **36** 637–646. (<https://doi.org/10.1016/j.rdc.2010.09.001>)
- 8 Remya R, Sai Keerthana PC, Das A, Neethu CM, Joseph T, Meenu V & Roshni PR. A case report on carbimazole induced myositis. *International Journal of Pharmaceutical Sciences Review and Research* 2015 **32** 268–269.

Received in final form 28 April 2021

Accepted 7 June 2021