

Supraciliary contraction segments: A new method for the treatment of presbyopia

Zeki Tunc, Firat Helvacioğlu, Yesim Ercalik, George Baikoff, Sadik Sencan

Background and Objective: To evaluate the safety and effectiveness of supraciliary contraction segment implants (SCSIs) for the treatment of presbyopia. **Materials and Methods:** This prospective, non-comparative study comprised 10 eyes from five phakic and emmetropic 50-year-old subjects. Preoperative and postoperative near and distance visual acuity, topography, axial length, pachymetry, and intraocular pressure were analyzed. A 5.32-mm long and 0.85-mm thick piece of polymethyl methacrylate (PMMA) and a 5.32-mm long or 0.55-mm thick dried hydrophilic SCSI were placed within the scleral tunnels that were created 2 mm away from the limbus. The 500–550 µm deep tunnels were parallel to the limbus and four segments were implanted per eye. The SCSIs were entirely placed at a depth of approximately 85% in the sclera. **Results:** The uncorrected distance visual acuity was similar before and after the surgery (0.00 logMAR). The monocular mean uncorrected near visual acuity (UNVA) was 0.5 ± 0.0 before surgery, 0.12 ± 0.10 logMAR at 1 month after surgery, 0.16 ± 0.18 logMAR at 3 months after surgery, and 0.29 ± 0.16 logMAR at the 18-month follow-up. **Conclusion:** Despite obtaining satisfactory results at 6 months after the surgery, a follow-up of the SCSI intervention at 18 months revealed a regression of the early post-op UNVA improvement caused by a progressive outward movement of SCSIs.

Key words: Accommodation, presbyopia, supraciliary segment implants

Presbyopia is a progressively diminished ability to focus on near objects with age, caused by a decrease in the amplitude of accommodation. Because the accommodation theory is still under discussion, no definite surgical treatment for presbyopia has been suggested.^[1] Although many types of surgeries have been suggested, there is no universally accepted technique. Actual surgical treatments for presbyopia include corneal refractive surgery (excimer laser, conductive keratoplasty, intrastromal femtosecond laser ablation, and intrastromal implants) and monovision intraocular lens (IOL) and multifocal IOL implantation. Scleral expansion bands (SEB), anterior ciliary sclerotomy, and accommodative IOL implantation can be considered to be techniques that are capable of achieving a dynamic accommodation.^[2,3]

Techniques such as anterior ciliary sclerotomy and scleral expansion band implantation, which involve the treatment of presbyopia via the sclera, are known as “scleral expansion” techniques. Scleral expansion surgery depends on Schachar’s theory of accommodation.^[4] These techniques are based on changing the anatomy of the functional segment, which suggests a geometric problem rather than a hardening of the crystalline lens with age. Pseudo-accommodation is achieved in the sclera with these types of surgeries, which alter the biomechanical dynamics of the anterior segment.^[3]

To our knowledge, this is the first study to evaluate the treatment of presbyopia using scleral contraction procedures. The technique used in the present study is potentially

reversible, which encouraged its selection. We evaluated the results obtained after 18 months for supraciliary contraction segment implants (SCSIs)^[5] in 10 eyes of five patients. The goal of the present technique was not scleral expansion, but the filling of the supra-ciliary area with deeply placed implants. We expected the zonula to relax due to SCSI-mediated shifting of the ciliary body toward the center. We aimed to achieve real accommodation, as indicated in Helmholtz’s theory, by shortening the equatorial portion of the crystalline lens and increasing its curvature.

Materials and Methods

This prospective, non-comparative study was approved by the Ethical Board Committee of the Maltepe University School of Medicine and followed the tenets of the Declaration of Helsinki. All of the patients who participated in the study agreed to return for the postoperative examinations. After a full explanation of the purpose of the study and the associated procedures, signed informed consent was obtained from all of the patients. All of the operations were performed by two surgeons (ZT, GB) at the Department of Ophthalmology, Maltepe University School of Medicine, Istanbul, Turkey.

The inclusion criteria were as follows: 50 years of age, emmetropia (less than ± 0.50 diopters of refractive error), less than 0.75 diopters (D) of astigmatism and no visual dysfunction other than presbyopia. The exclusion criteria were as follows: previous ocular surgery, an additional ocular pathology (e.g., glaucoma, cataract, diabetic retinopathy, and age-related macular degeneration) and any kind of systemic disease. To obtain comparable results, the patients selected for inclusion in this study had similar characteristics. Ten eyes that belonged to the five phakic and emmetropic individuals were included in the study. The patients underwent surgery between February 2006 and January 2008, and all of the patients were 50 years old. The monocular near visual acuity of each

Access this article online

Website:

www.ijo.in

DOI:

10.4103/0301-4738.97554

Quick Response Code:

Department of Ophthalmology, Maltepe University School of Medicine, Istanbul, Turkey

Correspondence to: Dr. Zeki Tunc, Kultur mah Kucuk Camlik Sit A1 Blok D3 Etiler, 34340 Istanbul, Turkey. E-mail: zeki@zekitunc.com

Manuscript received: 23.07.11; **Revision accepted:** 23.01.12

patient was 0.00 logarithm of the minimum angle of resolution (logMAR) with a correction of +2.00 D and mean monocular UNVA of the patients was 0.5 logMAR. The preoperative and postoperative distance (5.0 m) visual acuity (VA) (Snellen chart) and near (40.0 cm) VA (Precision Vision Logarithmic Visual Acuity Chart 2000, New ETDRS, using photopic conditions of 85.0 cd/m²) were measured using Snellen notation and then converted to logMAR units. The topography (EyeSys Vision, Inc, V 4.5), measurement of the axial length with A-scan immersion ultrasonography (Ocuscan RxP, Alcon), pachymetric measurements (DGH, Paghette 2) and intraocular pressure (IOP) (Haag Streit Goldman applanation tonometer) of the subjects were analyzed. The SCSi placement was analyzed by Fourier-domain optical coherence tomography (OCT) (Optovue RTVue with a cornea-anterior module [CAM]). Follow-up evaluations were performed at 1, 3, 6, 12, and 18 months after surgery. Preoperative and postoperative examinations were performed under equivalent lighting with the same type of chart. At the beginning of the study, a lack of instruments did not allow us to conduct the objective accommodation amplitude measurements, which were subsequently performed when the instrument was obtained (iTrace, Tracey Technology). ITrace aberrometry was performed with cycloplegia for distant and without cycloplegia for near stimulation. Subjective patient questionnaires have been filled out by each patient to assess the quality of near vision in daily life and the personal satisfaction of the patients.

All of the surgeries were performed under general anesthesia. Limbal conjunctival peritomy was prepared in four different quadrants. The surgeon performed radial scleral incisions that were 1.8 mm long, 500–550 μ m deep, and 2 mm away from the limbus. This procedure was performed in the quadrants denoted as 3, 6, 9, and 12 o'clock with the aid of a diamond blade. Through each incision, a 6.5-mm long scleral tunnel was excavated using a 1.8-mm crescent blade. While generating the tunnel, the radial incision was set at a depth of 500 μ m as an arbitrary origin, and then the depth calibration was performed by diamond knives, which were used for radial keratotomy. Rather than remaining superficial, a depth of more than 550 μ m was preferred. Sometimes, the ends of the tunnels were deeper and entered the supraciliary area. The SCSi were positioned approximately 500–550 μ m deep in the sclera. A 5.32-mm long and 0.85-mm thick piece of polymethyl methacrylat (PMMA) [Fig. 1] or a 5.32-mm long or 0.55-mm thick dried hydrophilic SCSi were placed within the scleral tunnels (four per eye). PMMA SCSi was used in eight of the eyes, and dried hydrophilic SCSi was used in two. We were careful to place the SCSi parallel to the limbus and at a level equivalent to that of the ciliary body [Figs. 2 and 3]. Scleral incisions and conjunctiva were sutured using 8/0 vicryl. The hydrophilic SCSi was dried to render it hard and more amenable to manipulation. Upon hydration, the dried SCSi became 5.9 mm long and 0.96 mm thick. The subjects were treated with antibiotic and steroid drops for 4 weeks postoperatively.

Statistical Analysis

Statistical analyses were performed using the Friedman test and the Wilcoxon signed-rank test. The test was conducted to interpret whether the changes in logMAR values were significant. The measurements obtained at 1, 3, 6, 12, and 18 months were included in the statistical test, and then the




Figure 1: The polymethyl methacrylat supraciliary segment implant, (a) lateral view, (b) anterior view

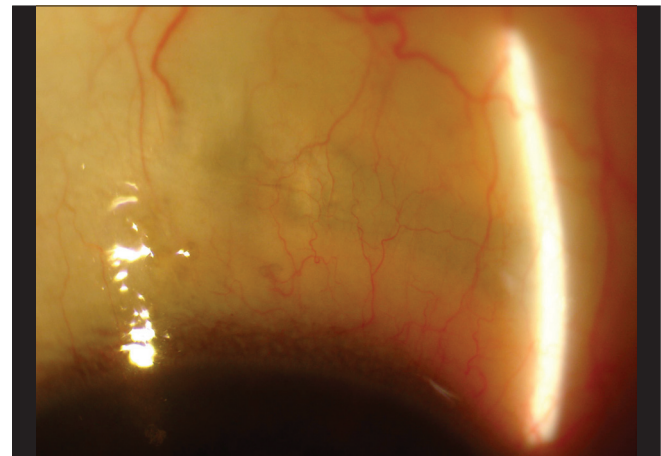


Figure 2: View of the supraciliary segment implant, which is placed in the sclera completely

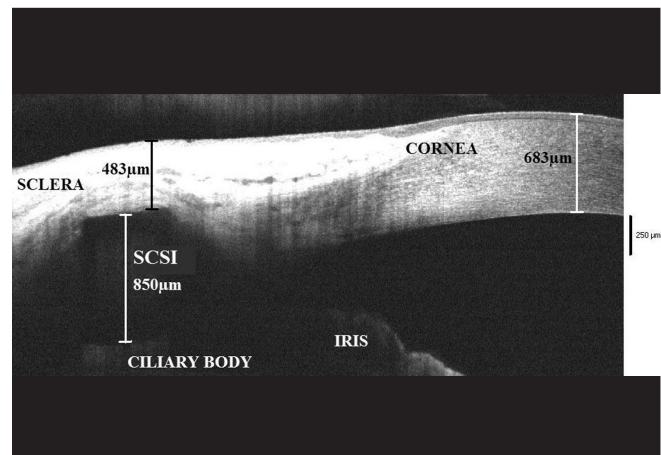


Figure 3: Fourier-domain optical coherence tomography showing the precise cross-sectional visualization and depth of the hyporeflexive intrascleral supraciliary contraction segment implant

changes were analyzed using the Friedman test. LogMAR values obtained at 1, 3, 6, 12, and 18 months were compared to the preoperative values using the Wilcoxon signed-rank test.

Results

During the early postoperative period, although the uncorrected distance visual acuities (UDVA) of three subjects during the early postoperative period were impaired due to astigmatism (mean 1.16 D), all 10 eyes showed UDVA-values of 0.00 logMAR 1 month after implantation [Fig. 4]. The mean preoperative and 3-month postoperative spherical equivalent refractive error of the patients was 0.175 D and 0.2 D, respectively. One month after the surgery, the uncorrected near visual acuity (UNVA) was 0.00 logMAR [Jaeger (J) 1] in two eyes (20%), 0.10 logMAR (J2) in six eyes (60%), and 0.30 logMAR (J5) in two eyes (20%) [Table 1A]. The mean monocular UNVA was 0.5 ± 0.0 before surgery, 0.12 ± 0.10 logMAR at 1 month after the surgery, 0.16 ± 0.18 logMAR at 3 months after the surgery, and 0.29 ± 0.16 logMAR at the 18-month follow-up [Fig. 5]. According to the Friedman test results, the changes in logMAR values were significant ($P < 0.001$). Furthermore, the logMAR values at 1, 3, 6, 12, and 18 months were compared with the preoperative values using the Wilcoxon signed-rank test. After the first month, the P -value was 0.004; at 3 months, the P -value was 0.008; and at 6, 12, and 18 months, the P -value was 0.011 ($P < 0.05$). The mean correction for a near vision of 0.00 logMAR was 2.00 ± 0.00 D prior to surgery, 0.40 ± 0.39 D at 1 month after surgery, 0.55 ± 0.42 D at 3 months after surgery, 0.93 ± 0.68 D at 6 months after surgery, 1.05 ± 0.37 D at 12 months after surgery, and 1.43 ± 0.60 D at 18 months after surgery [Table 1B]. According to the test results, the changes were statistically significant. The postoperative mean correction for a near vision of 0.00 logMAR increased with time [Fig. 6]. The mean objective accommodation amplitude measurement obtained using iTrace was 0.32 ± 0.39 D at 18 months after surgery. The patients' personal satisfaction with the procedure was investigated by questionnaires [Table 2A-C]. At the 3-month follow-up, four patients (80%) were able to read books and newspapers without glasses, whereas at 6 months, this outcome was observed in three patients (60%), at 12 months in two patients (40%), and at 18 months in one patient (20%). The mean axial length of the eyes was 22.86 ± 0.18 mm preoperatively and 22.82 ± 0.15 mm at 3 months after surgery. The preoperative mean central corneal thickness was 569.40 ± 24.07 μ m, and the 3-month postoperative central corneal pachymetry measurement indicated a mean value of 570.30 ± 23.54 μ m. The topography revealed surface changes within the first month. In all of the patients, the topography returned to preoperative values after 3 months and remained stable. The mean preoperative keratometry (K) value was 43.01 ± 0.18 D, whereas it was 42.56 ± 0.18 D at the postoperative 3-month follow-up [Table 3].

During the postoperative period, the most common complaints were redness, irritation, foreign body sensation, and photophobia, all of which decreased significantly by 2 weeks. One anterior chamber of the eye presented a reaction that could be controlled with medication and demonstrated an increase in IOP. The IOP of the subject decreased to preoperative values over a 10-day period. The mean IOP of the subjects was 12.9 ± 0.14 mmHg appplanation (App) preoperatively, and the postoperative 3-month follow-up mean

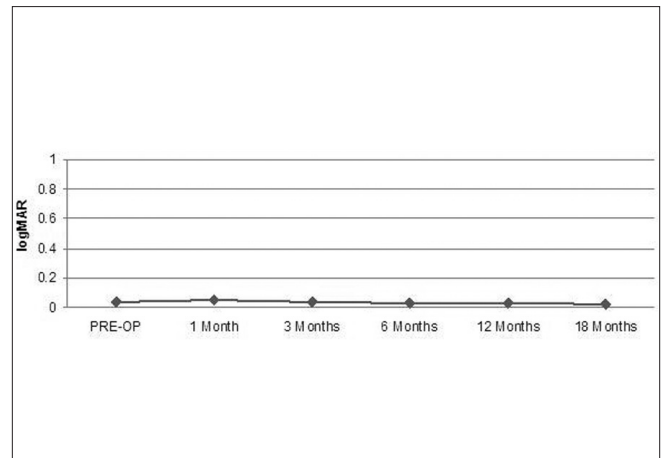


Figure 4: Preoperative and postoperative mean uncorrected distance visual acuity values

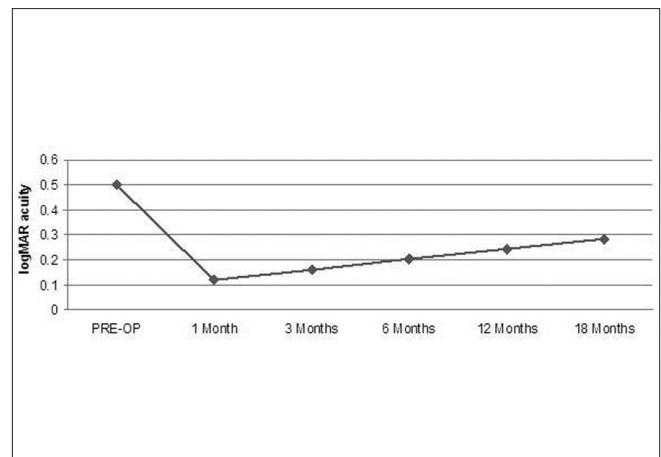


Figure 5: Preoperative and postoperative mean uncorrected near visual acuity values

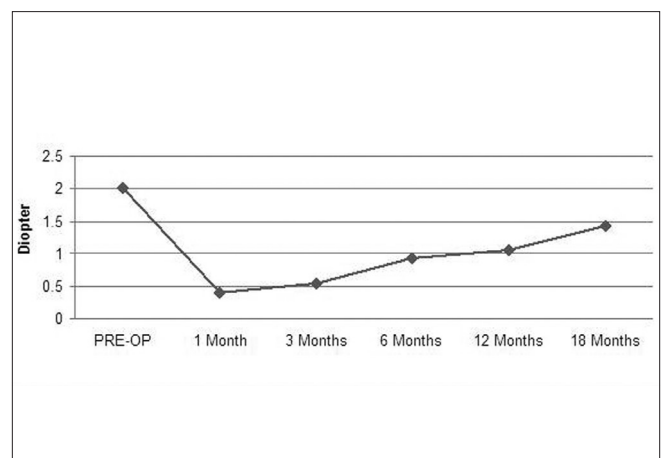


Figure 6: Preoperative and postoperative mean near correction for a near vision of 0.00 logMAR

Table 1A: Progression of UNVA values (logMAR)

	Pre-Op	1 Month	3 Months	6 Months	12 Months	18 Months
Patient 1 OD	0.5	0	0	0	0.1	0.1
Patient 1 OS	0.5	0	0	0	0.1	0.1
Patient 2 OD	0.5	0.1	0.1	0.1	0.18	0.18
Patient 2 OS	0.5	0.1	0.1	0.1	0.18	0.3
Patient 3 OD	0.5	0.3	0.5	0.5	0.5	0.5
Patient 3 OS	0.5	0.3	0.5	0.5	0.5	0.5
Patient 4 OD	0.5	0.1	0.1	0.18	0.2	0.2
Patient 4 OS	0.5	0.1	0.1	0.18	0.18	0.18
Patient 5 OD	0.5	0.1	0.1	0.2	0.2	0.4
Patient 5 OS	0.5	0.1	0.1	0.3	0.3	0.4
Mean ± SD	0.5 ± 0.00	0.12 ± 0.10	0.16 ± 0.18	0.21 ± 0.18	0.24 ± 0.15	0.29 ± 0.16

OD: Right eye, OS: Left eye

Table 1B: Preoperative and postoperative correction (Diopter) for near vision of 0.00 logMAR

	Pre-Op	1 Month	3 Months	6 Months	12 Months	18 Months
Patient 1 OD	2.00	0.00	0.00	0.00	0.50	0.50
Patient 1 OS	2.00	0.00	0.00	0.00	0.50	0.50
Patient 2 OD	2.00	0.50	0.50	0.50	1.00	1.75
Patient 2 OS	2.00	0.50	0.50	0.50	1.00	2.00
Patient 3 OD	2.00	1.00	1.25	2.00	1.50	2.00
Patient 3 OS	2.00	1.00	1.25	1.75	1.50	1.75
Patient 4 OD	2.00	0.50	0.50	1.00	1.25	1.50
Patient 4 OS	2.00	0.50	0.50	1.00	0.75	0.75
Patient 5 OD	2.00	0.00	0.50	1.25	1.25	1.75
Patient 5 OS	2.00	0.00	0.50	1.25	1.25	1.75
Mean ± SD	2.00 ± 0.00	0.40 ± 0.39	0.55 ± 0.42	0.93 ± 0.68	1.05 ± 0.37	1.43 ± 0.60

OD: Right eye, OS: Left eye

Table 2A: Patient self-evaluation of the presbyopic procedure

Since your presbyopic implant surgery,
how do you rate the overall improvement of UNVA (postoperative vs. preoperative)?

	No Improvement	Slight Improvement	Moderate Improvement	Marked Improvement	Extreme Improvement
1 Month		1 patient		3 patients	1 patient
3 Months		1 patient		3 patients	1 patient
6 Months		1 patient	1 patient	2 patients	1 patient
12 Months		2 patients	2 patients	1 patient	
18 Months	1 patient	3 patients		1 patient	

Table 2B: Patient self-evaluation of the presbyopic procedure

In general, how satisfied are you with the results of your presbyopic surgery?

	Very Dissatisfied	Dissatisfied	Neutral	Moderately Satisfied	Very Satisfied
1 Month			2 patients	2 patients	1 patient
3 Months				4 patients	1 patient
6 Months			1 patient	2 patients	1 patient
12 Months		2 patients	2 patients	1 patient	1 patient
18 Months		2 patients	2 patients	1 patient	

IOP was 12.3 ± 0.18 mmHg App. At the 6-month follow-up, 15 of 40 segments became superficial [Fig. 7], and two of those segments were removed from the conjunctiva [Fig. 8]. When the segment materials were considered, 12 (37.5%) of 32 PMMA and 3 (37.5%) of 8 hydrophilic segments became superficial at the 6-month follow-up. After 12 months, a limited outward movement of the SCSIs was found to be maintained; 20 (62.5%) of 32 PMMA and 5 (62.5%) of 8 hydrophilic segments were visible under the conjunctiva. At 18 months, the examinations revealed similar findings as 12 months and no more segments were removed.

Discussion

Several theories have been proposed to explain the mechanism of presbyopia. According to Helmholtz's theory, when the eye focuses on an object that is near, the ciliary muscle contracts, the zonula becomes relaxed, and the anterior and posterior curvatures of the crystalline lens increase. Consequently, the lens becomes spherical and more optically powerful, and the lens equator moves away from the sclera. With the elasticity of the lens, the anterior and posterior curvatures increase; however, this mechanism changes with age.^[3,6-8]

According to Schachar's theory of accommodation, which was first proposed in 1992, due to contraction of the ciliary muscle, the equatorial zonula tension increases, the anterior ciliary muscle moves forward and towards the sclera, and the anterior and posterior zonula become relaxed.^[9] As a

consequence of the equatorial traction, the surface of the peripheral lens flattens, the peripheral volume of the lens decreases, the center of the lens steepens, and the optical power of the central lens increases.^[2,3,10] The aim of Schachar's technique is to increase the effective distance between the ciliary body and the lens equator to restore the ciliary muscle function.^[9] The change in the lens geometry that develops secondary to SEB has been reported to provide a pseudo-accommodation by creating a multifocality effect on the lens.^[11,12] It has also been suggested that these patients demonstrate better sight capabilities because of psychological effects or by remembering the lines on the chart.^[2,13] Consequently, many studies have demonstrated that the SEB procedure has not provided any improvement in accommodation.^[7,8,14,15]

The imaging techniques for observing the ciliary body and crystalline lens during accommodation include A-scan imaging,^[16] ultrasound biomicroscopy,^[17] three-dimensional ultrasound biomicroscopy,^[18] Scheimpflug photographs,^[19] magnetic resonance imaging,^[20] and infrared cameras.^[21] Most of the experiments performed using these imaging procedures have been consistent with Helmholtz's theory of accommodation.^[22] Recently, in the IRM study, Strenk *et al.* reported that the mechanism of human accommodation is primarily Helmholtzian;^[23] no anterior accommodative movement of the ciliary muscle apex was observed. Although the authors agree on accommodation, there are different opinions with respect to presbyopia.

The original geometric theory described by Koretz and Handelman attributes presbyopia to a continually increasing zonular tension that is secondary to life-long increases in lens thickness; this process ultimately abrogates the ability to move the ciliary muscles.^[24] On the other hand, the modified geometric theory of Strenk *et al.* attributes presbyopia to a continually decreasing zonular tension that is secondary to life-long increases in lens thickness; this process ultimately causes the accommodative ciliary muscle movement to be irrelevant. MRI studies have indicated that human ciliary muscle contraction does not diminish with age.^[20,25]

Strenk *et al.* found that the ciliary muscle anteroposterior

Table 2C: Patient self-evaluation of the presbyopic procedure

	Would you undergo a presbyopic implant surgery again?	
	Yes	No
1 Month	5 patients	
3 Months	5 patients	
6 Months	2 patients	3 patients
12 Months	2 patients	3 patients
18 Months	1 patient	4 patients

Table 3: Patient demographics

	Age	Sex (M/F)	Preoperative			Three Months Postoperative		
			Mean K (D)	CCP* μ m	AL imm A-scan (mm)	Mean K (D)	CCP* μ m	AL imm A-scan (mm)
Patient 1 OD	50	M	43.36	555	22.93	42.39	558	22.09
Patient 1 OS	50	M	42.93	552	22.87	42.69	556	22.85
Patient 2 OD	50	M	41.85	587	22.63	41.21	585	22.64
Patient 2 OS	50	M	41.69	593	22.72	41.37	596	22.69
Patient 3 OD	50	M	43.69	556	23.01	43.74	552	22.97
Patient 3 OS	50	M	44.22	571	23.02	43.92	563	23.12
Patient 4 OD	50	M	41.73	599	22.76	40.45	601	22.64
Patient 4 OS	50	M	40.96	601	22.78	41.15	603	22.72
Patient 5 OD	50	M	44.84	545	22.84	44.67	548	22.86
Patient 5 OS	50	M	44.87	535	22.75	44.01	541	22.78
Mean \pm SD	50.00 \pm 0.00	10/0	43.01 \pm 1.41	569.40 \pm 24.07	22.86 \pm 0.18	42.56 \pm 1.47	570.30 \pm 23.54	22.82 \pm 0.15

Mean K: Mean keratometry, CCT: Central corneal thickness, AL imm A-scan: Axial length using an immersion A-scan

thickness increased with accommodation in the phakic eye. It was also mentioned that strategies for the surgical correction of presbyopia can rely on ciliary muscle contraction (inward movement), which is undiminished by age in phakic eyes and pseudophakic eyes.^[25]

Because all of these experiments have supported Helmholtz's theory of accommodation, we were encouraged to adhere to Helmholtz's theory in the technique performed herein for the sclera. In our technique, the SCSIs were placed at depths of 500–550 μm in the sclera. Although there were no measurements of the ciliary ring diameter, we postulated that at this depth, the SCSIs would not push on the thick external side of the sclera but would push the internal side up to 850 μm [Fig. 3]. At 5.5 mm in length, each of the four segments encompasses the eye like a circle to push the ciliary body, which causes the ciliary rim to shrink. Thus, the SCSIs would push the ciliary body to the center of the circumlental space, and a reduction of the ciliary ring and relaxation of the zonula are anticipated, as described by Helmholtz's theory.

In the present study, the topographic values did not change postoperatively, which demonstrated that the improvement in near vision was not the result of a corneal multifocality effect. In addition, we concluded that the near vision improvement was not due to secondary myopia because no differences were observed between the preoperative and postoperative refractive conditions and axial lengths. In the present technique, we aimed to fill the supraciliary area by placing the SCSIs deeply within the sclera [Fig. 3]. We think that the improvement of postoperative near vision resulted from the relaxed zonula and the increase in lens curvature after filling the ciliary area with the SCSIs.

At the 3-month follow-up, four patients (80%) were able to read books and newspapers without glasses. The same effect was observed at 6 months for three patients (60%), at 12 months for two patients (40%), and at 18 months for only one patient (20%); however, the correction for near vision diminished postoperatively in all of the patients. The preoperative and postoperative mean UNVA logMAR values at 1, 3, 6, 12, and 18 months were analyzed statistically using the Friedman and Wilcoxon signed-rank tests. The results were found to be statistically significant. Moreover, the objective accommodative measurement conducted using iTrace revealed relatively lower values (0.32 ± 0.39 D at 18 months after surgery) as compared with the subjective accommodation. For example, the patient in Fig. 9 had a UNVA 0.1 logMAR at 18 months, but iTrace demonstrated only 1.00 D of accommodation. In reality, 1.00 D of accommodation was probably underestimated, because iTrace provides the mean value of accommodation. An analysis of the refraction map for near vision revealed that iTrace demonstrated a shift in refraction into the myopic range with near focus. This shift reached as much as 2.8 D of myopia and 3.2 D of refractive range, thus explaining the continued good quality of life of the patient [Fig. 9].

The study had some limitations. First, the number of eyes might not permit statistical analyses with sufficient power. However, considering the nature of this pilot study, the data were sufficient to obtain important conclusions. Second, both eyes of the patients underwent surgery, and there was no unoperated control eye. The decision to use this strategy was

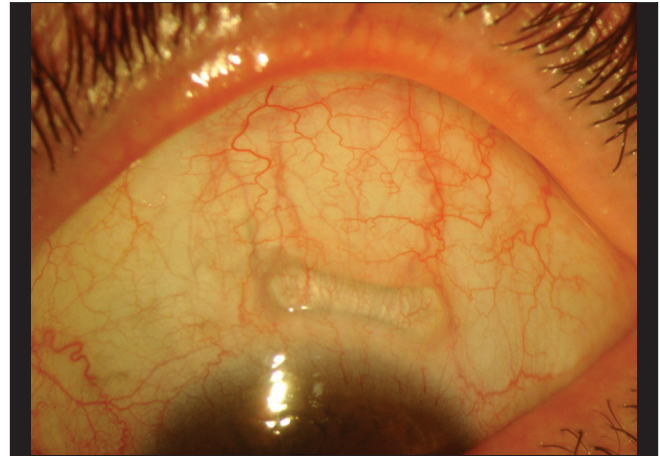


Figure 7: Views of the exposed supraciliary contraction segment implant under the conjunctiva

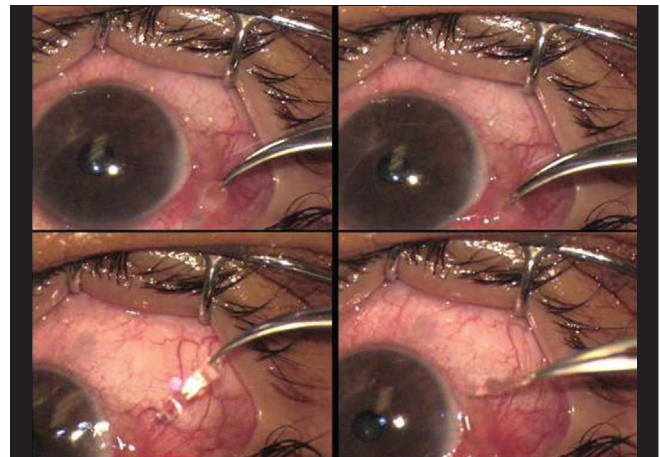


Figure 8: Supraciliary contraction segment implant extracted from the conjunctiva

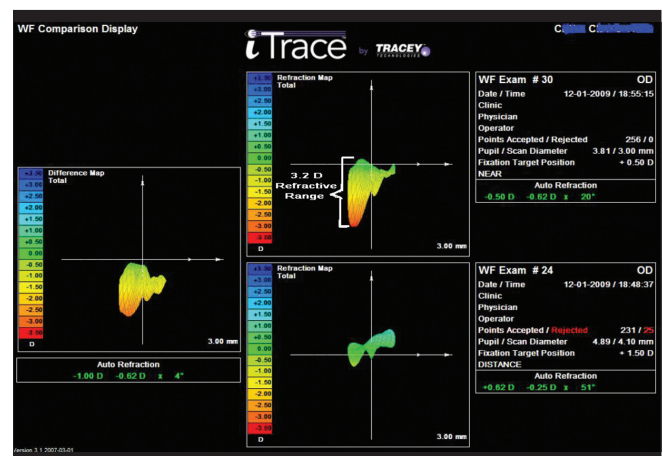


Figure 9: Objective accommodative measurement using iTrace in the difference map and demonstrating 1.00 D of accommodation

based on our patients' and our belief in this treatment option. Binocularity is an important factor for both distance and near vision. We think that when both eyes undergo surgery, outcomes that are more satisfactory are achieved. Because our main goal was to demonstrate an improvement in accommodation with the aid of these segments, the preoperative status of the eyes could be considered as the control group in the present study. The 18-month follow-up time of the study allowed us to obtain important data concerning the segment instability.

After the first 3-month period, we could not visualize the SCSIs under the sclera using slit-lamp examinations, which was a depth criterion for us. After 3 months, some of the segments appeared under the sclera as shades, and they became clearer in subsequent months. At the 6-month follow-up, the inward movements of 12 of 32 PMMA segments changed; they became outward movements. Thus, the segments started to rise to the surface of the sclera. After identifying the superficialization of the PMMA segments at 6 months, dried hydrophilic acrylic segments were used in the surgery performed for the last patient. Unfortunately, the same problem was encountered using this material; three of eight hydrophilic acrylic segments became superficial at 6 months. After 12 months, the outward movement of the SCSIs continued. 25 of them (80% PMMA, 20% hydrophilic acrylic) had moved to superficial areas of the sclera, and the other 15 (80% PMMA, 20% hydrophilic acrylic) were found at positions between 100 and 480 μm deep in the sclera [Fig. 10A]. Only PMMA segments of patient 1 did not move to superficial areas of the sclera and UNVA of this patient remained 0.1 logMAR for both eyes at 18 months after surgery. The movement of the SCSIs to the surface of the sclera did not push the ciliary body, and thus, a diminution of the accommodation occurred. Consequently, the mean UNVA of 0.16 ± 0.18 logMAR at 3 months after surgery decreased to 0.29 ± 0.16 logMAR at 18 months after surgery. In our clinical observations, as the SCSIs moved to the surface of the sclera, the UNVA demonstrated an associated decrease. Also, normal decrease in accommodative amplitude, which is 0.3 diopters/year, might affect this outcome.

The superficialization of SCSIs may be due to an incompatibility between the sclera and the PMMA and hydrophilic acrylic materials. Another explanation for the superficialization may be the capacity of the intraocular pressure to push the SCSi outward from the eye. At the 18-month follow-up, the effects of the surgery had decreased. In conclusion, despite obtaining satisfactory results at 6 and 12 months, the follow-up of the SCSi intervention at 18 months revealed a reduced improvement of the UNVA results in association with an outward movement of the SCSIs. Since there was not any refractive shift observed during this period, the decrease in the UNVA could be related to decreased ability of accommodation as the segments became superficial.

We believe that this prospective pilot study, which is the first clinical study to demonstrate the effects of constricting segments, revealed two important points concerning the surgical treatment of presbyopia. First, SCSIs were found to be capable of improving UNVA. Second, their effects were temporary because they were not stable in the supraciliary area. We think that a more detailed investigation of the outward movement of SCSIs with larger groups and different materials will improve the treatment strategies employed for presbyopia.

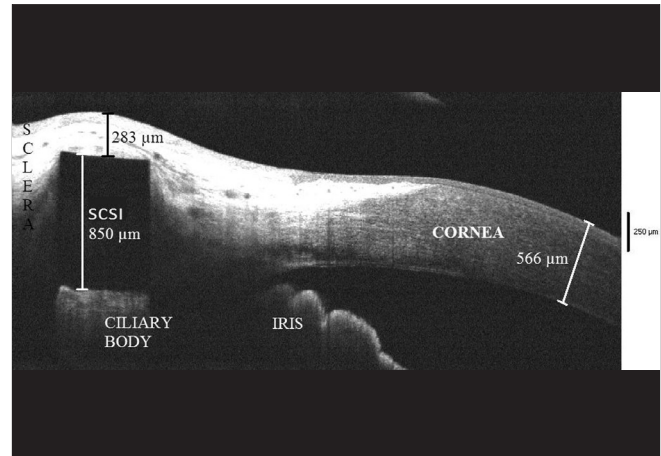


Figure 10: Tendency of the supraciliary contraction segment implants to rise to the surface of the sclera

References

1. Coleman DJ. Theory and mechanism of accommodation. In: Belville JK, Smith RJ, editors. *Presbyopia surgery: Pearls and pitfalls*. 1st ed. Thorofare, NJ: SLACK Inc.; 2006. p. 183-9.
2. Ostrin LA, Kasthurirangan S, Glasser A. Evaluation of a satisfied bilateral scleral expansion band patient. *J Cataract Refract Surg* 2004;30:1445-53.
3. Krueger R, McDonald M, Murube J, Wilson S. Current trends in the surgical correction of presbyopia. In: Boyd BF, editor. *Highlights of Ophthalmology International*. Vol. 29. Panama: El Dorado; 2001. p. 42-51.
4. Schachar RA, Huang T, Huang X. Mathematical proof of Schachar's hypothesis of accommodation. *Ann Ophthalmol* 1993;25:5-9.
5. Baikoff G. US patent no. 6,682,560, January 27th 2004.
6. Helmholtz H. Mechanism of accommodation. In: Southall JP, editor. *Helmholtz's Treatise on Physiological Optics*; Translated from the 3rd German edition. New York, NY: Dover; 1962. p. 143-73.
7. Quazi MA, Pepose JS, Shuster JJ. Implantation of scleral expansion band segments for the treatment of presbyopia. *Am J Ophthalmol* 2002;134:808-15.
8. Mathews S. Scleral expansion surgery does not restore accommodation in human presbyopia. *Ophthalmology* 1999;106:873-7.
9. Schachar RA. Cause and treatment of presbyopia with a method for increasing the amplitude of accommodation. *Ann Ophthalmol* 1992;24:445-7, 452.
10. Schachar RA, Black TD, Kash RL, Cudmore, DP, Schanzlin DJ. The mechanism of accommodation and presbyopia in the primate. *Ann Ophthalmol* 1995;27:58-67.
11. Singh G, Chalfin S. A complication of scleral expansion surgery for treatment of presbyopia. *Am J Ophthalmol* 2000;130:521-3.
12. Ludwig K, Kampik A. The mechanism of accommodation in primates. *Ophthalmology* 2000;107:221-2.
13. Elander R. Scleral expansion surgery does not restore accommodation in human presbyopia. *J Refract Surg* 1999;15:604.
14. Glasser A. Restoration of accommodation. *Curr Opin Ophthalmol* 2006;17:12-8.
15. Malecaze FJ, Gazagne CS, Tarroux MC, Gorrard JM. Scleral expansion bands for presbyopia. *Ophthalmology* 2001;108:2165-71.
16. Glasser A, Campbell MC. Presbyopia and the optical changes in the human crystalline lens with age. *Vision Res* 1998;38:209-29.

17. Ludwig K, Wegschneider E, Hoops J, Kampik A. *In vivo* imaging of the human zonular apparatus with high-resolution ultrasound biomicroscopy. *Graefes Arch Clin Exp Ophthalmol* 1999;237:361-71.
18. Stachs O, Kirschhoff A, Martin H, Guthoff R. 3D Ultrasonic imaging of the cilier body region. In: Guthoff R, Ludwig K, editors. *Current Aspects of Human Accommodation*. 1st ed. Heidelberg: Kaden Verlag; 2001. p. 103-13.
19. Koretz JF, Cook CA, Kaufman PL. Accommodation and presbyopia in the human eye: Changes in the anterior segment and crystalline lens with focus. *Invest Ophthalmol Vis Sci* 1997;38:569-78.
20. Strenk SA, Semmlow JL, Strenk LM, Munoz P, Gronlund-Jacob J, DeMarco JK. Age-related changes in human ciliary muscle and lens: A magnetic resonance imaging study. *Invest Ophthalmol Vis Sci* 1999;40:1162-9.
21. Wilson RS. Does the lens diameter increase or decrease during accommodation? *Human accommodation studies: A new technique using infrared retro-illumination video photography and pixel unit measurements*. *Trans Am Ophthalmol Soc* 1997;95:261-7; discussion 267-70.
22. Baikoff G, Lutun E, Wei J, Ferraz C. Anterior chamber optical coherence tomography study of human natural accommodation in a 19-year-old albino. *J Cataract Refract Surg* 2004;30:696-701.
23. Strenk SA, Strenk LM, Guo S. Magnetic resonance imaging of the anteroposterior position and thickness of the aging, accommodating, phakic, and pseudophakic ciliary muscle. *J Cataract Refract Surg* 2010;36:235-41.
24. Koretz JF, Handelman GH. How the human eye focuses. *Sci Am* 1988;259:92-9.
25. Strenk SA, Strenk LM, Guo S. Magnetic resonance imaging of aging, accommodating, phakic, and pseudophakic ciliary muscle diameters. *J Cataract Refract Surg* 2006;32:1792-8.

Cite this article as: Tunc Z, Helvacioğlu F, Ercalík Y, Baikoff G, Sencan S. Supraciliary contraction segments: A new method for the treatment of presbyopia. *Indian J Ophthalmol* 2014;62:116-23.

Source of Support: Nil. **Conflict of Interest:** None declared.