

Ascites Drainage Leading to Intestinal Adhesions at the Mesentery of the Small Intestine with Fatal Outcome

B. Kettler¹, H. Schrem¹, J. Klempnauer¹ and G. Grannas¹

¹General, Visceral and Transplant Surgery, Hannover Medical School, Hannover, Germany.

ABSTRACT: A common problem in patients with chronic liver diseases and liver cirrhosis is the development of ascites. First line therapy for ascites is the restriction of sodium intake and a diuretic treatment. Paracentesis is indicated in patients with large compromising volumes of ascites. In selected cases, permanent drainage of ascites over prolonged periods of time may be indicated. In the case presented here, a 66-year-old male patient, who was hospitalized with liver cirrhosis caused by alcoholic abuse, required permanent drainage of ascites. After three weeks of continuous ascites drainage, he developed bacterial peritonitis. Conventional attempts to remove the catheter by transcutaneous pulling failed and we thus decided to perform a median laparotomy to remove the catheter surgically. Intraoperatively an adhesion of the ascites drain (a so called ‘basket catheter’) to the mesentery very close to the small intestine was found, approximately 50 mm distal of the ligament suspensorium duodeni (ligament of Treitz). The basket catheter used for this patient was especially designed to drain infections, not fluids. We solved the adhesion, removed the basket catheter, placed a new surgical drain and finished the operation. The patient developed a rupture of his abdominal fascia suture 12 days later, which was caused by massive ascites and complicated by hepatorenal syndrome type I. The patient was taken to the operating theater again. After the second operation, the chronic liver failure decompensated and the patient died. Ascites caused by liver cirrhosis is still a medical challenge. The indication for the use of the correct percutaneous catheter for permanent paracentesis should be carefully considered. Some catheters are obviously not suited to drain ascites and may lead to fatal outcomes.

KEYWORDS: ascitic drainage, surgery, hepatorenal syndrome

CITATION: Kettler et al. Ascites Drainage Leading to Intestinal Adhesions at the Mesentery of the Small Intestine with Fatal Outcome. *Clinical Medicine Insights: Case Reports* 2014:7 3–5 doi: 10.4137/CCRep.S12920.

RECEIVED: July 31, 2013. **RESUBMITTED:** November 10, 2013. **ACCEPTED FOR PUBLICATION:** November 12, 2013.

ACADEMIC EDITOR: Athavale Nandkishor, Associate Editor

TYPE: Case Report

FUNDING: Author(s) disclose no funding sources.

COMPETING INTERESTS: Author(s) disclose no potential conflicts of interest.

COPYRIGHT: © the authors, publisher and licensee Libertas Academica Limited. This is an open-access article distributed under the terms of the Creative Commons CC-BY-NC 3.0 License.

CORRESPONDENCE: kettler.bastian@mh-hannover.de

Introduction

A common problem in patients with liver diseases is the development of ascites.¹ Ten years after the diagnosis of liver cirrhosis, more than half of the patients will develop ascites. This reduces the survival rate dramatically.¹ In the Western world, alcohol abuse and hepatitis are the most common causes for ascites. Other diseases can also cause ascites, but they are less common.¹

The first line therapy for ascites is the restriction of sodium intake and diuretic treatment. Many patients profit from a transjugular intrahepatic portosystemic shunt (TIPS) in cases with elevated portal venous pressure.¹ International guidelines recommend a (single) large volume abdominal paracentesis for patients with failure of the aforementioned first line treatment.^{1,2} Another method is the continuous

drainage of ascites over a period of 72 h.³ This therapy is recommended for patients with compromising ascites that is resistant to diuretic treatment.³ Other authors have described the possibility of using permanent ascites drains in patients with advanced cancer.⁴ However, in our presented case, long-term drainage of ascites was performed in a patient with liver cirrhosis.

Case Report

We present the case of a 66-year-old male patient with alcoholic liver cirrhosis and ascites who was transferred from a small hospital to our institution, which is a tertiary referral center for liver diseases due to clinical deterioration. Eight days earlier a catheter had been inserted into the abdominal cavity for permanent drainage of ascites.

The patient developed spontaneous bacterial peritonitis during his hospital stay in our institution. Antibiotic therapy was started, and the inserted catheter for permanent drainage of ascites needed to be removed or exchanged. Transcutaneous removal of the catheter failed due to massive pain attacks during gentle attempts of pulling at the catheter, and the physician noticed a resistance. This was the 22nd day after insertion of the catheter. After another frustrating attempt to remove the catheter, we decided to perform a median laparotomy for surgical removal of the catheter and the patient was taken to the operating theater.

Intraoperatively, an adhesion of the ascites drain (a basket catheter) to the mesentery very close to the small intestine was found, approximately -50 mm distal of the ligament suspensorium duodeni (ligament of Treitz). To our surprise, we found a plastic catheter that is designed to drain infections. The shape of the catheter fits to a plastic 'basket drain'. We removed the adhesion between the catheter and the mesentery (Figs. 1–4), removed the catheter, placed a new surgical drain and finished the operation.

Twelve days after the operation, the patient developed a rupture of the abdominal fascia suture, probably caused by massive amounts of ascites. We performed a second operation and closed the abdominal wall. After this second operation, the patient was treated at the intensive care unit and the chronic liver failure decompensated, leading to massive amounts of ascites, hepatorenal syndrome type I and hepatic encephalopathy. Unfortunately, the patient died six days after the second operation.

Discussion

The treatment of liver cirrhosis is standardized, as is the indication for paracentesis.² This can be done with single

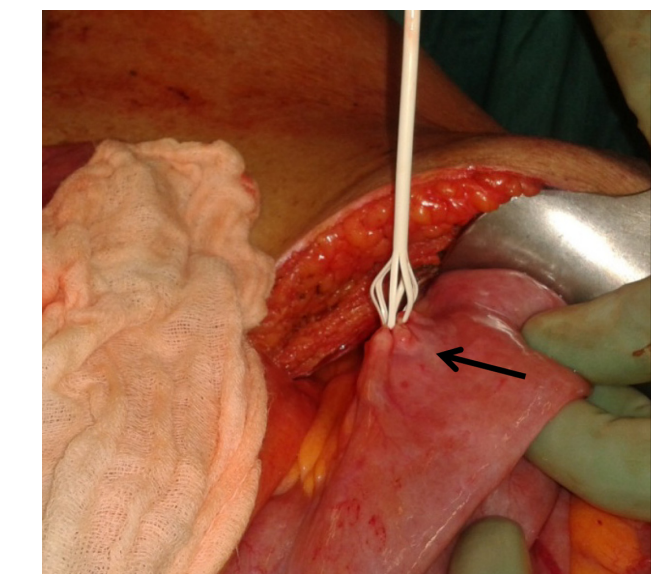


Figure 2. Detail picture of the adhesion (arrow).

large-volume paracentesis (first line) or a slower removing of the fluid for a few days with continued drainage.^{2,3} However, in our presenting case the drain was inside the abdomen for more than three weeks (date of the first operation) and the used catheter was designed to drain infections and not ascites. The adhesion of the catheter at the mesentery, close to the small intestine, caused a lot of discomfort to the patient. The basket catheter inside of the abdomen, with bacterial peritonitis developed concurrently, could not be removed conventionally and the resulting operations dramatically reduced the survival chances of the patient.^{5,6} It is known that abdominal surgical procedures increase the risk for severe complications in patients with liver cirrhosis.⁶ These complications can include rupture of the abdominal fascia suture and decompensation of chronic liver disease with production of massive amounts of ascites, hepatorenal syndrome type I and encephalopathy

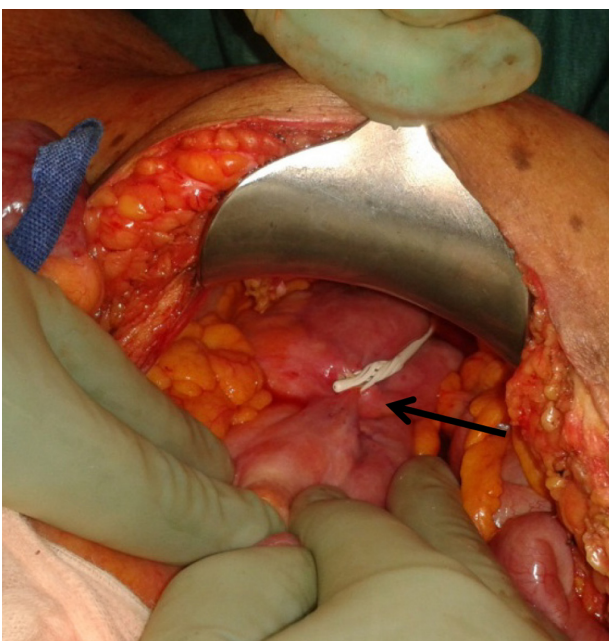


Figure 1. Median laparotomy (arrow: adhesion of the drain).

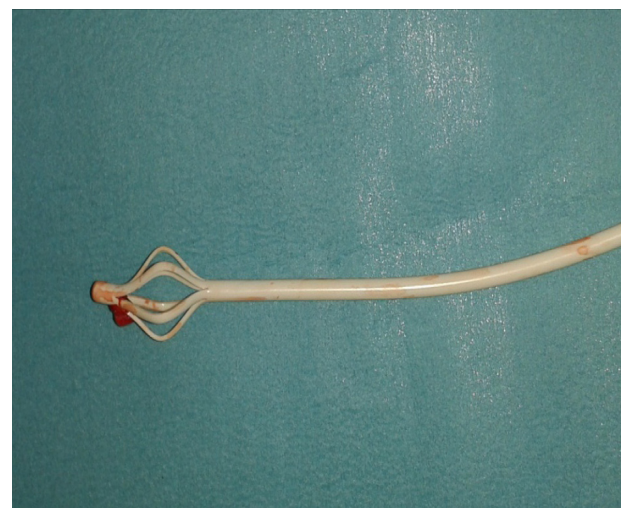


Figure 3. Removed drain.

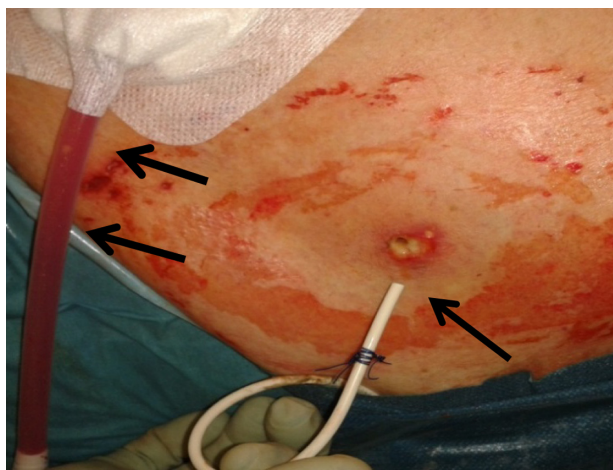

Figure 4. Removed drain (right side, one arrow) and newly placed surgical drain (left side, two arrows).

like in the presented case.⁶ The patient died six days after the second operation.

A single large volume paracentesis can be done without the insertion of a permanent catheter.¹ In cases that require permanent drainage of ascites, we prefer the use of pigtail catheters and not basket catheters, which are primarily designed to drain infections. Moreover, another alternative and widely accepted method for permanent drainage of ascites is the implantation of catheters originally designed for peritoneal dialysis. These catheters are placed by a mini laparotomy into the pouch of Douglas or Proust space. A subcutaneous exit channel prevents catheter infections in most cases. A similar and comparatively new method to drain ascites permanently is realized with the alpha pump.⁷ With this method the pump is implanted subcutaneously and the ascites is drained from the abdominal cavity into the bladder with minimal risk of subsequent bacterial peritonitis.⁷

Conclusion

Ascites caused by liver cirrhosis is a common problem. The application of paracentesis is well-established in international

guidelines. The indication for the use of the correct percutaneous catheter for permanent paracentesis should be carefully considered. Some catheters are obviously not suited to drain ascites and may lead to fatal outcomes.

Author Contributions

Conceived the concept: BK. Analyzed the data: BK, GG. Wrote the first draft of the manuscript: BK. Contributed to the writing of the manuscript: BK. Agree with manuscript results and conclusions: GG, HS. Jointly developed the structure and arguments for the paper: BK, HS. Made critical revisions and approved final version: HS, JK. All authors reviewed and approved of the final manuscript.

DISCLOSURES AND ETHICS

As a requirement of publication the authors have provided signed confirmation of their compliance with ethical and legal obligations including but not limited to compliance with ICMJE authorship and competing interests guidelines, that the article is neither under consideration for publication nor published elsewhere, of their compliance with legal and ethical guidelines concerning human and animal research participants (if applicable), and that permission has been obtained for reproduction of any copyrighted material. This article was subject to blind, independent, expert peer review. The reviewers reported no competing interests.

REFERENCES

1. Kuiper JJ, van Buuren HR, de Man RA. Ascites in cirrhosis: a review of management and complications. *The Netherlands Journal of Medicine*. 2007;(65)8: 283–7.
2. Ginès P, Cárdena A, Arroyo V, Rodés J. Management of Cirrhosis and Ascites. *New England Journal of Medicine*. 2004;350:1646–54.
3. Van Thiel D, Moore CM, Garcia M, George M, Nadir A. Continuous Peritoneal Drainage of Large Volume Ascites. *Dig Dis Sci*. 2011;56:2723–7.
4. Mercadante S, Intravaia G, Ferrera P, Villari P, David F. Peritoneal catheter for continuous drainage of ascites in advanced cancer patients. *Support Care Cancer*. 2008;16:975–8.
5. Ginès P, Schrier RW. Renal Failure in Cirrhosis. *New England Journal of Medicine*. 2009;361:1279–90.
6. Nicoll A. Surgical risk in patients with cirrhosis. *Gastroenterology and Hepatology*. 2012;27:1569–75.
7. Bellot P, Welker MW, Soriano G, et al. Automated low flow pump system for the treatment of refractory ascites: A multi-center safety and efficacy study. *Journal of Hepatology*. 2013;58:922–7.