



Echocardiographic assessment of mitral regurgitation: discussion of practical and methodologic aspects of severity quantification to improve diagnostic conclusiveness

Andreas Hagendorff¹ · Fabian Knebel² · Andreas Helfen³ · Stephan Stöbe¹ · Dariush Haghi⁴ · Tobias Ruf⁵ · Daniel Lavall¹ · Jan Knierim⁶ · Ertunc Altioek⁷ · Roland Brandt⁸ · Nicolas Merke⁶ · Sebastian Ewen⁹

Received: 27 December 2020 / Accepted: 8 March 2021 / Published online: 11 April 2021

© The Author(s) 2021

Abstract

The echocardiographic assessment of mitral valve regurgitation (MR) by characterizing specific morphological features and grading its severity is still challenging. Analysis of MR etiology is necessary to clarify the underlying pathological mechanism of the valvular defect. Severity of mitral regurgitation is often quantified based on semi-quantitative parameters. However, incongruent findings and/or interpretations of regurgitation severity are frequently observed. This proposal seeks to offer practical support to overcome these obstacles by offering a standardized workflow, an easy means to identify non-severe mitral regurgitation, and by focusing on the quantitative approach with calculation of the individual regurgitant fraction. This work also indicates main methodological problems of semi-quantitative parameters when evaluating MR severity and offers appropriateness criteria for their use. It addresses the diagnostic importance of left-ventricular wall thickness, left-ventricular and left atrial volumes in relation to disease progression, and disease-related complaints to improve interpretation of echocardiographic findings. Finally, it highlights the conditions influencing the MR dynamics during echocardiographic examination. These considerations allow a reproducible, verifiable, and transparent in-depth echocardiographic evaluation of MR patients ensuring consistent haemodynamic plausibility of echocardiographic results.

✉ Andreas Hagendorff
Andreas.Hagendorff@medizin.uni-leipzig.de

¹ Department of Cardiology, Klinik und Poliklinik für Kardiologie, University of Leipzig, Liebigstraße 20, 04103 Leipzig, Germany

² Department of Cardiology, University of Berlin, Charité Universitätsmedizin Berlin, Campus Mitte, Medizinische Klinik mit Schwerpunkt Kardiologie und Angiologie, Charitéplatz 1, 10117 Berlin, Germany

³ Department of Cardiology, Katholisches Klinikum Lünen Werne GmbH, St-Marien-Hospital Lünen, Altstadtstrasse 23, 44534 Lünen, Germany

⁴ Kardiologische Praxisklinik Ludwigshafen, Akademische Lehrpraxis der Universität Mannheim, Ludwig-Guttman-Strasse 11, 67071 Ludwigshafen, Germany

⁵ Department of Cardiology, Center of Cardiology, Heart Valve Center, University Medical Center Mainz, University of Mainz, Langenbeckstrasse 1, 55131 Mainz, Germany

⁶ Department of Cardiothoracic and Vascular Surgery, German Heart Center Berlin, Augustenburger Platz 1, Berlin 13353, Germany

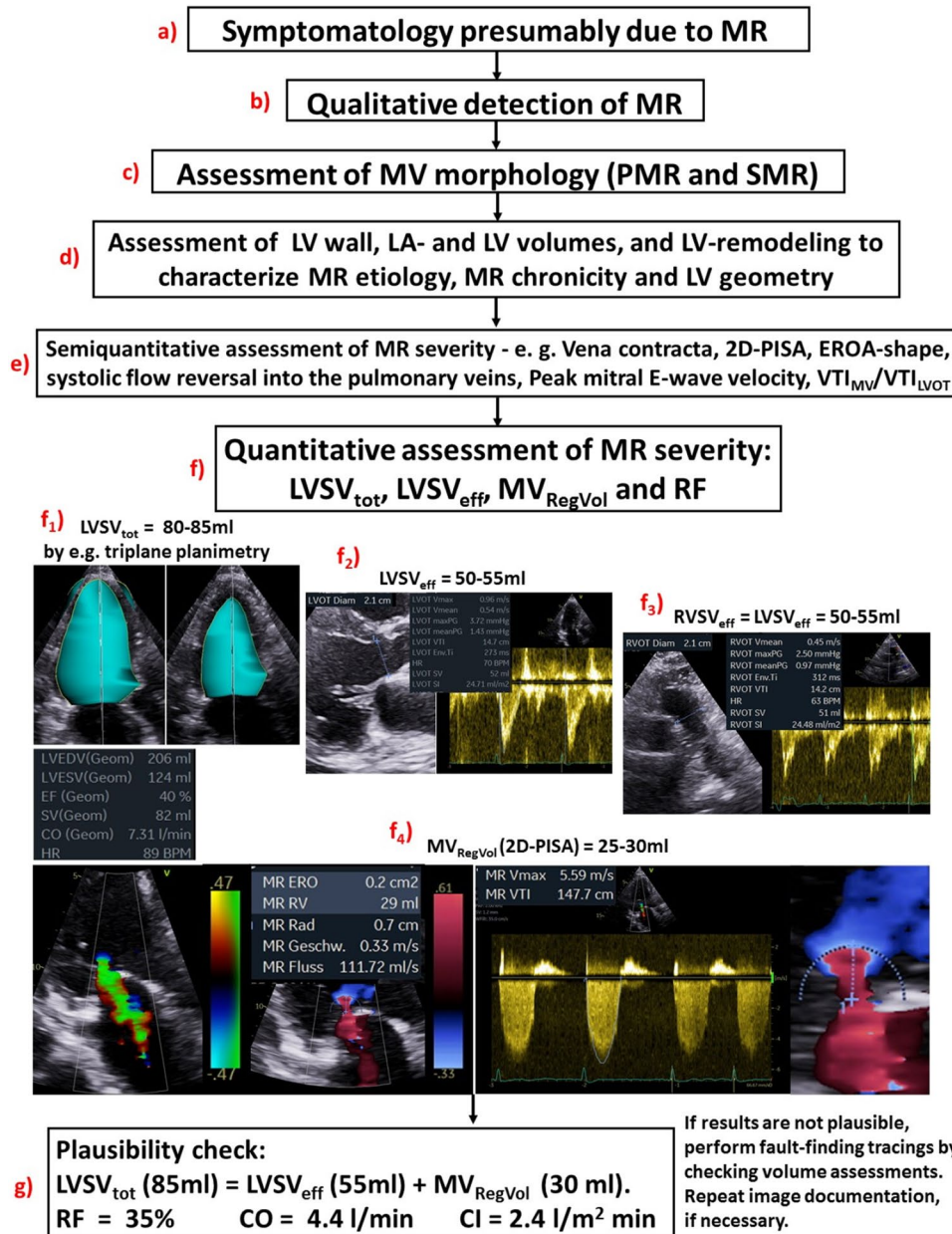
⁷ Department of Cardiology, University of Aachen, Pauwelsstrasse 30, 52074 Aachen, Germany

⁸ Department of Cardiology, Kerckhoff Heart Center, Benekestr. 2-8, 61231 Bad Nauheim, Germany

⁹ Klinik für Innere Medizin III - Kardiologie, Angiologie und Internistische Intensivmedizin, Universitätsklinikum des Saarlandes, Kirrberger Str, IMED, 66421 Homburg, Germany

Graphic abstract

Diagnostic steps to assess MR by TTE (in isolated MR)



Keywords Echocardiography · Mitral regurgitation · Quantification · Mitral regurgitant orifice area · PISA method · Regurgitant fraction

Introduction

The most frequently used tool for mitral regurgitation (MR) quantification in clinical practice is “eyeballing” of the colour flow jet area to differentiate between mild and severe MR [1]. This practice is primarily explained by its

ease of use. However, it seems inadequate to solely use a qualitative diagnostic parameter to distinguish between mild, moderate, and severe MR [2–5]. As mentioned in recent recommendations, “eyeballing” of the MR jet area is misleading [3, 5, 6]. This is caused by its variations depending on ultrasound settings (Fig. 1), the different

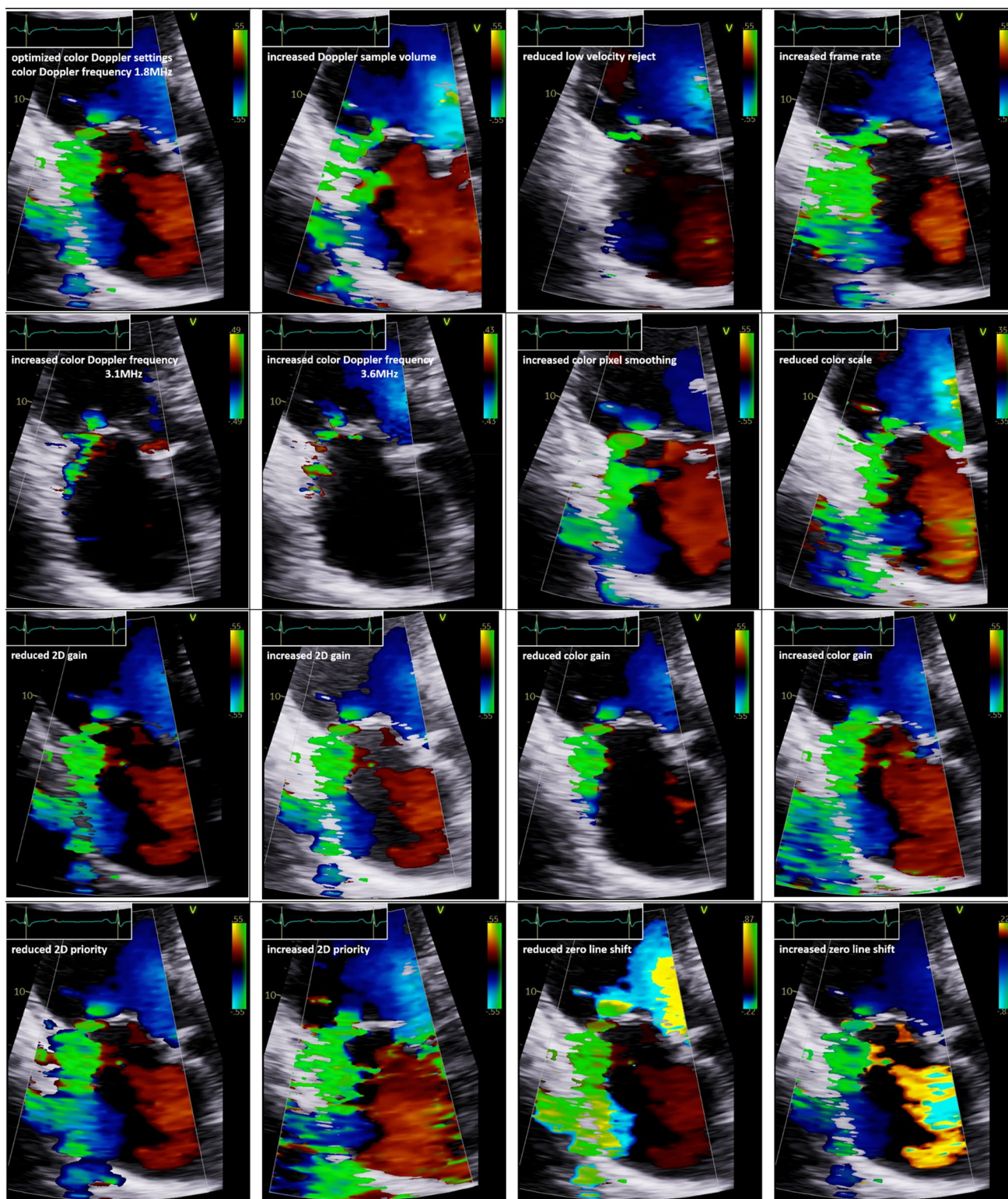


Fig. 1 The methodological factors influencing color-coded flow phenomena (PISA, VC, jet area)—illustrated by optimal colour Doppler settings with 1.8 MHz Doppler frequency, increased Doppler sample volume, reduced low-velocity reject, increased frame rate, increased

Doppler frequency with 3.1 and 3.6 MHz, increased colour pixel smoothing, reduced colour scale, reduced and increased 2D gain, reduced and increased colour gain, reduced and increased 2D priority, and reduced and increased zero line shift

display of the jet area in respective sectional planes, and the haemodynamic variations influencing MR dynamics. In consequence, recent papers had eliminated this method in the respective tables [6, 7]. The key point statements—“The colour flow area of regurgitant jet is not recommended to quantify the severity of MR. The colour flow imaging should only be used for diagnosing MR. A more quantitative approach is required when more than a small central MR jet is observed” [3]—emphasize the necessity of a definite quantitative approach for grading MR severity.

At the same time, semi-quantitative and/or quantitative parameters, such as the 2D-PISA (proximal isovelocity surface area) method, are used by a minority of primary care physicians and cardiologists [1], whereas in clinical trials, it is the most frequently used method for MR quantification [8–11].

Although recent recommendations describe the numerous limitations of the 2D-PISA method, making its use difficult, one key point message remains, namely “When feasible, the PISA method is highly recommended to quantify the severity of MR” [3]. However, the exact way of measuring of the 2D-PISA radius is unclear, as illustrated in Fig. 2. In the recent guidelines [5] “The radius of PISA is measured from the point of color Doppler aliasing to the VC (vena contracta)”. However, the 2D-PISA radius is illustrated in this recommendation [5], in the first description of the method [12], and in several other references [13] from the proximal convergence area to the ostium of the regurgitant orifice. This discrepancy is not clearly analysed in the literature [5, 13–15]—especially using modern colour Doppler technologies. Also, the impact of MR jet orientation is being debated controversially when using the 2D-PISA method. While some recommendations advise the use of the 2D-PISA in both central and eccentric jets [3, 16], others advise caution [15].

These two mainly used diagnostic features—the colour flow jet area and the 2D-PISA method—are complemented by additional semi-quantitative parameters, which eventuate in the “integrated approach” of MR quantification [3, 5, 6, 16]. However, all these semi-quantitative parameters have their limitations and can only be used in certain circumstances [13, 17–19]. A summary of the strengths and limitations of semi-quantitative parameters for grading of MR severity and the conditions when to apply or not to apply the respective parameters is particularized in Table 1. Considering the methodological challenges of the integrated approach, several concerns of semi-quantitative grading of MR severity should be considered to reduce the inter-observer variability to characterize more precisely and objectively MR severity. The dynamic nature of MR—especially with respect to loading conditions—cause a variability of MR quantification in clinical practice [20–22]. Thus,

especially in secondary MR (SMR) recommendations favour the approach of MR assessment at compensated stage [16].

The assessment of MR and the grading of its severity remain challenging today. It is the objective of this work to present tools for an in-depth analysis of the MR, taking practical, methodological, and pathophysiological aspects into consideration. To improve diagnostic conclusiveness the quantitative approach of MR assessment by determining left ventricular (LV) total and effective stroke volume ($LVSV_{tot}$, $LVSV_{eff}$), regurgitant volume at the mitral valve level (MV_{RegVol}) and regurgitant fraction (RF) is highlighted.

A proposal for a standardized workflow of the echocardiographic MR assessment

A standardized workflow during the echocardiographic examination and the patient’s visit is necessary to ensure a reproducible and verifiable MR assessment as well as documentation of treatment effects in MR patients. Patient’s characteristics and clinical parameters must be considered for therapeutic decision-making. Indexing of several echocardiographic parameters is based on body height, body weight, and surface area. Systemic blood pressure enables estimation of LV afterload. Clinical symptoms and their progression as well as alterations of echocardiographic parameters with disease progression are important to decide the necessity of therapeutic interventions. At last, age and comorbidities are not influencing MR severity, but are important to estimate the individual patients’ risk. Multiple factors cause differences in MR severity in the same patient at different time points, e.g., cardioversion of atrial fibrillation (AF) into sinus rhythm, resynchronisation therapy in patients with left bundle branch block (LBBB), optimized medical treatment (OMT) in heart failure, or revascularization in myocardial ischemia. To ensure comparability of echocardiographic investigations MR assessment should be performed according to recent recommendations at compensated stage [16].

The echocardiographic examination should consider and interpret the clinical symptoms, and the individual patient’s factors in relation to the presumed valvular defect (Figs. 3, 4). After qualitative MR detection by Doppler techniques, the next diagnostic steps by echocardiography should be the assessment of mitral valve (MV) morphology, LV wall thickness, left atrial (LA), and LV volume as well as LV shape and remodelling, prior to grading MR severity (Figs. 3, 4). Thereafter, a semi-quantitative MR assessment is advised, which should be followed by a quantification of MR severity, if moderate or severe MR is being suspected, or if severity of MR remains unclear (Fig. 4). Every changes of MR severity documented by repetitive standardized echocardiography should be noted to enable reliable conclusions about the respective treatment effects. Figure 5 depicts a

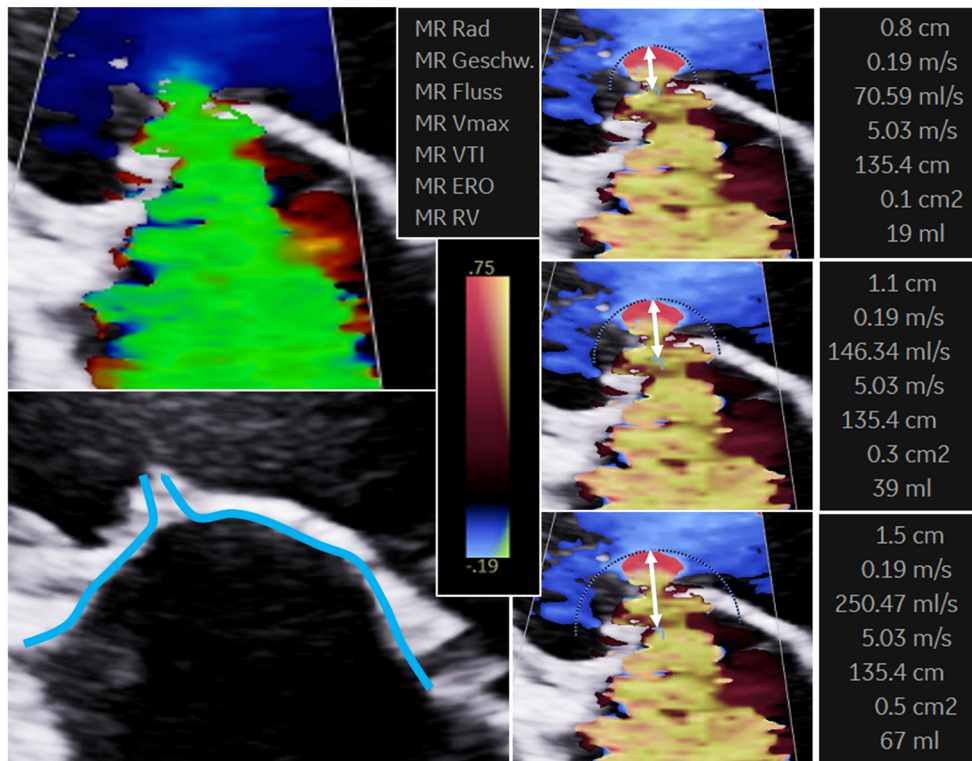
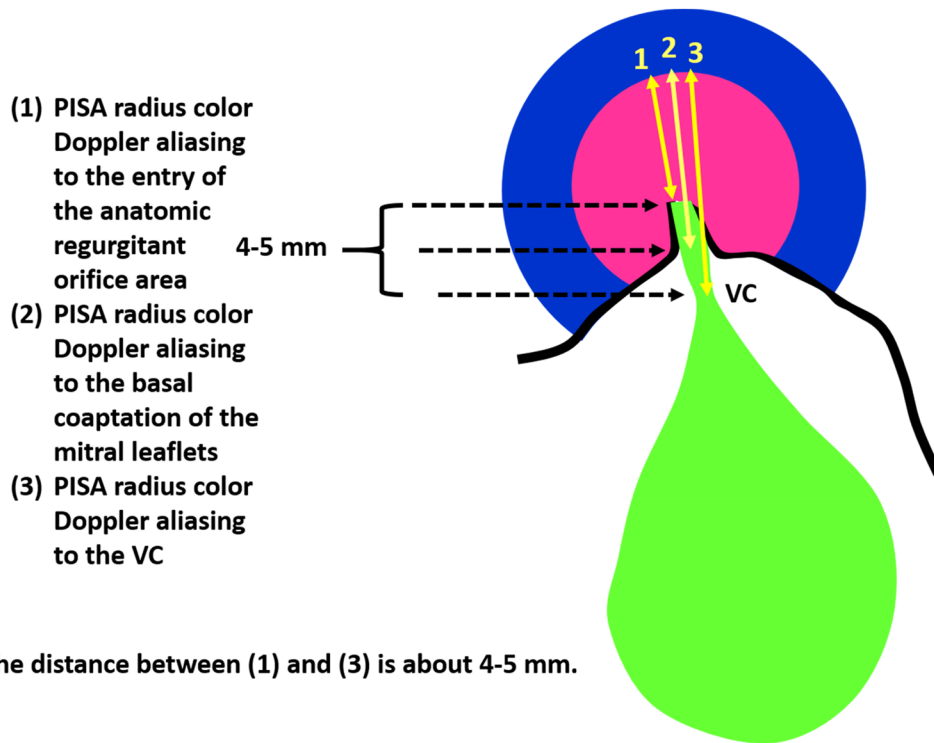


Fig. 2 Limitations of the 2D-PISA method (PISA radius= r)—scheme of the proximal convergence areas and the proximal regurgitant flow phenomenon through the regurgitant orifice illustrating the importance of the accurate definition of the 2D-PISA radius.

Example of regurgitant volume (MV_{RegVol}) assessment using different 2D-PISA radii with equal velocity time integrals of regurgitant velocities ($r=8$ mm, $MV_{RegVol}=19$ ml; $r=11$ mm, $MV_{RegVol}=39$ ml; $r=15$ mm, $MV_{RegVol}=67$ ml)

Table 1 Strengths, and limitations of the semi-quantitative parameters for grading MR severity focusing when to use or not to use the respective parameters

Semiquantitative parameter ^a	Strengths	Limitations	When to use or not to use
Valve morphology [3, 5, 23]	Easy to detect by TTE or TEE	Possibility of misinterpretation due to high heart rates	The only entity to imply severe MR is the rupture of a complete papillary muscle
LA and LV size [3, 5, 6]	LA and LV Enlargement are sensitive for chronic relevant MR Normal LV size excludes chronic relevant MR	Reliable results depend on standardization of sectional planes—thus, 3D volume assessment is preferred high inter-observer variability depending on image quality	Only if delineation of endocardial contours is practically possible If necessary, contrast echocardiography is recommended Quantitative assessment of LA and LV size is not reliable performed in foreshortening views and, if limited image quality is present
Vena contracta size [17, 18])	Easy to use, relatively independent of hemodynamic factors	Dependent on ultrasound settings, e.g., smoothing, low-velocity reject, 2D and color gain, etc. error-prone for eccentric jets	Mostly applicable in central jet formations using the parasternal long axis view Not reliable in the presence of eccentric jets especially in primary MR and in the region of the medial or lateral commissure if oblique sectional planes of the vena contracta (not perpendicular to the defect) are documented
2D-PISA-EROA; 2D-PISA-RegVol _{MV} size [3, 5, 6]	Possible to quantitatively assess EROA (lesion severity) and Reg Vol _{MV} with respects to methodologic accuracy	Underestimation of EROA and RegVol _{MV} by the elliptical shape of EROA Overestimation by improper labeling of the PISA radius PISA elongation by constrained flow field or eccentric jets, and by the dynamic nature of the MR Very limited if applied in eccentric jets—even using angle correction; limited by error-proneness of the PISA radius detection. Thus, high inter-observer variability	Only broadly applicable in central jet formation with flat PISAs (mostly to be observed in SMR Carpenter type 1 in patients with reduced LV function) Not applicable in eccentric PISAs (eccentric jet formation) and in elevated parabolic PISAs (constrained flow patterns) Not usable in multiple MR jets Non-applicable in late systolic dynamic MR (primary MR)
Shape of the EROA by 2D- and 3D-echocardiography size [24–26]	Applicable to detect individual changes of EROA using TEE Semilunar shape of EROA predictable for moderate or severe MR	Difficult to standardize the EROA in just one sectional plane due to its 3-dimensional shape—even using 3D techniques dependent on pixel size and ultrasound settings, not well validated in the literature	Only applicable in TEE; applicable to document individual changes of EROA in relation to hemodynamic factors Applicable to document acute treatment effects during intervention or surgery, diagnostic conclusiveness is limited by TTE color Doppler due to low spatial and temporal resolution Interpretation of EROA shape in TTE is very error-prone

Table 1 (continued)

Semiquantitative parameter ^a	Strengths	Limitations	When to use or not to use
Systolic flow reversal into the pulmonary veins size [27]	Simply to use and—if detectable—specific for severe MR	Dependent of flow direction of the regurgitant jet, on LA size and LA function, on LV contractility, and on hemodynamic factors as well as heart rhythm	Only well applicable, if sinus rhythm is present, if regurgitant jet enters the right pulmonary veins in TTE, and the left pulmonary veins in TEE, if LA size is normal or only mildly enlarged, and if LV contractility is normal or mildly reduced Thus, not applicable in severely enlarged LA, in severe LV dysfunction and during atrial fibrillation
Intensity of the regurgitant velocity signal using continuous wave (cw) Doppler and cw-jet profile size [3, 5, 6]	Easy to document and to interpret A triangular cw-jet profile indicates relevant MR severity	The regurgitant flow velocities should be recorded during the complete systole, that implies correct Doppler delineation during the complete heart cycle	The interpretation and jet profile can only be interpreted if acquisition of the cw-spectrum is methodically correct Thus, this method is only accepted as qualitative parameter due to its methodologic limitations [3, 5] Not applicable, if cw-alignment with blood flow is not verified, especially in eccentric regurgitant jets Proper Doppler alignment is almost always feasible by TTE
Peak mitral E-wave velocity, peak mitral A-wave velocity size [6]	Easy to document by transmitral pulsed wave (pw) Doppler V _{max} of E wave < 1 m/s often indicates non-relevant MR Increased A-wave excludes relevant MR	The correct interpretation depends on correct position of pw-sample volume Atrial fibrillation	Applicable, if the orifice area of the mitral valve is normal, if mitral annulus diameter is normal (a.p.-diameter < 35 mm) Limited diagnostic value in atrial fibrillation and severe diastolic dysfunction Not applicable in mitral stenosis Not applicable in severe mitral annulus dilatation
The ratio of transmitral velocity time integral (VTI _{MV}) and flow velocity time integral within the LV outflow tract (VTI _{LVOT}) (VTI _{MV} /VTI _{LVOT}) size [3, 28]	Easy to determine using pw-Doppler spectra	Diagnostic value depends on the accuracy of the positions of the sample volumes, which should be located at the tip of the MV leaflets and in the LYOT considering optimal alignment of the ultrasound beam with blood flow	Only applicable, if mitral annulus is not severely dilated and normal mitral valve morphology, leak-tight aortic valve and/or atrial fibrillation is present Thus, not applicable in severe mitral annulus dilatation, in mitral stenosis, and in aortic regurgitation Error-prone in atrial fibrillation

^aMorphological parameters like papillary muscle rupture, LA and LV size, as well as the semi-quantitative parameters vena contracta, 2D-PISA-EROA and 2D-PISA-MV_{RegValv}, the shape of the EROA, systolic flow reversal into the pulmonary veins, intensity of the regurgitant velocity signal using continuous wave Doppler and the jet profile, peak mitral E- and A-wave velocity, and the ratio of transmitral velocity time integral (VTI_{MV}) and flow velocity time integral within the LV outflow tract (VTI_{LVOT}) (VTI_{MV}/VTI_{LVOT}) are introduced

^aThe color Doppler jet area is not listed in the table of semi-quantitative parameters, because this parameter is solely useful for the qualitative detection of a mitral regurgitation, but is not recommended for grading the MR severity (Lancellotti et al. 2010 and 2016). Specific types of jet morphology, e.g., Coanda phenomenon, explain the defect morphology and give cause for quantitative assessment of MR severity

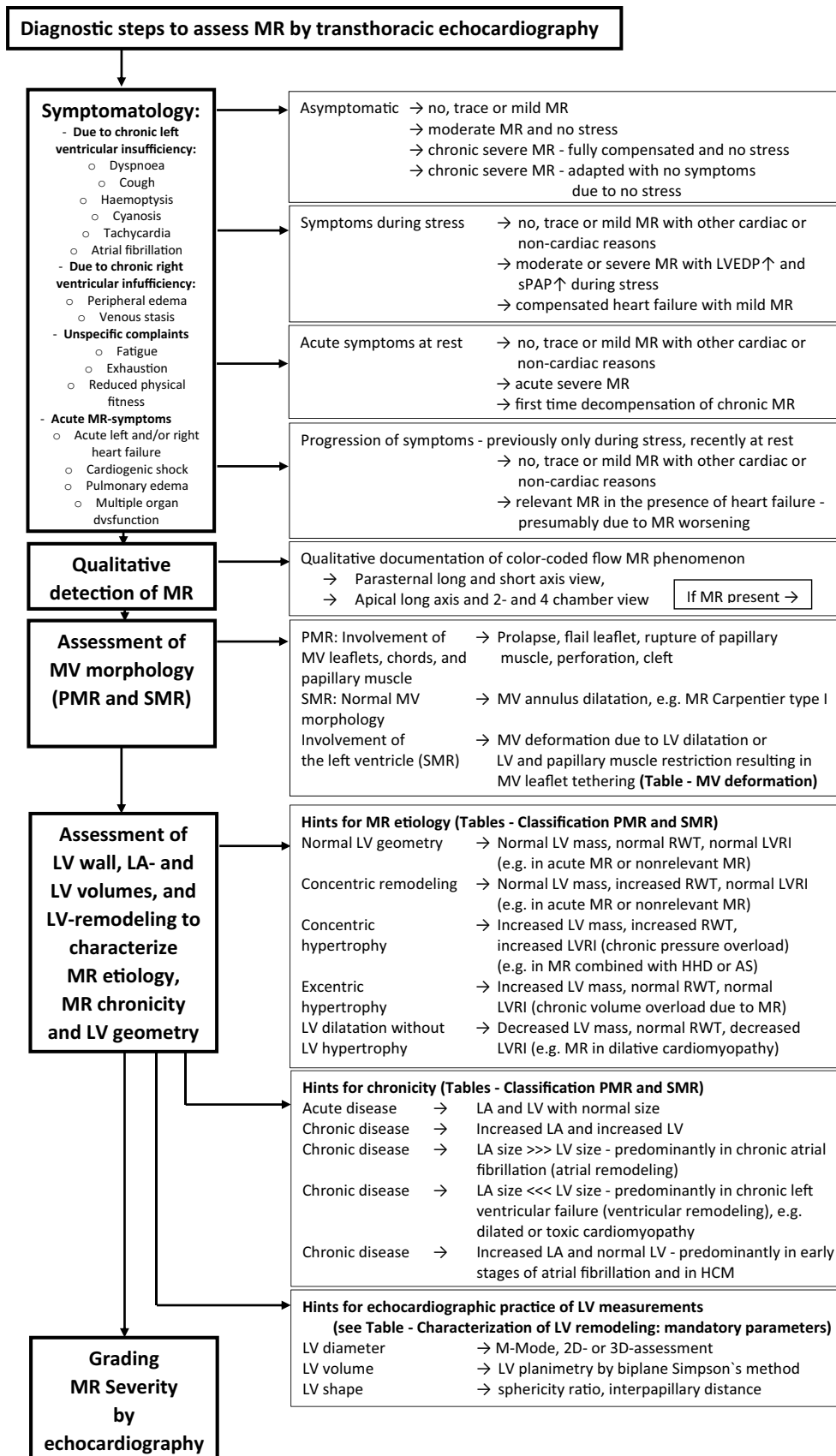


Fig. 3 Scheme to illustrate the diagnostic steps to assess MR by TTE: The first step includes the interpretation of clinical symptoms and the chronicity of the underlying disease in the context of MR with different severity. The second step is the qualitative detection of MR. The third step is the analysis of MV morphology and the differentiation between PMR and SMR. The fourth step is the assessment of LV wall, LA- and LV volumes as well as LV size and LV remodelling to get insights into MR etiology, MR chronicity, and LV geometry. The last step is the grading of MR severity. *HOCM* hypertrophic cardiomyopathy, *LA* left atrial, *LV* left ventricular, *LVEDP* LV end-diastolic pressure, *LVRI* LV remodelling index, *MR* mitral regurgitation, *MV* mitral valve, *PMR* primary MR, *RWT* relative wall thickness, *SMR* secondary MR, *sPAP* systolic pulmonary arterial pressure

recommended timeline for performing echocardiographic examinations in patients with significant MR who are considered for interventional/surgical treatment of MR.

The rationale for the stepwise workflow to assess MR severity to implement the causal relationships between clinical complaints, disease progression, and echocardiographic characteristics into the “integrated approach”

Identifying a causal relationship between clinical symptoms and MR might facilitate the interpretation of echocardiographic results in MR patients. However, symptoms as well as echocardiographic findings depend on chronicity of the disease progress. Acute MR is normally linked to severe symptoms, smaller LA and LV cavities, and severe PH, whereas chronic MR is linked to mild symptoms, larger LA and LV cavities, and different secondary PH severity. Due to this pathophysiological complexity, all possible morphologic variations of LA and LV size can be observed in clinically relevant MR.

If MR is qualitatively detected by Doppler techniques—e.g., colour flow Doppler—MV morphology should help differentiating between primary MR (PMR) and secondary MR (SMR) [29]. This classification focusses on morphological defects of the MV apparatus (PMR) and on secondary MV alterations induced by underlying LV diseases. Thus, structural involvement of the MV apparatus characterizes PMR and LV dilatation and/or LV dysfunction SMR. Pathologies of the leaflets or alterations of the intricate anatomy of the MV apparatus are causes of PMR, failure of MV leaflet coaptation due to MV annulus dilatation, increased leaflet tethering, and/or papillary muscle (PM) restriction are causes of SMR [3–6, 30, 31]. Furthermore, Carpentier’s classification scheme according to leaflets mobility [32] considers functional aspects of the MV leaflets.

The pathophysiological understanding of cardiac alterations in MR requires a morphological characterization of the cardiac cavities [3–6, 16]. Both, PMR and SMR, impose

a volume load on the left ventricle and the left atrium. LV dilatation increases MV tethering forces, while LV dysfunction reduces MV closing forces, both driving factors of SMR [33]. SMR resulting from predominant mitral annular dilatation is increasingly being recognized as SMR induced by atrial remodelling [34]. The volume load in chronic PMR and SMR further aggravates LV dilatation to accommodate for the MV_{RegVol} and to maintain $LVS_{V_{eff}}$. LV function is preserved in the compensated state in PMR, but declines in a decompensated condition. In the decompensated state, MV_{RegVol} itself is a pathophysiological driver that contributes to the disease progress with concomitant increase of LV end-diastolic pressure (LVEDP) and secondary pulmonary hypertension (PH) [35, 36]. LV ejection fraction (LVEF) overestimates LV function in MR. Forward $LVEF = LVS_{V_{eff}}/LV$ end-diastolic volume (LVEDV) seems to represent more reliably LV function than global LVEF in MR [37, 38]. Hence, MR severity relative to LV remodeling has been proposed [16, 39, 40]. In consequence, LV function, LV remodelling, and global haemodynamics often differ between PMR and SMR. Thus, LV wall thickness, LV mass, LV mass index, LV diameter, LV volume, LVEF, as well as LA volume and LA volume should be measured by echocardiography to characterize LV geometry, e.g., concentric remodelling, and concentric and eccentric LV hypertrophy [41]. Relative wall thickness (RWT) and LV mass should be measured using the posterior wall. Considering clinical symptoms and chronicity of the underlying diseases in relation to the specific echocardiographic findings, an extended MR classification is proposed for PMR and SMR patients. Five subtypes can be differentiated in PMR (Table 2). Furthermore, seven subtypes can be differentiated in SMR (Table 3) with respect to symmetric LV remodelling, asynchrony of LV contraction, regional myocardial injury, asymmetric LV hypertrophy, LV stiffening, and LA remodelling [3, 5].

Thus, one target of paramount importance is to characterize cardiac remodelling due to MR effects, which implies the specific assessment of LV [43–45] and LA geometry by echocardiography [46]—especially in SMR patients [3, 5, 6]. Despite recent technical improvements in echocardiography and automated features to analyze LA and LV volumes and function, conventional 2D echocardiography remains the current standard and enables the assessment of relevant cardiac parameters as illustrated in Table 4. Linear internal 2D measurements of LV diameters and LV wall thickness as well as LV volume measurements by 2D planimetry are still used in clinical practice [5, 41, 47]—especially for calculation of LV mass [41]. 3D approaches for LV mass determination are preferably recommended [48]. The sphericity ratio and sphericity index, interpapillary muscle distance, the anterior–posterior and medial–lateral PM displacement, and the length between the PM bulges and the respective

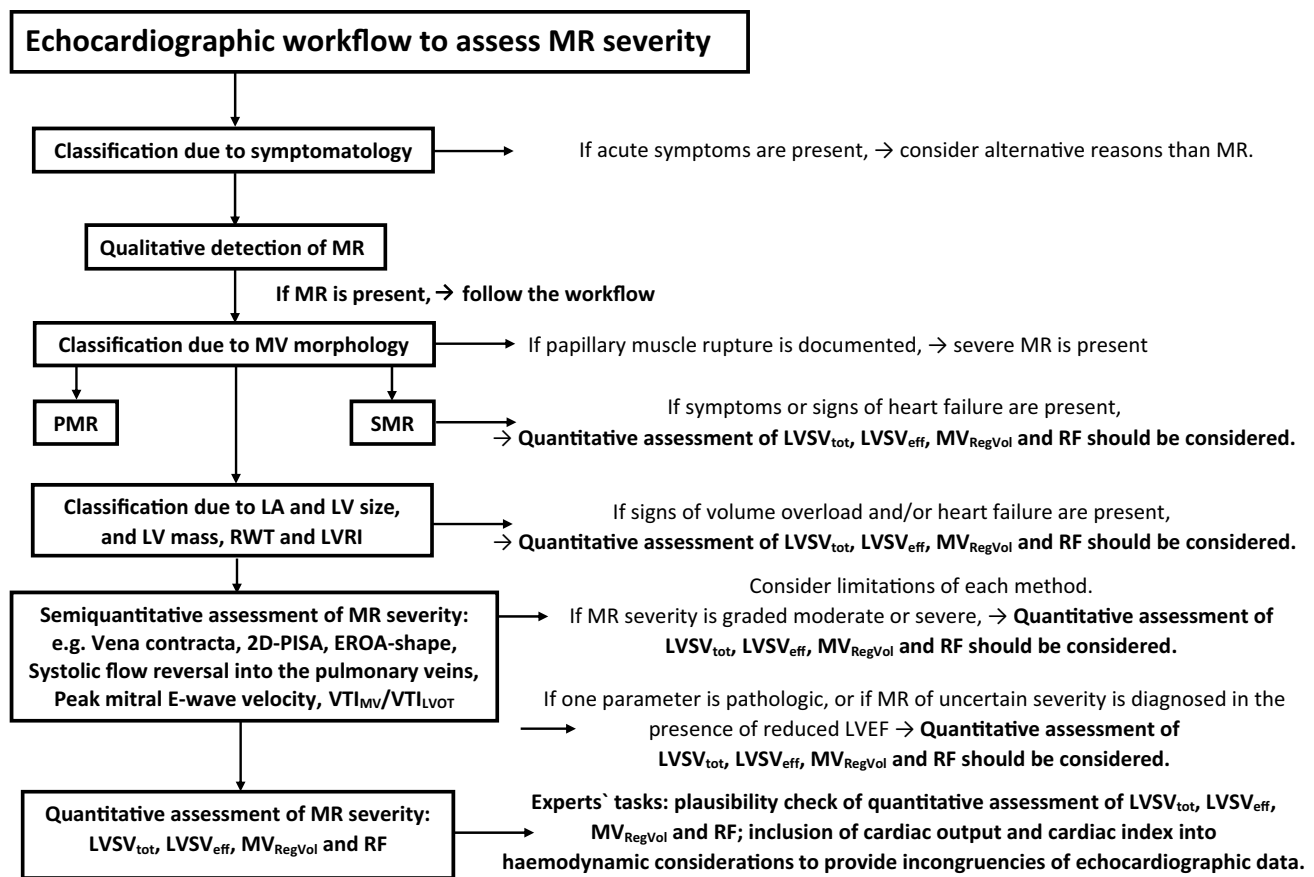


Fig. 4 Scheme to illustrate the echocardiographic workflow to assess MR severity: After interpretation of symptomatology with respect to the causal relationship to the MR qualitative MR detection results in MR classification due to the MV morphology. Echocardiographic parameters of LA and LV size and LV wall thickness characterize loading conditions and enable to distinguish between pressure or volume overload and between compensated or decompensated conditions. The assessment of MR severity starts with the integrated approach and the analysis of semi-quantitative parameters. The final experts' task of analysis of MR severity is the quantitative assessment of $LVSV_{tot}$, $LVSV_{eff}$, MV_{RegVol} , and RF as a plausibility check. At every level of the assessment of MR severity expert consultation as

well as the quantitative analysis of MR severity should be considered with respect to severe symptoms, signs of volume overload and heart failure as well as incongruent results by the grading of MR severity by the semi-quantitative approach. *2D* two-dimensional, *EROA* effective regurgitant orifice area, *LA* left atrial, *LV* left ventricular, *LVOT* LV outflow tract, *LVRI* LV remodelling index, $LVSV_{eff}$ effective LV stroke volume, $LVSV_{tot}$ total LV stroke volume, *MR* mitral regurgitation, *MV* mitral valve, MV_{RegVol} regurgitant MV volume, *PISA* proximal isovelocity surface area, *PMR* primary MR, *RF* regurgitant fraction, *RWT* relative wall thickness, *SMR* secondary MR, *VTI* velocity time integral

contralateral MV annulus should be considered for characterization of LV remodelling [3, 49–51]. Furthermore, LV remodelling with disease progression or reverse LV remodeling during treatment can be assessed by monitoring LV geometry [3, 51]. LA volume measurement by 2D planimetry of the maximum LA area in the 2- and 4-chamber view (2-ChV, 4-ChV) or using 3D echocardiography is preferred [48]. The progression of LA and LV volumes and reduction of LVEF during follow-up examinations are helpful to determine haemodynamically significant deterioration even in MR patients classified as clinically not severe.

The second target is the analysis of MV morphology by echocardiography. Due to the complexity of the MV apparatus, 3D image acquisition has become an indispensable tool

of echocardiographic MV assessment [48, 52–55]. However, conventional 2D echocardiography enables the measurement of specific parameters characterizing pathologies of MV morphology. MV degeneration can be identified by the presence of intensified echo-densities due to thickening and calcification of the MV annulus [42]. MV prolapse is characterized by systolic displacement of a leaflet by ≥ 2 mm overriding the annular plane into the LA [3, 52]. Rupture of the primary chordae, or ultimately of a PM, causes flail of the leaflet into the LA and is usually associated with severe MR. Analysis of MV involvement in endocarditis should include size of vegetations, presence of abscesses, aneurysms, or perforations [56]. Congenital MV defects, e.g., clefts, can be uncovered in the 3D TOE, favouring definitively this modern

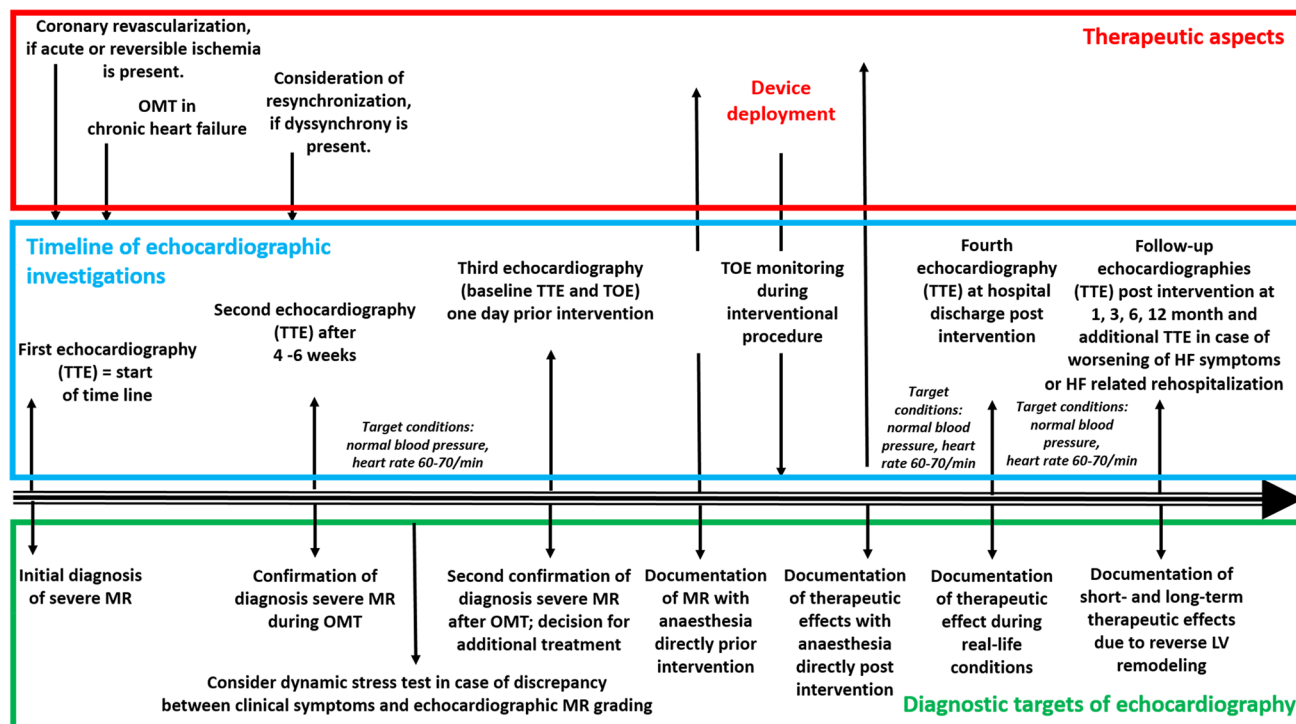


Fig. 5 Proposal for standards of echocardiographic timing in MR patients. The scheme illustrates a potential timeline of echocardiographic investigations during MR treatment. The upper red box presents the therapeutic aspects and strategies, the mid blue box presents the proposed time points of echocardiographic investigations—espe-

cially focusing on secondary mitral regurgitation (SMR)-, the bottom green box illustrates the diagnostic targets of the respective echocardiographic investigations. *LV* left ventricular, *MR* mitral regurgitation, *OMT* optimized medical treatment, *TOE* transoesophageal echocardiography, *TTE* transthoracic echocardiography

technology [55]. MV deformation due to LV remodelling in SMR should be assessed by measurement of MV annulus, coaptation distance/gap, coaptation length/height, as well as coaptation depth and tenting height (Table 5) [3, 5, 57]. The tenting area (area between the MA and the leaflets during systole) of $\geq 2.1 \text{ cm}^2$ is a pathologic finding due to tethering in SMR [3–5]. MV analysis in SMR should be completed by the assessment of the anterior/medial and posterior/posterolateral tethering angle (Table 5) [3, 5]. As pathophysiology of MR is a constant and complex interplay between initial pathology and further propagation of the disease by volume overload, coexistence between PMR and SMR can be observed and should be labeled as mixed origin.

The rationale to implement a quantitative MR assessment to characterize MR severity

The echocardiographic workflow of grading MR severity (Figs. 3, 4) starts with a semi-quantitative MR assessment and serves two goals. First, all non-severe MR should be detected, preventing unnecessary and time-consuming further evaluation. For example, when sinus rhythm is present, an a-wave dominant inflow pattern into the LV using

Doppler interrogation above the MV excludes severe MR. Also, a dominant inflow during systole from the pulmonary veins into the LA cannot be observed in severe MR. Finally, a normal LA volume is not found in chronic severe MR. These and other semi-quantitative parameters, along with their strengths, limitations, and appropriateness are listed in Table 1. In-depth quantitative evaluation should be initiated in cases if MR classification remains unclear.

The quantitative approach is based on the determination of the individual RF. This parameter is included in all current recommendations [3, 5, 6]. RF relies on the determination of LVSV_{tot} and LVSV_{eff} . The absolute value of $\text{MV}_{\text{RegVol}}$ should always be interpreted with respect to LVEDV. It is obvious that the amount of $\text{MV}_{\text{RegVol}}$ is much more important in small hearts than in larger hearts, which can be impressively illustrated by interspecies comparisons (Fig. 6). In consequence, haemodynamic conditions can be characterized by plausible LVEDV, LVEF, and LV forward stroke volume ($=\text{LVSV}_{\text{eff}}$). Determination of $\text{MV}_{\text{RegVol}}$ by the 2D-PISA method alone was associated with significant overestimation of $\text{MR}_{\text{RegVol}}$ as documented in recent transcatheter MV repair (TMVR) trials [10, 58, 59] and further MR outcome trials [60].

Table 2 Proposal to classify primary mitral regurgitation (PMR) more in detail with respect to specific echocardiographic findings, the chronicity of the underlying diseases, and the clinical complaints of the patients

	Subtype of PMR	LV size	LV wall thickness	LA size	Course of the disease	Complaints	Echocardiographic example
PMR	involvement of the MV apparatus or MV by excess of MV tissue, e.g. Morbus Barlow, fibroelastic deficiency, connective tissue diseases [30, 31]	normally enlarged	<ul style="list-style-type: none"> normal increased LV mass due to eccentric LV hypertrophy 	normal to enlarged	a) normally chronic b) acute in complications e.g. chordae or papillary muscle rupture	a) normally mild and well compensated, development of symptoms with E/E' and sPAP increase b) severe in acute complications	
PMR	restrictive involvement of the MV apparatus due to rheumatic or other inflammatory diseases (e.g. Loeffler) [42]	<ul style="list-style-type: none"> normal or small in concomitant MV stenosis enlarged in rare cases LV at end stages 	normal	normal to enlarged	a) normally chronic b) acute in complications e.g. chordae or papillary muscle rupture	a) normally well compensated b) severe, if acute complications occur	
PMR	structural involvement of the MV apparatus due to ischemia (rupture of chords or papillary muscle) [23].	normal at early stages of the disease enlarged in chronic disease	normal or increased depending on concomitant hypertension	normal or increased	a) acute b) subacute (two-stage event)	a) severe b) severe	
PMR	structural defects of the MV apparatus or MV by endocarditis (leaflet destruction, annular abscesses, perforations) [3,5].	normal and/or depending on further underlying heart diseases	normal	normal	acute or subacute	mild to moderate to severe depending on MV destruction	
PMR	structural congenital defects of the MV apparatus or MV (e.g. clefts, parachute valve, double orifice MV) [3,5].	in adults normally enlarged	<ul style="list-style-type: none"> normal increased LV mass due to excentric LV hypertrophy 	enlarged	chronic	mild to moderate – increasing with LV remodelling	

PMR subtypes are characterized by description of left-ventricular (LV) size, LV wall thickness, left atrial (LA) size, the course of the disease, and one respective echocardiographic example

MV mitral valve, sPAP systolic pulmonary arterial pressure

Calculation of RF is based on the measurement of LVEDV and LV endsystolic volume (LVESV) as well as LVS_{eff} and MV_{RegVol} to estimate cardiac output (CO) and cardiac index (CI) by echocardiography. Practical tips to avoid pitfalls when determining cardiac volumes—especially LVS_{tot} , LVS_{eff} , and right-ventricular (RV) stroke volume (RVS_{eff}), are listed in Table 6. The practical approach to check Doppler measurements of RVS_{eff} by a plausibility cross-check is illustrated in Fig. 7. However, this concept is still not validated by prognostic data [2, 3, 5]. Compared to

cardiac magnetic resonance (CMR) tomography, a significant underestimation of LV volumes by echocardiography has been reported [63]. Furthermore, over- and underestimation of LV volumes in humans [64] and phantoms [65, 66] have been described comparing different imaging methods, e.g., native 2D- and 3D echocardiography, contrast echocardiography, CMR, and computed tomography. Recently, conclusive LV volume assessment by 2D echocardiography was illustrated if image quality is adequate [67–70]. The differences in LV volumes between 2D echocardiography

Table 3 Proposal to classify secondary mitral regurgitation (SMR) more in detail with respect to specific echocardiographic findings, the chronicity of the underlying diseases, and the clinical complaints of the patients

	Subtype of SMR	LV size	LV wall thickness	LA size	Course of the disease	Complaints	Echocardiographic example
SMR	normal MV leaflets with symmetric LV remodeling a) DCM b) NCCM c) non-infective ICM d) Infective ICM e) TAI-CM	<ul style="list-style-type: none"> LV enlargement is normally predominant in comparison to LA enlargement. LV enlargement is symmetric 	<ul style="list-style-type: none"> normal or thin increased in acute stages due to reversible edema formation, not due to LVH 	LA enlargement is depending on the chronicity of the underlying disease a) normal or mildly enlarged in DCM and NCCM b) initially normal in non-infective and infective ICM and TAI-CM	<ul style="list-style-type: none"> normally chronic in DCM and NCCM acute or subacute in non-infective and infective ICM and TAI-CM normally acute in AM 	<ul style="list-style-type: none"> severe in acute diseases mild to moderate with chronic disease progression severe in end stage chronic disease 	
SMR	normal MV leaflets with symmetric LV remodeling due to LBBB	<ul style="list-style-type: none"> LV enlargement is normally predominant in comparison to LA enlargement. LV enlargement is asymmetric 	<ul style="list-style-type: none"> normal or thin in septal LV myocardium increased postero-lateral wall thickness 	LA enlargement is depending on the chronicity of the underlying disease	<ul style="list-style-type: none"> normally chronic 	<ul style="list-style-type: none"> severe in end stage chronic disease 	
SMR	normal MV leaflets due to regional LV injury a) myocardial stunning b) LV aneurysm c) e.g. sarcoidosis	<ul style="list-style-type: none"> normally or mildly enlarged regional LV enlargement 	<ul style="list-style-type: none"> thin in acute myocardial infarction thick in edema formation thin in scars normal post early intervention 	LA enlargement is depending on the chronicity of the underlying disease	<ul style="list-style-type: none"> normally acute in stunning normally chronic in LV aneurysm and sarcoidosis 	<ul style="list-style-type: none"> severe after acute infarction mild to moderate with chronic disease progression 	
SMR	normal MV leaflets in the chronic LA and LV remodeling a) HHD b) IHD c) CHF in "pure" AS d) CHF due to chronified myocarditis	normally enlarged	<ul style="list-style-type: none"> normal or slightly increased in IHD increased in HHD and AS normal or increased (edema) post myocarditis 	normally enlarged due to the chronic course of the diseases	normally chronic	<ul style="list-style-type: none"> mild to moderate with chronic disease progression severe in end stage chronic disease 	
SMR	normal MV leaflets with predominant LA remodeling due to a) AF b) constrictive pericarditis c) mitral stenosis	normal or small	normal or increased depending on concomitant hypertension	normally enlarged	normally chronic	<ul style="list-style-type: none"> mild to moderate with chronic disease progression with systemic venous congestion severe in end stage chronic disease 	
SMR	normal MV leaflets with severe LVH (in obstructive HCM in combination with SAM phenomenon)	normal	Increased LV wall thickness – especially the subvalvular LV septum	normally enlarged due to the diastolic dysfunction	normally chronic	<ul style="list-style-type: none"> mild to moderate with chronic disease progression symptoms due to LVOT obstruction, but not due to FMR 	
SMR	normal MV leaflets with increased LV stiffness	normal or small	Increased LV wall thickness – mainly due to storage diseases	normally enlarged	normally chronic	<ul style="list-style-type: none"> mild to moderate to severe with chronic disease progression 	

Table 3 (continued)

PMR subtypes are characterized by description of left ventricular (LV) size, LV wall thickness, left atrial (LA) size, the course of the disease and one respective echocardiographic example

AF atrial fibrillation, *AM* acute myocarditis, *AS* aortic valve stenosis; *CHF* chronic heart failure, *DCM* dilated cardiomyopathy, *HCM* hypertrophic cardiomyopathy, *HHD* hypertensive heart disease, *ICM* inflammatory cardiomyopathy, *IHD* ischemic heart disease, *LBBB* left bundle branch block, *LVH* left-ventricular hypertrophy, *LVOT* left-ventricular outflow tract, *MV* mitral valve, *NCCM* non-compaction cardiomyopathy, *SAM* “systolic anterior movement”, *TAI-CM* tachyarrhythmia-induced cardiomyopathy

and CMR can be minimized by triplane, 3D-, and contrast echocardiography [71, 72]. A Doppler echocardiographic approach to calculate $LVS_{V_{tot}}$ by the LV filling volume has been proposed in recent recommendations using MV diameter in the 4-chamber view and the transmitral velocity time integral (VTI) at the level of the mitral annulus [2, 3, 5]. However, this approach seems to be error-prone due to the non-circular shape of the MV annulus.

$LVS_{V_{eff}}$ in “pure” MR can be determined by Doppler calculations using cross-sectional area (CSA) or diameters of the LV outflow tract (LVOT) and the corresponding pulsed wave (pw) Doppler velocity time integral (VTI) [2, 3, 5]. In patients with combined aortic valve disease, $LVS_{V_{eff}}$ assessment is more complex, because Doppler calculations of $LVS_{V_{eff}}$ should be performed using the CSA or diameter of the RV outflow tract (RVOT) and the respective pw-Doppler VTI to assess $RVS_{V_{eff}}$, which corresponds to $LVS_{V_{eff}}$, if no or only mild pulmonary regurgitation is present. However, $RVS_{V_{eff}}$ measurement is challenging due to the variable anatomy of the RVOT and the additional time needed for precise measurements.

The problem of incongruent haemodynamic measurements in MR patients is highlighted by the recently introduced terms “proportionate” and “disproportionate” MR [40, 73–75]. The concept of proportionality between blood flow and orifice areas can be illustrated by the continuity equation determining effective orifice area in patients with aortic valve stenosis (AS) [36, 76]. The same principle of proportionality can only theoretically be applied to the calculation of the MV_{RegVol} (Fig. 8), because MV_{RegVol} cannot be practically measured by pw-Doppler techniques due to methodological limitations. However, a plausibility cross-check of $LVS_{V_{tot}}$, $LVS_{V_{eff}}$, MV_{RegVol} , CO, and CI can be performed independently of the method used for determination of these parameters, because proportionality is a prerequisite between EROA and MV_{RegVol} . The usage of the continuity equation for MV_{RegVol} determination is impossible due to the high transmitral velocities of regurgitant flow at the level of the mitral annulus, the EROA changes of the valve during the systolic time interval, and the deceleration of flow velocities between EROA and the mitral annulus level. Because of the rheological need of proportionality

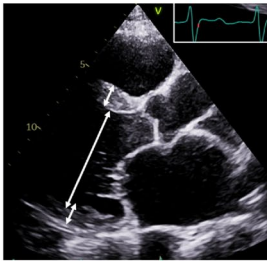
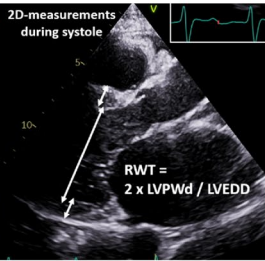
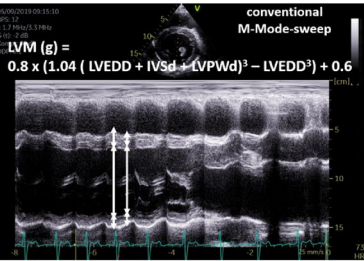
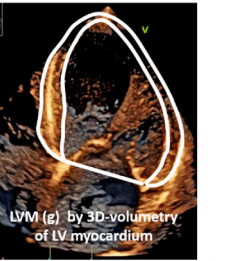
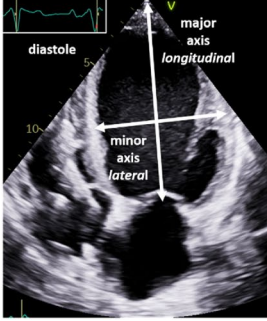

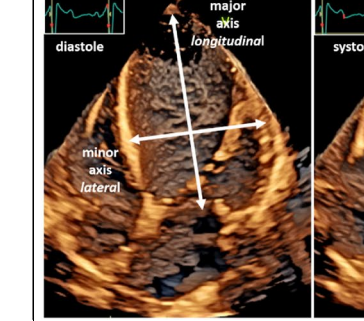
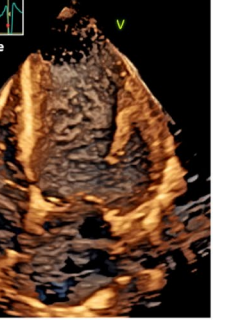

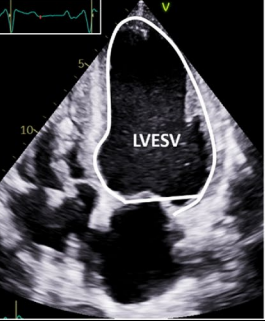
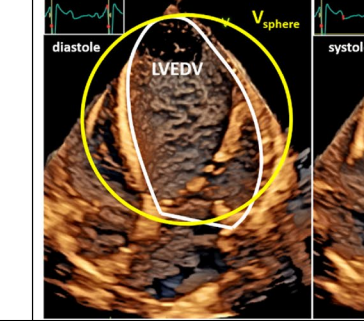
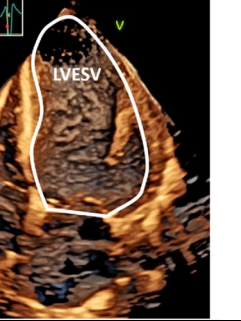
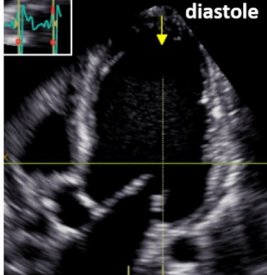
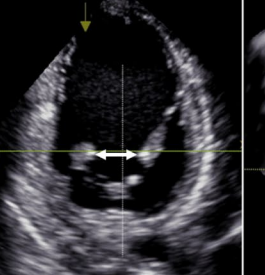
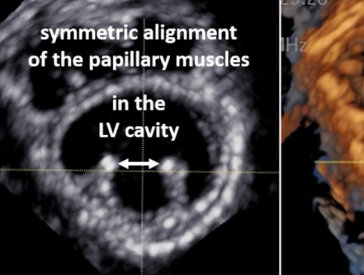
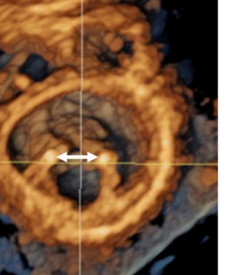
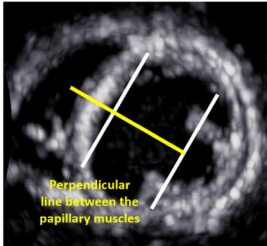
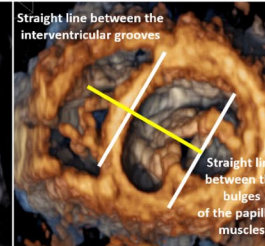
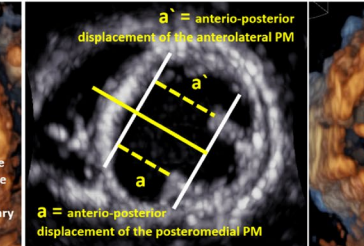
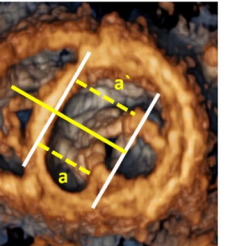
between EROA and retrograde volume flow or flow velocities, the term “disproportionateness” [40, 73–75] can only be interpreted as a characterization of SMR severity in relation to the impaired LV function. However, the potential therapeutical benefit of MR treatment in relation to heart failure cannot be described by the disproportionality between LVEDV and EROA, because these parameters are proportionally interrelated at a defined LVEF (Fig. 9).

MR severity can be assessed as mild or moderate in heart failure patients at rest during compensated stage with OMT. However, this MR characterization at rest might not describe the individual risk of re-decompensation. Thus, in these cases, haemodynamic impairment should predominantly be documented by increase in SMR severity during mild-to-moderate dynamic stress testing to support this hypothesis [77, 78]. Early treatment of SMR is comprehensible during these conditions because of the potential for reverse LV remodeling and prevention of further deterioration of LV function, which should be documented by prospective trials.

Summary and conclusion

The analysis of MR severity has become more and more important with respect to therapeutic options for MR treatment. The grading of MR severity by “eyeballing” and the 2D-PISA method is common in clinical practice, but it often leads to incongruent results with a high inter-observer variability. In addition, the dynamics of MR due to volume conditions, heart rhythm, and respective medical treatment require a high level of standardization in echocardiography. However, echocardiography allows for reliable assessment of $LVS_{V_{tot}}$, $LVS_{V_{eff}}$, MV_{RegVol} , and RF in MR patients. Prerequisites are verifiable documentations, respective technical skill, and plausible measurements. The present proposal provides a “new” haemodynamically oriented workflow, which integrates a detailed MR classification scheme, considering the clinical complaints, the chronicity of the disease process, the MV morphology, and the echocardiographic parameters characterizing LA and LV remodelling. The essential point to

Table 4 Echocardiographic parameters characterizing left-ventricular (LV) remodelling in MR patients using conventional 2D echocardiography or 3D TTE

<p>LV wall thickness - normal: <11mm LV-diameter - < 58mm (♂) < 52mm (♀)</p> <p>●</p>		<p>2D-measurements during systole</p>  <p>RWT = $2 \times \text{LVPWd} / \text{LVEDD}$</p>	<p>conventional M-Mode-sweep</p>  <p>LVM (g) = $0.8 \times (1.04 (\text{LVEDD} + \text{IVSd} + \text{LVPWd})^3 - \text{LVEDD}^3) + 0.6$</p>	 <p>LVM (g) by 3D-volumetry of LV myocardium</p>
<p>Sphericity ratio normal: major axis/minor axis > 1.5</p> <p>●</p>	 <p>diastole</p> <p>major axis longitudinal</p> <p>minor axis lateral</p>	 <p>systole</p> <p>major axis longitudinal</p> <p>minor axis lateral</p>	 <p>diastole</p> <p>major axis longitudinal</p> <p>minor axis lateral</p>	 <p>systole</p> <p>major axis longitudinal</p> <p>minor axis lateral</p>
<p>Sphericity index normal: $(\text{major axis}/2)^2 \times \pi < 0.7$</p>	 <p>diastole</p> <p>V_{sphere}</p> <p>LVEDV</p>	 <p>systole</p> <p>V_{sphere}</p> <p>LVESV</p>	 <p>diastole</p> <p>V_{sphere}</p> <p>LVEDV</p>	 <p>systole</p> <p>V_{sphere}</p> <p>LVESV</p>
<p>Interpapillary muscle distance (IPMD) normal: < 20mm</p> <p>●</p>	 <p>diastole</p>	 <p>symmetric alignment of the papillary muscles in the LV cavity</p>	 <p>symmetric alignment of the papillary muscles in the LV cavity</p>	 <p>symmetric alignment of the papillary muscles in the LV cavity</p>
<p>Anterior-posterior displacement of the papillary muscles (PM) normal: <22mm</p>	 <p>Perpendicular line between the papillary muscles</p>	 <p>Straight line between the bulges of the papillary muscles</p>	 <p>a = anterior-posterior displacement of the anterolateral PM</p>	 <p>a = anterior-posterior displacement of the posteromedial PM</p>

note is the integration of a quantitative assessment of MR severity into the recent “integrated approach” to provide

haemodynamic plausibility and to avoid inconsistencies of echocardiographic measurements.

Table 4 (continued)

<p>Medial-lateral displacement of the papillary muscles (PM) normal: <15mm</p>				
<p>length between the bulges of the posterolateral PM and the respective contralateral MV annulus (MA) normal: <40mm</p>				
<p>Length between the bulges of the anterolateral PM and the respective contralateral mitral annulus (MA) normal: <40mm</p>				

In the first column, the echocardiographic target parameters are listed including the normal ranges: LV wall thickness and relative wall thickness (RWT), LV diameter, LV mass (LVM), sphericity ratio, sphericity index, interpapillary muscle distance (IPMD), anterior–posterior and medial–lateral displacement of the papillary muscles (PM), as well as the length between the bulges of the posterolateral or anterolateral PM and the respective contralateral MV annulus (MA). The parameters recommended as mandatory [3, 5] are marked with ●. The respective images illustrate the assessment of the respective parameters in 2D sectional planes or within 3D data sets

Appendix: Conference discussion

Prof. Dr. Andreas Hagendorff (Leipzig) The “2. Mitteldeutscher Echokardiographie Kongress” in Leipzig had the thematic priority about echocardiography in MR patients at the debate “echocardiography-guided clinical trials: TMVR trials and their consequences” and the session “quantification of MR severity: a problem—which cannot or can be solved”. Due to the corona crisis, we had to communicate mostly in T-conferences during the year 2020. Thus, this year, the discussion about the topic of our expert proposal was also web-based like the congress itself in October 2020. To introduce into the following conference discussion: Please, tell us the most frequent errors assessing MR severity using the “integrative approach”?

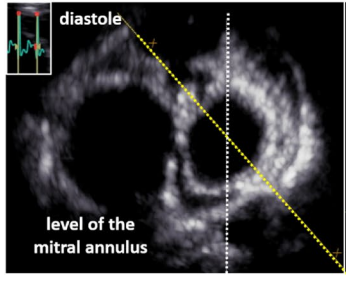
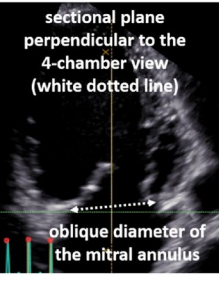
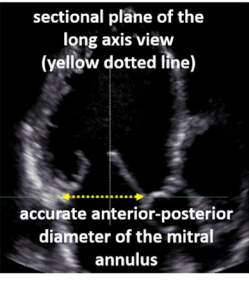
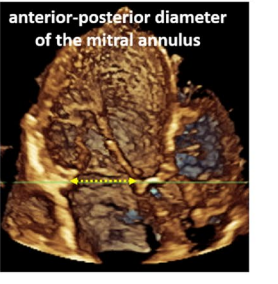
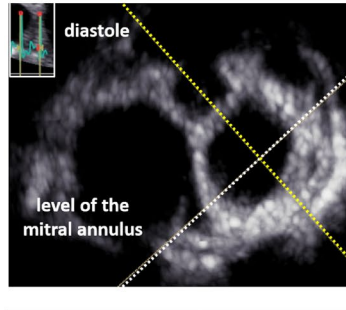
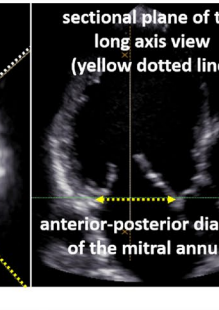
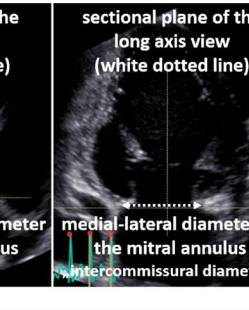

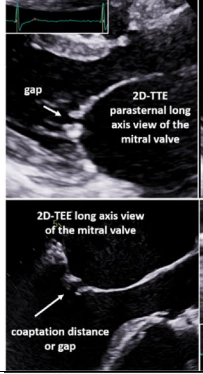
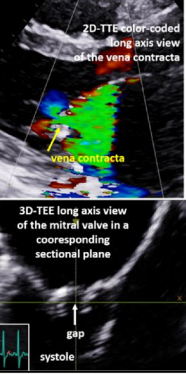
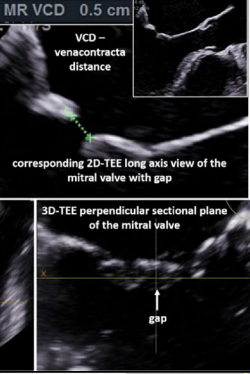
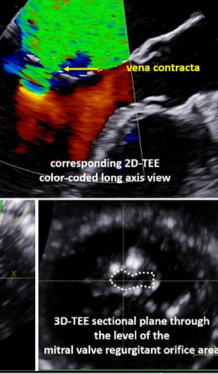
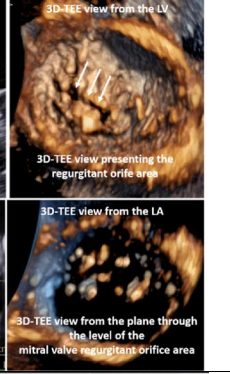
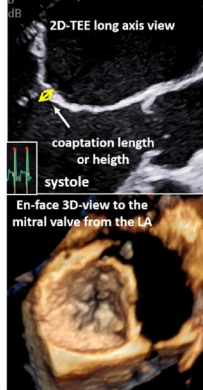
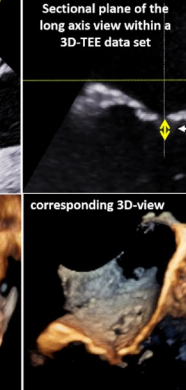

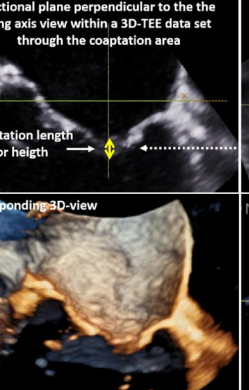
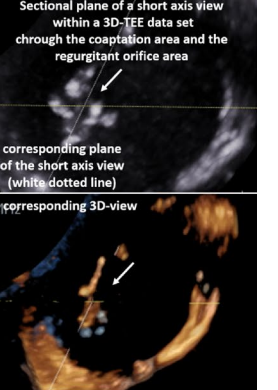
Prof. Dr. Fabian Knebel (Berlin) The most frequent error in the assessment of MR severity is the misuse of the MR jet area and its relation to the LA size. This approach is in principle inappropriate, because misinterpretation is inevitable. Further frequent errors are the use of improper images

for MR assessment anyway, and the overuse of the 2D-PISA method for all MR types irrespectively to the eccentricity of the jet formation. Several simple questions can help to scrutinize the results and to uncover misinterpretations, e.g., is a relevant chronic MR possible, if the patient has no complaints?—Is a relevant MR possible in a patient with a normal LV function, if E-wave velocity is low or A-wave velocity is high?—Is a relevant MR possible if E/E` and sPAP are normal?

Prof. Dr. Andreas Hagendorff (Leipzig) The 2D-PISA method is highly prone to errors. However, do you think the 2D-PISA method can be accepted as a reasonable approach under certain conditions? Will 3D-PISA measurements will improve the assessment of MR severity?

Dr. Jan Knierim (Berlin) Notably, only the elliptical shape of the orifice area is often mentioned as a reason for underestimation of EROA and MR_{RegVol} by the 2D-PISA-method. The multiple other factors for overestimating EROA and MR_{RegVol} , e.g., improper labeling of the PISA radius, PISA elongation by constrained flow field and eccentric

Table 5 Echocardiographic parameters characterizing mitral valve (MV) deformation in SMR patients using conventional 2D echocardiography or 3D TTE

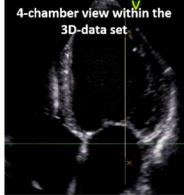
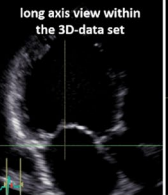
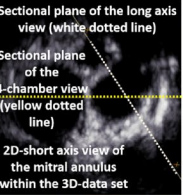
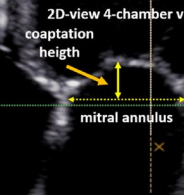
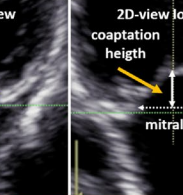

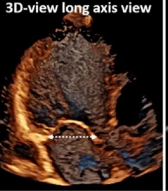

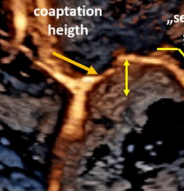
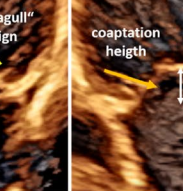
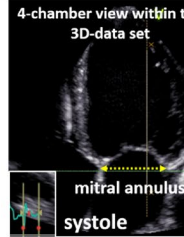
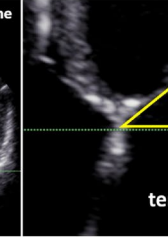
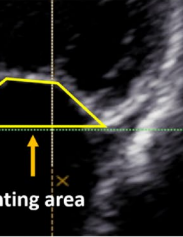
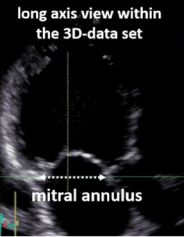
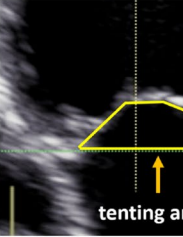
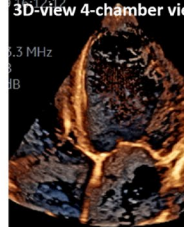
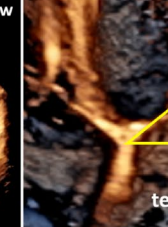
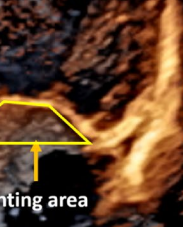
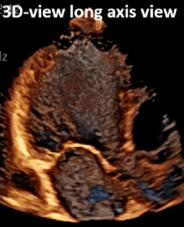
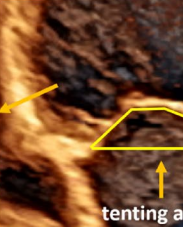
<p>Anterior-posterior mitral annulus diameter normal values: mean at end-diastole < 35mm (♂) < 32mm (♀)</p> <p>●</p>	 <p>diastole</p> <p>level of the mitral annulus</p>	 <p>sectional plane perpendicular to the 4-chamber view (white dotted line)</p> <p>oblique diameter of the mitral annulus</p>	 <p>sectional plane of the long axis view (yellow dotted line)</p> <p>accurate anterior-posterior diameter of the mitral annulus</p>	 <p>anterior-posterior diameter of the mitral annulus</p>	
<p>Medial-lateral mitral annulus diameter (intercommissural diameter) normal values: mean at end-diastole < 34mm (♂) < 31mm (♀)</p> <p>●</p>	 <p>diastole</p> <p>level of the mitral annulus</p>	 <p>sectional plane of the long axis view (yellow dotted line)</p> <p>anterior-posterior diameter of the mitral annulus</p>	 <p>sectional plane of the long axis view (white dotted line)</p> <p>medial-lateral diameter of the mitral annulus</p> <p>intercommissural diameter</p>	 <p>intercommissural diameter of the mitral annulus</p>	
<p>Coaptation distance or gap normal value: < 0</p> <p>●</p>	 <p>gap</p> <p>2D-TTE parasternal long axis view of the mitral valve</p>	 <p>2D-TTE color-coded long axis view of the vena contracta</p> <p>vena contracta</p>	 <p>MR VCD 0.5 cm</p> <p>VCD-vena contracta distance</p> <p>corresponding 2D-TTE long axis view of the mitral valve with gap</p>	 <p>vena contracta</p> <p>corresponding 2D-TTE color-coded long axis view</p>	 <p>3D-TEE view from the LV</p> <p>3D-TEE view presenting the regurgitant orifice area</p>
<p>Coaptation length or height normal range: 8-12 mm</p> <p>●</p>	 <p>2D-TTE long axis view of the mitral valve</p> <p>coaptation length or height</p> <p>systole</p>	 <p>3D-TEE long axis view of the mitral valve in a corresponding sectional plane</p> <p>gap</p> <p>coaptation length or height</p>	 <p>3D-TEE perpendicular sectional plane of the mitral valve</p> <p>gap</p> <p>coaptation length or height</p>	 <p>3D-TEE sectional plane through the level of the mitral valve regurgitant orifice area</p> <p>coaptation length or height</p>	 <p>3D-TEE view from the LA</p> <p>3D-TEE view from the plane through the level of the mitral valve regurgitant orifice area</p>

jets, dynamic nature of the MR, etc. are rarely mentioned. However, the 2D-PISA method is quite reasonable in cases of circular EROA shape and flat PISA hemispheres like in SMR Carpentier type I patients with reduced LV function and central regurgitant jet formation. 3D-PISA is a very promising tool and will obviously solve several problems of the 2D-PISA-method. Unfortunately, it is still too time-consuming at present in daily routine.

Prof. Dr. Andreas Hagendorff (Leipzig) Focusing on methodological problems by echocardiography to assess MR severity, should we provide the machine settings—especially for color Doppler images—in routine practice and/or in scientific papers due to better transparency of a verifiable documentation?

Dr. Andreas Helfen (Lünen) Considering the methodical aspects of spectral and color Doppler data acquisition, it is

Table 5 (continued)

<p>Effective height = tenting height = tenting distance normal ranges: < 4-10mm (♂) < 4-9mm (♀)</p> <p>“seagull” sign (qualitative pathological finding)</p>					
					
<p>Mitral annulus at end-systole mean value of normal ranges: < 31mm (♂) < 28mm (♀) tenting area mean value of normal ranges: < 0.6-2.1cm² (♂) < 0.6-1.7cm² (♀)</p>					
					

desirable that even in clinical practice, ultrasound settings are provided to allow insights into the quality of Doppler measurements when therapeutic options for MR patients are discussed in the heart team. Furthermore, disease progression or improvement, e.g., due to reverse LV remodeling, can be better detected comparing images with the same settings during follow-up visits. In scientific papers, the information about the machine settings should be recommended as mandatory. A second important methodological problem is linked to the measurement of the 2D-PISA radius. Although it is stated that the radius of the proximal flow convergence has to be measured “from the point of the color aliasing to the VC” [5], all studies cited in this recommendation measured the radius from the point of color aliasing to the level of the regurgitant orifice.

Prof. Dr. Andreas Hagendorff (Leipzig) Do you want to propose some ideas to provide better transparency of the echocardiographic documentation of MR by color Doppler?

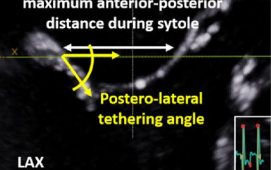
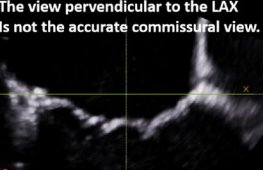
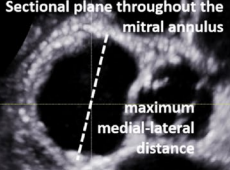
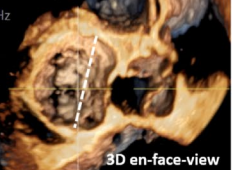
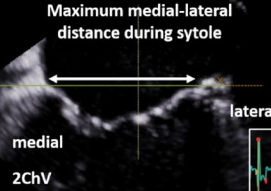
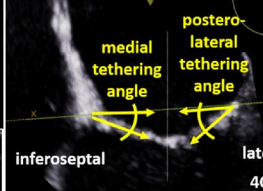

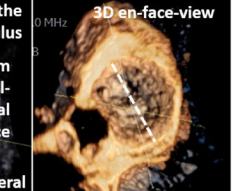
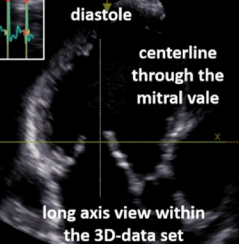
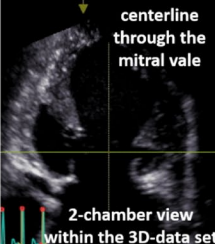
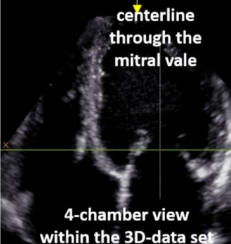
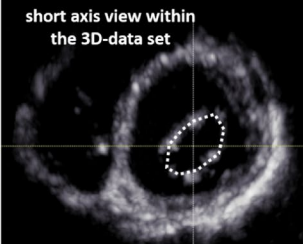
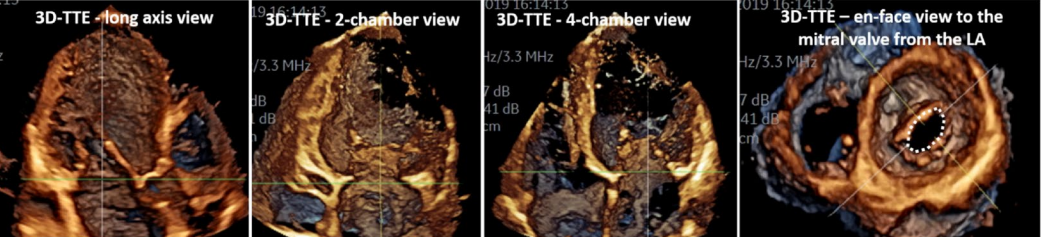
Dr. Stephan Stöbe (Leipzig) This is almost an unfair question, because it gives the impression to impose requirements on routine echocardiography. However, especially

in the scientific arena, we should aim for a higher standard. Thus, it would be desirable to illustrate—e.g., if a 2D-PISA-measurement is performed—the correlation of color-coded images to the cardiac cycle by a proper ECG documentation, to present an anatomical colored M-Mode to verify the optimal alignment of central jet formation within the cardiac cycle, to perform an adjustment of color-coded Doppler settings by comparison of the color delineation at the LVOT during systole in comparison to LV wall, and to prove the sample volume position and the cursor alignment of PW and CW Doppler spectra using duplex mode. All these documentations could be transparently displayed by image libraries in scientific papers as supplementals.

Prof. Dr. Andreas Hagendorff (Leipzig) Comparable to the previous question, how to improve the MR analysis with respect to the time-dependency within the cardiac cycle?

Prof. Dr. Dariusch Haghi (Ludwigshafen) As mentioned in the paper, dynamic MR time-dependency can conventionally be documented by colour-coded anatomical M-Mode showing alterations in PISA radii during systole. Perhaps 3D-colour-coded echocardiography will improve MR

Table 5 (continued)

<p>Posterolateral tethering angle normal range: < 30°</p>	 <p>maximum anterior-posterior distance during systole Postero-lateral tethering angle LAX</p>	<p>The view perpendicular to the LAX is not the accurate commissural view.</p> 	<p>Sectional plane throughout the mitral annulus</p>  <p>maximum medial-lateral distance</p>	 <p>3D en-face-view</p>
<p>Medial tethering angle normal range: < 30°</p>	<p>Maximum medial-lateral distance during systole</p>  <p>medial lateral 2ChV</p>	<p>inferoseptal lateral</p>  <p>medial tethering angle postero-lateral tethering angle 4ChV</p>	<p>Sectional plane throughout the mitral annulus</p>  <p>septal lateral maximum medial-lateral distance</p>	 <p>3D en-face-view</p>
<p>Mitral valve orifice area normal range: < 4cm²</p> <p>●</p>	<p>diastole</p>  <p>centerline through the mitral vane long axis view within the 3D-data set</p>	<p>centerline through the mitral vane</p>  <p>centerline through the mitral vane 2-chamber view within the 3D-data set</p>	<p>centerline through the mitral vane</p>  <p>centerline through the mitral vane 4-chamber view within the 3D-data set</p>	<p>short axis view within the 3D-data set</p> 
 <p>3D-TTE - long axis view 3D-TTE - 2-chamber view 3D-TTE - 4-chamber view 3D-TTE - en-face view to the mitral valve from the LA</p>				

In the first column, the echocardiographic target parameters are listed including the normal ranges: anterior–posterior and medial–lateral MV annulus diameter (intercommissural diameter) at early diastole, coaptation distance or gap, coaptation length or height, effective height, tenting height or tenting distance, the “seagull” sign, MV annulus diameter at end-systole, posterolateral and medial tethering angle, and mitral valve orifice area. The parameters recommended as mandatory [3, 5] are marked with ●. The respective images illustrate the assessment of the respective parameters in 2D sectional planes or within 3D data sets

analysis with respect to its time-dependency within the cardiac cycle.

Prof. Dr. Andreas Hagendorff (Leipzig) Beside the time-dependency of MR within the cardiac cycle, the dynamic nature of MR during various conditions—especially in SMR—should be considered in our therapeutic decision-making. Can you recommend a strategy to clarify the importance of SMR in patients, in whom the grading of MR severity at baseline cannot explain the severity of complaints?

Dr. Nicolas Merke (Berlin) It is important to prove that the clinical symptoms are originated from the MR. Especially in SMR, which is characterized by the diseased left ventricle, mild-to-moderate dynamic stress will increase the MR degree. Thus, dynamic stress echocardiography seems to be the adequate method to document the risk of LV failure due to SMR.

Prof. Dr. Andreas Hagendorff (Leipzig) The assessment of MR severity should be performed at compensated conditions during optimized treatment (revascularization, resynchronization, and OMT). How to document this prerequisite—especially in clinical trials?

Dr. Nicolas Merke (Berlin) The information about medication and dosages like circulatory parameters may be added to the report to ensure comparability of echocardiographic findings during OMT.

Prof. Dr. Andreas Hagendorff (Leipzig) The grading of MR severity during OMT arises the question about the volume state during echocardiography. What is the “physiological” volume load?

Dr. Roland Brandt (Bad Nauheim) The “physiological” volume load is definitely not the condition in the theatre, because normally the patient is in an almost hypovolemic

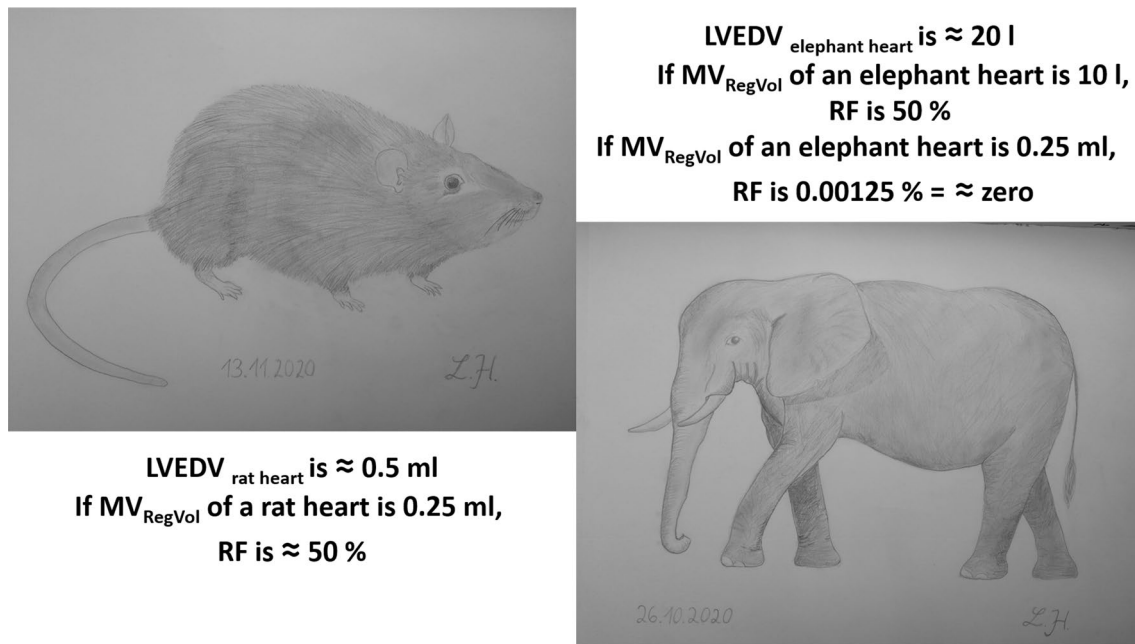


Fig. 6 Illustration of the interspecies differences of regurgitant volume in relation to total stroke volume ($LVS\bar{V}_{tot}$). The normal $LVS\bar{V}_{tot}$ of a rat heart is about 0.5 ml [61] resulting in a regurgitant fraction (RF) of 50% if regurgitant volume at the mitral valve (MV_{RegVol}) is

about 0.25 ml. The normal $LVS\bar{V}_{tot}$ of an elephant heart is about 20 l [62] resulting in a RF of about zero, if MV_{RegVol} is about 0.25 ml. An RF of about 50% needs an MV_{RegVol} of about 5 l

state prior to invasive diagnostics or intervention. In addition, general anesthesia and positive-pressure ventilation cause a reduction in sympathetic tone and have an unloading effect on the left ventricle. Therefore, TOE under general anesthesia may underestimate the degree of MR compared to the baseline evaluation in the ambulatory setting. The so-called “physiological” volume should reflect real-life conditions. Thus, we propose the echocardiographic analysis 1 day prior to intervention or surgery and at hospital discharge at comparable cardiovascular conditions for objective documentation of treatment effects.

Prof. Dr. Andreas Hagendorff (Leipzig) With respect to possible dehydration, is it allowed to assess MR severity by inducing volume overload?

Dr. Nicolas Merke (Berlin) It is certainly allowed to test intraoperatively MR severity by increasing volume load. On the other hand, the volume amount to adjust a “normal” state in the catheter laboratory is not known. Thus, provoking increased MR severity by volume load or drug-induced increase of LV afterload is crucial. The better way to test the dynamics of MR severity—as mentioned before—is a dynamic stress test. Even if the semi-quantitative and quantitative parameters are difficult to assess during dynamic stress echocardiography, the pathological increase of E/E'

and sPAP can often be determined during stress and will be helpful for decision-making.

Prof. Dr. Andreas Hagendorff (Leipzig) The characterization of MR pathology is based on the Carpentier classification and the differentiation between PMR and SMR. Are there further aspects to classify MR with respect to potential MR treatment?

Dr. Daniel Lavall (Leipzig) The Carpentier classification and the differentiation between PMR and SMR are crucial for medical, surgical, and interventional therapy as well as for prognostic considerations. However, multiple aspects—the MR etiology, the MR chronicity, concomitant diseases, clinical complaints, and special echocardiographic findings—may also be considered in a classification to specify more in detail the underlying MR mechanisms. We assume that the proposed classification aligned to echocardiographic and clinical characteristics might be helpful to guide therapeutic approaches.

Prof. Dr. Andreas Hagendorff (Leipzig) How to define the morphological differences between fibroelastic deficiency, Barlow’s disease and MV annulus disjunction?

Dr. Tobias Ruf (Mainz) Fibroelastic deficiency is characterized by thin MV leaflet, MV prolapse—frequently in a single scallop—and frequent chordae rupture, whereas

Table 6 Target parameters of left-ventricular (LV) volumes and mitral regurgitant volume (MV_{RegVol}), the different methods for assessment, the methodological limitations, and the conditions when to use or not to use the respective method

Target parameter	Methods	Limitations	When to use or not to use
$LVSV_{tot}$	<p>LV planimetry (2D)</p> <p>Monoplane long axis view (LAX)</p> <p>Biplane 2- and 4- chamber view (2- and 4-ChV)</p> <p>Triplane</p> <p>LV volumetry (3D)</p> <p>Mitral inflow (Doppler)</p>	<p>LV planimetry (2D)</p> <p>not-sufficient standardization of the views</p> <p>not-sufficient imaging conditions of endocardial contours</p> <p>foreshortening views</p> <p>regional wall motion abnormalities</p> <p>LV volumetry (3D)</p> <p>not-sufficient image quality, especially spatial resolution</p> <p>Mitral inflow (Doppler)</p> <p>Mitral annulus is not circular</p> <p>Transmitral pw-Doppler spectrum must be acquired at mitral annulus level</p> <p>Position of the sample volume cannot be standardized due to the movement of the mitral annulus</p>	<p>LV planimetry (2D)—in general, only to use if endocardial contours can be adequately delineated. If not, try to use LV opacification with contrast echocardiography. Delineation of all trabecula as endocardium causes underestimation, delineation of the midmyocardial contour between longitudinal and circumferential fibers causes overestimation of LV volumes. Carefully labeling of the apex of the cavity, the mitral annulus and the LVOT—especially wrong labeling of the basal regions produces significant underestimation of LV volumes</p> <p>Monoplane LV planimetry is only applicable if no wall motion abnormalities are present. Monoplane LAX planimetry results mostly in larger LV volumes in comparison to 2- and 4-ChV. Monoplane LV planimetry is misleading in patients with regional wall motion abnormalities</p> <p>Biplane 2- and 4-ChV is not allowed in foreshortening and not-standardized views. Thus, it is only applicable if maximum LV length is accurately documented. Monoplane 2-ChV planimetry results mostly in the lowest LV volumes, monoplane 4-ChV planimetry results mostly in the underestimated LV volumes due to foreshortening. Biplane LV planimetry is misleading in patients with regional wall motion abnormalities</p> <p>Triplane is the best approach to document standardized views. Triplane LV planimetry is an acceptable approach to assess reliable LV volumes in patients with regional wall motion abnormalities. Triplane LV planimetry is superior to LV volumetry (3D) in patients with not optimal image quality in patients with regional wall motion abnormalities. However, it can only be used in patients with excellent image quality and sufficient temporal resolution (volume rates > 20/s). If volume stitching is needed, image acquisition requires regular heart rate and cooperation of the patient during breath hold</p> <p>Mitral inflow (Doppler)—in clinical practice this method is too error-prone to be recommended because diameter of the mitral annulus is not exactly determined in the 4-ChV and cannot be corrected with respect to the dynamic alterations during diastole. Transmitral pw-Doppler spectrum at the level of the mitral annulus must be aligned to the inflow velocities. This approach is generally obsolete in patients with mitral valve stenosis or pathologically increased transmitral velocities</p>

Table 6 (continued)

Target parameter	Methods	Limitations	When to use or not to use
LVSV _{eff}	Doppler calculation using LVOT diameter (D _{LVOT}) and LVOT velocity time integral (VTI _{LVOT}): $LVSV_{eff} = 0.785 \times D_{LVOT}^2 \times VTI_{LVOT}$	Oblique labeling of D _{LVOT} mostly causing underestimation of D _{LVOT} and LVSV _{eff} Wrong position of the position of the sample volume. If it is located too far into the left ventricle, LVSV _{eff} is underestimated	LVSV _{eff} assessment by Doppler echocardiography is well applicable in patients with normal morphology of aortic valve and LVOT LVSV _{eff} assessment by Doppler echocardiography is not applicable in patients with relevant aortic stenosis (overestimation of LVSV _{eff} due to increased VTI _{LVOT} because of flow increase proximal to the aortic valve stenosis) and/or relevant aortic valve regurgitation (overestimation of LVSV _{eff} due to increased VTI _{LVOT} which represent the addition of LVSV _{eff} and regurgitant volume at the aortic valve) If D _{LVOT} cannot be accurately measured in TTE, D _{LVOT} or cross-sectional LVOT area can be determined by 2D- or 3D-TOE imaging
RVSV _{eff}	Doppler calculation using RVOT diameter (D _{RVOT}) and RVOT velocity time integral (VTI _{RVOT}): $RVSV_{eff} = 0.785 \times D_{RVOT}^2 \times VTI_{RVOT}$	Wrong labeling of D _{RVOT} mostly caused by lung shadowing causing underestimation of D _{RVOT} and RVSV _{eff} Wrong labeling of D _{RVOT} too far into the right ventricle causing severe overestimation of D _{RVOT} and RVSV _{eff} Wrong position of the position of the sample volume in relation to the labeling of D _{RVOT} . Causing both over- or underestimation of RVSV _{eff}	RVSV _{eff} assessment by Doppler echocardiography is well applicable in patients with normal morphology of pulmonary valve and RVOT. Plausibility control assessment is recommended comparing measurements at different levels at the RVOT, the pulmonary valve and the pulmonary trunk (see Fig. 4) RVSV _{eff} assessment by Doppler echocardiography is not applicable in patients with relevant pulmonic stenosis or regurgitation In patients with aortic valve disease, RVSV _{eff} assessment by Doppler echocardiography (if pulmonary valve is normal and no or mild regurgitation is present) enables the estimation of LVSV _{eff} because during these conditions RVSV _{eff} is equal to LVSV _{eff} If D _{RVOT} cannot be accurately measured in TTE, D _{RVOT} or cross-sectional RVOT area can be determined by 2D- or 3D-TOE imaging
2D-PISA-MR _{RegVol}	2D-PISA-method	underestimation of RegVol _{MV} by the elliptical shape of EROA overestimation by improper labeling of the PISA radius, PISA elongation by constrained flow field or eccentric jets, and by the dynamic nature of the MR; very limited, if applied in eccentric jets—even using angle correction; limited by error-proneness of the PISA radius detection	MR _{RegVol} by the 2D-PISA method is only applicable in patients with mitral regurgitation if regurgitant jet formation is not eccentric and proximal convergence areas are flat, e.g. in patients with mitral valve regurgitation type Carpentier I with reduced LV function Highly error-prone in primary MR with eccentric jet formation Not applicable in the presence of relevant mitral valve stenosis Not applicable in the presence of concomitant aortic valve diseases

Table 6 (continued)

Target parameter	Methods	Limitations	When to use or not to use
Calculated MR_{RegVol}	Calculation using LVS_{tot} assessment by planimetry or volumetry and LVS_{eff} by Doppler echocardiography: $MR_{RegVol} = LVS_{tot} - LVS_{eff}$	In principle, error-prone due to the assessment of multiple parameters for both, LVS_{tot} and LVS_{eff} determination The validity of this approach is highly dependent on image quality, standardization, technical skill, and expertise	LVS_{tot} assessment can only be performed in native 2D echocardiography if image quality is adequate. Otherwise contrast echocardiography is recommended The choice of method for LVS_{tot} assessment depends on alterations of LV geometry due to regional wall motion abnormalities. If image quality is adequate, 3D volumetry is superior to triplane. Triplane LV planimetry is superior to biplane. Biplane LV planimetry is superior to monoplane LVS_{eff} assessment requires the correct position of the sample volumes of pw Doppler and the correct allocation of the respective diameters of LVOT and RVOT to the positions of the sample volume. Alternatively, diameters and cross-sectional areas can be determined by 2D- and 3D-TOE data sets

LVS_{tot} total LV stroke volume, LVS_{eff} effective forward LV stroke volume, RVS_{eff} effective forward RV stroke volume, $LVOT$ —LV outflow tract, $RVOT$ right-ventricular outflow tract, TOE transoesophageal echocardiography, TTE transthoracic echocardiography

Barlow's disease shows bulky billowing leaflets with excess of tissue, thick MV leaflets and multi-segmental prolapse. However, the echocardiographic characterization is challenging. In contrast the MV annulus disjunction is a sole echocardiographic diagnosis showing insertion of the MV leaflets at the LA level and a curling motion of the LV wall during systole predominantly in the posterolateral LV segments.

Prof. Dr. Andreas Hagendorff (Leipzig) Again, focusing on MV morphology do you think that 3D echocardiography is mandatory for better diagnosis of leaflet perforation or clefts?

PD Dr. Ertunc Altioek (Aachen) The answer is easy—“yes”. 3D TTE and 3D TOE allow improved en-face visualizing of MV leaflets permitting more precise localization of pathologies and the origin of regurgitation jets compared to 2D echocardiography. However, it should be noted that 3D TOE imaging can be limited particularly by dropout artefacts giving the appearance of not existing valve perforation or cleft. This limitation may be overcome by visualization of the defect in more than one view and by demonstration of color Doppler flow through the valve at the site of the suspected perforation or cleft.

Prof. Dr. Andreas Hagendorff (Leipzig) Looking at the individual RF as an objective individual parameter of MR severity—is this quantitative approach a solution to provide conclusive echocardiographic results?

PD Dr. Sebastian Ewen The accurate quantification of MR severity by the individual RF would be the desirable “gold standard” of MR assessment. However, this approach is the most difficult one and requires maximum accuracy of echocardiographic image acquisition and high expertise of measurement procedures. Thus, the quantitative RF determination is comparably error-prone as the “integrated approach” of the current recommendations [3, 5] in untrained echocardiography. The verification of cardiac volumes determined by Doppler techniques or planimetry/volumetry—especially the comparison of LVS_{tot} , LVS_{eff} , and MR_{RegVol} in MR patients—is necessary to provide haemodynamic plausibility and to avoid miscalculation of MR severity.

Prof. Dr. Andreas Hagendorff (Leipzig) The quantitative approach of MR assessment is still a maximum challenge. Do you think this approach can be implemented into the so-called clinical routine?

Prof. Dr. Fabian Knebel (Berlin) My answer will disappoint you. The determination of the individual RF is nothing for routine scanning procedures. In addition, we need a complete rethinking in echocardiography regarding the possibilities and options of accurate LV and RV volume assessment by all possible echocardiographic techniques to accept this quantitative approach. However, if AS patients are classified according to

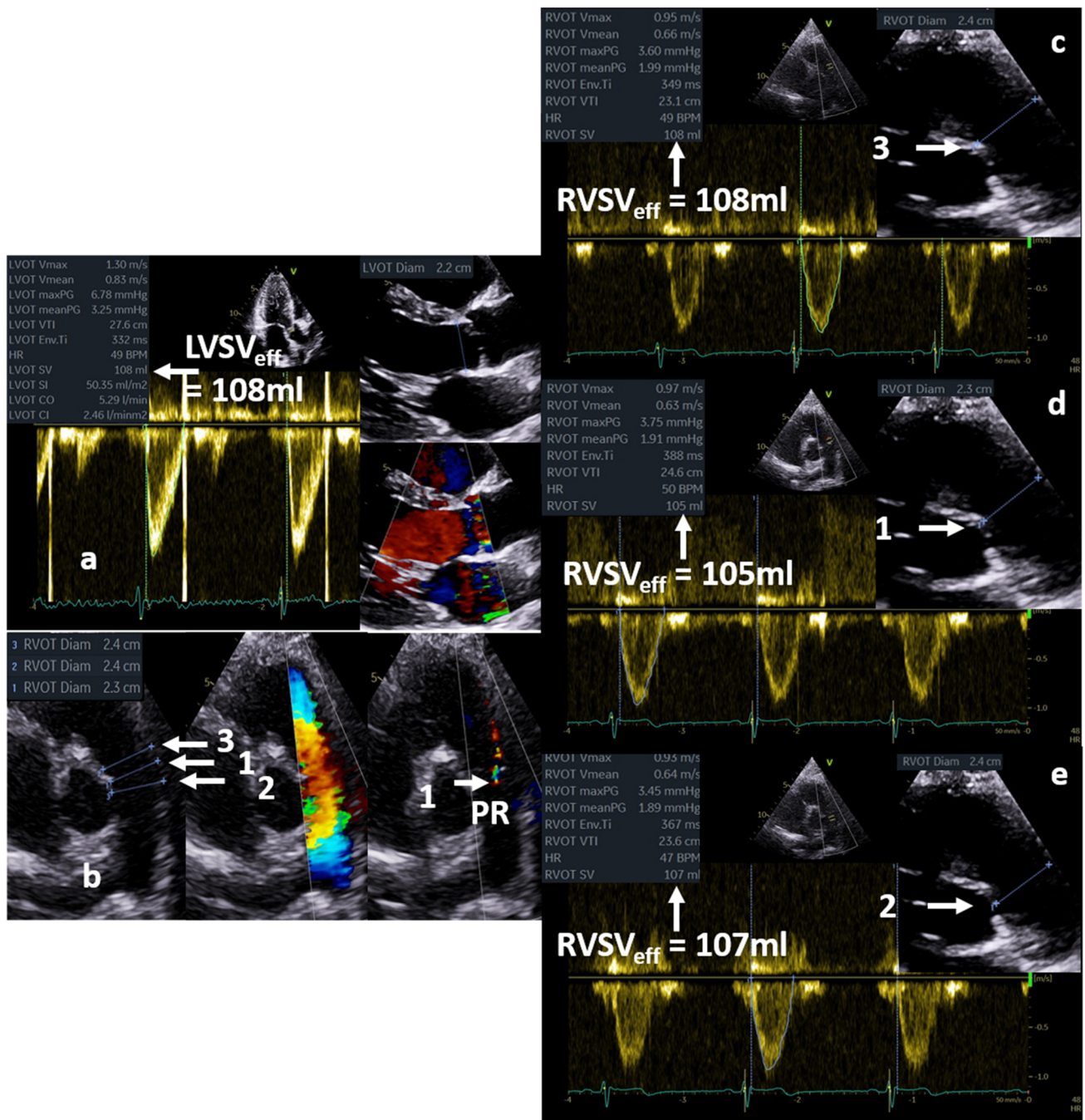


Fig. 7 Illustration of practical aspects of LSV_{eff} or RSV_{eff} determination. Labeling of the D_{LVOT} and correct positioning of the pw-sample volume documented by the cusp artefact in the pw-Doppler spectrum with the respective results (**a**); three-point labeling of diameters at the level of the pulmonic valve (1) documented by the origin of the pulmonary regurgitation, at the level of the proximal pulmonic

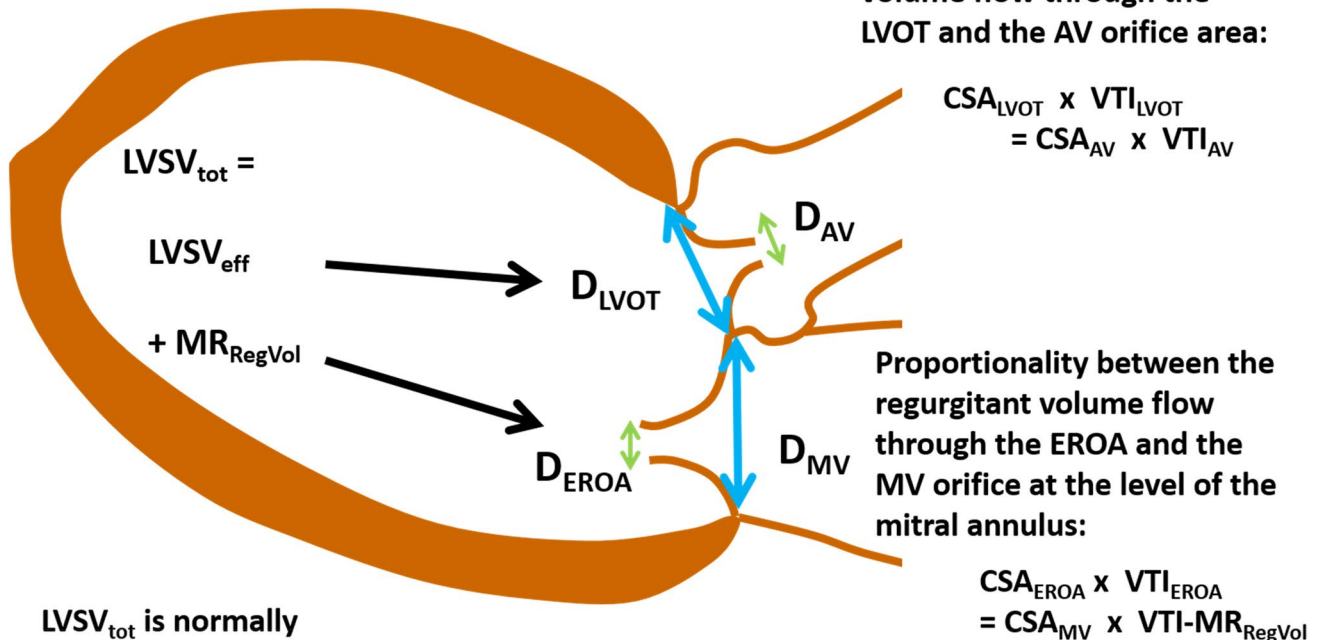
trunk (2) and at the level of the distal RVOT (3) for the respective position of the pw-Doppler sample volume (**b**); labeling of the D_{RVOT} and the corresponding pw-Doppler spectrum at the RVOT (**c**), at the pulmonic valve (**d**), and at the proximal pulmonic trunk (**e**) with the respective results. All determined forward stroke volumes are within similar ranges, hence documenting plausible results

LVSV_{eff} determined by Doppler echocardiography after exclusion of aortic valve regurgitation:

$$\text{LVSV}_{\text{eff}} = \text{CSA}_{\text{LVOT}} \times \text{VTI}_{\text{LVOT}}$$

Proportionality between the volume flow through the LVOT and the AV orifice area:

$$\text{CSA}_{\text{LVOT}} \times \text{VTI}_{\text{LVOT}} = \text{CSA}_{\text{AV}} \times \text{VTI}_{\text{AV}}$$



LVSV_{tot} is normally determined by LV 2D planimetry or LV 3D volumetry.

LVSV_{tot} – determination by transmitral Doppler echocardiography is highly error-prone because of the oval shape of the mitral annulus:

$$\text{LVSV}_{\text{tot}} = \text{CSA}_{\text{MV}} \times \text{VTI}_{\text{MV}}$$

$$\text{CSA}_{\text{EROA}} \times \text{VTI}_{\text{EROA}} = \text{CSA}_{\text{MV}} \times \text{VTI-MR}_{\text{RegVol}}$$

Fig. 8 Illustration of the proportionality of forward blood flow volume or effective left-ventricular stroke volume (LVSV_{eff}) and of transmitral regurgitant volume (MV_{RegVol}) between the respective cross-section areas (CSAs) and blood flow velocities in a system of communicating tubes. Considering the volume flow during one heart cycle total left-ventricular stroke volume (LVSV_{tot}) is the summation of LVSV_{eff} and MV_{RegVol}. LVSV_{eff} at the level of the left-ventricular outflow tract (LVOT) is equal to the level of the aortic valve (AV) orifice according to the continuity equation. By analogy MV_{RegVol} at the level of the effective regurgitant orifice area (EROA) is equal to MV_{RegVol} at the level of mitral valve (MV) annulus. Thus, both LVSV_{eff} and MV_{RegVol} exhibit proportionality between respective

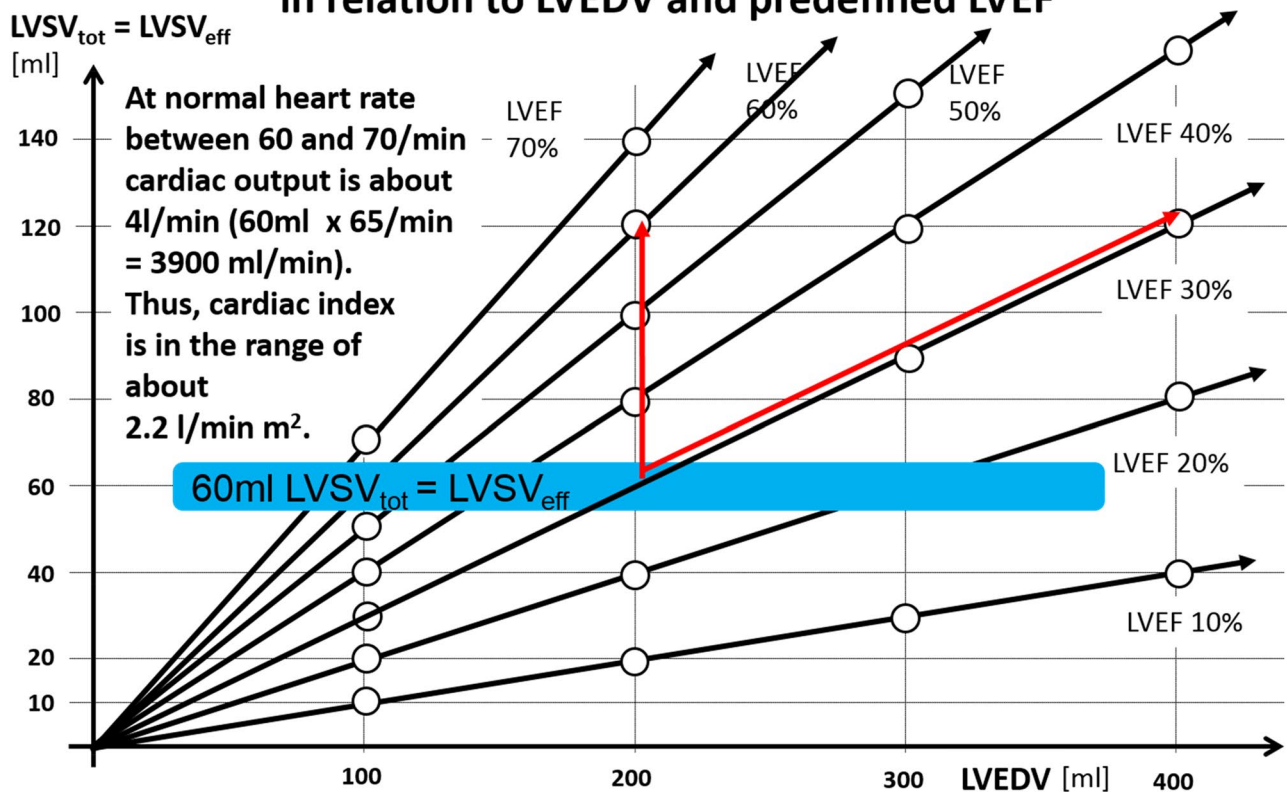
cross-section areas (CSA) and velocity time integrals (VTI). CSA_{AV} CSA of the AV orifice, CSA_{EROA} CSA of the MV regurgitant orifice, CSA_{LVOT} CSA of the LVOT, CSA_{MV} CSA at the level of the MV annulus, D_{AV} diameter of the AV orifice, D_{EROA} diameter of the MV regurgitant orifice, D_{LVOT} diameter of the LVOT, D_{MV} diameter at the level of the MV annulus, VTI_{AV} VTI of the systolic forward blood flow through the AV orifice, VTI_{EROA} VTI of the diastolic backward blood flow through the MV regurgitant orifice, VTI_{LVOT} VTI of the systolic forward blood flow through the LVOT, VTI_{MV} VTI of the diastolic forward mitral flow at the level of the MV annulus, VTI-MV_{RegVol} VTI of the systolic regurgitant transmitral blood flow at the level of the MV annulus

flow conditions determined by Doppler echocardiography. Perhaps, it is possible to determine LVSV_{eff} in MR patients, and thus, the estimation of CO and CI might be the first step to characterize the cardiovascular conditions in MR patients. Currently, the quantitative approach of RF determination is only feasible for experts.

However, to finalize our discussion, what is the most important challenge to improve the quality of echocardiography for assessment of MR severity?

Prof. Dr. Andreas Hagendorff (Leipzig) The answer is simple. We need to improve echocardiographic teaching as concerns basic knowledge of physics, anatomy and pathophysiology, technical skill of the scanning, image optimization, standardization and completeness of documentation, clinical experience, interpretation of the findings, and knowledge about possible treatment options. I think, we have still to cover these educational challenges—even in the near era of artificial intelligence.

$LVSV_{tot}$ which is equal to $LVSV_{eff}$ in the presence of no MR and no AR in relation to LVEDV and predefined LVEF



MR_{RegVol} has to be 60 ml to enable 50% regurgitant fraction (RF) in the presence of $LVSF_{eff} = 60$ ml, which is only possible with a $LVSV_{tot} = 120$ ml. Thus (red arrows), if MR is severe (at least 50% RF), LVEDV has to be 400ml – if LVEF is 30% - and LVEF has to be 60% - if LVEDV is 200ml.

Fig. 9 The relation between $LVSV_{tot}$, which is equal to $LVSV_{eff}$ in the absence of mitral regurgitation (MR) and aortic regurgitation (AR), and left-ventricular end-diastolic volume (LVEDV) with respect to left ejection fraction (LVEF) If LVEDV of 200 ml in the presence of LVEF of 30% is assumed at stable haemodynamic conditions labeled by the blue area ($LVSV_{tot} = LVSV_{eff} = 60$ ml indicating a cardiac index > 2.2 l/min m² at a normal heart rate of 65/min), $LVSV_{tot}$ must

be equal to $LVSV_{eff}$, indicating the absence of MR and AR to provide the necessary cardiac output or cardiac index. The red arrows display the necessary increase of LVEDV or LVEF assuming severe MR with a regurgitant fraction of 50%. Thus, to provide $LVSV_{eff}$ of 60 ml and MV_{RegVol} of 60 ml, $LVSV_{tot}$ of 120 ml is necessary. Consequently, LVEDV must be 400 ml if LVEF is 30%, and LVEF must be 60% if LVEDV is 200 ml

Acknowledgements The pencil drawings of Fig. 6 are performed by Louise Hagendorff. Louise Hagendorff has given consent to publish the drawings.

Funding Open Access funding enabled and organized by Projekt DEAL.. This research did not receive any specific grant from funding agencies in the public, commercial, or not-for-profit sectors.

Declarations

Conflict of interest The authors declare that they have no competing interest.

Open Access This article is licensed under a Creative Commons Attribution 4.0 International License, which permits use, sharing, adaptation, distribution and reproduction in any medium or format, as long as you give appropriate credit to the original author(s) and the source,

provide a link to the Creative Commons licence, and indicate if changes were made. The images or other third party material in this article are included in the article’s Creative Commons licence, unless indicated otherwise in a credit line to the material. If material is not included in the article’s Creative Commons licence and your intended use is not permitted by statutory regulation or exceeds the permitted use, you will need to obtain permission directly from the copyright holder. To view a copy of this licence, visit <http://creativecommons.org/licenses/by/4.0/>.

References

1. Wang A, Grayburn P, Foster JA, McCulloch ML, Badhwar V, Gammie JS, Costa SP, Benitez RM, Rinaldi MJ, Thourani VH, Martin RP (2016) Practice gaps in the care of mitral valve regurgitation: insights from the American College of Cardiology

- mitral regurgitation gap analysis and advisory panel. *Am Heart J* 172(2):70–79. <https://doi.org/10.1016/j.ahj.2015.11.003>
2. Lancellotti P, Moura L, Pierard LA, Agricola E, Popescu BA, Tribouilloy C, Hagendorff A, Monin JL, Badano L, Zamorano JL, European Association of Echocardiography (2010) European Association of Echocardiography recommendations for the assessment of valvular regurgitation Part 1 aortic and pulmonary regurgitation (native valve disease). *Eur J Echocardiogr* 11(3):223–244. <https://doi.org/10.1093/ejehocardiography/jeq030>
 3. Lancellotti P, Tribouilloy C, Hagendorff A, Popescu BA, Edvardsen T, Pierard LA, Badano L, Zamorano JL, Scientific Document Committee of the European Association of Cardiovascular Imaging (2013) Recommendations for the echocardiographic assessment of native valvular regurgitation: an executive summary from the European Association of Cardiovascular Imaging. *Eur Heart J Cardiovasc Imaging* 14(7):611–644. <https://doi.org/10.1093/ehjci/jet105>
 4. Nickenig G, Mohr FM, Kelm M, Kuck KH, Bookstegers HJ, Schillinger W, Brachmann J, Lange R, Reichenspurner H (2013) Konsensus der Deutschen Gesellschaft für Kardiologie—Herz- und Kreislaufforschung und der Deutschen Gesellschaft für Thorax-Herz- und Gefäßchirurgie zur Behandlung der Mitralklappeninsuffizienz. *Kardiologie* 7:76–90. <https://doi.org/10.1007/s12181-013-0488-1>
 5. Zoghbi WA, Adams D, Bonow RO, Enriquez-Sarano M, Foster E, Grayburn PA, Hahn RT, Han Y, Hung J, Lang RM, Little SH, Shah DJ, Shernan S, Thavendiranathan P, Thomas JD, Weissman NJ (2017) Recommendations for noninvasive evaluation of native valvular regurgitation: a report from the American society of echocardiography developed in collaboration with the society for cardiovascular magnetic resonance. *J Am Soc Echocardiogr* 30(4):303–371. <https://doi.org/10.1016/j.echo.2017.01.007>
 6. Bonow RO, O’Gara PT, Adams DH, Badhwar V, Bavaria JE, Elmariah S, Hung JW, Lindenfeld J, Morris AA, Satpathy R, Whisenant B, Woo YJ (2020) 2020 focused update of the 2017 ACC expert consensus decision pathway on the management of mitral regurgitation: a report of the American College of Cardiology solution set oversight committee. *J Am Coll Cardiol* 75(17):2236–2270. <https://doi.org/10.1016/j.jacc.2020.02.005>
 7. Hagendorff A, Fehske W, Flachskampf FA, Helfen A, Kreidel F, Kruck S, La Rosée K, Tiemann K, Voigt JU, von Bardeleben RS, Ralf Zahn R, Fabian Knebel F (2020) Manual zur Indikation und Durchführung der Echokardiographie—update 2020 der Deutschen Gesellschaft für Kardiologie. *Kardiologie* 14:396–431. <https://doi.org/10.1007/s12181-020-00402-3>
 8. Stone GW, Vahanian AS, Adams DH, Abraham WT, Borer JS, Bax JJ, Schofer J, Cutlip DE, Krucoff MW, Blackstone EH, Généreux P, Mack MJ, Siegel RJ, Grayburn PA, Enriquez-Sarano M, Lancellotti P, Filippatos G, Kappetein AP (2015) Clinical trial design principles and endpoint definitions for transcatheter mitral valve repair and replacement: part 1: clinical trial design principles: a consensus document from the mitral valve academic research consortium. *J Am Coll Cardiol* 66(3):278–307. <https://doi.org/10.1016/j.jacc.2015.05.046>
 9. Stone GW, Adams DH, Abraham WT, Kappetein AP, Généreux P, Vranckx P, Mehran R, Kuck KH, Leon MB, Piazza N, Head SJ, Filippatos G, Vahanian AS (2015) Clinical trial design principles and endpoint definitions for transcatheter mitral valve repair and replacement: Part 2: endpoint definitions: a consensus document from the mitral valve academic research consortium. *J Am Coll Cardiol* 66(3):308–321. <https://doi.org/10.1016/j.jacc.2015.05.049>
 10. Stone GW, Lindenfeld J, Abraham WT, Kar S, Lim DS, Mishell JM, Whisenant B, Grayburn PA, Rinaldi M, Kapadia SR, Rajagopal V, Sarembock IJ, Brieke A, Marx SO, Cohen DJ, Weissman NJ, Mack MJ, Investigators COAPT (2018) Transcatheter mitral-valve repair in patients with heart failure. *N Engl J Med* 379(24):2307–2318. <https://doi.org/10.1056/NEJMoa1806640>
 11. Asch AF, Grayburn PA, Siegel RJ, Kar S, Lim DS, Zaroff JG, Mishell JM, Whisenant B, Mack MJ, JoAnn Lindenfeld JA, Abraham WT, Stone GW, Weissman NJ (2019) Echocardiographic outcomes after transcatheter leaflet approximation in patients with secondary mitral regurgitation: the COAPT trial. *J Am Coll Cardiol* 74(24):2969–2979. <https://doi.org/10.1016/j.jacc.2019.09.017>
 12. Recusani F, Bargiggia GS, Yoganathan AP, Raisaro A, Valdes-Cruz LM, Sung HW, Bertucci C, Gallati M, Moises VA, Simpson IA, Tronconi L, Sahn DJ (1991) A new method for quantification of regurgitant flow rate using color Doppler flow imaging of the flow convergence region proximal to a discrete orifice. An in vitro study. *Circulation* 83(2):594–604. <https://doi.org/10.1161/01.cir.83.2.594>
 13. Grayburn PA, Weissman NJ, Zamorano JL (2012) Quantitation of mitral regurgitation. *Circulation* 126(16):2005–2017. <https://doi.org/10.1161/CIRCULATIONAHA.112.121590>
 14. Simpson IA, Shiota T, Gharib M, Sahn DJ (1996) Current status of flow convergence for clinical applications: is it a leaning tower of “PISA”? *J Am Coll Cardiol* 27(2):504–509. [https://doi.org/10.1016/0735-1097\(95\)00486-6](https://doi.org/10.1016/0735-1097(95)00486-6)
 15. Yosefy C, Levine RA, Solis J, Vaturi M, Handschumacher MD, Hung J (2007) Proximal flow convergence region as assessed by real-time 3-dimensional echocardiography: challenging the hemispheric assumption. *J Am Soc Echocardiogr* 20(4):389–396. <https://doi.org/10.1016/j.echo.2006.09.006>
 16. Grayburn PA, Carabello B, Hung J, Gillam LD, Liang D, Mack MJ, McCarthy PM, Miller DC, Trento A, Siegel RJ (2014) Defining “severe” secondary mitral regurgitation: emphasizing an integrated approach. *J Am Coll Cardiol* 64(25):2792–2801. <https://doi.org/10.1016/j.jacc.2014.10.016>
 17. Quéré JP, Tribouilloy C, Enriquez-Sarano M (2003) Vena contracta measurement: theoretic basis and usefulness in the assessment of valvular regurgitation severity. *Curr Cardiol Rep* 5(2):110–115. <https://doi.org/10.1007/s11886-003-0077-1>
 18. Biner S, Rafique A, Rafii F, Tolstrup K, Noorani O, Shiota T, Gurudevan S, Siegel RJ (2010) Reproducibility of proximal isovelocity surface area, vena contracta, and regurgitant jet area for assessment of mitral regurgitation severity. *JACC Cardiovasc Imaging* 3(3):235–243. <https://doi.org/10.1016/j.jcmg.2009.09.029>
 19. Uretsky S, Aldaia L, Marcoff L, Koulogiannis K, Argulian E, Lasam G, Gillam L (2020) Concordance and discordance of echocardiographic parameters recommended for assessing the severity of mitral regurgitation. *Circ Cardiovasc Imaging* 13(5):e010278. <https://doi.org/10.1161/CIRCIMAGING.119.010278> (**Epub 2020**)
 20. Schwammenthal E, Chen C, Benning F, Block M, Breithardt G, Levine RA (1994) Dynamics of mitral regurgitant flow and orifice area. Physiologic application of the proximal flow convergence method: clinical data and experimental testing. *Circulation* 90(1):307–322. <https://doi.org/10.1161/01.cir.90.1.307>
 21. Hung J, Otsuji Y, Handschumacher MD, Schwammenthal E, Levine RA (1999) Mechanism of dynamic regurgitant orifice area variation in functional mitral regurgitation: physiologic insights from the proximal flow convergence technique. *J Am Coll Cardiol* 33(2):538–545. [https://doi.org/10.1016/s0735-1097\(98\)00570-1](https://doi.org/10.1016/s0735-1097(98)00570-1)
 22. Buck T, Plicht B, Kahlert P, Schenk IM, Hunold P, Erbel R (2008) Effect of dynamic flow rate and orifice area on mitral regurgitant stroke volume quantification using the proximal isovelocity surface area method. *J Am Coll Cardiol* 52(9):767–778. <https://doi.org/10.1016/j.jacc.2008.05.028>

23. Watanabe N (2019) Acute mitral regurgitation. *Heart* 105(9):671–677. <https://doi.org/10.1136/heartjnl-2018-313373>
24. Altioek E, Hamada S, van Hall S, Hanenberg M, Dohmen G, Almalla M, Grabskaya E, Becker M, Marx N, Hoffmann R (2011) Comparison of direct planimetry of mitral valve regurgitation orifice area by three-dimensional transesophageal echocardiography to effective regurgitant orifice area obtained by proximal flow convergence method and vena contracta area determined by color Doppler echocardiography. *Am J Cardiol* 107(3):452–458. <https://doi.org/10.1016/j.amjcard.2010.09.043>
25. Chandra S, Salgo IS, Sugeng L, Weinert L, Settlemier SH, Mor-Avi V, Lang RM (2011) A three-dimensional insight into the complexity of flow convergence in mitral regurgitation: adjunctive benefit of anatomic regurgitant orifice area. *Am J Physiol Heart Circ Physiol* 301(3):H1015–H1024. <https://doi.org/10.1152/ajpheart.00275.2011>
26. Zeng X, Levine RA, Hua L, Morris EL, Kang Y, Flaherty M, Morgan NV, Hung J (2011) Diagnostic value of vena contracta area in the quantification of mitral regurgitation severity by color Doppler 3D echocardiography. *Circ Cardiovasc Imaging* 4(5):506–513. <https://doi.org/10.1161/CIRCIMAGING.110.961649>
27. Enriquez-Sarano M, Dujardin KS, Tribouillois CM, Seward JB, Yoganathan AP, Bailey KR, Tajik AJ (1999) Determinants of pulmonary venous flow reversal in mitral regurgitation and its usefulness in determining the severity of regurgitation. *Am J Cardiol* 83(4):535–541. [https://doi.org/10.1016/s0002-9149\(98\)00909-6](https://doi.org/10.1016/s0002-9149(98)00909-6)
28. Tribouillois C, Shen WF, Rey JL, Adam MC, Lesbre JP (1994) Mitral to aortic velocity-time integral ratio. A non-geometric pulsed-Doppler regurgitant index in isolated pure mitral regurgitation. *Eur Heart J* 15(10):1335–1339. <https://doi.org/10.1093/oxfordjournals.eurheartj.a060390>
29. Carabello BA (2008) The current therapy for mitral regurgitation. *J Am Coll Cardiol* 52(5):319–326. <https://doi.org/10.1016/j.jacc.2008.02.084>
30. Bennett S, Thamman R, Griffiths T, Oxley C, Khan JN, Phan T, Patwala A, Heatlie G, Kwok CS (2019) Mitral annular disjunction: a systematic review of the literature. *Echocardiography* 36(8):1549–1558. <https://doi.org/10.1111/echo.14437>
31. Dziadzko V, Dziadzko M, Medina-Inojosa JR, Benfari G, Michelena HI, Crestanello JA, Maalouf J, Thapa P, Enriquez-Sarano M (2019) Causes and mechanisms of isolated mitral regurgitation in the community: clinical context and outcome. *Eur Heart J* 40(27):2194–2202. <https://doi.org/10.1093/eurheartj/ehz314>
32. Carpentier A (1983) Cardiac valve surgery—the “French correction.” *J Thorac Cardiovasc Surg* 86(3):323–337
33. Enriquez-Sarano M, Akins CW, Vahanian A (2009) Mitral regurgitation. *Lancet* 373:1382–1394. [https://doi.org/10.1016/S0140-6736\(09\)60692-9](https://doi.org/10.1016/S0140-6736(09)60692-9)
34. Deferm S, Bertrand PB, Verbrugge FH et al (2019) Atrial functional mitral regurgitation: JACC review topic of the week. *J Am Coll Cardiol* 73:2465–2476. <https://doi.org/10.1016/j.jacc.2019.02.061>
35. Opie LH, Commerford PJ, Gersh BJ, Pfeffer MA (2006) Controversies in ventricular remodeling. *Lancet* 367:356–367. [https://doi.org/10.1016/S0140-6736\(06\)68074-4](https://doi.org/10.1016/S0140-6736(06)68074-4)
36. Baumgartner H, Falk V, Bax JJ, De Bonis M, Hamm C, Holm PJ, Jung B, Lancellotti P, Lansac E, Muñoz DR, Rosenhek R, Sjogren J, Tornos Mas P, Vahanian A, Walther T, Wendler O, Windecker S, Zamorano JL (2017) 2017 ESC/EACTS Guidelines for the management of valvular heart disease. *Eur Heart J* 38(36):2739–2791. <https://doi.org/10.1093/eurheartj/ehx391>
37. Lavall D, Reil JC, Segura Schmitz L et al (2016) Early hemodynamic improvement after percutaneous mitral valve repair evaluated by noninvasive pressure-volume analysis. *J Am Soc Echocardiogr* 29:888–898. <https://doi.org/10.1016/j.echo.2016.05.012>
38. Kamperidis V, Marsan NA, Delgado V, Bax JJ (2016) Left ventricular systolic function assessment in secondary mitral regurgitation: Left ventricular ejection fraction vs. speckle tracking global longitudinal strain. *Eur Heart J* 37:811–816. <https://doi.org/10.1093/eurheartj/ehv680>
39. Gaasch WH, Aurigemma GP, Meyer TE (2020) An appraisal of the association of clinical outcomes with the severity of regurgitant volume relative to end-diastolic volume in patients with secondary mitral regurgitation. *JAMA Cardiol* 5:476–481. <https://doi.org/10.1001/jamacardio.2019.5980>
40. Packer M, Grayburn PA (2020) New evidence supporting a novel conceptual framework for distinguishing proportionate and disproportionate functional mitral regurgitation. *JAMA Cardiol*. <https://doi.org/10.1001/jamacardio.2019.5971>
41. Lang RM, Badano LP, Mor-Avi V, Afilalo J, Armstrong A, Ernande L, Flachskampf FA, Foster E, Goldstein SA, Kuznetsova T, Lancellotti P, Muraru D, Picard MH, Rietzschel ER, Rudski L, Spencer KT, Tsang W, Voigt JU (2015) Recommendations for cardiac chamber quantification by echocardiography in adults: an update from the American Society of Echocardiography and the European Association of Cardiovascular Imaging. *Eur Heart J Cardiovasc Imaging* 16(3):233–270. <https://doi.org/10.1093/ehjci/jev014>
42. Abramowitz Y, Jilaihawi H, Chakravarty T, Mack MJ, Makkar RR (2015) Mitral annulus calcification. *J Am Coll Cardiol* 66(17):1934–1941. <https://doi.org/10.1016/j.jacc.2015.08.872>
43. De Castro S, Caselli S, Maron M, Pelliccia A, Cavarretta E, Maddukuri P, Cartoni D, Di Angelantonio E, Kuvin JT, Patel AR, Pandian NG (2007) Left ventricular remodeling index (LVRI) in various pathophysiological conditions: a real-time three-dimensional echocardiographic study. *Heart* 93(2):205–209. <https://doi.org/10.1136/hrt.2006.093997>
44. Kono T, Sabbah HN, Stein PD, Brymer JF, Khaja F (1991) Left ventricular shape as a determinant of functional mitral regurgitation in patients with severe heart failure secondary to either coronary artery disease or idiopathic dilated cardiomyopathy. *Am J Cardiol* 68(4):355–359. [https://doi.org/10.1016/0002-9149\(91\)90831-5](https://doi.org/10.1016/0002-9149(91)90831-5)
45. Yiu SF, Enriquez-Sarano M, Tribouillois C, Seward JB, Tajik AJ (2000) Determinants of the degree of functional mitral regurgitation in patients with systolic left ventricular dysfunction: a quantitative clinical study. *Circulation* 102(12):1400–1406. <https://doi.org/10.1161/01.cir.102.12.1400>
46. Balachandran P, Schaff HV, Lahr BD, Nguyen A, Daly RC, Maltais S, Pislaru SV, Dearani JA (2020) Preoperative left atrial volume index is associated with postoperative outcomes in mitral valve repair for chronic mitral regurgitation. *J Thorac Cardiovasc Surg* 160(3):661–672.e5. <https://doi.org/10.1016/j.jtcvs.2019.08.040>
47. Kou S, Caballero L, Dulgheru R, Voilliot D, De Sousa C, Kacharava G, Athanassopoulos GD, Barone D, Baroni M, Cardim N, Gomez De Diego JJ, Hagendorff A, Henri C, Hristova K, Lopez T, Magne J, De La Morena G, Popescu BA, Penicka M, Ozyigit T, Rodrigo Carbonero JD, Salustri A, Van De Veire N, Von Bardeleben RS, Vinereanu D, Voigt JU, Zamorano JL, Donal E, Lang RM, Badano LP, Lancellotti P (2014) Echocardiographic reference ranges for normal cardiac chamber size: results from the NORRE study. *Eur Heart J Cardiovasc Imaging* 15(6):680–690. <https://doi.org/10.1093/ehjci/jet284>
48. Lang RM, Badano LP, Tsang W, Adams DH, Agricola E, Buck T, Faletra FF, Franke A, Hung J, de Isla LP, Kamp O, Kasprzak JD, Lancellotti P, Marwick TH, McCulloch ML, Monaghan MJ, Nihoyannopoulos P, Pandian NG, Pellikka PA, Pepi M, Roberson DA, Shernan SK, Shirali GS, Sugeng L, Ten Cate FJ, Vannan MA, Zamorano JL, Zoghbi WA (2012) EAE/ASE recommendations for image acquisition and display using three-dimensional

- echocardiography. *Eur Heart J Cardiovasc Imaging* 13(1):1–46. <https://doi.org/10.1093/ehjci/13/1/1>
49. Magne J, Pibarot P, Dagenais F, Hachicha Z, Dumesnil JG, Senchal M (2007) Preoperative posterior leaflet angle accurately predicts outcome after restrictive mitral valve annuloplasty for ischemic mitral regurgitation. *Circulation* 115(6):782–791. <https://doi.org/10.1161/CIRCULATIONAHA.106.649236>
 50. Gelsomino S, van Garsse L, Lucà F, Lorusso R, Cheriex E, Rao CM, Caciolli S, Vizzardi E, Crudeli E, Stefàno P, Gensini GF, Maessen J (2011) Impact of preoperative anterior leaflet tethering on the recurrence of ischemic mitral regurgitation and the lack of left ventricular reverse remodeling after restrictive annuloplasty. *J Am Soc Echocardiogr* 24(12):1365–1375. <https://doi.org/10.1016/j.echo.2011.09.015>
 51. Shakil O, Jainandunsing JS, Ilic R, Matyal R, Mahmood F (2013) Ischemic mitral regurgitation: an intraoperative echocardiographic perspective. *J Cardiothorac Vasc Anesth* 27(3):573–585. <https://doi.org/10.1053/j.jvca.2012.06.003>
 52. Pepi M, Tamborini G, Maltagliati A, Galli CA, Sisillo E, Salvi L, Naliato M, Porqueddu M, Parolari A, Zanobini M, Alamanni F (2006) Head-to-head comparison of two- and three-dimensional transthoracic and transesophageal echocardiography in the localization of mitral valve prolapse. *J Am Coll Cardiol* 48(12):2524–2530. <https://doi.org/10.1016/j.jacc.2006.02.079>
 53. Thompson KA, Shiota T, Tolstrup K, Gurudevan SV, Siegel RJ (2011) Utility of three-dimensional transesophageal echocardiography in the diagnosis of valvular perforations. *Am J Cardiol* 107(1):100–102. <https://doi.org/10.1016/j.amjcard.2010.08.051>
 54. Lee AP, Hsiung MC, Salgo IS, Fang F, Xie JM, Zhang YC, Lin QS, Looi JL, Wan S, Wong RH, Underwood MJ, Sun JP, Yin WH, Wei J, Tsai SK, Yu CM (2013) Quantitative analysis of mitral valve morphology in mitral valve prolapse with real-time 3-dimensional echocardiography: importance of annular saddle shape in the pathogenesis of mitral regurgitation. *Circulation* 127(7):832–841. <https://doi.org/10.1161/CIRCULATIONAHA.112.118083>
 55. Narang A, Addetia K, Weinert L, Yamat M, Shah AP, Blair JE, Mor-Avi V, Lang RM (2018) Diagnosis of isolated cleft mitral valve using three-dimensional echocardiography. *J Am Soc Echocardiogr* 31(11):1161–1167. <https://doi.org/10.1016/j.echo.2018.06.008>
 56. De Castro S, Cartoni D, d'Amati G, Beni S, Yao J, Fiorell M, Gallo P, Fedele F, Pandian NG (2000) Diagnostic accuracy of transthoracic and multiplane transesophageal echocardiography for valvular perforation in acute infective endocarditis: correlation with anatomic findings. *Clin Infect Dis* 30(5):825–826. <https://doi.org/10.1086/313762>
 57. Dwivedi G, Mahadevan G, Jimenez D, Frenneaux M, Steeds RP (2014) Reference values for mitral and tricuspid annular dimensions using two-dimensional echocardiography. *Echo Res Pract* 1(2):43–50. <https://doi.org/10.1530/ERP-14-0050>
 58. Obadia JF, Messika-Zeitoun D, Leurent G, Iung B, Bonnet G, Piriou N, Lefèvre T, Piot C, Rouleau F, Carrié D, Nejari M, Ohlmann P, Leclercq F, Saint Etienne C, Teiger E, Leroux L, Karam N, Michel N, Gilard M, Donal E, Trochu JN, Cormier B, Armoiry X, Boutitie F, Maucort-Boulch D, Barnel C, Samson G, Guerin P, Vahanian A, Mewton N, Investigators MITRA-FR (2018) Percutaneous repair or medical treatment for secondary mitral regurgitation. *N Engl J Med* 379(24):2297–2306. <https://doi.org/10.1056/NEJMoa1805374>
 59. Witte KK, Lipiecki J, Siminiak T, Meredith IT, Malkin CJ, Goldberg SL, Stark MA, von Bardeleben RS, Cremer PC, Jaber WA, Celermajer DS, Kaye DM, Sievert H (2019) REDUCE FMR trial: a randomized sham-controlled study of percutaneous mitral annuloplasty in functional mitral regurgitation. *JACC Heart Fail* 7:945–955. <https://doi.org/10.1016/j.jchf.2019.06.011>
 60. Namazi F, van der Bijl P, Fortuni F, Mertens BJA, Kamperidis V, van Wijngaarden SE, Stone GW, Narula J, Ajmone Marsan N, Vahanian A, Delgado V, Bax JJ (2020) Regurgitant volume/left ventricular end-diastolic volume ratio: prognostic value in patients with secondary mitral regurgitation. *JACC Cardiovasc Imaging*. <https://doi.org/10.1016/j.jcmg.2020.06.032>
 61. Arias T, Chen J, Fayad ZA, Fuster V, Hajjar RJ, Chemaly ER (2013) Comparison of echocardiographic measurements of left ventricular volumes to full volume magnetic resonance imaging in normal and diseased rats. *J Am Soc Echocardiogr* 26(8):910–918. <https://doi.org/10.1016/j.echo.2013.04.016>
 62. Holt JP, Rhode EA, Kines H (1968) Ventricular volumes and body weight in mammals. *Am J Physiol* 215(3):704–715. <https://doi.org/10.1152/ajplegacy.1968.215.3.704>
 63. Rigolli M, Anandabaskaran S, Christiansen JP, Whalley GA (2016) Bias associated with left ventricular quantification by multimodality imaging: a systematic review and meta-analysis. *Open Heart* 3(1):388. <https://doi.org/10.1136/openhrt-2015-000388> (eCollection 2016)
 64. Mocerri P, Doyen D, Bertora D, Cerboni P, Ferrari E, Gibelin P (2012) Real time three-dimensional echocardiographic assessment of left ventricular function in heart failure patients: underestimation of left ventricular volume increases with the degree of dilatation. *Echocardiography* 29(8):970–977. <https://doi.org/10.1111/j.1540-8175.2012.01707.x>
 65. Mårtensson M, Winter R, Cederlund K, Ripsweden J, Mir-Akbari H, Nowak J, Brodin LA (2008) Assessment of left ventricular volumes using simplified 3-D echocardiography and computed tomography—a phantom and clinical study. *Cardiovasc Ultrasound*. <https://doi.org/10.1186/1476-7120-6-26>
 66. Aurich M, André F, Keller M, Greiner S, Hess A, Buss SJ, Katus HA, Meregali D (2014) Assessment of left ventricular volumes with echocardiography and cardiac magnetic resonance imaging: real-life evaluation of standard versus new semiautomatic methods. *J Am Soc Echocardiogr* 27(10):1017–1024. <https://doi.org/10.1016/j.echo.2014.07.006>
 67. Hagendorff A, Doenst T, Falk V (2019) Echocardiographic assessment of functional mitral regurgitation: opening Pandora's box? *ESC Heart Fail* 6(4):678–685. <https://doi.org/10.1002/ehf2.12491>
 68. Hagendorff A, Knebel F, Helfen A, Stöbe S, Doenst T, Falk V (2020) Disproportionate mitral regurgitation: another myth? A critical appraisal of echocardiographic assessment of functional mitral regurgitation. *Int J Cardiovasc Imaging*. <https://doi.org/10.1007/s10554-020-01975-6>
 69. Kamoen V, Calle S, De Buyzere M, Timmermans F (2020) Proportionate or disproportionate secondary mitral regurgitation: how to untangle the Gordian knot? *Heart* 106(22):1719–1725. <https://doi.org/10.1136/heartjnl-2020-317040>
 70. Stöbe S, Kreyer K, Jurisch D, Pfeiffer D, Lavall D, Farese G, Laufs U, Hagendorff A (2020) Echocardiographic analysis of acute effects of percutaneous mitral annuloplasty on severity of functional mitral regurgitation. *ESC Heart Fail* 7(4):1645–1652. <https://doi.org/10.1002/ehf2.12719>
 71. Malm S, Frigstad S, Sagberg E, Larsson H, Skjaerpe T (2004) Accurate and reproducible measurement of left ventricular volume and ejection fraction by contrast echocardiography: a comparison with magnetic resonance imaging. *J Am Coll Cardiol* 44(5):1030–1035. <https://doi.org/10.1016/j.jacc.2004.05.068>
 72. Jenkins C, Moir S, Chan J, Rakhit D, Haluska B, Marwick TH (2009) Left ventricular volume measurement with echocardiography: a comparison of left ventricular opacification, three-dimensional echocardiography, or both with magnetic resonance imaging. *Eur Heart J* 30(1):98–106. <https://doi.org/10.1093/eurheartj/ehn484>
 73. Grayburn PA, Sannino A, Packer M (2019) Proportionate and disproportionate functional mitral regurgitation: a new conceptual

- framework that reconciles the results of the MITRA-FR and COAPT trials. *JACC Cardiovasc Imaging* 12(2):353–362. <https://doi.org/10.1016/j.jcmg.2018.11.006>
74. Hahn RT (2020) Disproportionate emphasis on proportionate mitral regurgitation—are there better measures of regurgitant severity? *JAMA Cardiol*. <https://doi.org/10.1001/jamacardio.2019.6235>
 75. Packer M (2020) Disproportionate functional mitral regurgitation: a new therapeutic target in patients with heart failure and a reduced ejection fraction. *Eur J Heart Fail* 22(1):23–25. <https://doi.org/10.1002/ejhf.1469>
 76. Hagendorff A, Knebel F, Helfen A, Knierim J, Sinning C, Stöbe S, Fehske W, Ewen S (2020) Expert consensus document on the assessment of the severity of aortic valve stenosis by echocardiography to provide diagnostic conclusiveness by standardized verifiable documentation. *Clin Res Cardiol* 109(3):271–288. <https://doi.org/10.1007/s00392-019-01539-2>
 77. Izumo M, Lancellotti P, Suzuki K, Kou S, Shimozato T, Hayashi A, Akashi YJ, Osada N, Omiya K, Nobuoka S, Ohtaki E, Miyake F (2009) Three-dimensional echocardiographic assessments of exercise-induced changes in left ventricular shape and dyssynchrony in patients with dynamic functional mitral regurgitation. *Eur J Echocardiogr* 10(8):961–967. <https://doi.org/10.1093/ejechoard/jep114>
 78. Bertrand PB, Schwammenthal E, Levine RA, Vandervoort PM (2017) Exercise dynamics in secondary mitral regurgitation: pathophysiology and therapeutic implications. *Circulation* 135(3):297–314. <https://doi.org/10.1161/CIRCULATIONAHA.116.025260>