

Ruptured hemorrhagic bulla in a patient with a HeartMate 3 treated with an Amplatzer device

Bulla hemorrágica rota en un paciente con un HeartMate 3 tratado con un dispositivo Amplatzer

Adrian daSilva-deAbreu^{1,2*}, Oscar Maitas^{1,2}, Juan P. Rodriguez-Escudero¹, Sapna Desai^{1,2},
Clement Eiswirth^{1,2}, Selim Krim^{1,2}, Hamang Patel^{1,2}, Hector O. Ventura^{1,2}, and Stacy A. Mandras^{1,2}

¹Department of Cardiovascular Diseases, John Ochsner Heart and Vascular Institute, Ochsner Medical Center, New Orleans, LA, USA; ²Ochsner Clinical School, Faculty of Medicine, The University of Queensland, New Orleans, LA, USA.

A 60-year-old female with underlying emphysema and left ventricular assist device (LVAD) HeartMate 3 presented with progressive hemoptysis, dyspnea, and right chest pain. Baseline hemoglobin was 11.1 g/dL and INR 2.9. A chest computed tomography showed enlargement of a right lung bulla with internal hemorrhage, measuring 105.6 mm in its widest diameter, and fluid-air level in its more cephalic portion (Fig. 1). Anticoagulation was held and cardiothoracic surgery consulted. The 2nd day, the LVAD had low-flow alarms, her hemoglobin decreased to 6.1 g/dL and she developed hypovolemic shock and hypoxic respiratory failure requiring intubation, blood transfusion, and inotrope/vasopressor therapy. A chest tube was placed for hemothorax, draining 2.7 L of blood. Angiography showed no active contrast extravasation but the hemothorax persisted through the next day. A second angiography was performed, during which a Montefiore pigtail catheter was advanced over a 0.035 in wire into the right pulmonary artery and diagnostic angiography was performed. Although no extravasation was evidenced, it was empirically decided to plug the right

lower lobe artery to halt further hemothorax, for which a 18 mm Amplatzer Vascular Plug II was deemed to provide appropriate occlusion. The catheter and sheath were exchanged for a 7 French by 100 cm Ansel sheath, which was advanced into the right lower lobe pulmonary artery. An 18 mm Amplatzer Vascular Plug II was advanced through the sheath and successfully deployed in the right lower lobe pulmonary artery (Fig. 2), and the hemorrhagic output decreased. She underwent surgical washout with removal of 1 L of clot. Her admission also complicated with an acute ischemic stroke and ventilator-associated pneumonia and was discharged on hospital day 32 without residual neurological deficits.

Bleeding and thrombosis are seen less frequently with centrifugal-flow pumps such as HeartMate 3¹; nonetheless, bleeding complications continue to pose significant morbidity and mortality for patients with LVADs. This case highlights the importance of coordinated multidisciplinary management and the ingenious use of transcatheter interventions, such as pulmonary arterial occlusion with Amplatzer

Correspondence:

*Adrian daSilva-deAbreu
E-mail: adrianjdasilva@gmail.com

Date of reception: 03-07-2020

Date of acceptance: 20-11-2020

DOI: 10.24875/ACM.20000331

Available online: 23-03-2021

Arch Cardiol Mex. 2021;91(3):371-372

www.archivoscardiologia.com

1405-9940 / © 2020 Instituto Nacional de Cardiología Ignacio Chávez. Published by Permalyer. This is an open access article under the CC BY-NC-ND license (<http://creativecommons.org/licenses/by-nc-nd/4.0/>).

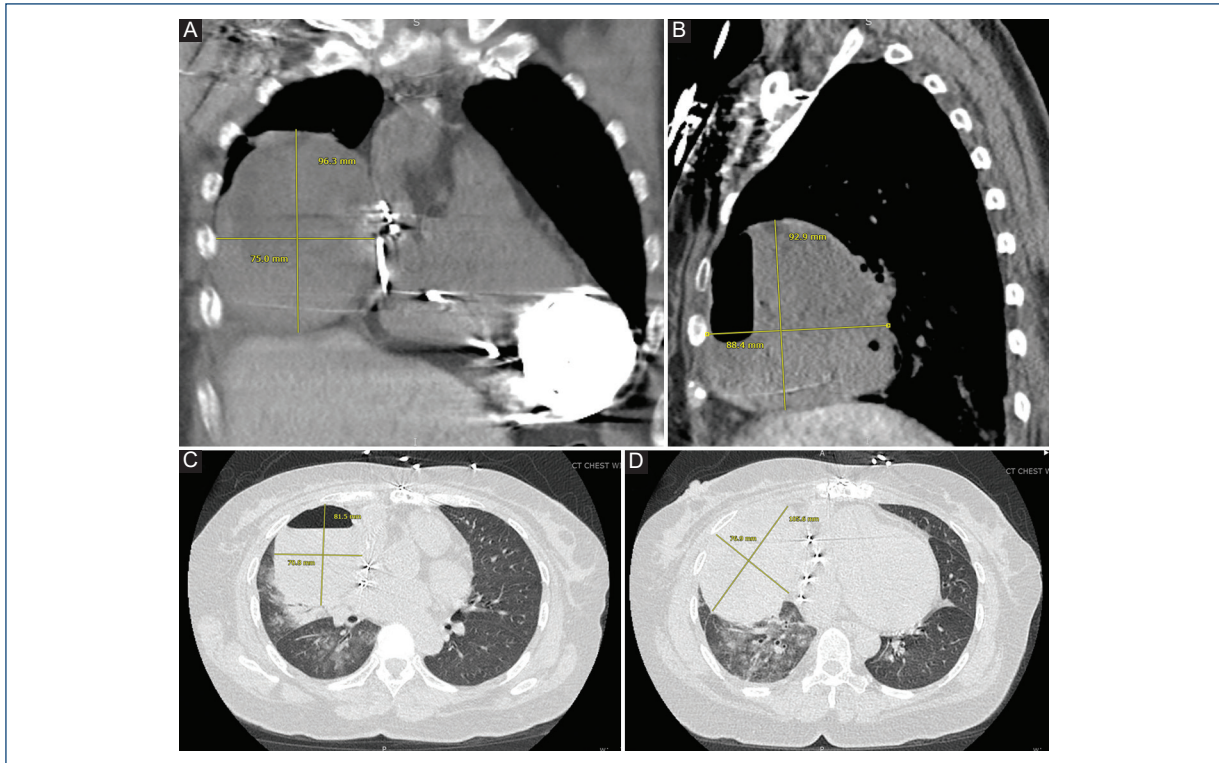


Figure 1. Chest computed tomography evidencing a large right lung bulla with internal hemorrhage (panels A-D). The bulla measured 105.6 mm in its widest diameter, and there was a fluid-air level in its more cephalic portion.

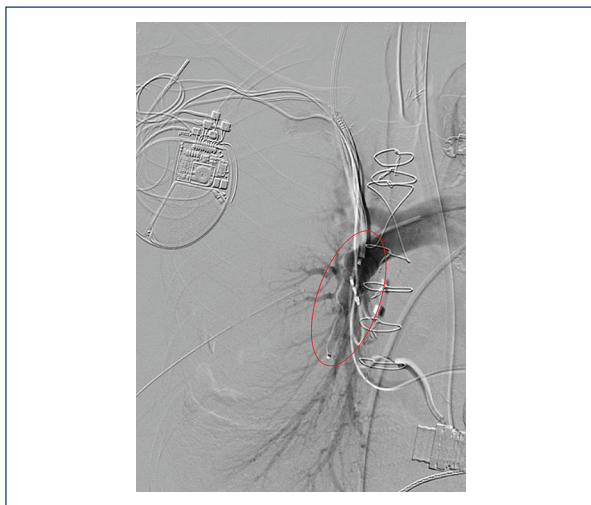

Figure 2. Post-procedural fluoroscopy. An 18-mm Amplatzer device was deployed in the right inferior pulmonary artery successfully decreasing distal flow and halting extravasation of blood.

devices, to achieve bleeding-source control in patients with LVADs.

Funding

None.

Conflicts of interest

The declare no conflicts of interests.

Ethical disclosures

Protection of human and animal subjects. The authors declare that no experiments were performed on humans or animals for this study.

Confidentiality of data. The authors declare that they have followed the protocols of their work center on the publication of patient data.

Right to privacy and informed consent. The authors declare that no patient data appear in this article.

References

1. Mehra MR, Uriel N, Naka Y, Cleveland JC, Yuzefpolskaya M, Salerno CT, et al. A fully magnetically levitated left ventricular assist device-final report. *N Engl J Med.* 2019;380:1618-27.