

# Soft Tissue Augmentation Using De-Epithelialized Free Gingival Graft Compared to Single-line Incision Subepithelial Connective Tissue Graft in the Management of Miller Class I and II Gingival Recession: A Randomized Controlled Clinical Trial

## Abstract

**Aims:** The purpose of this randomized controlled clinical trial was to clinically assess soft tissue augmentation and compare patients' morbidity and root coverage outcomes of coronally advanced flap (CAF) with subepithelial connective tissue graft (SCTG) versus de-epithelialized free gingival graft (DFGG) in the management of Miller Class I and II gingival recession. **Materials and Methods:** Twenty-eight patients with Miller's Class I or II gingival recession (GR) defects were randomly assigned into two equal parallel groups treated with either CAF + SCTG, harvested using single-line incision technique (control), or CAF + DFGG (test). Gingival thickness (GT), recession depth, recession width, percentage of root coverage, keratinized tissue width, pocket depth, and clinical attachment level were measured at baseline and 3 and 6 months postoperatively. Patient-reported outcomes were assessed postoperatively, including pain, stress, bleeding, and inability to chew. Patients' overall satisfaction and root coverage esthetic scores were recorded at 6 months. **Results:** Both groups demonstrated a statistically significant improvement in all clinical outcomes after 3 and 6 months compared to baseline. DFGG showed a statistically significant increase in GT after 6 months. No statistically significant difference was detected in other clinical outcomes between both groups at different time intervals. Both treatments achieved 92.9% complete root coverage. Patients treated with CAF + DFGG reported significantly higher stress and inability to chew scores after 2 weeks than those treated with SCTG. There were no significant differences in patient satisfaction between both groups. **Conclusions:** CAF + SCTG and CAF + DFGG were both effective and can be applied safely in treating Miller Class I and II GRs.

**Keywords:** Connective tissue graft(s), gingival recession, gingival thickness, mucogingival surgery, plastic periodontal surgery

## Introduction

During the last decades, the field of periodontology has been vastly influenced by the esthetic trend with various surgical procedures proposed in the literature for treating gingival recession (GR).<sup>[1]</sup> Subepithelial connective tissue graft (SCTG) harvesting technique initially comprised graft harvesting with epithelium removal, leading to secondary intention wound healing with accompanying discomfort and pain. Hence, the "single-incision technique"<sup>[2]</sup> avoiding vertical incisions was developed, which guaranteed uninterrupted palatal blood supply, prevented palatal sloughing, and consequently improved post-operative healing. It is well established

that coronally advanced flap (CAF) + SCTG is more effective than CAF alone and could be considered the 'gold standard' for the treatment of Miller Class I and II GR.<sup>[3-5]</sup>

SCTG has several disadvantages, including patient morbidity, being time-consuming, technique sensitive, and risk for palatal sloughing.<sup>[6]</sup> Moreover, SCTG harvested close to bone contains more fatty and glandular tissue, making it less stable, more prone to shrinkage, and might act as a barrier for vascularization.<sup>[7]</sup> Hence, the focus now is targeted toward novel techniques for harvesting SCTG that would minimize patient morbidity. Accordingly, Zucchelli *et al.*<sup>[6]</sup> first introduced de-epithelialized free gingival graft (DFGG) that was de-epithelialized extraorally and allowed CTG harvesting

Mohamed Mashaly<sup>1</sup>,  
Noha A. Ghallab<sup>2</sup>,  
Weam Elbattawy<sup>2</sup>,  
Azza Ezz Elarab<sup>3</sup>

<sup>1</sup>Department of Periodontology, Faculty of Dentistry, Cairo University, Cairo, Egypt, <sup>2</sup>Department of Oral Medicine and Periodontology, Faculty of Dentistry, Cairo University, Cairo, Egypt, <sup>3</sup>Department of Oral Medicine and Periodontology, Vice Dean for Postgraduate Affairs and Research, Faculty of Dentistry, Cairo University, Cairo, Egypt

Submitted : 30-Aug-2020  
Revised : 29-Sep-2020  
Accepted : 18-Oct-2020  
Published : 24-Sep-2022

**Address for correspondence:**  
Dr. Mohamed Mashaly,  
27A Baghdad Street, Heliopolis,  
Cairo, Egypt.  
E-mail: momashaly@gmail.com

Access this article online

Website:  
www.contempclindent.org

DOI: 10.4103/ccd.ccd\_763\_20

Quick Response Code:



This is an open access journal, and articles are distributed under the terms of the Creative Commons Attribution-NonCommercial-ShareAlike 4.0 License, which allows others to remix, tweak, and build upon the work non-commercially, as long as appropriate credit is given and the new creations are licensed under the identical terms.

For reprints contact: WKHLRPMedknow\_reprints@wolterskluwer.com

**How to cite this article:** Mashaly M, Ghallab NA, Elbattawy W, Elarab AE. Soft tissue augmentation using de-epithelialized free gingival graft compared to single-line incision subepithelial connective tissue graft in the management of miller class I and II gingival recession: A randomized controlled clinical trial. *Contemp Clin Dent* 2022;13:227-35.

irrespective of the palatal fibromucosa thickness. Further studies proved effectiveness of CAF + DFGG in attaining root coverage and decreased patient morbidity.<sup>[8-10]</sup>

Most recently, a meta-analysis by Tavelli *et al.*<sup>[11]</sup> demonstrated that CAF + DFGG provided superior root coverage outcomes than CAF + SCTG and recommended using DFGG as a CTG harvesting technique. The authors highlighted the inconclusive evidence regarding difference between both harvesting techniques and recommended conducting further randomized clinical trials, which urged us to conduct this investigation. The primary outcome of this trial was to assess soft tissue augmentation by measuring changes in gingival thickness (GT), since thick gingiva prevents the extension of inflammation which precludes GR.<sup>[12]</sup> The null hypothesis tested is that there should be no difference found regarding GT between CAF + DFGG and CAF + SCTG after 6 months. Given the existing gap of knowledge, this randomized clinical trial aimed to assess soft tissue augmentation achieved by CAF + DFGG versus CAF + SCTG for the management of Miller Class I and II GR.

## Materials and Methods

### Study population

This randomized clinical trial was registered in the Clinical trials.gov (ID: NCT03213483), approved by the Research

Ethics committee, Faculty of Dentistry, Cairo University (Approval number: 3-7-17), conducted in accordance with the Helsinki Declaration of 1975, as revised in 2013 and reported according to the CONSORT guidelines, 2012 [Figure 1].<sup>[13]</sup> This study included 28 Miller Class I and II GR patients (11 males and 17 females, aged 22–37 years) selected from the outpatient clinic, Department of Periodontology, Faculty of Dentistry, Cairo University, between October 2017 and January 2019, meeting the following inclusion criteria: single or multiple Miller’s Class I and II GR  $\geq 2$  mm in depth;<sup>[6]</sup> patients  $\geq 18$  years; periodontally and systemically healthy; presence of identifiable cemento-enamel junction (CEJ); and clinical indication and/or patient request for recession coverage and O’Leary index<sup>[14]</sup>  $< 20\%$ . Exclusion criteria included pregnant or lactating women, smokers, and teeth with cervical restorations/abrasion.

All patients provided written informed consent to participate in this trial. Initial patient examination was performed including full-mouth probing and radiographic examination to exclude presence of interproximal bone loss. Full-mouth supragingival scaling and 0.12% chlorhexidine HCL mouthwash (the Arab Drug Company for pharmaceutical and Chemical Industries CO., Cairo, Egypt) twice daily was prescribed for 2 weeks with patient motivation and oral hygiene instructions.

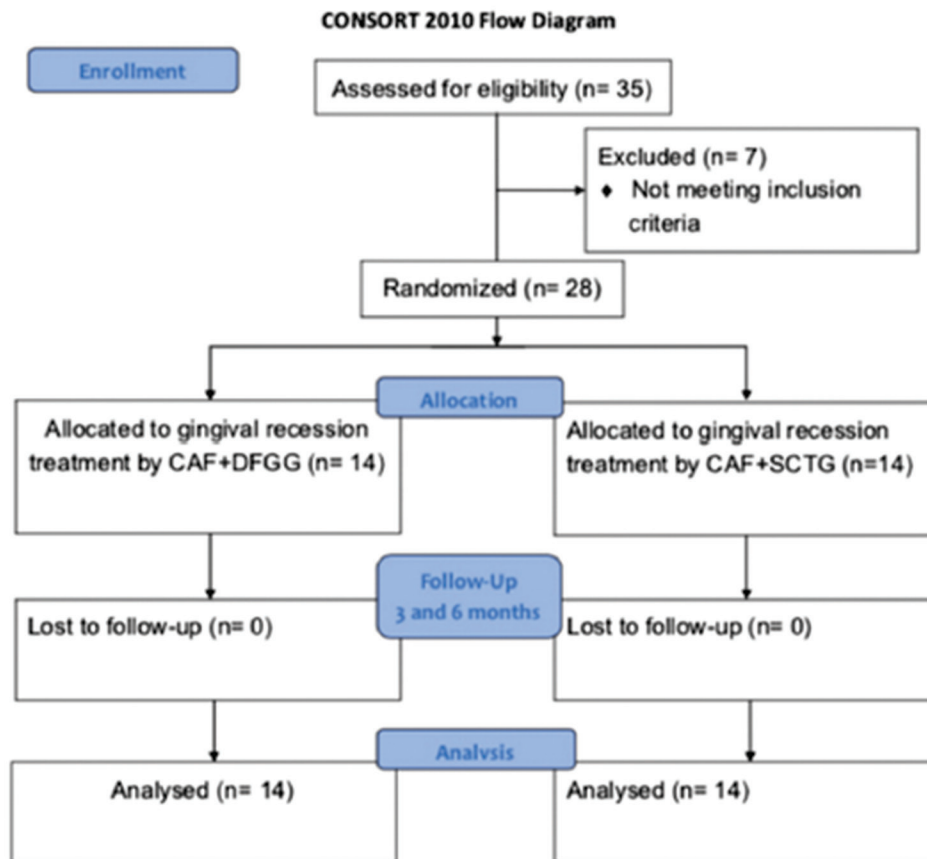


Figure 1: CONSORT flowchart of the study

## Randomization and blinding

Sequence generation was executed using simple randomization by generating numbers from 1:28 using [www.random.org](http://www.random.org) by an investigator (GN) not involved in recruitment nor treatment procedures. Allocation concealment was implemented by the same investigator using sequentially numbered, opaque, sealed envelopes handled to the surgeon (MM) who did not open them until the beginning of interventions. After pretreatment phase, eligible participants who agreed to complete the study were randomly assigned into two equal parallel groups with a 1:1 allocation ratio to receive either CAF + DFGG (test group) or CAF + SCTG (control group) based on generated sequence. Due to the differences in harvesting techniques, both the operating surgeon (MM) and the participants could not be blinded to the procedure. The outcome assessor (EW) and statistician (KK) were blinded.

## Clinical parameters

Clinical parameters were recorded at baseline and 3 and 6 months postoperatively by a single examiner (EW) who was blinded, trained, and calibrated with a good intraexaminer agreement (0.82  $\kappa$  value). Periodontal parameters recorded were GT as a primary outcome and secondary outcomes such as recession depth (RD), recession width (RW), percentage of root coverage, probing pocket depth (PPD), clinical attachment level (CAL), and width of keratinized tissue (KTW). Measurements were recorded and rounded to the highest millimeter using William's graduated periodontal probe (Martin™ graduated periodontal probe No. 43-357-00, KLS martin Group, Germany). GT was determined at a single point 1 mm apical to the gingival margin with a short anesthetic needle that was inserted perpendicular through gingiva until the bone was touched and a silicon stopper that was adjusted flushing with the surface and fixed with cyanoacrylate adhesive, and penetration depth was then measured.<sup>[15]</sup> Selection of the 6 months of follow-up was based on Jepsen *et al.*<sup>[16]</sup> who suggested that data after 6 months can be predictably used to foresee long-term outcomes of root coverage after CAF. Based on Cairo *et al.*,<sup>[17]</sup> root coverage esthetic score (RES) system was assessed 6 months postoperatively.

## Patient-reported outcomes

Postoperative pain was assessed using visual analog scale (VAS) with numbers from 0 to 10 at days 3 and 7 postoperatively. Postoperative stress and inability to chew were assessed using VAS 2 weeks postoperatively. Postoperative bleeding was assessed as binary question (Y/N) during the first 2 weeks and overall patient satisfaction was assessed as a binary question after 6 months.

## Treatment protocols

### Coronally advanced flap at the recipient site

In both groups, CAF was performed according to de Sanctis and Zucchelli:<sup>[18]</sup> two horizontal incisions were

performed, mesial and distal to the GR followed by two beveled oblique incisions extending to alveolar mucosa. Trapezoidal flap was elevated with “split-full-split” approach. The anatomic interdental papillae were de-epithelized to create connective tissue beds for suturing of surgical papillae. Graft width was measured as the RW with 3 mm connective tissue both mesial and distal, while graft height was adjusted at 4 mm.<sup>[10]</sup>

### Harvesting the subepithelial connective tissue graft

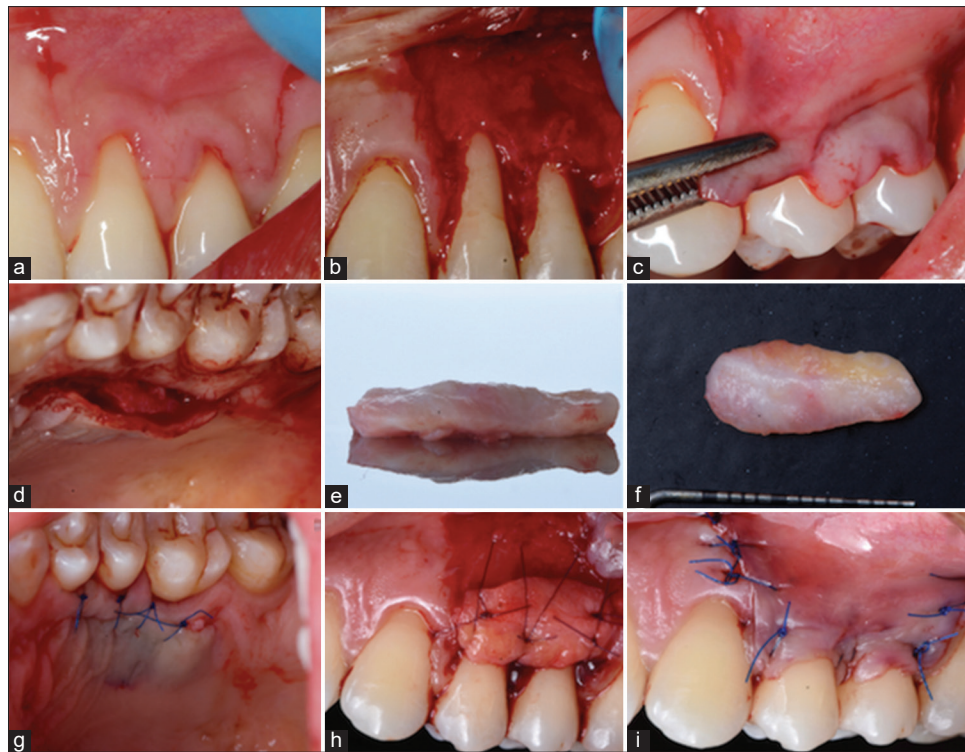SCTG was harvested from the palate using single incision technique [Figure 2] as described by Hürzeler and Weng:<sup>[2]</sup> A single incision was done 2 mm apical to the gingival margin, parallel to the palatal long axis. Partial thickness flap was then raised, and SCTG was separated by four down-to-bone incisions and harvested from underlying bone by blunt dissection. SCTG thickness was adjusted at 1 mm uniform thickness. The donor site was sutured using 5-0 polypropylene sutures (Polypropylene blue 5-0 Assut sutures, Assut Medical Sàrl, Switzerland). SCTG was then stabilized with two simple interrupted periosteal sutures and a sling suture using 6-0 resorbable sutures (Polyglycolic acid 6-0 Assut sutures, Assut Medical Sàrl, Switzerland). The flap was positioned 1 mm coronal to the CEJ. Suturing of the flap started with two apical interrupted periosteal sutures directed from the flap to the adjacent soft tissue using 5-0 polypropylene sutures and then proceeded coronally. A final sling suture allowed stabilization and adaptation of the flap.

### Harvesting the de-epithelialized free gingival graft

FGG was harvested from the palate as described by Zucchelli *et al.*<sup>[6]</sup> [Figure 3]: two horizontal and two vertical incisions delineating the graft, along the coronal horizontal incision. The blade was oriented perpendicular to the palate, and once an adequate soft tissue thickness was obtained, it was rotated to be almost parallel to the superficial surface. Upon harvesting, yellow fatty tissue was eliminated. The palatal wound was protected with gel foam and stabilized with sutures. The graft was de-epithelialized with a 15c blade while keeping the blade parallel to the external surface, and graft thickness was adjusted at 1 mm uniform thickness. The different consistency (epithelium is harder and rougher) and light reflection (epithelium reflects more light) helped ensure clinically removal of epithelium. DFGG was then stabilized and the flap was sutured like control group.

### Postsurgical phase

Postoperative analgesics three times daily (Ibuprofen 600 mg Abbott, Egypt) and systemic antibiotics twice daily (Amoxicillin 500 mg Cap., Egyptian Int. Pharmaceutical Industrial Co., A. R. E) were prescribed for 5 days. Patients were instructed to rinse with 0.12% chlorhexidine HCL three times a day for 2 weeks and to avoid any hard brushing and trauma to the surgical site. Sutures were removed 14 days postsurgically, and then patients were



**Figure 2: Overview of CAF + SCTG procedure: (a) Trapezoidal flap, (b) papillae de-epithelialization, (c) flap advancement, (d) single line incision and SCTG, (e) SCTG after being harvested, (f) SCTG, (g) suturing of donor site, (h) SCTG sutured, (i) suturing of flap. CAF: Coronally advanced flap, SCTG: Subepithelial connective tissue graft**

instructed to gently brush the operated area with a soft tooth brush using roll technique.<sup>[6]</sup>

#### Statistical and power analysis

A total sample size of 22 patients was calculated to detect a mean difference of 0.218<sup>[6]</sup> in GT between the two groups, with a level of significance  $\alpha = 0.05$  and 80% power, which was increased to 28 patients to compensate for dropouts (Power and sample size program: biostat.mc.vanderbilt.edu/twiki/bin/view/Main/Power Sample Size). The data were explored for normality by Kolmogorov–Smirnov and Shapiro–Wilk tests and presented as mean, standard deviation, mean difference, 95% confidence interval (CI), median and range, and frequencies and percentages. For parametric data, ANOVA and unpaired Student's *t*-test were used; for nonparametric data, Mann–Whitney test was used; and for qualitative data, Fisher's Exact test was used. Significance level was set at  $P \leq 0.05$ . Statistical analysis was performed with IBM SPSS Statistics (IBM SPSS Statistics for Windows Version 23.0, IBM Corp., Armonk, NY, USA).

#### Results

Figure 4 shows preoperative and 6-month postoperative clinical photographs of the two groups.

#### Clinical parameters

Table 1 shows clinical parameters recorded for both groups throughout the study. There was no significant

difference between both groups regarding baseline parameters. After 3 and 6 months, both DFGG and SCTG groups demonstrated a significant increase in the mean GT and KTW compared to baseline values. The DFGG group showed a significant increase in GT after 6 months compared to 3 months. Interestingly, sites treated with DFGG showed a significant increase in GT compared to SCTG after 6 months. Nevertheless, no significant difference was observed between the two groups regarding all other clinical parameters at different periods. Patients treated with DFGG achieved  $96.4\% \pm 13.4\%$  root coverage after 6 months, while SCTG obtained  $95.2\% \pm 17.8\%$  root coverage with no significant difference ( $P = 0.843$ ) between them. Both groups achieved  $92.9\% \pm 17.8\%$  of colorectal cancer (CRC) after 6 months and showed an equal risk (0.071) of not achieving CRC after 6 months, with an odds ratio of 1 (0.06%–17.75, 95% CI). The mean RES scores after 6 months were  $9.5 \pm 0.65$  and  $9.29 \pm 0.83$  for DFGG and SCTG groups, respectively, with no significant difference ( $P = 0.452$ ) between them.

#### Patient-reported outcomes

The VAS median (range) values of postoperative pain after 3 days were 3 (2–4) and 2 (1–9) for DFGG and SCTG, respectively, with a significant difference ( $P = 0.007$ ) between them. Nevertheless, at 7 days postsurgically, both groups reported a decrease in the VAS median (range) values of postoperative pain, showing 0 (0–2)

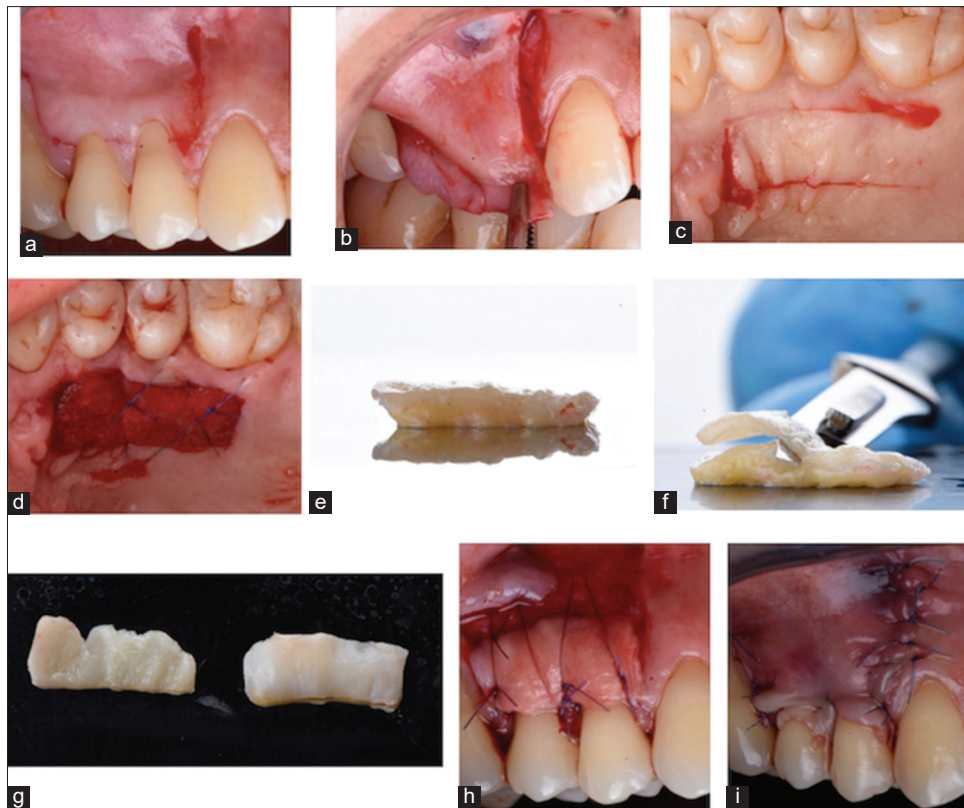


Figure 3: Overview of CAF + DFGG procedure: (a) Trapezoidal flap, (b) flap advancement, (c) horizontal and vertical incisions, (d) gel foam, (e) FGG after harvesting, (f) de-epithelialization of the graft, (g) different light reflection, (h) DFGG sutured, (i) suturing of flap. CAF: Coronally advanced flap, DFGG: De-epithelialized free gingival graft

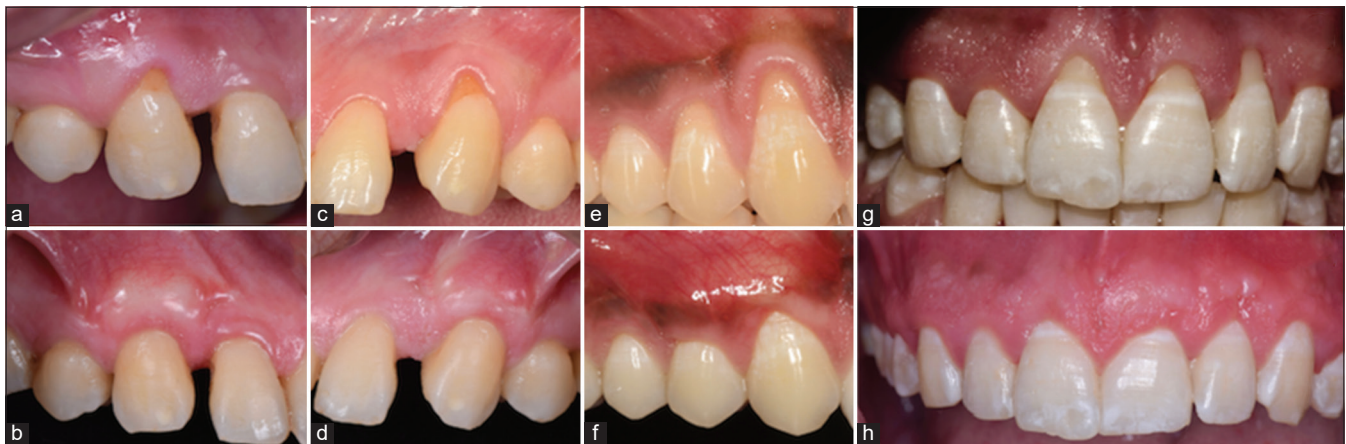

Figure 4: Preoperative and 6 months postoperative clinical photographs: (a) 2 mm recession at the maxillary right canine, (b) CAF + SCTG showing CRC after 6 months, (c) 2 mm recession at maxillary left canine, (d) CAF + SCTG showing CRC after 6 months, (e) 3 mm recession at the maxillary right canine, 2 mm at the maxillary right first premolar (f) CAF + DFGG showing CRC after 6 months, (g) recession at maxillary right central (2 mm), maxillary left central (2 mm) and left lateral (3 mm) (h) CAF + DFGG showing CRC after 6 months. CAF: Coronally advanced flap, DFGG: De-epithelialized free gingival graft, SCTG: Subepithelial connective tissue graft, CRC: Colorectal cancer

and 0 (0–9) for DFGG and SCTG, respectively, with no significant difference ( $P = 0.959$ ) between them. Both groups showed a significant decrease ( $P = 0.001$ ) in pain-related VAS values after 7 days compared to 3 days postsurgically. The VAS median (range) values of postoperative stress were 5 (3–8) and 0 (0–10) and for inability to chew were 4 (2–9) and 1 (0–9) after 2 weeks for DFGG and SCTG, respectively, with a significant

difference ( $P < 0.001$ ) between them. Postoperative bleeding after 2 weeks occurred in only one case (7.14%) in DFGG group where a hematoma developed in the donor site and ruptured causing bleeding that healed without complications. Patients treated with SCTG did not report any complications related to bleeding. Overall patient's satisfaction with the whole procedure was equally reported (92.9%) by both groups after 6 months.

**Table 1: Clinical parameters of both studied groups throughout the experimental period**

	DFGG, mean±SD	SCTG, mean±SD	Mean difference (95% CI)	P
GT mm				
Baseline	1 <sup>a</sup> ±0	1 <sup>a</sup> ±0	0 (0–0)	NA
3 months	2.57 <sup>b</sup> ±0.51	2.21 <sup>b</sup> ±0.43	0.36 (–0.01–0.72)	0.06
6 months	2.92 <sup>c</sup> ±0.62	2.21 <sup>b</sup> ±0.43	0.71 (0.3–1.13)	0.001*
P	<0.001*	<0.001*		
KTW mm				
Baseline	2.64 <sup>a</sup> ±1	2.71 <sup>a</sup> ±0.83	–0.07 (–0.79–0.64)	0.839
3 months	3.64 <sup>b</sup> ±0.84	3.71 <sup>b</sup> ±0.83	–0.07 (–0.72–0.58)	0.82
6 months	3.64 <sup>b</sup> ±0.84	3.79 <sup>b</sup> ±0.8	–0.15 (–0.78–0.5)	0.65
P	<0.001*	<0.001*		
PD mm				
Baseline	1.07 <sup>a</sup> ±0.27	1.29 <sup>a</sup> ±0.47	–0.21 (–0.51–0.08)	0.149
3 months	1.57 <sup>b</sup> ±0.51	1.2 <sup>a</sup> ±0.43	0.36 (–0.01–0.72)	0.06
6 months	1.57 <sup>b</sup> ±0.51	1.21 <sup>a</sup> ±0.43	0.36 (–0.01–0.72)	0.06
P	<0.001*	0.52		
RD mm				
Baseline	2.14 <sup>a</sup> ±0.66	2.07 <sup>a</sup> ±0.62	0.07 (–0.43–0.57)	0.752
3 months	0.07 <sup>b</sup> ±0.27	0.14 <sup>b</sup> ±0.53	0.07 (–0.4–0.26)	0.959
6 months	0.07 <sup>b</sup> ±0.27	0.14 <sup>b</sup> ±0.53	0.07 (–0.4–0.26)	0.959
P	<0.001*	<0.001*		
RW mm				
Baseline	2.14 <sup>a</sup> ±0.86	2.21 <sup>a</sup> ±0.43	–0.07 (–0.6–0.46)	0.666
3 months	0 <sup>b</sup> ±0	0.29 <sup>b</sup> ±0.73	–0.29 (–0.69–0.11)	0.15
6 months	0 <sup>b</sup> ±0	0.29 <sup>b</sup> ±0.73	–0.29 (–0.69–0.11)	0.15
P	<0.001*	<0.001*		
CAL mm				
Baseline	3.21 <sup>a</sup> ±0.7	3.36 <sup>a</sup> ±0.74	–0.14 (–0.7–0.42)	0.548
3 months	1 <sup>b</sup> ±0.68	1.36 <sup>b</sup> ±0.63	–0.36 (–0.87–0.15)	0.204
6 months	1.07 <sup>b</sup> ±0.73	1.36 <sup>b</sup> ±0.63	–0.29 (–0.82–0.25)	0.37
P	<0.001*	<0.001*		

\*Significant at  $P \leq 0.05$ . Different superscripts in the same column are statistically significantly different. NA: Not applicable; DFGG: De-epithelialized free gingival graft; SCTG: Subepithelial connective tissue graft; SD: Standard deviation; CI: Confidence interval; GT: Gingival thickness; KTW: Keratinized tissue width; RD: Recession depth; RW: Recession width; PD: Pocket depth; CAL: Clinical attachment level

## Discussion

The periodontal literature is in constant search for efficient CTG harvesting techniques to minimize patient's morbidity and obtain better quality connective tissue for enhancing root coverage outcomes. This led to emergence of the DFGG by Zucchelli *et al.*,<sup>[6]</sup> being denser, firmer, and more stable than SCTG.<sup>[7]</sup> Although DFGG would risk including some of the epithelium in the graft, a histologic study in humans reported that epithelial remnants were found in 80% of CTGs and still didn't affect the root coverage outcomes.<sup>[19]</sup> To the best of the authors' knowledge, this is the first randomized clinical trial comparing soft tissue augmentation using DFGG compared to SCTG with single-line incision in the management of Miller Class I and II GR. The graft was de-epithelialized with a 15c blade to enable better visualization and ensure complete removal of epithelium, which was consistent with a recent report showing no significant difference between de-epithelialization using blade or abrasion.<sup>[20]</sup>

The current results showed that SCTG significantly increased GT and KTW, reduced RD and RW, and achieved 92.9% CRC after 6 months, which are consistent with numerous studies investigating SCTG as a surgical treatment for root coverage.<sup>[21–23]</sup> These observations are supported by previous systematic reviews concluding that SCTG provided significant root coverage as well as keratinized tissue gain.<sup>[3,24,25]</sup> This study also showed that SCTG significantly increased GT after 6 months versus baseline, which was in line with previous reports,<sup>[15,26]</sup> yet the effect of this improvement in preventing future GR needs to be further investigated in clinical trials with longer follow-up periods. In this trial, SCTG achieved a 95.2% root coverage after 6 months, which was superior to Moslemi *et al.*<sup>[27]</sup> (69%) and in agreement with several studies as Zucchelli *et al.*,<sup>[6]</sup> Cardaropoli *et al.*,<sup>[26]</sup> and Rosetti *et al.*<sup>[28]</sup> reporting 91.6%, 96.97%, and 95.5%, respectively.

In addition, this investigation demonstrated that DFGG significantly increased GT and KTW and reduced

RD and RW besides achieving 96.4% root coverage after 6 months, which is in accordance with previous studies<sup>[6,8,10]</sup> and in support with the results of a recent systemic review.<sup>[11]</sup> Similarly, Zucchelli *et al.*<sup>[6]</sup> reported 96.5% root coverage after using DFGG. Interestingly, DFGG group achieved a significant increase in GT from 3 to 6 months postoperatively, which might be attributed to the better quality of the harvested CTG. This was based on previous histologic studies,<sup>[7,29]</sup> which proved that epithelial differentiation is mainly influenced by the underlying connective tissue, suggesting that CTG obtained by de-epithelialization of a FGG might enhance keratinization of the overlying epithelium. Furthermore, this study achieved a 92.9% of CRC 6 months after using DFGG, which was superior than Zucchelli *et al.*<sup>[6]</sup> (85%) and (83%)<sup>[10]</sup> who included smokers. Inferior results were also shown by Zucchelli *et al.*<sup>[8]</sup> comparing DFGG with (88%) and without (48%) removing the labial submucosal tissue at the recipient site. A tenable explanation for these discrepancies might be the inclusion of deep GR affecting lower incisors only, which are less predictable than maxillary teeth in achieving CRC.<sup>[30]</sup>

The current analysis revealed that both DFGG and SCTG demonstrated significant clinical outcomes in terms of RD, RW, PPD, CAL, KTW, and % of root coverage and RES after 6 months and both achieved 92.9% CRC. In a more clinical sense, although no statistically significant difference was detected, both procedures were clinically effective in improving root coverage outcomes. These findings may be attributed to the fact that both techniques are inherently similar regarding their success rates in obtaining root coverage.<sup>[6]</sup>

Interestingly, DFGG showed a significant increase in GT after 6 months compared to SCTG, which is a statistical and clinical evidence proving the superior quality of CTG harvested by DFGG over SCTG. It is scientifically established that keratinization of the gingival epithelium is influenced by induction from the underlying connective tissue.<sup>[29,31,32]</sup> This might explain the superiority observed in DFGG group which by providing more stable, fibrous, and better-quality connective tissue resulted in increasing GT more than SCTG. Moreover, the main privileges currently noted with DFGG were the ease of harvesting regardless the thickness of palatal fibromucosa, ability to obtain grafts of controlled dimensions, firmer, and better CTG quality during suturing besides enhancing GT. Collectively, DFGG might be suggested as a suitable alternative to SCTG as a root coverage procedure.

The DFGG group revealed significant higher pain scores than SCTG group 3 days postsurgically, which is consistent with previous studies,<sup>[33-35]</sup> which might be due to the open wound healing by secondary intention in DFGG group versus the primary intention wound

healing in SCTG group. However, pain scores showed no significant difference after 7 days between both groups. This was consistent with Zucchelli *et al.*<sup>[6]</sup> reporting similar pain killer consumption postsurgically between patients treated with DFGG and SCTG and also in accordance with McGuire *et al.*<sup>[36]</sup> who stated that pain after free gingival grafts was highest over the first week then diminished significantly. Meanwhile, DFGG showed significant higher stress and inability to chew scores than SCTG which might be attributed to the open palatal wound where patients were afraid of jeopardizing the healing of the palatal wound, thus avoided chewing on this side. To explain such results, Zucchelli *et al.*<sup>[6]</sup> speculated that the presence of a soft tissue closing and protecting the donor site at least for the first week in patients treated with SCTG helped greatly in reducing stress and forgetting about the presence of the palatal wound. Nevertheless, both groups showed the same overall percentage of patient satisfaction (92.9%).

It must be emphasized that Zucchelli *et al.*<sup>[6]</sup> performed a trap-door technique<sup>[31]</sup> for harvesting a SCTG, which employs two vertical incisions causing interruption of the palatal blood supply with an increased risk for palatal sloughing and flap necrosis in 28% of subjects. To decrease patient's morbidity, SCTG harvesting in this investigation was performed by single-incision technique to avoid vertical incisions, which assures an un-interrupted palatal blood supply, thus preventing palatal sloughing. In the same context, only one patient assigned to the SCTG group experienced palatal flap necrosis associated with severe postoperative pain, which might be caused by thinning of the palatal flap while harvesting.

## Conclusions

Within the limitations of this study, it might be concluded that DFGG is a promising method for harvesting a CTG and significantly enhanced GT after 6 months. This study paves the way for future randomized clinical trials with longer follow-ups and larger sample sizes investigating different CTG harvesting techniques.

## Acknowledgment

The authors would like to thank Dr. Khaled Keraa for his help in the statistical analysis of this work. The authors would also like to thank Dr. Omar Hesham Salah and Dr. Mohamed Aref for their help with clinical photographs and documenting the clinical cases.

## Financial support and sponsorship

The study was self-funded by the authors to be refunded later by the Ministry of Higher Education, Cairo, Egypt on international publishing.

## Conflicts of interest

There are no conflicts of interest.

## References

- Lindhe J, Lang N, Karring T. Clinical periodontology and implant dentistry. 5<sup>th</sup> ed. Ernes E, editor. Oxford: Blackwell Munksgaard; 2008.
- Hürzeler MB, Weng D. A single-incision technique to harvest subepithelial connective tissue grafts from the palate. *Int J Periodontics Restorative Dent* 1999;19:279-87.
- Chambrone L, Chambrone D, Pustiglioni FE, Chambrone LA, Lima LA. Can subepithelial connective tissue grafts be considered the gold standard procedure in the treatment of Miller Class I and II recession-type defects? *J Dent* 2008;36:659-71.
- Cortellini P, Tonetti M, Baldi C, Francetti L, Rasperini G, Rotundo R, *et al.* Does placement of a connective tissue graft improve the outcomes of coronally advanced flap for coverage of single gingival recessions in upper anterior teeth? A multi-centre, randomized, double-blind, clinical trial. *J Clin Periodontol* 2009;36:68-79.
- Cairo F, Nieri M, Pagliaro U. Efficacy of periodontal plastic surgery procedures in the treatment of localized facial gingival recessions. A systematic review. *J Clin Periodontol* 2014;41 Suppl 15:S44-62.
- Zucchelli G, Mele M, Stefanini M, Mazzotti C, Marzadori M, Montebugnoli L, *et al.* Patient morbidity and root coverage outcome after subepithelial connective tissue and de-epithelialized grafts: A comparative randomized-controlled clinical trial. *J Clin Periodontol* 2010;37:728-38.
- Bertl K, Piffl M, Hirtler L, Rendl B, Nürnberger S, Stavropoulos A, *et al.* Relative composition of fibrous connective and fatty/glandular tissue in connective tissue grafts depends on the harvesting technique but not the donor site of the hard palate. *J Periodontol* 2015;86:1331-9.
- Zucchelli G, Marzadori M, Mounssif I, Mazzotti C, Stefanini M. Coronally advanced flap+connective tissue graft techniques for the treatment of deep gingival recession in the lower incisors. A controlled randomized clinical trial. *J Clin Periodontol* 2014;41:806-13.
- Zucchelli G, Mounssif I, Mazzotti C, Stefanini M, Marzadori M, Petracchi E, *et al.* Coronally advanced flap with and without connective tissue graft for the treatment of multiple gingival recessions: A comparative short- and long-term controlled randomized clinical trial. *J Clin Periodontol* 2014;41:396-403.
- Zucchelli G, Mounssif I, Mazzotti C, Montebugnoli L, Sangiorgi M, Mele M, *et al.* Does the dimension of the graft influence patient morbidity and root coverage outcomes? A randomized controlled clinical trial. *J Clin Periodontol* 2014;41:708-16.
- Tavelli L, Ravidà A, Lin GH, Del Amo FS, Tattan M, Wang HL. Comparison between subepithelial connective tissue graft and de-epithelialized gingival graft: A systematic review and a meta-analysis. *J Int Acad Periodontol* 2019;21:82-96.
- Baker DL, Seymour GJ. The possible pathogenesis of gingival recession. A histological study of induced recession in the rat. *J Clin Periodontol* 1976;3:208-19.
- Moher D, Hopewell S, Schulz KF, Montori V, Gøtzsche PC, Devereaux PJ, *et al.* CONSORT 2010 explanation and elaboration: Updated guidelines for reporting parallel group randomised trials. *Int J Surg* 2012;10:28-55.
- O'Leary TJ, Drake RB, Naylor JE. The plaque control record. *J Periodontol* 1972;43:38.
- Paolantonio M, Dolci M, Esposito P, D'Archivio D, Lisanti L, Di Luccio A, *et al.* Subpedicle acellular dermal matrix graft and autogenous connective tissue graft in the treatment of gingival recessions: A comparative 1-year clinical study. *J Periodontol* 2002;73:1299-307.
- Jepsen K, Stefanini M, Sanz M, Zucchelli G, Jepsen S. Long-Term Stability of Root Coverage by Coronally Advanced Flap Procedures. *J Periodontol* 2017;88:626-33.
- Cairo F, Rotundo R, Miller PD, Pini Prato GP. Root coverage esthetic score: A system to evaluate the esthetic outcome of the treatment of gingival recession through evaluation of clinical cases. *J Periodontol* 2009;80:705-10.
- de Sanctis M, Zucchelli G. Coronally advanced flap: A modified surgical approach for isolated recession-type defects: Three-year results. *J Clin Periodontol* 2007;34:262-8.
- Harris RJ. Histologic evaluation of connective tissue grafts in humans. *Int J Periodontics Restorative Dent* 2003;23:575-83.
- Marques de Mattos P, Papalexou V, Tramontina VA, Kim SH, Luczyszyn SM, Bettega PVC, *et al.* Evaluation of 2 techniques of epithelial removal in subepithelial connective tissue graft surgery: A comparative histological study. *J Periodontal Implant Sci* 2020;50:2-13.
- Cairo F, Cortellini P, Tonetti M, Nieri M, Mervelt J, Cincinelli S, *et al.* Coronally advanced flap with and without connective tissue graft for the treatment of single maxillary gingival recession with loss of inter-dental attachment. A randomized controlled clinical trial. *J Clin Periodontol* 2012;39:760-8.
- McGuire MK, Scheyer ET, Nunn M. Evaluation of human recession defects treated with coronally advanced flaps and either enamel matrix derivative or connective tissue: Comparison of clinical parameters at 10 years. *J Periodontol* 2012;83:1353-62.
- Kuis D, Sciran I, Lajnert V, Snjaric D, Prpic J, Pezelj-Ribaric S, *et al.* Coronally advanced flap alone or with connective tissue graft in the treatment of single gingival recession defects: A long-term randomized clinical trial. *J Periodontol* 2013;84:1576-85.
- Pini-Prato G, Nieri M, Pagliaro U, Giorgi TS, La Marca M, Franceschi D, *et al.* Surgical treatment of single gingival recessions: Clinical guidelines. *Eur J Oral Implantol* 2014;7:9-43.
- Chambrone L, Tatakis DN. Periodontal soft tissue root coverage procedures: A systematic review from the AAP Regeneration Workshop. *J Periodontol* 2015;86 (2 Suppl):S8-51.
- Cardaropoli D, Tamagnone L, Roffredo A, Gaveglio L. Treatment of gingival recession defects using coronally advanced flap with a porcine collagen matrix compared to coronally advanced flap with connective tissue graft: A randomized controlled clinical trial. *J Periodontol* 2012;83:321-8.
- Moslemi N, Mousavi Jazi M, Haghghati F, Morovati SP, Jamali R. Acellular dermal matrix allograft versus subepithelial connective tissue graft in treatment of gingival recessions: A 5-year randomized clinical study. *J Clin Periodontol* 2011;38:1122-9.
- Rosetti EP, Marcantonio E Jr., Zuza EP, Marcantonio RA. Root coverage stability of the subepithelial connective tissue graft and guided tissue regeneration: A 30-month follow-up clinical trial. *J Dent* 2013;41:114-20.
- Karring T, Lang NP, Løe H. The role of gingival connective tissue in determining epithelial differentiation. *J Periodontol* 1975;10:1-1.
- Huang LH, Neiva RE, Wang HL. Factors affecting the outcomes of coronally advanced flap root coverage procedure. *J Periodontol* 2005;76:1729-34.
- Edel A. Clinical evaluation of free connective tissue grafts used to increase the width of keratinised gingiva. *J Clin Periodontol* 1974;1:185-96.
- de Luca M, Albanese E, Megna M, Cancedda R, Mangiante PE, Cadoni A, *et al.* Evidence that human oral epithelium



- reconstituted *in vitro* and transplanted onto patients with defects in the oral mucosa retains properties of the original donor site. *Transplantation* 1990;50:454-9.
33. Del Pizzo M, Modica F, Bethaz N, Priotto P, Romagnoli R. The connective tissue graft: A comparative clinical evaluation of wound healing at the palatal donor site. A preliminary study. *J Clin Periodontol* 2002;29:848-54.
  34. Griffin TJ, Cheung WS, Zavras AI, Damoulis PD. Postoperative complications following gingival augmentation procedures. *J Periodontol* 2006;77:2070-9.
  35. Wessel JR, Tatakis DN. Patient outcomes following subepithelial connective tissue graft and free gingival graft procedures. *J Periodontol* 2008;79:425-30.
  36. McGuire MK, Scheyer ET, Gwaltney C. Commentary: Incorporating patient-reported outcomes in periodontal clinical trials. *J Periodontol* 2014;85:1313-9.