



Case report

The direct anterior approach for acetabular augmentation in primary total hip arthroplasty

Erin Honcharuk, MD ^{a,*}, Stephen Kayiaros, MD ^a, Lee E. Rubin, MD ^b^a Department of Orthopaedics, Rutgers–Robert Wood Johnson University Hospital, New Brunswick, NJ, USA^b Department of Orthopaedics and Rehabilitation, Yale University School of Medicine, New Haven, CT, USA

ARTICLE INFO

Article history:

Received 30 January 2017

Received in revised form

13 March 2017

Accepted 13 March 2017

Available online 12 May 2017

Keywords:

Total hip arthroplasty

Direct anterior approach

Acetabular augment

Acetabular defect

ABSTRACT

Addressing acetabular bone defects can be difficult and depends on the amount of bone loss. Augments, either with bone or highly porous metals, are options that still allow the use of a hemispherical cup. Almost all previous research and publication on acetabular augments have focused on revision hip arthroplasty utilizing either a modified lateral or a posterolateral surgical approach. We describe 3 cases of augmenting acetabular bone defects through a direct anterior approach for primary total hip arthroplasty. We achieved proper cup placement, alignment, and augment incorporation while reconstructing complex acetabular deficiencies. All patients had complete pain relief and a satisfactory clinical outcome with stable radiographs at follow-up. With appropriate training, acetabular augmentation can be performed safely and efficiently with excellent clinical results through this approach.

© 2017 The Authors. Published by Elsevier Inc. on behalf of The American Association of Hip and Knee Surgeons. This is an open access article under the CC BY-NC-ND license (<http://creativecommons.org/licenses/by-nc-nd/4.0/>).

Introduction

Historically, osteolysis secondary to polyethylene wear after failed total hip arthroplasty (THA) often resulted in large peri-acetabular bone defects. Similar bone deficiency in the acetabulum can also be seen in patients with native hips secondary to developmental hip dysplasia, avascular necrosis, and inflammatory arthritis, among other causes. Managing acetabular defects in both primary and revision hip arthroplasty can be accomplished in several different ways depending on the amount of bone loss. The use of acetabular augments can add support when the acetabular dome alone is unable to properly support a hemispherical cup [1,2]. Initially, either bulk allograft or autograft bone grafts were used [3], but the advent and availability of highly porous metal augments have increased the number of available options for lateral rim augmentation.

Augments for the deficient acetabulum are most commonly performed via traditional laterally based approaches, including both the modified lateral and posterolateral approach. However, with the increasing popularity of the direct anterior approach (DAA), expert hip surgeons have become more comfortable managing revision hip arthroplasty through this approach. Exposure of the lateral acetabulum can be readily accomplished using the DAA and many acetabular defects can now be reconstructed using this surgical approach. We describe 3 similar cases of acetabular augmentation performed through the DAA for primary THA in the setting of Paprosky IIB and IIIA defects of the native hip joint. Finally, we discuss the outcomes of the DAA and the 2 reconstruction options presented for augmentation. This is the first report we are aware of that describes complex reconstruction of acetabular deficiency through the DAA.

Case histories

Case 1

This is a 72-year-old male, body mass index 29, with a nearly 1-year history of right hip pain. His past medical history is significant for alcoholism and he has currently been sober for the past 3 years. Radiographs of his right hip showed avascular necrosis of the femoral head with complete collapse and secondary

One or more of the authors of this paper have disclosed potential or pertinent conflicts of interest, which may include receipt of payment, either direct or indirect, institutional support, or association with an entity in the biomedical field which may be perceived to have potential conflict of interest with this work. For full disclosure statements refer to <http://dx.doi.org/10.1016/j.artd.2017.03.007>.

* Corresponding author. 1 RWJ Place, New Brunswick, NJ 08901, USA. Tel.: +1 732 235 7869.

E-mail address: ErinHoncharuk@gmail.com

<http://dx.doi.org/10.1016/j.artd.2017.03.007>

2352-3441/© 2017 The Authors. Published by Elsevier Inc. on behalf of The American Association of Hip and Knee Surgeons. This is an open access article under the CC BY-NC-ND license (<http://creativecommons.org/licenses/by-nc-nd/4.0/>).

degenerative changes (Fig. 1). There was also a Paprosky IIIA acetabular defect and hip subluxation. He was taken to the operating room (OR) for a THA utilizing the DAA.

Intraoperatively, the psoas tendon was found to be contracted that required a recession lengthening to facilitate exposure of the acetabulum. The defect was quite large and would be addressed with a highly porous metal augment. The cotyloid fossa and the transverse acetabular ligament were identified during the exposure to define the true acetabulum and reconstruct the hip center. Sequential reaming revealed that a 52-mm trial obtained excellent position and apposition between the anterior and posterior walls. The superior and lateral acetabular defect left nearly half of the cup uncovered. A 54 × 20 mm metal augment (GRIPTION TF; DePuy Synthes, Warsaw, IN) would be used for the reconstruction. With the trial cup in position and serving as the “scaffold,” the augment was secured to the ilium with 3 screws. Then the cup was impacted and secured first with a screw into the ischium, followed by 2 screws into the ilium. A small amount of cement was placed between the augment and the cup prior to final seating (Fig. 2a-c). Reconstruction of the femur ensued with a trial reduction of the hip followed by final implantation of the components. A single fluoroscopic image was obtained with the trials in place to confirm satisfactory position of the components and restoration of the hip center, leg length, and offset (Fig. 3). Postoperatively, he ambulated with a walker for protected weight bearing for 4 weeks. The patient was ambulating without assistive devices at 6 months postoperatively, and was completely pain free.

Case 2

This is a 69-year-old female, BMI 25.4, with a 1-year history of worsening left hip pain. She experienced severe pain, rated as 7/10, with notable grinding and crunching, and a feeling of shortening of the limb. There was no history of septic joint, prior hip trauma, or other known injury or prior surgery. There was no pain or symptoms in the contralateral right hip. She walked with a single-point cane and visible pelvic obliquity upon ambulation. Radiographs revealed severe osteoarthritis with femoral head collapse and irregularity of the joint surface (Fig. 4). Avascular necrosis with collapse was considered, but the patient had no known risk factors for the disease. A Paprosky IIB defect in the lateral rim was identified and anticipated during the templating process for a complex THA.

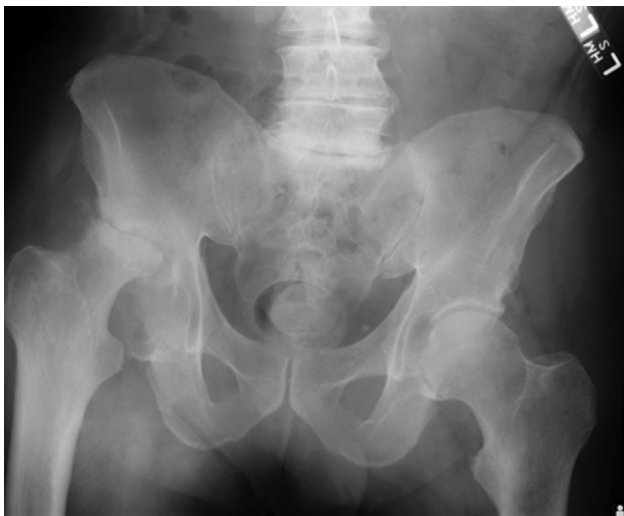


Figure 1. Preoperative anteroposterior pelvis radiograph of case 1 demonstrating avascular necrosis of the right femoral head with complete collapse, superolateral acetabular bone loss, and hip subluxation consistent with Paprosky 3A defect.

In the OR, a DAA was utilized on a radiolucent OR bed for exposure and the transverse acetabular ligament was identified for “cup-first” reconstruction, using anatomic placement of a 58-mm DePuy multihole revision acetabular shell with 2 screws placed into the posterior column. Next, attempted preparation for a 58 × 10 mm metallic augment was made with the manufacturer’s rasps and a burr, but the augment size proved to be too large to fit the patient’s anatomy without further bone compromise. A significant bone defect was identified between the lateral shell and the residual lateral ilium, so the most eburnated apex portion of the native femoral head was identified. Two custom autologous trapezoidal bone wedges were created from this area of bone using the sagittal saw, then each was impacted into the lateral defect for a press-fit custom augment reconstruction (Fig. 5a and b). Two additional screws were placed into the construct to achieve a secure fit. A 36-mm neutral liner was secured, and a #6 high-offset Summit stem and +5 mm × 36 mm Metal head completed the construct. Postoperatively, she was listed as partial weight bearing with a rolling walker for 6 weeks (Fig. 6). She had virtually no pain during the recovery, and regained full range of motion, complete weight-bearing capability, and complete graft incorporation at the 12-month follow-up visit (Fig. 7).

Case 3

This is a 56-year-old female, BMI 23.9, with known bilateral hip osteoarthritis. She previously underwent contralateral right THA 3 years prior to presentation, with excellent pain relief, but with worsening left hip pain, limping, and a short left leg. Her hip was grinding and she often used both a cane and a walker for basic ambulation, describing herself as “chair bound,” with 10/10 discomfort and failure of numerous analgesic and nonsteroidal anti-inflammatory drug options previously. She had a known history of alcohol abuse and had previously been cancelled for the left hip replacement 1 year prior to presentation by another local surgeon. Her medical history was also significant for hepatitis C, bipolar disorder, anxiety, and depression, with $\frac{1}{2}$ pack of cigarette smoking daily. Radiographs demonstrated severe osteoarthritis with extensive cystic erosions of the acetabulum, and loss of the lateral rim consistent with a Paprosky grade IIB defect (Fig. 8). Additionally, she had baseline pelvic obliquity due to residual apex right adolescent idiopathic scoliosis, causing extrinsic elevation of the left hemipelvis and further shortening of the left lower extremity. With risk factor optimization, she was able to stop smoking completely, ceased all alcohol intake, and was otherwise stable and prepared for complex THA.

In the OR, a DAA was utilized on a radiolucent OR bed for exposure and the transverse acetabular ligament was identified for attempted cup-first reconstruction, using anatomic placement of a 52-mm DePuy multihole revision acetabular shell. Unfortunately, there was a very large lateral defect and the loss of the lateral buttress precluded stable cup placement. With a trial shell in place, we prepared the lateral ilium with a burr to accept a 50 × 15 mm metal augment (GRIPTION TF; DePuy Synthes) to re-create the lateral wall using an “augment-first” technique. This was secured to bleeding host bone with multiple screws, then the final shell was secured with bone cement at the interface and 3 screws placed into the posterior-superior quadrant. Finally, a neutral 36-mm liner was secured, and a #3 high-offset Trilock femoral stem and +5-mm Delta ceramic femoral head were used to complete the construct (Fig. 9). Postoperatively, her pain and grinding were completely relieved early on, and 4 weeks of shared weight bearing using a walker was utilized. She recovered uneventfully, and demonstrated osteointegration of the cup and augment at 12 months with complete restoration of gait mechanics (Fig. 10).

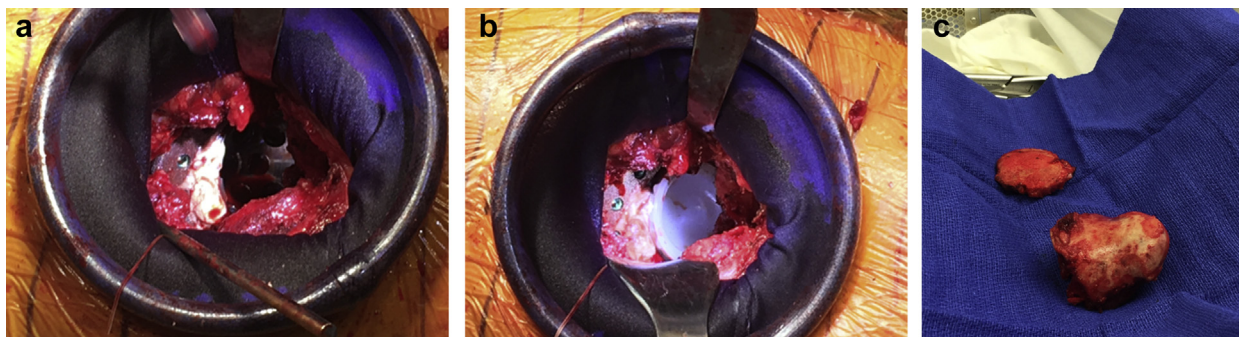


Figure 2. Intraoperative picture of the metal augument (a) cemented to the shell and (b) with the cup in place. (c) Gross picture of the femoral head showing severe deformation.

Discussion

There has been an increase in the utilization of the DAA for THA over the past 15 years with hopes of improving patient outcomes. This is a result of using a true internervous and intermuscular plane, with resultant less muscle dissection and damage. A cadaver study found increased damage to the gluteus minimus muscle and tendon with the mini-posterior vs DAA. However, there was similar muscular damage to the gluteus medius and increased damage to the tensor fascia lata and direct head of rectus femoris with the anterior approach. Furthermore, although all tendons of the external rotators required release in the posterior approach, only 50% required release of either piriformis or the conjoined tendon in the anterior approach [4].

Protecting the muscles around the hip may lead to decreased pain postoperatively and improved mobilization. Compared to the posterior approach, patients who had the DAA had less pain [2] and required less pain medications during their hospital stay [5]. In these first few postoperative days, they were also able to walk further distances [5]. Hospital length of stay was shorter [5,6], and more patients were discharged home vs rehabilitation center [7]. At 6 and 12 weeks postoperatively, only patients who had a DAA, vs an anterolateral approach, had improvement in single leg support and multiple walking parameters, such as stride length, cadence, and speed, compared to preoperative measurements [8]. Additionally, compared to the mini-posterior approach, the DAA allows for a

quicker time to single leg stance and absence of Trendelenburg sign [9]. Patients more quickly were able to ambulate without assistive devices [10] and, at 3 weeks, patients walked faster and fewer required an assistive device [9]. These improvements in walking scores were maintained out to 3 months postoperatively vs the posterolateral approach [5]. Although the approach has a learning curve of anywhere between 50 and 100 patients, over that time, there is a decrease in total number of complications and operative time, such that operative time and blood loss are similar to other approaches [7]. As surgeons become more comfortable with this approach, the indications for using DAA will also expand to include complex primary arthroplasty and revision cases.

Reconstructing acetabular bone loss can be challenging and depend on the type of defect. The Paprosky classification system for acetabular bone loss helps to guide reconstruction of the deficient acetabulum (Fig. 11). Type I defects have minimal bone loss and more than 70% of the prosthesis can be supported by host bone [2]. The implant may require screw fixation for adjunctive stability. Type II defects have distortion of the acetabular rim with destruction of part of the dome and/or medial wall but the anterior and posterior columns are intact [1]. The defects are further subdivided into A, B, and C. In type IIA, there is generalized oval enlargement of the acetabulum with superior dome bone loss; Kohler's line is intact as there is no ischial or teardrop osteolysis. In type IIB, the defect is superior and lateral. Although there is minimal teardrop and ischial osteolysis, Kohler's line is still intact. Furthermore, more than 50% of the prosthesis is in contact with host bone. In type IIC, there is loss of the medial wall defect with disruption of Kohler's line and moderate teardrop osteolysis. For all type II defects, a

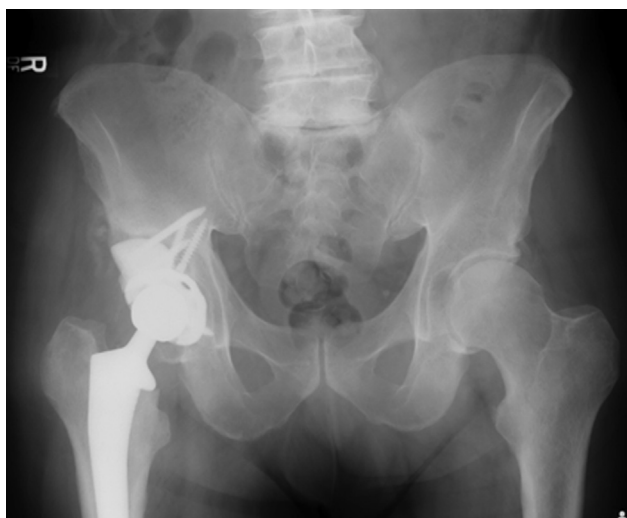

Figure 3. Immediate postoperative anteroposterior pelvis radiograph of case 1 with satisfactory position of component and restoration of leg lengths and hip center.

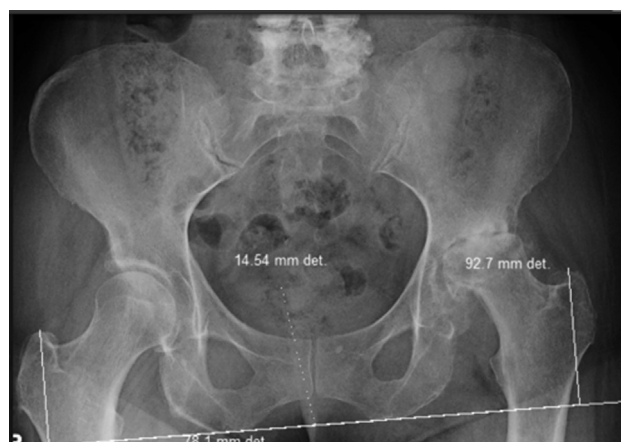

Figure 4. Preoperative anteroposterior pelvis radiograph of case 2 with evidence of femoral head collapse and severe osteoarthritis consistent with Paprosky 2B defect.

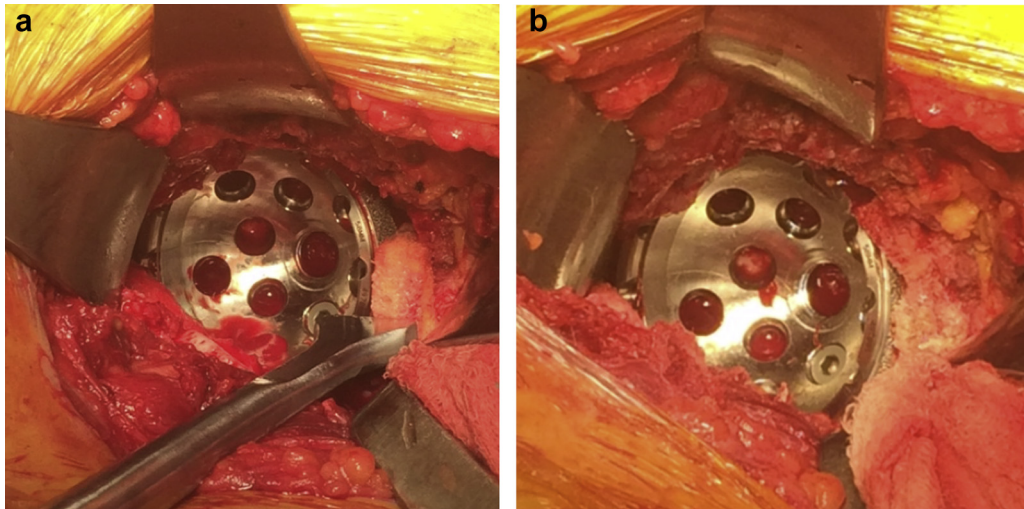


Figure 5. Intraoperative pictures of (a) the first autologous bone graft and (b) with both bone wedges in place.

hemispherical cup can be supported [1,2]; however, even with additional screw fixation, this still may require a high hip center reconstruction technique [11]. A recent biomechanical study reports that reconstruction with even minimal elevation of the hip center, over 5 mm, the acetabulum is exposed to increased stresses and a decrease in cortical bone mass [12]. As such, the use of highly porous metal augments or bone grafting is a viable option for these defect to add the necessary stability to the acetabular component [1,2,11].

Type III defects have severe bone loss and there is more than 2-cm superior migration of the hip center [1]. They are further subdivided as either IIIA or IIIB. Type IIIA defects are superolateral with 30%–60% of the acetabular rim missing. Although Kohler's line is intact, there is moderate teardrop and ischial osteolysis. In type IIIB defects, there is superomedial migration and more than 60% loss in bone stock. There is severe osteolysis of both the teardrop and the ischium with disruption of Kohler's line. Type IIIB has a higher incidence of pelvic discontinuity. For both type III defects, because the columns are not supportive, a hemispherical cup alone

cannot be used. Augmentation of the defect is required [2]. Surgical options for severe defects include jumbo cups, high hip center placement, impaction grafting with cement, bilobed oblong cups, ilioischial cages, structural allografts, highly porous metal augments, and the cup-cage construct [13]. Weeden and Paprosky [14] recommend that an augment or similar reconstruction technique for these severe defects be used to improve initial stability and promote osseous integration of the implant.

Structural bone grafts have been used since the 1980s for acetabular augmentation [3]. DeWal et al [3] examined 15 primary and 13 revision THAs that required acetabular augmentation with either allograft or autograft with adjuvant screw fixation. Radiographs for the primary THA group demonstrated lucencies in 7.7% of the components, but with 100% incorporation and no revisions at

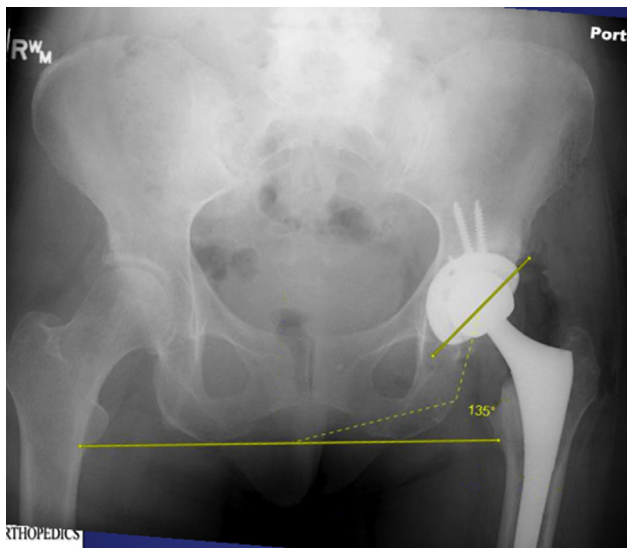


Figure 6. Immediate postoperative anteroposterior pelvis radiograph of case 2 with appropriate placement of the components and bone augments.

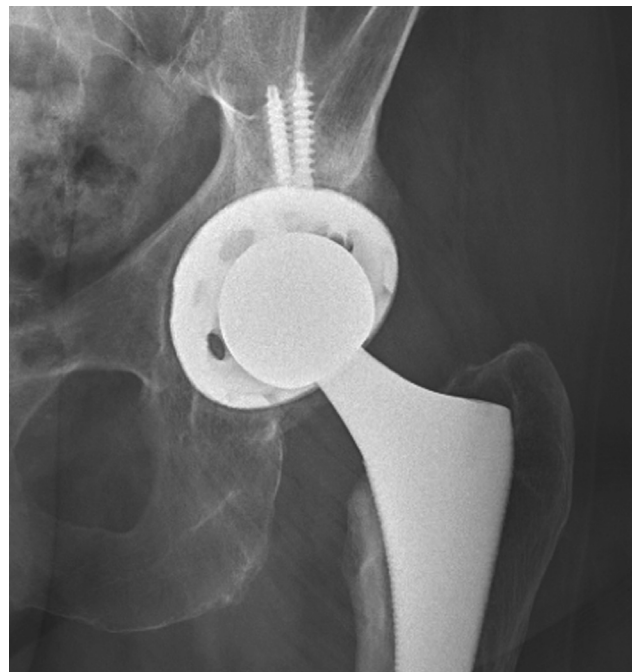

Figure 7. Anteroposterior hip radiograph of case 2 at 12 months demonstrating complete graft incorporation.

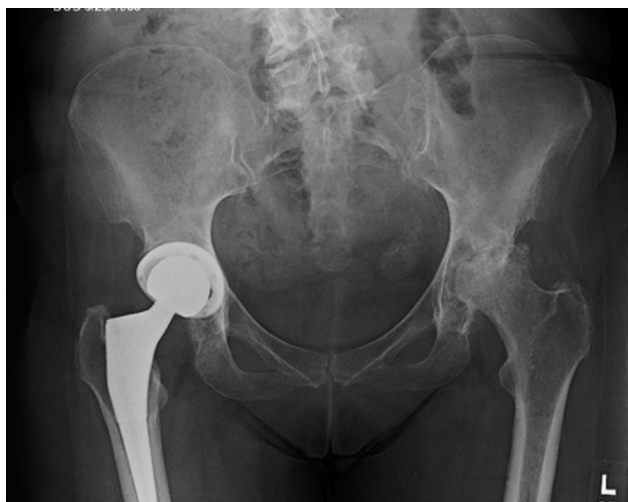

Figure 8. Preoperative anteroposterior pelvis radiograph of case 3 demonstrates severe osteoarthritis with extensive cystic erosions of the acetabulum, and loss of the lateral rim consistent with Paprosky 2B defect.

7.7 years of follow-up. In the revision group, the radiolucency rate was between 7.7% and 15.3% and 2 acetabular components were loose. One patient refused reoperation and the second was functional and did not want to proceed with surgical intervention. In 20 revision THAs with acetabular bone deficits treated with bone allograft, Merle d'Aubigne score improved from 10.9 to 16.2. At 6 years of follow-up, the survival rate was 84.4%, with 3 acetabular cups required for revision: the first for septic loosening, the second for aseptic cup loosening, and the third for recurrent dislocations. In the latter two, the bone graft was well incorporated and additional bone grafting was not needed [15]. Farrell et al [16] examined 28 primary THAs that required autologous bone grafting and reported minimal absorption of graft thickness, an average of 1 mm, during both medium- and long-term follow-up. Additionally, in 5 hips that required revision, 1 graft had substantial resorption, 2 grafts had minimal absorption, and the other 3 grafts showed healing and were intact. At 21 years of follow-up, survivorship for revisions requiring allograft for type IIIA defects was 72%. Most failures occurred early, on average 6.2 years postoperatively, for

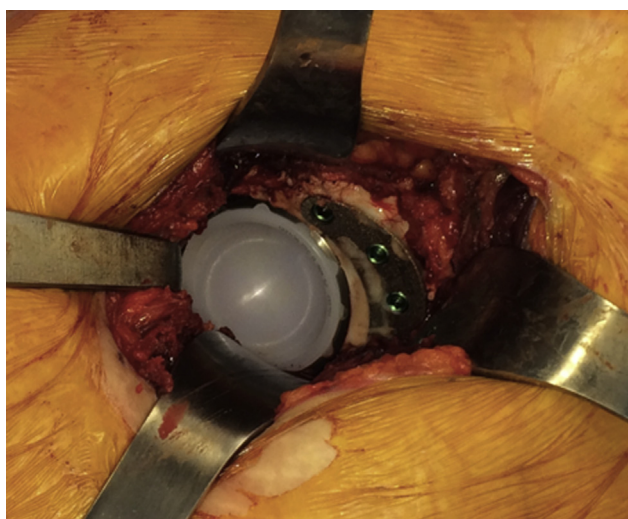


Figure 9. Intraoperative picture with a metal augment in place.

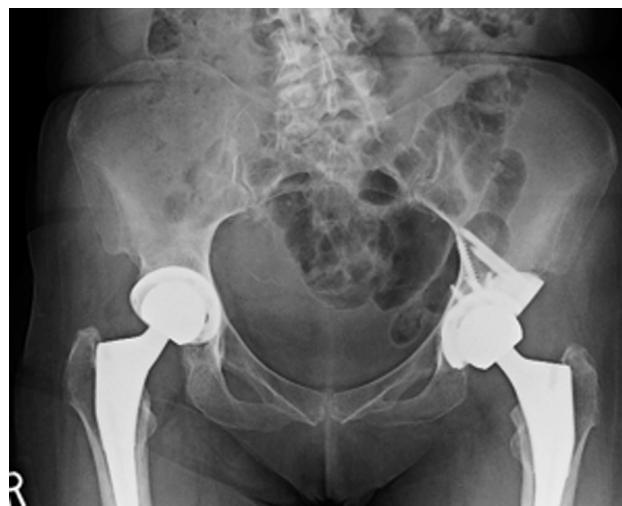

Figure 10. Anteroposterior pelvis radiograph of case 3 at 12 months demonstrating osteointegration of the cup and augment.

aseptic loosening. Re-revision found good incorporation of the allograft with no need of further augmentation [17].

The introduction of modular highly porous metal augments has provided another reconstructive option of acetabular augmentation while still allowing the use of an uncemented hemispherical acetabular component [18]. The high coefficient of friction of these materials allows for improved initial fixation and is superior in the presence of poor bone stock [19,20]. Several studies have reported on the outcomes of patients with use of highly porous metal augments. In a study of 16 revision THAs with Paprosky type II or III defects, they found that there were less patients with severe pain and with a severe limp [18]. Sporer and Paprosky evaluated patients with either type IIIA defects [19] or type IIIB defects [21] who underwent THA revision with follow-up for 1-4 years. They found an increase in the Postel-Merle d'Aubigne score: 6.8-10.6 in the IIIB group and 6.1-10.3 in the IIIA group. In the IIIA group, none of the patients showed signs of loosening and 1 patient required revision for instability. In the IIIB group, none of the patients required a revision; 1 patient had a broken screw and possible loosening, but was without symptoms.

In another study of 97 hips that underwent reconstruction with either IIA or IIB defects, with an average follow-up at an average of 45 months, the Harris Hip Score had a significant improvement from 55 to 76. Eighty-eight hips were in place and functioning well without any evidence of aseptic loosening. Ten hips had post-operative infections and 8 underwent 2-stage resection hip arthroplasty. The other 2 patients refused resection and were managed with irrigation and debridement with concomitant suppressive antibiotics. Another patient required cup revision and a constrained liner for chronic instability and fracture of the polyethylene liner. Two additional patients required liner exchange for loosening of the liner; the revision shells were stable intraoperatively with evidence of bony ingrowth [20]. Borlan et al [22] reported on 24 THA revisions that required highly porous metal augments and impaction bone grafting. Both cup position and abduction angle improved postoperatively and there was minimal migration, less than 5 mm, over an average 5-year follow-up. One patient required revision for a fractured augment; 3 patients had nonprogressive lucencies and 2 patients had lucencies suggestive of loosening, but both were asymptomatic [22]. In 8 patients who underwent a THA either primarily or for revision with the use of porous metal augments for IIA defects, there were no revisions at

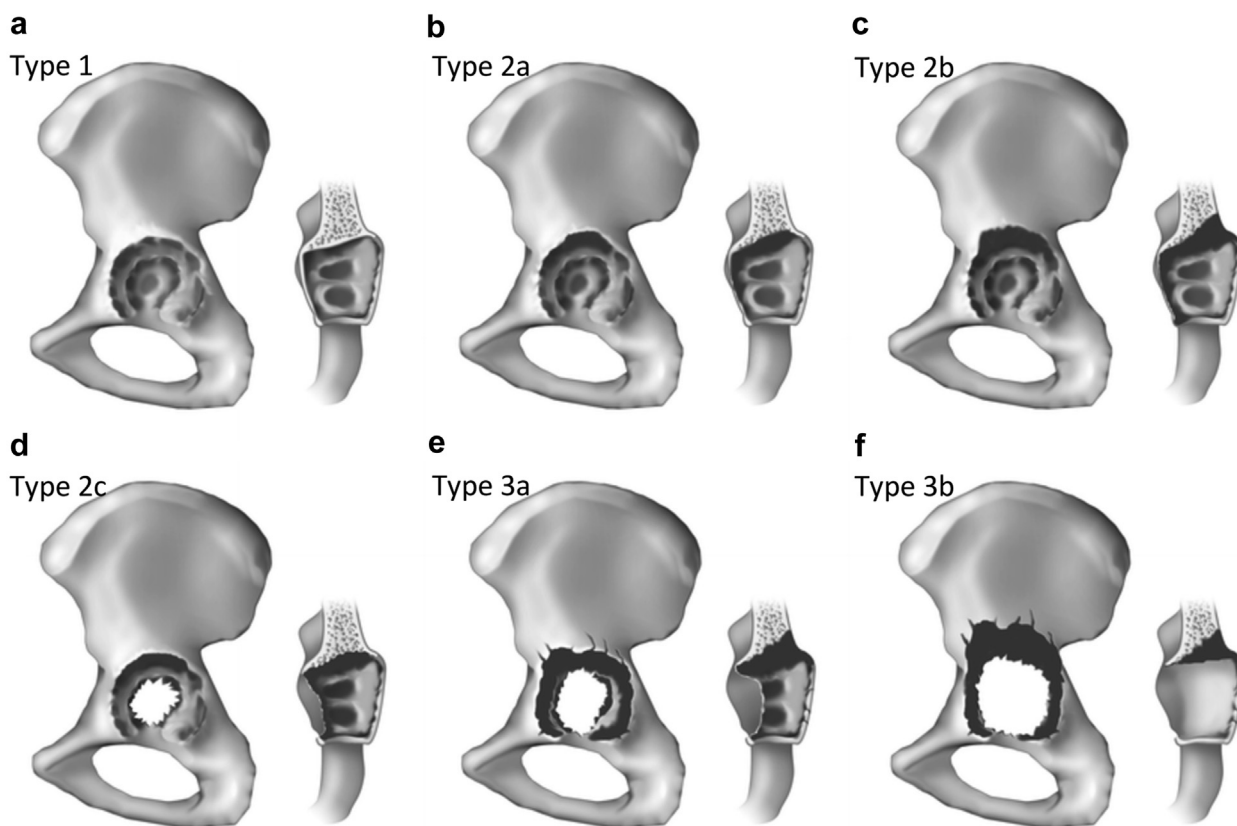


Figure 11. Paprosky classification of acetabular defects, (a) type 1, (b) type 2a, (c) type 2b, (d) type 2c, (e) type 3a, (f) type 3b [29].

2 years of follow-up and improvements in Harris Hip Scores from 27 to 85 [23].

Augmentation can also improve the location of the hip center. In a study examining 23 hips with either IIIA or IIIB defects treated with porous metal augments, preoperative mean location of the center of rotation of the hip was 41 mm vertical and 39 mm horizontal from the interteardrop line. The mean leg length discrepancy was 28 mm. Postoperatively, the location moved to an average of 26.3 mm vertically and 40.5 mm horizontally with a leg length discrepancy of 8.3 mm [24]. In another study, 34 THA revisions with acetabular defects ranging from type IIA to IIIB demonstrated improvement in the hip center from an average of 50 mm from the interteardrop line to 35 mm postoperatively [13].

Highly porous metal augments can reduce the need for custom fabrication of bone grafts or metallic implants and is thought to have a higher potential for biologic fixation [18]. Furthermore, the elastic modulus of trabecular metal is more similar to subchondral bone, which can improve load-directed bone remodeling and minimize stress shielding [13,20]. Overall, osteointegration is improved, which can be identified radiographically through 5 signs: radiolucent lines, superolateral buttress, medial stress shielding, radial trabeculae, and inferomedial buttress [13]. In 34 acetabular reconstructions at an average of 34 months, 20 showed 4 of 5 signs, 13 showed 3 signs, and 1 showed 2 signs. The last patient underwent revision for recurrent instability, and intraoperative examination revealed that the cup-augment construct was fully ingrown. Two patients in their series required revision for loose acetabular shells.

Although trabecular metal has a porosity of 80%, the augments used in this series (GRIPTION; DePuy Synthes) are 63% porous, and both these metal products allow for increased depth of bone ingrowth [19]. Trabecular metal is made from porous

tantalum, while GRIPTION is manufactured from a commercially pure titanium alloy structure and has the highest coefficient of friction at 1.2, vs 0.88 for trabecular metal, of all the open-celled metallic foams [25]. Most of the research has focused on trabecular metal [26] with Whitehouse et al [27] reporting a 92% survivorship after 10 years of trabecular metal augments. Mahmoud et al [28], using both trabecular metal and GRIPTION, found that metal augments are compatible with both cemented polyethylene cups and uncemented metal acetabular cups with survivorship over 95% for each. However, there was no comparison between the 2 augments in this study and, unfortunately, there is no peer-reviewed research thus far on GRIPTION [25], despite that multiple implant manufacturers have now developed augments with similar shape and purpose. Certainly, future research would be beneficial to evaluate and compare different materials of these augments to validate their stability, in-growth potential, and long-term outcomes. This particularly becomes important considering the restrictive contracting environment now present in many hospitals. Given the paucity of these complex cases that require augmentation, combined with existing vendor contract limitations and bundle-driven savings initiatives for primary hip arthroplasty cases, surgeons may be limited to which particular manufacturer's augmentation implant is available to them. This may be especially true if the augment is being used for a “complex” primary THA rather than a revision case, as hospital-based contracting is often less strict for selection of revision implants.

To the best of our knowledge, this is the first report in the literature demonstrating the use of acetabular augmentation for lateral rim defects through the DAA in complex primary THA. Our cases demonstrate that lateral rim exposure can be readily achieved using

the standard DAA exposure, and defects of the acetabulum can be reconstructed with either custom bone autograft press-fit wedges or highly porous metal augments. All cases demonstrated successful reconstruction of the hip center for optimizing hip biomechanics and restoration of leg length and offset. Reconstruction can be facilitated by use of a radiolucent OR bed or a specialized orthopaedic table at the surgeon's discretion, and the procedure can be accomplished using a cup-first or an augment-first surgical technique based on intraoperative exploration of the defect.

We believe that the DAA facilitates supine pelvic positioning and provides outstanding, anatomic acetabular exposure, thus facilitating augment placement to address lateral acetabular defects. One limitation of this series is the relatively short follow-up, which ranged from 6 to 12 months. Although the scope of our study was to report on our experience with this specific surgical technique, and while the 3 patients did well postoperatively, the short-term follow-up is a limitation and should be noted. Ultimately, patient outcome and implant survivorship will be important to note over time. Longer term follow-up of these cases and expansion of the series to include cases from multiple DAA centers will help to further define the role of the DAA in optimizing the reconstruction of these complex defects and also to determine if the subsequent revision rate can be reduced by optimizing the initial accuracy of hip reconstruction at the time of index arthroplasty.

Summary

Reconstruction of the acetabulum with significant bony rim defects during primary THA can be a challenge. Multiple options are currently available, including reconstruction with bone allograft, bone autograft, or highly porous metal augments. New techniques are improving long-term outcomes for implant survivorship. This is the first paper that reports on the use of these various techniques in primary THA through the DAA. More literature is needed on the long-term outcomes of these patients using modern acetabular implants and highly cross-linked polyethylene, and also to compare the DAA with other approaches regarding the accuracy of reconstruction and the optimization of the early postoperative recovery. Although a small series is presented here, these clinical and radiographic results are promising that acetabular augmentation can be effectively accomplished through the DAA.

References

- [1] Paprosky WG, Perona PG, Lawrence JM. Acetabular defect classification and surgical reconstruction in revision arthroplasty. A 6-year follow-up evaluation. *J Arthroplasty* 1994;9(1):33.
- [2] Sheth NP, Nelson CL, Springer BD, Fehring TK, Paprosky WG. Acetabular bone loss in revision total hip arthroplasty: evaluation and management. *J Am Acad Orthop Surg* 2013;21:128.
- [3] DeWal H, Chen F, Su E, Di Cesare PE. Use of structural bone graft with cementless acetabular cups in total hip arthroplasty. *J Arthroplasty* 2003;18(1):23.
- [4] Meneghini RM, Pagnano MW, Trousdale RT, Hozack WJ. Muscle damage during MIS total hip arthroplasty: Smith-Peterson versus posterior approach. *Clin Orthop Relat Res* 2006;453:293.
- [5] Barrett WP, Turner SE, Leopold JP. Prospective randomized study of direct anterior vs postero-lateral approach for total hip arthroplasty. *J Arthroplasty* 2013;28:1634.
- [6] Martin CT, Pugely AJ, Gao Y, Clark CR. A comparison of hospital length of stay and short-term morbidity between the anterior and posterior approaches to total hip arthroplasty. *J Arthroplasty* 2013;28(5):849.
- [7] Connolly KP, Kamath AF. Direct anterior total hip arthroplasty: comparative outcomes and contemporary results. *World J Orthop* 2016;7(2):94.
- [8] Mayr E, Nogler M, Benedetti MG, et al. A prospective randomized assessment of earlier functional recovery in THA patients by minimally invasive direct anterior approach: a gait analysis study. *Clin Biomech* 2009;24(10):812.
- [9] Nakata K, Nishikawa M, Yamamoto K, Hiroto S, Yoshikawa H. A clinical comparative study of the direct anterior with mini-posterior approach: two consecutive series. *J Arthroplasty* 2009;24(5):698.
- [10] Taunton MJ, Mason B, Odum SM, Springer BD. Direct anterior hip arthroplasty yields more rapid voluntary cessation of walking aids: a prospective, randomized clinical trial. *J Arthroplasty* 2014;29(9 Suppl):169.
- [11] Fernandez-Fairen M, Murcia A, Blanco A, et al. Revision of failed total hip arthroplasty acetabular cups to porous tantalum components. *J Arthroplasty* 2010;25(6):865.
- [12] Nie Y, Pei F, Li Z. Effect of high hip center on stress for dysplastic hip. *Orthopedics* 2014;37(7):e637.
- [13] Siegmeth A, Duncan CP, Masri BA, Kim WY, Garbus DS. Modular tantalum augments for acetabular defects in revision hip arthroplasty. *Clin Orthop Relat Res* 2009;467:199.
- [14] Weeden SH, Paprosky WG. Porous-ingrowth revision acetabular implants secured with peripheral screws: a minimum twelve-year follow-up. *J Bone Joint Surg Am* 2006;88(6):1266.
- [15] Traina F, Giardina F, De Clerico M, Toni A. Structural allograft and primary press-fit cup for severe acetabular deficiency: a minimum 6-year follow-up study. *Int Orthop* 2005;29(3):135.
- [16] Farrell CM, Berry DJ, Cabanela ME. Autogenous femoral head bone grafts for acetabular deficiency in total-hip arthroplasty for developmental dysplasia of the hip: long-term effect on pelvic bone stock. *J Arthroplasty* 2005;20(6):698.
- [17] Brown NM, Morrison J, Sporer SM, Paprosky WG. The use of structural distal femoral allograft for acetabular reconstruction of Paprosky type IIIA defects at a mean 21 years of follow-up. *J Arthroplasty* 2016;31(3):680.
- [18] Nehme A, Lewallen DG, Hanssen A. Modular porous metal augments for treatment of severe acetabular bone loss during revision hip arthroplasty. *Clin Orthop Relat Res* 2004;429:201.
- [19] Van Kleunen JP, Lee GC, Lementowski PW, Nelson CL, Garino JP. Acetabular revisions using trabecular metal cups and augments. *J Arthroplasty* 2009;24(6 Suppl):64.
- [20] Sporer SM, Paprosky WG. The use of a trabecular metal acetabular component and trabecular metal augment for severe acetabular defects. *J Arthroplasty* 2006;21(6 Suppl 2):83.
- [21] Sporer SM, Paprosky WG. Acetabular revision using a trabecular metal acetabular component for severe acetabular bone loss associated with a pelvic discontinuity. *J Arthroplasty* 2006;21(6 Suppl 2):87.
- [22] Borlan WS, Bhattacharya R, Holland JP, Brewster NT. Use of porous trabecular metal augments with impaction bone grafting in management of acetabular bone loss. *Acta Orthop* 2012;83(4):347.
- [23] Restepo C, Heller S, Chen AF. Tritanium acetabular wedge augments: short-term results. *Ann Transl Med* 2016;4(12):235.
- [24] Flecher X, Sporer S, Paprosky W. Management of severe bone loss in acetabular revision using a trabecular metal shell. *J Arthroplasty* 2008;23(7):949.
- [25] Levine BR, Fabi DW. Porous metals in orthopedic applications—a review. *Mat Wiss U Werkstofftech* 2010;41(12):1002.
- [26] Puliod L, Rachala SR, Cabanela ME. Cementless acetabular revision: past, present, and future. *Int Orthop* 2011;35(2):289.
- [27] Whitehouse MR, Masri BA, Duncan CP, Garbus DS. Continued good results with trabecular metal augments for acetabular defects in hip arthroplasty at 7 to 11 years. *Clin Orthop Relat Res* 2015;473(2):521.
- [28] Mahmoud AN, Sundberg M, Flivik G. Comparable results with porous metal augments in combination with either cemented or uncemented cups in revision hip arthroplasty: an analysis of one hundred forty-seven revisions at a mean of five years. *J Arthroplasty* 2017;32(5):1612.
- [29] Telleria JJM, Gee AO. Classifications in brief: Paprosky classification of acetabular bone loss. *Clin Orthop Relat Res* 2013;471:3725.