



## Review

## Is spinal tuberculosis changing with changing time?

Mohammad Noah Hasan Khan<sup>a,\*</sup>, Abdul Basit Jamal<sup>b</sup>, Auzair Hafeez<sup>c</sup>, Marium Sadiq<sup>d</sup>,  
Muhammad Umer Rasool<sup>e</sup>

<sup>a</sup> Royal Victoria Hospital, Belfast, Flat 3 Blenheim Court, 3 Westwood Road Southampton, United Kingdom

<sup>b</sup> Ittefaq Hospital Trust Lahore, Pakistan

<sup>c</sup> Ghurki Hospital Trust Lahore, Pakistan

<sup>d</sup> National University of Medical Sciences, Rawalpindi, Pakistan

<sup>e</sup> North Manchester General Hospital MFT, United Kingdom



## ARTICLE INFO

## Keywords:

Spinal tuberculosis  
Pott's disease  
Cage fixation  
Antituberculous drugs  
Anterior decompression

## ABSTRACT

**Introduction:** Spinal tuberculosis is a chronic destructive disease with long-term morbidity. Patients are usually young especially from a poor socioeconomic background. Destruction of the intervertebral disk space and the adjacent vertebral bodies is the characteristic lesion. The dorsal spine is the most affected region with multi-level noncontiguous involvement being detected more frequently. Patients usually present with chronic back pain associated with spinal tenderness, paraplegia, spinal deformities, as well as with constitutional symptoms. Magnetic resonance imaging has proved to be more sensitive and specific for its diagnosis, but availability and affordability of this investigation remain a problem in developing countries. Anti-tuberculous drug therapy has revolutionized the treatment of this debilitating disease. Surgery is still required in selected cases especially with evolving neurological deficit, progressive deformity, intractable pain and lack of response to drug therapy. With early diagnosis and effective treatment, prognosis is generally good.

**Materials/Methods:** After getting permission from the clinical governance department, We collected the retrospective data of 305 patients with diagnosed spinal tuberculosis, who underwent surgical intervention.

**Results:** There was no significant difference in incidence among males and females. Housewives were the most affected. Lower dorsal spinal was the commonest site involved but our study didn't confirm the incidence of multi-level disease process. Anterior decompression along with Cage fixation was most frequently performed procedure.

**Conclusion:** Despite the availability of highly effective antituberculous drugs, advanced surgical procedure, the spinal tuberculosis still maintains its demographic profile. There has been no change in characteristics of spinal presentation of this chronic debilitating disease. Patients continue to suffer the same way as they were suffering decades ago.

## 1. Introduction

Spinal involvement in tuberculosis is a frequently extrapulmonary manifestation of the disease. In developing nations, the incidence of spinal tuberculosis is high mainly because of poverty, unhygienic living conditions and poor access to good quality healthcare. Resurgence in all forms of tuberculosis, including spinal tuberculosis, has been observed because of the recent increase in acquired immunodeficiency caused by human immunodeficiency virus. (see Tables 1–5)

Spinal tuberculosis is chronic debilitating disease with long term

morbidity yet there are no straightforward guidelines for the diagnosis and treatment. Neurological compromise and spinal deformity (Fig. 1 & Fig. 2) are main complications of no treatment. To prevent the development of permanent neurological disability and to minimize the spinal deformity, early diagnosis and prompt treatment is necessary [1,2].

The development of multidrug resistance in Mycobacterium Tuberculosis, increased incidence of immunodeficient patients with tuberculosis, availability of advanced imaging modalities (Fig. 3, Fig. 4) and development of specialized spinal reconstructive techniques (Fig. 5) have all changed the management of this disease [3].

\* Corresponding author.

E-mail addresses: [noah\\_khan@hotmail.com](mailto:noah_khan@hotmail.com) (M.N. Hasan Khan), [dr.basit@live.com](mailto:dr.basit@live.com) (A.B. Jamal), [Auzair.hafeez964@gmail.com](mailto:Auzair.hafeez964@gmail.com) (A. Hafeez), [mariumsadiq1319@gmail.com](mailto:mariumsadiq1319@gmail.com) (M. Sadiq), [muhhammadumerrasool90@gmail.com](mailto:muhhammadumerrasool90@gmail.com) (M.U. Rasool).

<https://doi.org/10.1016/j.amsu.2021.102421>

Received 15 April 2021; Received in revised form 17 May 2021; Accepted 22 May 2021

Available online 28 May 2021

2049-0801/© 2021 The Author(s). Published by Elsevier Ltd on behalf of IJS Publishing Group Ltd. This is an open access article under the CC BY-NC-ND license

(<http://creativecommons.org/licenses/by-nc-nd/4.0/>).

**Table 1**  
Patients socio-demographic characteristics (N = 305).

Variable	Frequency (N)	Percent (%)
<b>Gender</b>		
Male	168	55.1
Female	137	44.9
<b>Age Group</b>		
<16	34	11.1
16–30	85	27.9
31–45	83	27.2
45–60	65	21.3
>60	38	12.5
<b>Job Type</b>		
Student	79	25.9
Housewife	97	31.8
Office Worker	10	3.3
Laborer	47	15.4
Shopkeeper	38	12.5
Retired	21	6.9
Teacher	13	4.3
<b>Residence</b>		
Urban	34	11.1
Rural	271	88.9
<b>Socioeconomic Class</b>		
Lower	244	80.0
Middle	61	20.0
High	0	0.0

**Table 2**  
Primary complains/symptoms of tuberculosis (N = 305).

Symptoms	Yes (%)	No (%)
Lower Back Pain	302 (99)	3 (1)
Weight Loss	295 (96.7)	10 (3.3)
Appetite Loss	289 (94.8)	16 (5.2)
Fever	176 (57.7)	129 (42.3)
Neck Pain	2 (0.7)	303 (99.3)
Lower Limb Weakness	2 (0.7)	303 (99.3)
Upper Limb Weakness	2 (0.7)	303 (99.3)
Deformity	3 (1)	302 (99)

**Table 3**  
Diagnosis and treatment for Skeletal Tuberculosis in Patients.

Variable	Frequency (N)	Percent (%)
<b>Duration of Symptoms</b>		
<6 months	70	23
6–12 months	231	75.7
>12 months	4	1.3
<b>Duration of Treatments</b>		
<3 months	1	0.3
3–6 months	3	1.0
6–12 months	300	98.4
>12 months	1	0.3
<b>How Diagnosis made</b>		
Radiographs	147	48.2
MRI	158	51.8
<b>Fixation Level</b>		
Cervical	13	4.3
Upper Dorsal	36	11.8
Lower Dorsal	128	42.0
Dorsolumbar Junction	29	9.5
Lumbar	93	30.5
Lumbosacral Junction	6	2.0
<b>Fused Segments</b>		
1 segment	264	86.6
2-3 segment	36	11.8
>3 segment	5	1.6
<b>Treatment</b>	<b>Yes (%)</b>	<b>No (%)</b>
Cage Fixation	280 (91.8)	25 (8.2)
Anterior Decompression	201 (65.9)	104 (34.1)
Pedicular Screw Fixation	22 (7.2)	283 (92.8)
Posterior Fusion	6 (2)	299 (98)

**Table 4**  
Bivariate analysis.

Job	Socioeconomic Class		P value
	Lower	Middle	
Student	58 (19)	21 (6.9)	0.00*
Housewife	85 (27.9)	12 (3.9)	
Office Worker	1 (0.3)	9 (3)	
Laborer	47 (15.4)	0 (0)	
Shopkeeper	33 (10.8)	5 (1.6)	
Retired	7 (2.3)	14 (4.6)	
Teacher	13 (4.3)	0 (0)	

In Pakistan, the incidence of immunodeficiency, especially in children, caused by human immunodeficiency virus is on the rise [4]. New multidrug resistant strains of mycobacterium have also been detected in our country [5]. Both factors have sparked a flurry of activity towards the prevention and treatment of this disease [6].

Methods of diagnosis and quality of treatment have shown great advances in recent years, but tuberculosis remains a global public health problem. According to World Health Organization, “the disease burden of tuberculosis is falling globally but not fast enough” and around 10 million people developed clinical symptomatic tuberculosis in 2017 [7].

Pakistan, being a developing country with slow economic growth programs for prevention and control of tuberculosis started late.

A lot of research publication [8,9], local as well as international, about tuberculosis are available but there are few studies with large number of patients suffering from spinal tuberculosis and its management. That’s why the level of spine affected by this disease and trend of surgical management are not clear.

The main purpose of our study is to give insight and literature to better provide antituberculosis therapy and further understand the epidemiological characteristics, diagnosis, and status of spinal level of disease and treatment of spinal tuberculosis in our region of world at this moment. Spinal tuberculosis has been reported in published literature to involve lower dorsal and upper lumbar regions than other portions of the spine [4]. The idea for the study came when surgeons and doctors at 1 spinal center observed that the case presentations and level of pathology was contradicting the research and literature given in most cases. This study intends to retrospectively analyse the clinical data of the patients with spinal tuberculosis in a tertiary care teaching hospital in Lahore, Pakistan.

## 2. Materials and methods

After noticing a change in current trend of the disease, we discussed the project with clinical governance in our hospital and registered it as a quality improvement project in the trust. After getting access to the data, We retrospectively reviewed patients, who were treated with surgery from January 2020 to June 2020 in a tertiary care teaching hospital in Pakistan, to see the exact level of pathology and compare it with given literature and figures to see if the disease is following trend or not. Variables kept for the study were age, gender, job, residence socioeconomic class, duration of symptoms, primary site, how diagnosis was made, medical therapy and definitive management. All patients, who were managed conservatively, were excluded. Patient notes and radiology were reviewed to calculate variables and patient sensitive data was omitted. All data was recorded in Microsoft excel sheets and analyzed via IBM SPSS® (v.25).

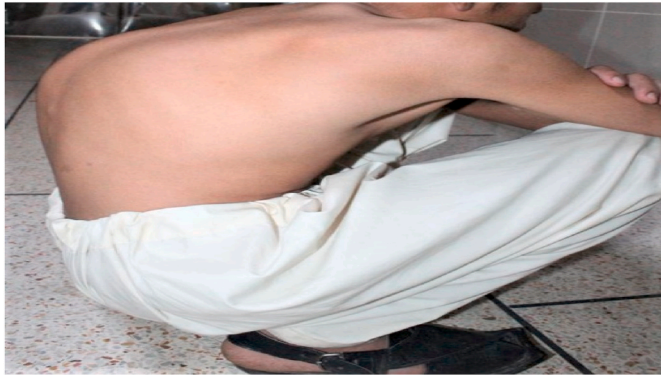## 3. Results

### 3.1. Demographic

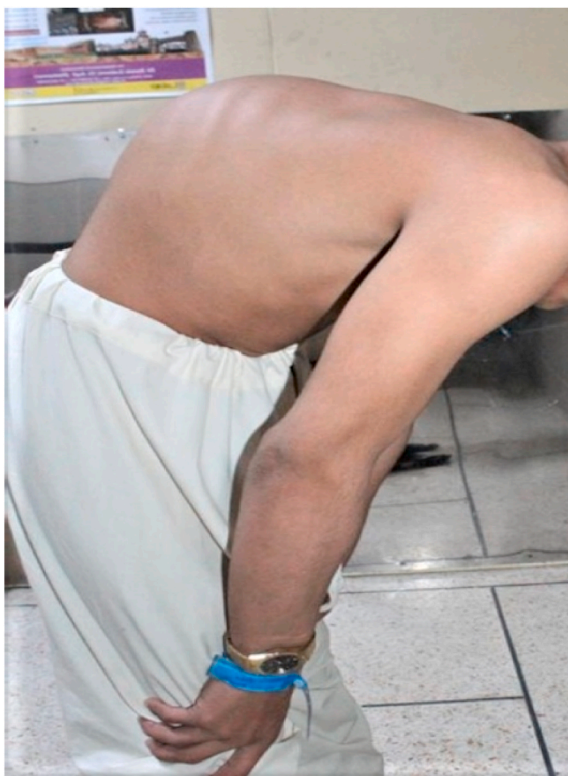In present study, 305 patients were evaluated and 302 were diagnosed with skeletal TB of which 168 (55.1%) are male and 137 (44.9%)

**Table 5**  
Level of disease.

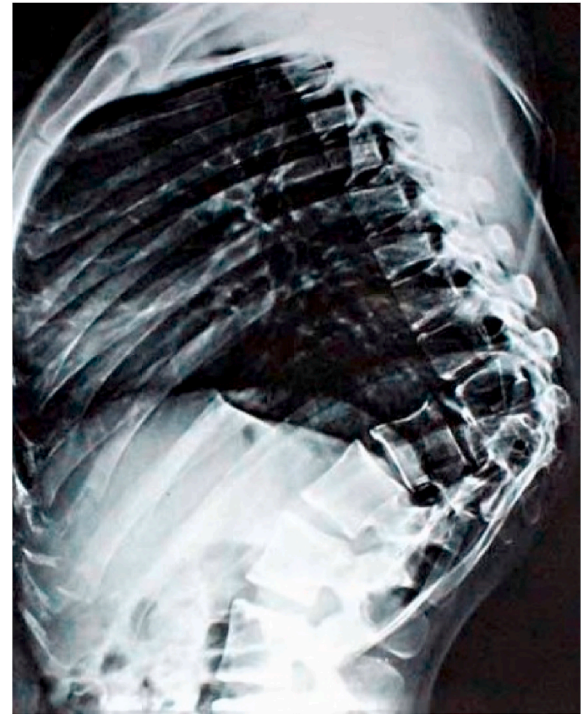
Age Groups	Fixation Level						P value
	Cervical	Upper Dorsal	Lower Dorsal	Dorsolumbar Junction	Lumbar	Lumbosacral Junction	
<16	2 (0.7)	8 (2.6)	12 (3.9)	2 (0.7)	10 (3.3)	0 (0)	0.373
16–30	4 (1.3)	7 (2.3)	37 (12.1)	8 (2.6)	28 (9.2)	1 (0.3)	
31–45	5 (1.6)	6 (2)	36 (11.8)	8 (2.6)	27 (8.9)	1 (0.3)	
45–60	0 (0)	9 (3)	31 (10.2)	4 (1.3)	18 (5.9)	3 (1)	
>60	2 (0.7)	6 (2)	12 (3.9)	7 (2.3)	10 (3.3)	1 (0.3)	



**Fig. 1.** Patient with tuberculosis of thoracic spine.



**Fig. 2.** Patient with deformity due to tuberculosis thoracic spine.



**Fig. 3.** X ray showing tuberculosis of thoracic spine.

female patients. Majority of the patients (27.9%) were 16–30 years old and (31.8%) are housewives. In addition, 89% patients suffering from skeletal TB were from rural area and (80%) of them belong to lower socioeconomic class.

**3.2. Presenting complaints**

Majority of patients (90%) had reported primary complains or symptoms of lower back pain, weight loss and appetite loss and (57.7%) had fever symptom and no significant number of patients had shown symptoms of neck pain, lower limb weakness, upper limb weakness and deformity.

**3.3. Diagnosis and treatment**

Maximum duration of illness or symptoms of TB in 231 (75%) patients lasts for 6–12 months and 300 (98%) patients had gone through 6–12 months of treatment. To determine the spread of the disease, diagnosis was performed by MRI of 158 patients and radiographs of 147 patients. Fixation was done on lower dorsal in 128 (42%) patients and on Lumbar in 93 (30%) patients. The development of skeletal TB was 264 (86.6%) for one fused segment. Most of the patients underwent cage fixation in 280 (91.8%) and anterior decompression in 201 (65.9%).

**3.4. Socioeconomic status**

In bivariate analysis, Job type and socioeconomic class are statistically significant at p value of 0.00 (<0.05). According to this study, highest number of skeletal TB cases 85 (27.9%) are in housewives and they belong to lower socioeconomic class. After housewives, prevalence



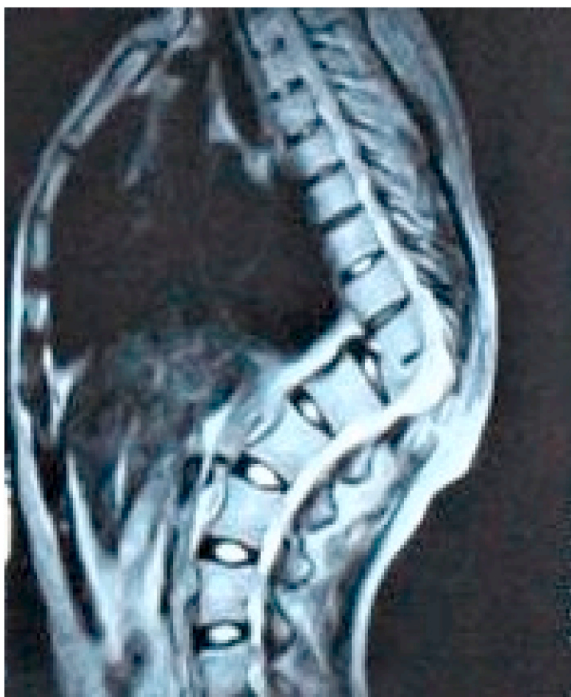

Fig. 4. X ray showing tuberculous of thoracic spine.

of skeletal tuberculosis cases is in students (58, 19%) and laborers (47, 15.4%)

### 3.5. Level of disease

Maximum Fixation done on lower Dorsal in 37 (12.1%) patients who were from age group of 16–30 years and 36 (11.8%) were from 31 to 45 years. Fixation on Lumbar in 28 (9.2%) patients were from 16 to 30 years of age group and 27 (8.9%) were from 31 to 45 years.

## 4. Discussion

Percival Pott described the spinal involvement in tuberculosis in 1782, and this presentation of the disease still holds his name [10]. It accounts for almost 50% of the cases of skeletal tuberculosis [11]. It

mostly involves dorsal and lumbar spine as a whole and is one of the leading causes of spinal deformity and paralysis [12].

Being the most common form of skeletal involvement, spinal tuberculosis follows the same increasing trend in incidence as is the tuberculosis trend overall [13].

In accordance with many studies [14], the largest number of patients in our study were the 16–30 years old (27.9%). At the time of diagnosis, 12.5% of our patients were older than 60 years.

Like pulmonary tuberculosis, spinal involvement is also chronic and slowly progressive disease. But unlike pulmonary tuberculosis, spinal disease has different symptoms profile. It is not usually accompanied by symptoms such as productive cough, fever, weight loss or night sweats. That's why it's very easy to be misdiagnosed as compared to its pulmonary counterpart.

Similar to other studies (3), back pain was the most common presenting symptom, followed by weight loss with limb weakness being the least common symptom.

Early diagnosis is of paramount importance for prevention of possible complications as it allows rapid therapeutic interventions. Disk space narrowing and vertebral body endplate destruction are the most common initial radiological findings, however these changes are hard to detect on plain radiographs especially in the earlier stages of disease. That formed the bases of MRI scans in 51.8% of our patients. Like other studies [9,15], the dorsal (58.1%) and lumbar spines (42%) were the spinal segments most affected.

The management of spinal tuberculosis consists of supportive care, drugs in the form of antituberculous chemotherapy, and surgical intervention. Antituberculous chemotherapy remains the mainstay of therapy throughout the treatment process of the disease for a duration of 6–9 months [16].

Compliance to therapy is a big problem because of long duration of therapy and serious adverse reaction to drugs. This has resulted in emergence of multi drug resistant strains [17]. Also, chemotherapy alone, can't correct the anatomical deformity caused by bony destruction. That's why, Surgical intervention still holds an important role in the management of spinal tuberculosis. At the same time, surgery cannot be assumed to work as sole treatment modality. Therefore, antituberculous chemotherapy and surgical intervention work symbiotically, as adequate antitubercular chemotherapy combined with surgical treatment is important to save the spinal cord function and avoid neurological dysfunction.

Surgical debridement provides local control of disease, decompresses

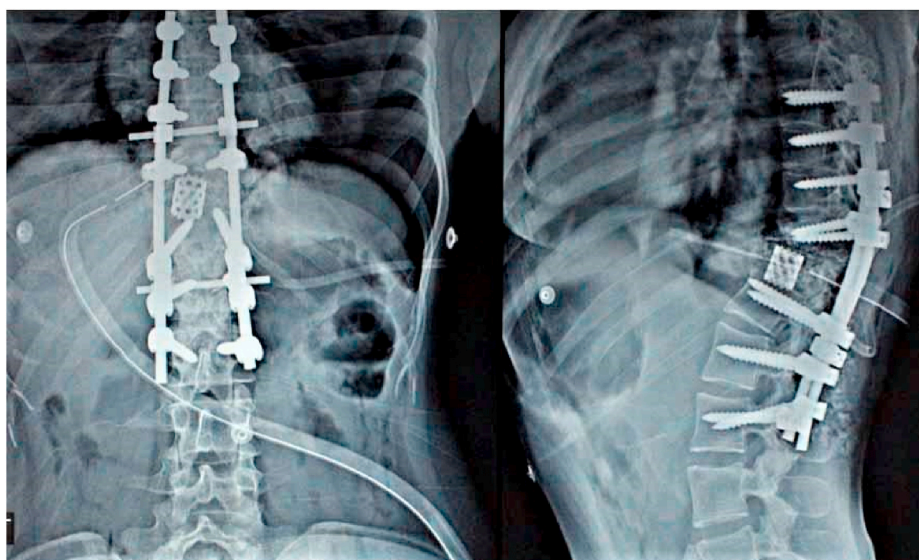


Fig. 5. Screw+ cage fixation thoracic spine+ lumbar spine post therapy.

the spinal cord and nerves, corrects deformity, and reshapes the stability of involved spinal segment [18].

Advanced surgical techniques including anterior, posterior, and combined approaches and fixation with cage or pedicular screws have revolutionized the surgical correction of spinal alignment and sagittal and coronal balance [19,20]. Surgery is most commonly performed for intractable pain, progressive neurological compromise and deformity, and ineffective antituberculous chemotherapy. Our patient population also underwent surgical intervention for these same indications.

## 5. Conclusion

Despite changing time and availability of highly effective antituberculous chemotherapy and advancement in surgical modalities, spinal tuberculosis still maintains its demographic profile in terms of population distribution as well as involvement of spinal segment level. Spine is still the most favorite site of skeletal manifestation of this centuries old debilitating disease. More research is needed to detect factors responsible for persistent prevalence of spinal tuberculosis to devise the strategic plan for reduction in incidence of this disease.

### Please state any conflicts of interest

Nil

### Please state any sources of funding for your research

Nil

### Conflict of interest

There are no conflict of interests for this study amongst authors or any organization.

### Ethical approval

Retrospective study looking at patient notes so no ethical approval needed.

### Sources of funding

Nil.

### Author statement

Mr Mohammad Noah H Khsn: lead author idea and write up.  
 Dr Abdul Basit Jamal: data analysis and collection.  
 Dr Auzair Hafeez: Data collection.  
 Marium Sadiq: data analysis.  
 Dr Umar Rasool: proof reading and corrections of statistics.

### Registration of research studies

Name of the registry:  
 Unique Identifying number or registration ID:  
 Hyperlink to your specific registration (must be publicly accessible and will be checked):

### Guarantor

Mohammad Noah H Khan corresponding author.

### Consent

All data anonymised.

### Declaration of competing interest

Nil.

### References

- [1] A.K. Jain, I.K. Dhammi, Tuberculosis of the spine: a review, *Clin. Orthop.* 460 (2007) 39–49. Jul.
- [2] A.K. Jain, Tuberculosis of the spine: a fresh look at an old disease, *J Bone Joint Surg Br* 92 (7) (2010) 905–913. Jul.
- [3] M. Turgut, Spinal tuberculosis (Pott's disease): its clinical presentation, surgical management, and outcome. A survey study on 694 patients, *Neurosurg. Rev.* 24 (1) (2001) 8–13. Mar.
- [4] WHO | HIV cases–Pakistan [internet]. WHO. World health organization; [cited 2021 Mar 30]. Available from: <http://www.who.int/csr/don/03-july-2019-hiv-cases-pakistan/en/>.
- [5] R. Hasan, K. Jabeen, A. Ali, Y. Rafiq, R. Laiq, B. Malik, et al., Extensively drug-resistant tuberculosis, Pakistan, *Emerg. Infect. Dis.* 16 (9) (2010) 1473–1475. Sep.
- [6] J. Huang, H. Zhang, K. Zeng, Q. Gao, The clinical outcomes of surgical treatment of noncontiguous spinal tuberculosis: a retrospective study in 23 cases, *PLoS One* 9 (4) (2014), e93648. Apr 3.
- [7] Organization WH. Global tuberculosis report 2018 [internet]. World health organization [cited 2021 Mar 30]. Available from: <https://apps.who.int/iris/handle/10665/274453>, 2018.
- [8] N. Schlesinger, A. Lardizabal, J. Rao, J. Rao, R. McDonald, Tuberculosis of the spine: experience in an inner city hospital, *JCR J Clin Rheumatol* 11 (1) (2005) 17–20. Feb.
- [9] H. Wang, C. Li, J. Wang, Z. Zhang, Y. Zhou, Characteristics of patients with spinal tuberculosis: seven-year experience of a teaching hospital in Southwest China, *Int. Orthop.* 36 (7) (2012) 1429–1434. Jul.
- [10] G.J. Gorse, M.J. Pais, J.A. Kusske, T.C. Cesario, Tuberculous spondylitis: a report of six cases and a review of the literature, *Medicine (Baltim.)* 62 (3) (1983) 178. May.
- [11] M.-S. Moon, S.-S. Kim, H.-L. Moon, D.-H. Kim, Mycobacterium tuberculosis in spinal tuberculosis, *Asian Spine J* 11 (1) (2017) 138–149. Feb 28.
- [12] W.Y. Cheung, K.D.K. Luk, Clinical and radiological outcomes after conservative treatment of TB spondylitis: is the 15 years' follow-up in the MRC study long enough? *Eur. Spine J.* 22 (4) (2013) 594–602. Jun 1.
- [13] E. Treccarichi, E. Meco, V. Mazzotta, M. Fantoni, Tuberculous spondylodiscitis: epidemiology, clinical features, treatment, and outcome, *Eur. Rev. Med. Pharmacol. Sci.* (16 Suppl 2) (2012) 58–72. Apr 1.
- [14] T. Shi, Z. Zhang, F. Dai, Q. Zhou, Q. He, F. Luo, et al., Retrospective study of 967 patients with spinal tuberculosis, *Orthopedics* 39 (5) (2016) e838–e843. Sep. 1.
- [15] N. Danchaiwittit, S. Temram, K. Thepmongkhon, P. Chiewvit, Diagnostic accuracy of MR imaging in tuberculous spondylitis, *J. Med. Assoc. Thai.* 90 (8) (2007) 1581. Aug 1.
- [16] T. Jiang, J. Zhao, M. He, K. Wang, M. Fowdur, Y. Wu, Outcomes and treatment of lumbosacral spinal tuberculosis: a retrospective study of 53 patients, in: P.-J. Cardona (Ed.), *PLoS One* 10 (6) (2015), e0130185. Jun 29.
- [17] A.K. Jain, K.R. Jaggi, H. Bhayana, R. Saha, Drug-resistant spinal tuberculosis, *Indian J. Orthop.* 52 (2) (2018) 100–107. Apr.
- [18] O. Karaeminogullari, U. Aydinli, R. Ozerdemoglu, C. Ozturk, Tuberculosis of the lumbar spine: outcomes after combined treatment of two-drug therapy and surgery, *Orthopedics* 30 (1) (2007) 55–59. Jan.
- [19] P.S. Issack, O. Boachie-Adjei, Surgical correction of kyphotic deformity in spinal tuberculosis, *Int. Orthop.* 36 (2) (2012) 353–357. Feb.
- [20] S. Kapoor, S. Kapoor, M. Agrawal, P. Aggarwal, B.K. Jain, Thoracoscopic decompression in Pott's spine and its long-term follow-up, *Int. Orthop.* 36 (2) (2012) 331–337. Feb.