

C A S E R E P O R T

Scapular reconstructions after resection for bone tumors: a single-institution experience and review of the literature

Alessio Biazzo¹, Massimiliano De Paolis², Davide Maria Donati²

¹Traumatologic Orthopaedic Center, Milano; ²Rizzoli Orthopaedic Institute, Bologna

Summary. Scapulectomy and limb-salvage surgery are indicated for low and high-grade tumors of the scapula and soft-tissue sarcomas that secondary invade the bone. After total or partial scapulectomy there are 3 options of reconstruction: humeral suspension (flail shoulder), total endoprosthesis and massive bone allograft. Nowadays prosthesis and allograft reconstructions are the most used and humeral suspension is reserved only as salvage technique when no other surgery is possible. Several studies reported dislocations and wound infections as the most frequent complications of scapular prosthesis, account for 10-20%. Recently, in the attempt to prevent these complications, some authors have used homologous allografts to replace shoulder girdle after scapulectomy for bone tumors, avoiding common complications of scapular prosthesis. Scapular reconstruction following tumor resection is a safe procedure and can be performed with good functional, oncological and cosmetic results but in reference centres and by skill surgeons. In this paper we present three cases of scapular reconstructions following resections for scapular tumors (chondrosarcoma in all cases) performed in our Institute and we analyse the different options of reconstruction described in the current literature. The final message is to send these rare tumors to reference centres where a multidisciplinary team is able to treat these rare entities and where a group of skill oncology surgeons are able to plan this complex surgery. (www.actabiomedica.it)

Key words: scapular reconstruction, allograft, scapular tumor, resection, scapular prosthesis

Case 1

We report the case of a 68-year-old woman with grade 1 chondrosarcoma of the right scapula, treated at our Institute with total scapulectomy and reconstruction with homologous massive allograft of scapula.

The patient was admitted at our Institute on April 2007 because of occasional discovery of an osteolysis of the scapula (Fig. 1).

During hospitalization she performed Magnetic Resonance Imaging (MRI) (Fig. 2) that showed the cartilaginous nature of the tumor and a computer tomography (CT)-guided biopsy: the diagnosis was grade 1 chondrosarcoma of bone. The tumor was located in S1-S2 region according the Enneking's classification (4).

On June 2007 an intra-articular total scapulectomy [type 3 according Malawer's classification (8)] and reconstruction with homologous massive bone allograft was performed. A posterior surgical approach was used with an anterior extension (deltopectoral approach), to obtain a good view of the neurovascular structures and the posterior muscles surrounding the scapula. The acromion-clavicular joint was fixed with a transarticular Kirschner wire; coracoclavicular fixation was obtained with an artificial ligament (LARS, Ligament Advanced Reinforcement System) passed beneath the base of the coracoid and superiorly through two holes in the clavicle.

The host coracoid process was fixed to the allograft bone with a screw (Fig. 3-a-b). The joint capsule, tendon and the periscapular muscles detached during the

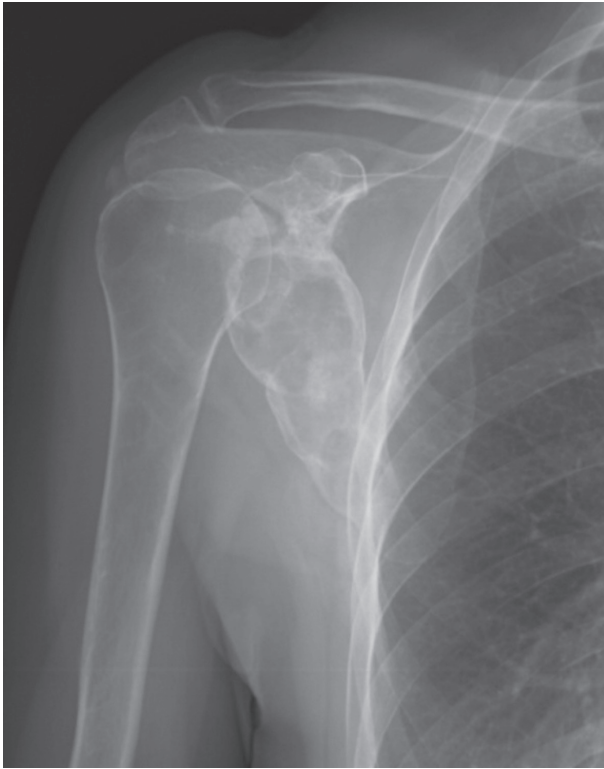

Figure 1. Radiograph shows an osteolytic lesion of the scapula with calcifications

resection procedure, were reattached to their origins or sutured to the corresponding stumps on the allograft.

The upper limb was immobilized with abduction brace for the first 4 weeks and then passive motion of the shoulder joint was allowed for 4 weeks. Active exercises and functional rehabilitation started at

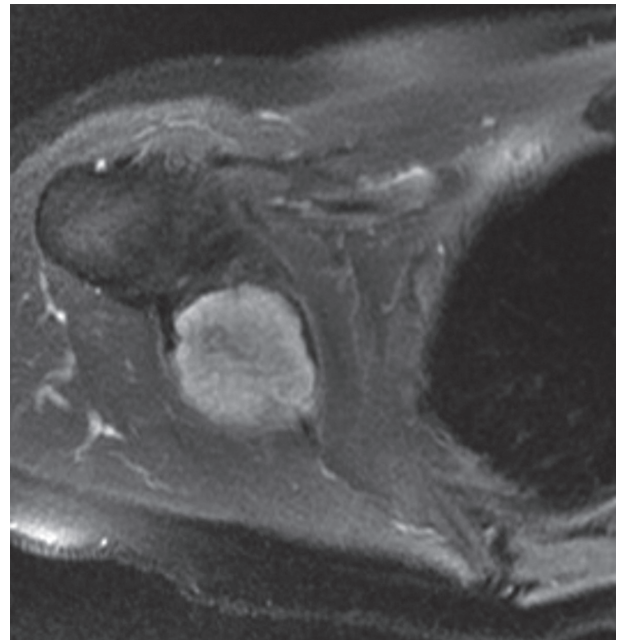


Figure 2. STIR sequences show a hyperintense lesion of scapula invading soft tissues

2 months postoperatively. Physiotherapy in water was preferred at the beginning to reduce stress and load to the shoulder joint.

From an oncological point of view, wide surgical margins were achieved.

During the follow-up the patient complained intolerance to fixation and underwent removal of Kirschner-wire and regularization of the graft.

On September 2009 she underwent wedge resec-

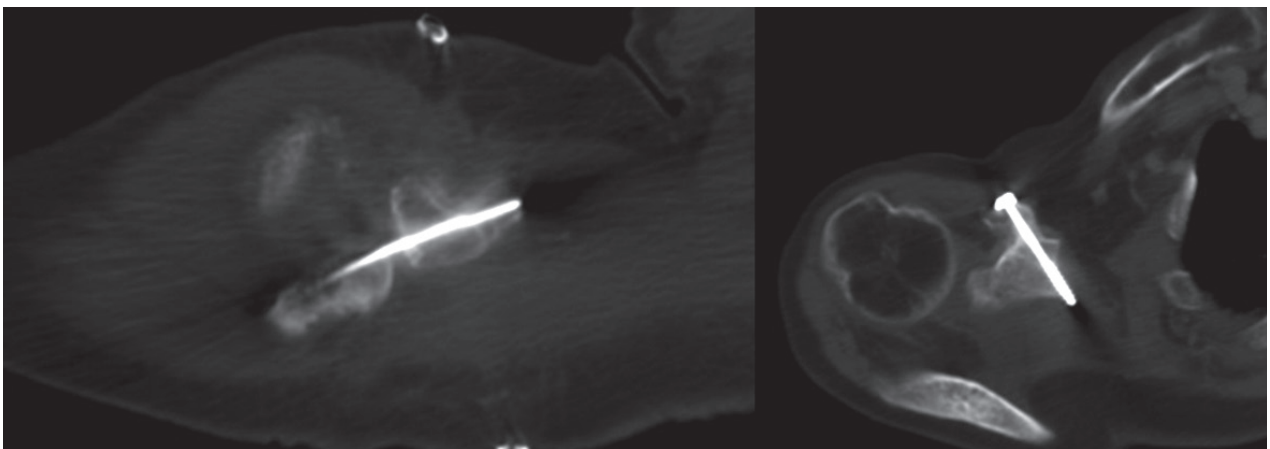


Figure 3 a-b. Postoperative CT-scan shows the internal fixation of the graft to the host bone

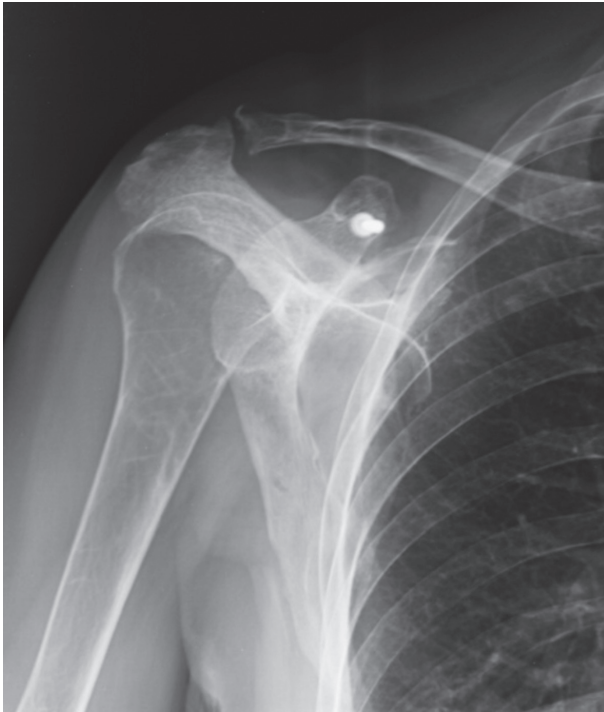

Figure 4. Follow-up at 7 years

tion of left lung because three nodules were found at CT-scan but histologically there was no evidence of disease.

At last follow-up of September 2014 the patient had no evidence of disease (Fig. 4).

The functional result was good with abduction for 45° and MSTTS score (5) of 82%.

Case 2

The second case is a 58 year-old woman with low-grade chondrosarcoma of the right coracoid process (Fig. 5).

The patient was admitted at our Institute on February 2010 because of pain and swelling of the anterior part of the shoulder.

In 1997, due to a shoulder trauma and subsequent radiography, a diagnosis of enchondroma of the coracoid process was made. So the patient began clinical and radiographic follow-up until 2009, when she complained pain and swelling in the right shoulder.

X-ray and TC showed an osteolysis of the coracoid process with central calcifications (Fig. 5).

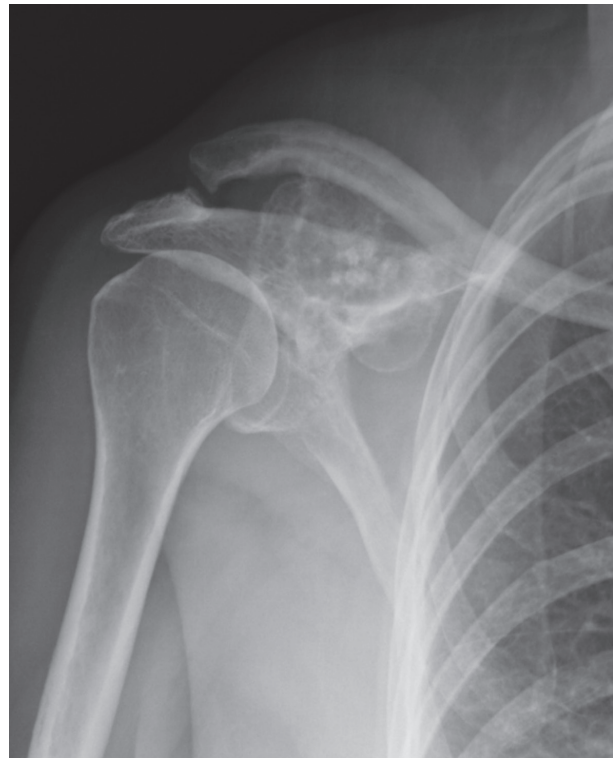

Figure 5. Osteolysis of the coracoid process with calcifications

CT-guided biopsy was performed and the diagnosis was low-grade central chondrosarcoma.

After staging disease, on February 2010 a resection of the coracoid process and reconstruction with homologous bone allograft was performed (Fig. 6).

A deltopectoral approach extended posteriorly was used to obtain a good view of the neurovascular structures and the posterior muscles surrounding the scapula. After resection of the tumour, the bone gap was reconstructed with an homologous bone graft from our bone tissue bank. The allograft was fixed with plate and screw to the host bone. The acromion-clavicular joint was fixed with a transarticular Kirschner wire; coracoclavicular fixation was obtained with an artificial ligament (LARS). The joint capsule, tendon and the periscapular muscles detached during the resection procedure, were reattached to their origins to the corresponding stumps on the allograft.

Wide margins were achieved.

During follow-up she complained intolerance to fixation and the K-wire was removed.

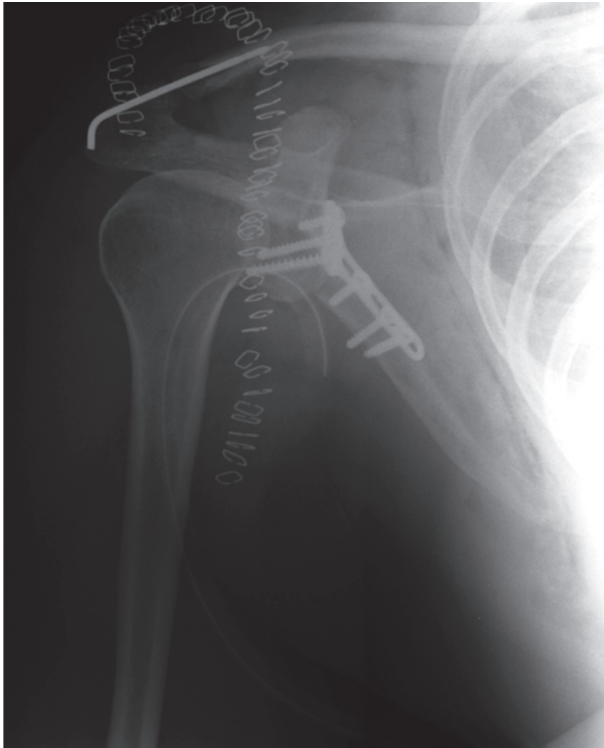

Figure 6. Postoperative radiography

At last follow-up on October 2014 there was no evidence of disease. She had good abduction and strength, without limitation in daily-life.

MSTS score was 77%.

Case 3

The last case is a 31 year-old woman with low-grade chondrosarcoma of the left scapula (Fig. 7).

The patient was hospitalized at our Institute on August 2009 for swelling and pain of the left shoulder since three months.

So she performed x-rays, CT and MRI that showed an osteolysis of the coracoid process with central calcifications.

CT-guided biopsy was performed: the diagnosis was low-grade central chondrosarcoma.

After staging the tumor, resection of the glenoid and reconstruction with custom-made prostheses was performed on December 2009. A deltopectoral approach extended posteriorly was used to perform the resection of the tumour. The specimen was then sent

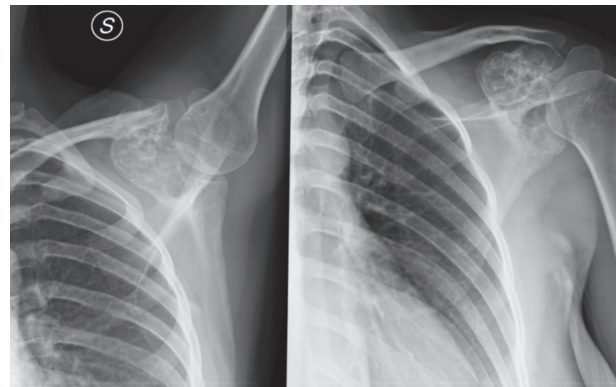


Figure 7. Preoperative radiography

to our pathologist for histological examination. The acromion-clavicular joint was fixed with a transarticular screw and K-wire (Fig. 3, 4). The custom-made prosthesis was fixed to the residual scapula with screws (Fig. 4). The joint capsule, tendon and the periscapular muscles detached during the resection procedure, were sutured to the corresponding stumps of the prosthesis.

During surgery, a fracture occurred accidentally into the body of the scapula, which was then stabilized with two opposing ribs of homologous bone and plates (Fig. 8). From an oncological point of view wide margins were achieved.

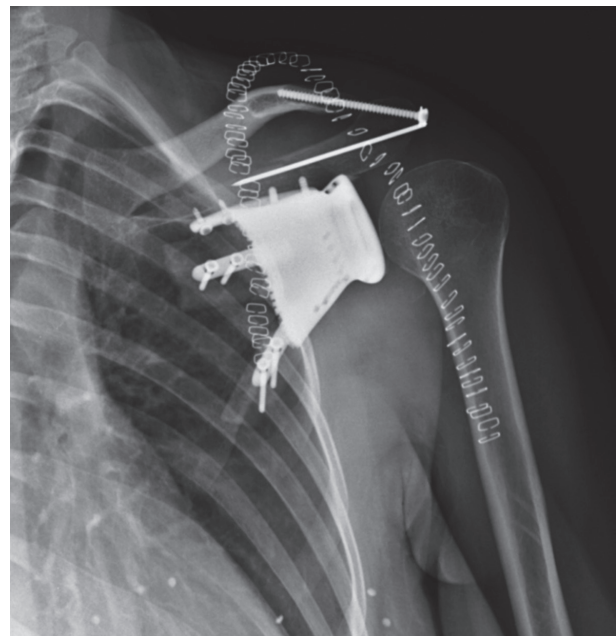

Figure 8. Postoperative radiography

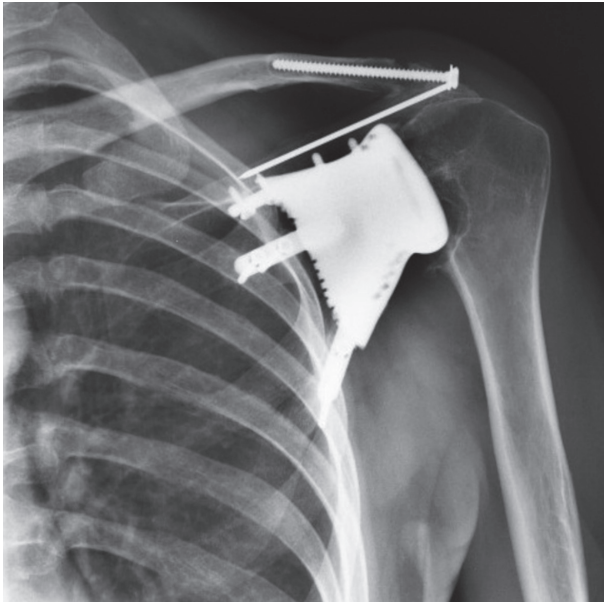


Figure 9. Five year follow-up x-ray

At last follow-up on June 2015 there was no evidence of disease; the prosthesis was stable but she complained occasional pain, she had limited extrarotation and abduction for 30°. X-ray showed osteolysis of the proximal humerus due to arthritis (Fig. 9). Despite occasional pain and discomfort, the patient refused revision surgery.

MSTS score was 62%.

Discussion

Bone tumors of the scapula are very rare. According to the Rizzoli Bone Tumor database, the most common lesion is chondrosarcoma (52.4%), followed by Ewing sarcoma (27.4%) and osteosarcoma (12.9%) (14).

The Enneking classification system for bone tumors of the scapula, approved by the Musculoskeletal Tumor Society (5), divides the scapula into 2 zones (Fig. 10). The surgical options depend on the location and size of the tumor. Usually, S1 tumors can be treated with partial scapulectomy without reconstruction; S2 tumors require glenoid reconstruction. Tumors affecting S1 and S2 region require total scapulectomy and represent a challenge for the orthopaedic surgeon,

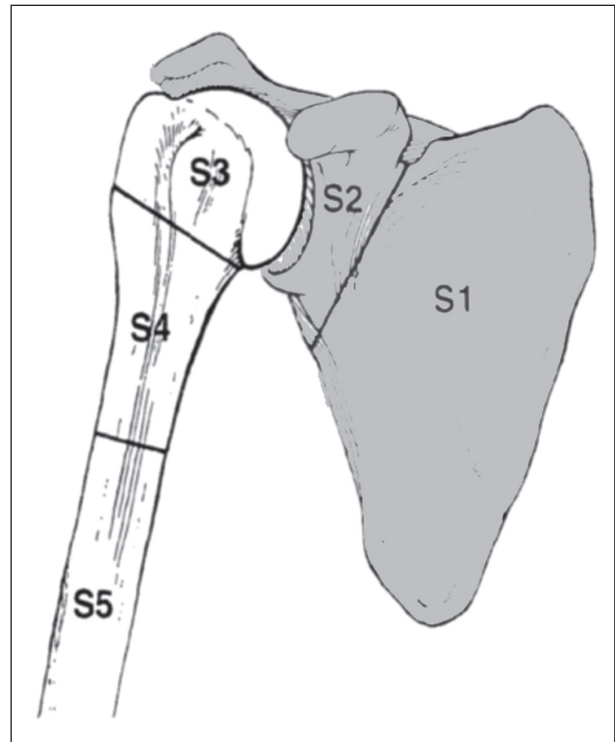


Figure 10. Segment 1 (S1): scapular blade and spine; segment 2 (S2): glenoid, coracoid process and acromion.

because of the complex anatomy of this region and the need to perform en-bloc resection with adequate margins preserving the neurovascular bundle and possibly rotator cuff and muscles of the shoulder girdle. Whenever the glenohumeral joint is preserved, good function of the arm can be expected.

Contraindications include tumour extension into the axilla with involvement of the neurovascular bundle and inability of the patient or unwillingness to tolerate limb-salvage surgery. Relative contraindications may include chest wall invasion, pathological fractures, previous infection, lymph node involvement and inappropriate placed biopsy with soft-tissue contamination (10).

The first scapulectomy was reported by Lister in 1819 (7), who described a case of an ossified aneurismal tumour. Since then, most shoulder girdle resections have been performed for low and high-grade sarcomas of the scapula and soft tissues.

Currently, the Malawer classification system (8) is the most used for shoulder girdle resections and is based on the concepts of surgical margins (intra-artic-

ular vs. extra-articular), the relationship of the tumor to anatomic compartments (intracompartmental vs. extracompartmental), the status of the gleno-humeral joint and the abductor mechanism.

After total or partial scapulectomy there are 3 options of reconstruction: humeral suspension (flail shoulder), total endoprosthesis (non-constrained or constrained) and bone allograft.

Humeral suspension was the most popular reconstructive procedure after total scapulectomy until the early 1990s. In humeral suspension the proximal humerus is simply stabilized with heavy nonabsorbable sutures or wires to the clavicle. Mayil Vahanan et al. (11) reported on the functional and oncological results of 23 patients who underwent scapulectomy for scapular tumors without reconstruction (flail shoulder). They described excellent/good results in 13 patients and fair/poor in 10 patients. Restriction of shoulder abduction was the major functional limitation, but they had normal hand and wrist functions.

Pritsch et al. (15) in 2006 performed a study with 2 groups of 16 patients each one, comparing the functional results of humeral suspension and scapular endoprosthetic reconstruction. They assessed that after total scapulectomy, scapular endoprosthetic reconstruction led to better functional and cosmetic results than humeral suspension and therefore they recommended performing this procedure whenever rhomboids, latissimus dorsi, deltoid and trapezius could be preserved. So, nowadays, humeral suspension represents a salvage technique when no further reconstruction is possible.

The aim of endoprosthetic scapular reconstruction is to form a connection between the arm and the chest wall, lateralizing the reconstructed shoulder and preserving its offset, preventing traction on the brachial plexus and filling the defect that remained after resection of the scapula (10).

Baran et al. (1) reported on the results of 7 patients who underwent partial or total scapulectomy followed by reconstruction with fibular autograft (1 case) and scapular prosthesis (6 cases) for bone or soft tissue scapular tumors. In this series there was no complication after surgery. MSTS score was 73,3%.

Tang et al. (17) described a study of 10 patients who underwent constrained prosthetic replacement after total scapulectomy for bone malignant tumor.

They reported 1 dislocation, treated with open reduction, and 1 superficial wound infection, treated with surgical debridement. MSTS score was 76,7%.

Masamed et al. (9) and Schwab et al. (16) presented the biggest groups of patients who underwent scapular prosthesis, reporting on the functional results and complications of 13 and 19 patients respectively. Both authors reported dislocations and wound infections as the most frequent complications, account for 10%-20%.

Recently, in the attempt to prevent the complications of scapular prosthesis, some authors have used homologous allografts to replace shoulder girdle after scapulectomy for bone tumours (2, 13, 19). Zhang et al. (19) described scapular allograft reconstructions of 7 patients who underwent partial or total scapulectomy. They concluded that the glenoid-saved reconstruction had better functional results than the glenoid-resected group. They had 1 deep infection that required surgical debridement and 1 case of shoulder pain throughout the follow-up period. MSTS score was 80%. More recently, Capanna et al. (2) presented the largest series of scapular allograft reconstructions after total scapulectomy: they performed 6 massive bone allografts, of which 1 was an irradiated autograft. They had 2 breakages of the osteosynthesis and 2 allograft fractures, with ISOLS score of 66.7%.

Our functional results are similar to other studies (Tab. 1), with average MSTS score of 73% (range 62%-82%) and a long follow-up (average 60 months). The main limit is the restricted number of patients, due to the rarity of scapular tumors and the selected surgical indications.

Conclusion

Limb salvage surgery of the scapula is a challenge for the orthopaedic surgeon, because of the complex anatomy of this region and the need to perform en-bloc resection with adequate margins preserving the neurovascular bundle and possibly rotator cuff and muscles of the shoulder girdle.

Scapular reconstruction following tumour resection can be performed with good functional, oncological and cosmetic results but in reference centres and

Table 1. Reported results of scapular reconstructions (prosthesis and allograft) in comparison to the current study

Author	Patients	Reconstruction	Follow-up	Complications	Functional score
Witting (18)	3	Constrained prosthesis	16 months	None	ISOLS 80%-90%
Schwab (16)	19	Constrained-nonconstrained prosthesis	18 months	2 infections 2 dislocations 2 wound necrosis	ISOLS 82%
Pritsch (15)	15	Constrained-nonconstrained prosthesis	90 months	2 wound dehiscences 1 dislocation	ISOLS 79%
Masamed (9)	13	Constrained prosthesis	Not available	3 dislocations 3 wound seromas	Not available
Baran (1)	7	1 Fibular autograft 6 Constrained-non constrained prosthesis	35 months	1 shoulder instability	MSTS 73.3%
Tang (17)	10	Constrained prosthesis	36 months	1 dislocation 1 wound infection	ISOLS 76.6%
Lee (6)	2	2 Glenoid allograft	33 months	None	ISOLS 90%
Mnaimneh (13)	6	5 Total scapula allograft 1 glenoid allograft	1 allograft fracture 44 months	ISOLS 82%	
Zhang (19)	3	3 glenoid allograft	26 months	1 chronic pain	ISOLS 79%
Chandrasekar (3)	2	2 irradiated scapula autograft	36 months	None	Not available
Merriman (12)	1	1 total scapula allograft	61 months	None	Not available
Capanna (2)	6	5 total scapula allograft 1 irradiated scapula autograft	66 months	2 osteosynthesis failures 1 allograft fracture	ISOLS 66.7%
Current study	3	1 total scapula allograft 1 glenoid prosthesis 1 coracoid allograft	60 months	1 intraoperative scapula fracture and proximal humerus arthritis	MSTS 73%

by skill surgeons. The goals of scapular reconstructions are to restore shoulder stability and good elbow, hand and wrist function, adequate suspension of the humerus and meticulous soft-tissue reconstruction, without compromising oncological results.

Preservation of rotator cuff and deltoid can warranty good flexion and abduction.

The main limit of these studies is the number of patients, due to the rarity of scapular tumors. Further studies, bigger group of patients and long-term follow-up are necessary to assess the functional results of scapular allografts and prosthesis reconstructions.

Finally, this paper does not aim to help the orthopaedic surgeon to perform a shoulder girdle resection.

The final message is to send these rare tumors to reference centres where a multidisciplinary team is able to treat these rare tumors and where a group of skill orthopaedic oncology surgeons are able to plan this complex surgery.

References

1. Baran O, Havitçioğlu H. Extremity saving surgery and reconstruction for tumors of the scapula. *Acta Orthop Traumatol Turc* 2007; 41(3): 195-201.
2. Capanna R, Totti F, Van der Geest IC, Müller DA. Scapular allograft reconstruction after total scapulectomy: surgical technique and functional results. *J Shoulder Elbow Surg* 2015 Apr 1. pii: S1058-2746(15)00079-8.

3. Chandrasekar CR, Mohammed R, Grimer RJ. Extracorporeally irradiated scapula as autograft in tumor surgery. *J Shoulder Elbow Surg* 2009 May-Jun; 18(3): e28-32.
4. Enneking W, Dunham W, Gebhardt M, Malawar M, Pritchard D. A system for the classification of skeletal resections. *Chir Organi Mov* 1990; 75: 217-40.
5. Enneking WF, Dunham W, Gebhardt MC, Malawar M, Pritchard DJ. A system for the functional evaluation of reconstructive procedures after surgical treatment of tumors of the musculoskeletal system. *Clin Orthop Relat Res* 1993 Jan; 286: 241-6.
6. Lee FY, Hornicek FJ, Hazan EJ, Kloen P, Wolfe MA, Mankin HJ. Reconstruction of the shoulder joint using an acetabular allograft. A report of two cases. *Clin Orthop Relat Res* 1998 Dec; 357: 116-21.
7. Lister R. Ossified aneurismal tumour of subscapular artery. *Edinb Med J* 1820; 16: 66-70.
8. Malawar MM. Tumors of the shoulder girdle. Technique of resection and description of a surgical classification. *Orthop Clin North Am* 1991 Jan; 22(1): 7-35.
9. Masamed R, Leach TJ, Menendez LR. En bloc shoulder resection with total shoulder prosthetic replacement: indications and imaging findings. *AJR Am J Roentgenol* 2008 Aug; 191(2): 482-9.
10. Mavrogenis AF, Mastorakos DP, Triantafyllopoulos G, Sakellariou VI, Galanis EC, Papagelopoulos PJ. Total scapulectomy and constrained reverse total shoulder reconstruction for a Ewing's sarcoma. *J Surg Oncol* 2009 Dec 1; 100(7): 611-5.
11. Mayil Vahanan N, Mohanlal P, Bose JC, Gangadharan R, Karthisundar V. The functional and oncological results after scapulectomy for scapular tumours: 2-16-year results. *Int Orthop* 2007 Dec; 31(6): 831-6.
12. Merriman DJ, Deavers MT, Czerniak BA, Lin PP. Massive desmoplastic fibroblastoma with scapular invasion. *Orthopedics* 2010 Aug 11; 33(8).
13. Mnaymneh WA, Temple HT, Malinin TI. Allograft reconstruction after resection of malignant tumors of the scapula. *Clin Orthop Relat Res* 2002 Dec; 405: 223-9.
14. Picci P. Epidemiology. In: Picci P, Manfrini M, Fabbr N, Gambarotti M, Vanel D, editors. *Atlas of musculoskeletal tumors and tumorlike lesions*. Cham: Springer; 2014: 3-8.
15. Pritsch T, Bickels J, Wu CC, Squires MH, Malawar MM. Is scapular endoprosthesis functionally superior to humeral suspension? *Clin Orthop Relat Res* 2007 Mar; 456: 188-95.
16. Schwab JH, Athanasian EA, Morris CD, Boland PJ, Healey JH. Function correlates with deltoid preservation in patients having scapular replacement. *Clin Orthop Relat Res* 2006 Nov; 452: 225-30.
17. Tang X, Guo W, Yang R, Ji T, Sun X. Reconstruction with constrained prosthesis after total scapulectomy. *J Shoulder Elbow Surg* 2011 Oct; 20(7): 1163-9.
18. Wittig JC, Bickels J, Wodajo F, Kellar-Graney KL, Malawar MM. Constrained total scapula reconstruction after resection of a high-grade sarcoma. *Clin Orthop Relat Res* 2002 Apr; 397: 143-55.
19. Zhang K, Duan H, Xiang Z, Tu C. Surgical technique and clinical results for scapular allograft reconstruction following resection of scapular tumors. *J Exp Clin Cancer Res* 2009 Apr 1; 28: 45.

Received: 26 July 2016

Accepted: 21 October 2016

Correspondence:

Alessio Biazzo

Traumatologic Orthopaedic Center

via Bignami 1, Milano

E-mail: ale.biazzo@yahoo.it