

Contents lists available at [ScienceDirect](https://www.sciencedirect.com)

International Journal of Surgery Case Reports

journal homepage: www.casereports.com

Spontaneous partial uterine laceration in primigravida at 16 weeks of gestation: A case report

Kaori Iino^{a,b,*}, Kanji Tanaka^a, Anna Takabayashi^a, Asami Akaishi^a, Kana Ishihara^a, Yoshihito Yokoyama^a^a Department of Obstetrics and Gynecology, Hirosaki University Graduate School of Medicine, Hirosaki, 5 Zaifu Hirosaki, Aomori, 036-8562, Japan^b National Hospital Organization Hirosaki National Hospital, Japan

ARTICLE INFO

Article history:

Received 9 June 2020

Received in revised form 1 July 2020

Accepted 2 July 2020

Available online 15 July 2020

Keywords:

Uterine laceration

Uterine rupture

Spontaneous hemoperitoneum in pregnancy

Fetal death

Case report

ABSTRACT

INTRODUCTION: Although uterine rupture is well discussed, uterine laceration and partial myometrial laceration are little known. A previous report hypothesized that the stress of labor was associated with uterine laceration.

PRESENTATION OF CASE: We present a rare case of uterine laceration in a patient in the second trimester. A 34-year-old primigravida woman at 16 weeks' gestation without a history of uterine surgery complained of sudden low abdominal pain. Ultrasonography showed fetal death and intraperitoneal free fluid. A laparotomy was performed, and partial uterine laceration in the posterior wall along with active bleeding was confirmed.

DISCUSSION: The etiology of uterine laceration in early pregnancy might be different from both classical uterine rupture and previously published uterine laceration. We hypothesized that tissue inadaptability for uterine enlargement, such as that owing to endometriosis and subtle injury by surgical approach, may be associated with the onset mechanism.

CONCLUSION: The diagnosis of uterine laceration in early pregnancy is quite difficult because of the absence of specific clinical findings. However, it sometimes causes massive intraperitoneal bleeding and has poor prognosis. Therefore, when uterine laceration is suspected as a cause of hemoperitoneum in a pregnant woman, clinicians should perform exploratory laparotomy appropriately.

© 2020 Published by Elsevier Ltd on behalf of IJS Publishing Group Ltd. This is an open access article under the CC BY-NC-ND license (<http://creativecommons.org/licenses/by-nc-nd/4.0/>).

1. Introduction

Uterine rupture, which is defined as complete myometrial disruption, can result in high maternal and fetal morbidity and mortality. The estimated incidence of uterine rupture is 5.3–5.9 per 10,000 pregnancies [1–3]. The major risk factor for uterine rupture is prior uterine surgery, such as cesarean section and myomectomy [1–3].

While there are many reports and data about uterine rupture, uterine laceration, in which a part of the myometrium is torn, is not well discussed. Uterine laceration is rare and almost unknown; however, it sometimes causes massive intraperitoneal bleeding and has poor prognosis [4–7].

Hayashi reported an inner myometrial laceration and hypothesized that intrapartum physical stress was the main etiological factor [4]. Here, we experienced a case of spontaneous uterine injury that caused massive intraperitoneal bleeding and intrauterine fetal death at 16 weeks' gestation in a primigravida woman with unscarred uterus. The etiology of uterine injury in relatively earlier gestational age and without uterine surgery may differ from that in classical uterine rupture and inner myometrial laceration in labor.

The aim of this study was to present the clinical course and management of the patient who was diagnosed as uterine laceration in second trimester, and to discuss the etiology of uterine injury in early pregnancy. This work has been reported in accordance to the Surgical Case REport (SCARE) guidelines [8].

The aim of this study was to present the clinical course and management of the patient who was diagnosed as uterine laceration in second trimester, and to discuss the etiology of uterine injury in early pregnancy. This work has been reported in accordance to the Surgical Case REport (SCARE) guidelines [8].

2. Presentation of case

A 34-year-old Asian primigravida woman at 16 weeks' gestation came to the previous hospital and presented with sudden and continuous lower abdominal pain. Her past medical history included cystectomy of the para-salpinx by laparotomy. There was no history of previous uterine surgery, such as cesarean section or myomectomy. She had never experienced dilation and curettage before the pregnancy. Prior to the development of abdominal pain, the course of the pregnancy was uneventful. Serum laboratory and ultrasound examination did not reveal any abnormal findings; hence, the patient was observed in the hospital with pain medication.

* Corresponding author at: Department of Obstetrics and Gynecology, Hirosaki University Graduate School of Medicine, 5 Zaifu, Hirosaki, Aomori, 036-8562, Japan.
E-mail address: iino-ka@hirosaki-u.ac.jp (K. Iino).

However, after 24 h from the admission her lower abdominal pain worsened, and transabdominal ultrasound scan showed intrauterine fetal death. The patient was taken to our hospital immediately. On arrival at our hospital the patient complained strong and continuous lower abdominal pain. She did not experienced vaginal bleeding. The uterine was not contractions. Then, we found some intraperitoneal free fluid by transabdominal ultrasound scan. The placenta was located on the right side, posterior to the uterine wall. On physical examination, the blood pressure was 80/40 mmHg, pulse was 120 beats per minute, temperature was 37.5 °C, and the respiratory rate was normal. She appeared pale and conscious. Her abdomen was soft, and she had severe pain involving the entire uterus. Serum laboratory examination showed leukocytosis ($28.6 \times 10^3/\mu\text{L}$), normal platelet count, normal coagulation markers, and a hemoglobin level of 8.1 g/dL. Although contrast-enhanced computed tomography (CT) showed intraperitoneal free fluid with partially high signal, other abnormal findings were not detected (Fig. 1(a)). The results of the laboratory and radiographic examinations suggested the possibility of hemoperitoneum. However, we could not definitively diagnose hemoperitoneum because the patient had no risk factors for uterine rupture or hemoperitoneum. While the patient was closely monitored in the intensive care unit (ICU), her hemoglobin level gradually decreased to 6.6 g/dL and ultrasound examination showed a slight increase in intraperitoneal fluid. At this time, we diagnosed the patient with hemoperitoneum, and exploratory laparotomy was performed. A large hematoma was removed from the abdominal cavity (Fig. 1(b)). There was a tear (approximately 2 cm) in the myometrium on the lower uterine posterior wall (Fig. 1(c)). We measured the depth of the laceration from the surface of serosa, and found that the tear reached uterus cavity. Surrounding the uterine tear, no apparent cause of uterine laceration could be observed macroscopically. Apart from hematoma there were no abnormal findings in the abdominal cavity, like endometriosis and adhesion. In addition, the position of the placenta was distant from the uterine tear, and there was no sign of placental detachment. We obtained a small tissue sample from near the tear for pathological examination; however, the evaluation did not identify the cause of the rupture. The bilateral tubes and ovaries were normal. Dilatation of the cervical canal and curettage were performed, and the laceration was sutured. The estimated blood loss was 2520 mL. In total, 12 units of red blood cells, 1680 mL of fresh frozen plasma, and 8 units of cryoprecipitate were transfused. The patient's anemia gradually improved, and she was discharged 7 days later.

3. Discussion

There are various degrees of uterine injuries occurring during pregnancy. Uterine rupture, which is a full thickness tear of the uterine wall, is rare but carries a high risk of maternal and fetal morbidity and mortality [1–3]. The major risk factor of uterine rupture is prior uterine surgery, such as cesarean section or myomectomy, other risk factors are placenta previa, obesity, induction of labor (oxytocin or prostaglandin), high parity, multiple birth, and malformation of the uterus [1–3].

In contrast with uterine rupture, the partial disruption of the uterine wall, which some reports described as inner myometrial laceration, has not well discussed [4–7]. This type of uterine injury sometimes occurs in women without a history of uterine surgery [4,7]. Hence, some reports suggest that the etiology of inner myometrial laceration might be different from that of classical uterine rupture [4,7]. Hayashi investigated 37 cases of inner myometrial laceration and hypothesized that severe stress on the uterine cervix was caused by an abnormal rise in intrauterine pressure during labor resulting in uterine laceration [4]. In fact, the inner myome-

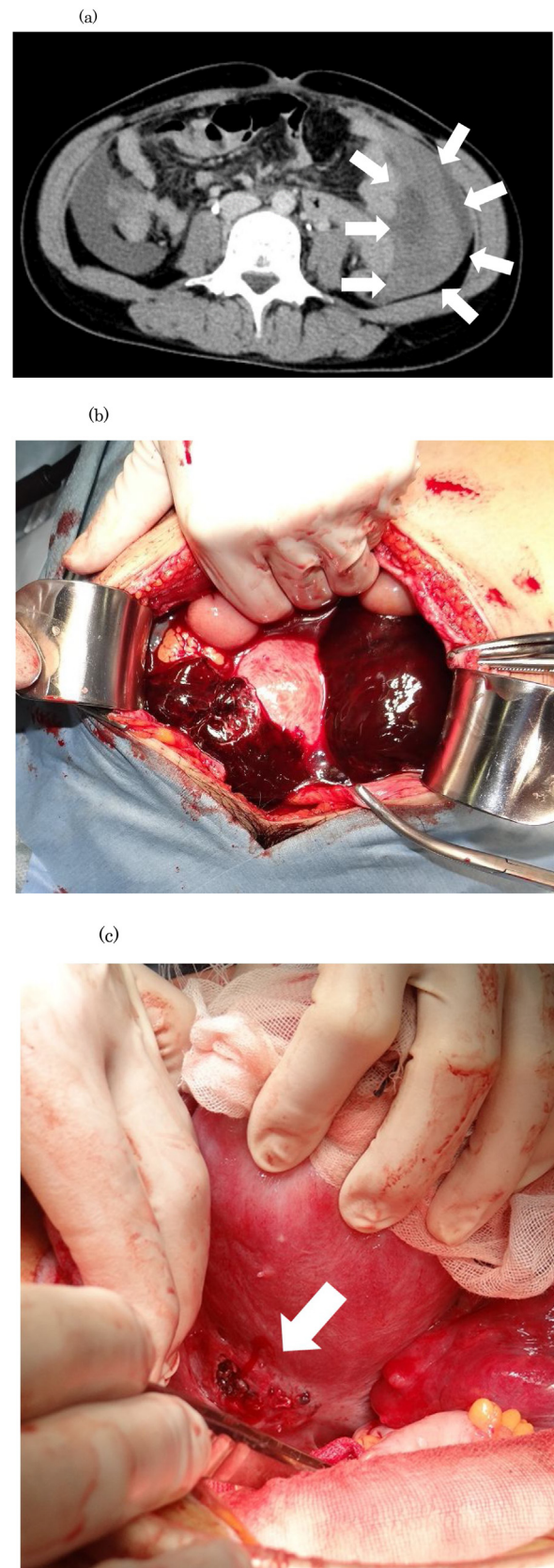


Fig. 1. (a) Computed tomography showing intraperitoneal free fluid with partially high signal. (b) Massive hematoma in the abdominal cavity. (c) The lower uterine posterior wall was ruptured.

trial laceration in all reported cases occurred during labor [4–7]. However, we experienced partial uterine myometrial laceration in 16 weeks of gestation and was not associated with labor. In addition, our patient showed no risk factors for uterine rupture. This suggested that the etiology of the present case would differ from that of both classical uterine rupture and inner myometrial laceration. Although we were unable to find a similar case, uterine rupture in early pregnancy was reported in three patients who had no risk of uterine rupture in the second trimester [9–11]. These three reports pointed out the potential of the unrecognized perforation in the previous curettage. Considering these reports and our presented case, uterine myometrial tear in early pregnancy might be induced by obstruction of increasing uterine volume, such as partial stiffness of tissue owing to previous unrecognized uterine injury or endometriosis. In the present case, previous cystectomy of the para-salpinx by laparotomy might cause subtle injury on the surface of uterus resulting in a partial myometrial laceration in subsequent pregnancy.

Spontaneous hemoperitoneum in pregnancy (SHiP) in association with endometriosis has several features comparable with those in our patient, such as acute abdominal pain, massive intraperitoneal bleeding, and necessity of surgical approach [11]. In addition, among 59 cases of SHiP summarized by Marit C.I. Lier, many patients were in a relatively early gestational age, similar to that in our case [12]. Thus, our presented case and some cases of SHiP might have similar backgrounds.

4. Conclusion

The etiology of uterine laceration in relatively early pregnancy is unclear; however, tissue inadaptability for uterine enlargement, such as that owing to endometriosis and subtle injury by surgical approach, may be associated with the onset mechanism. This type of uterine laceration is rare and difficult to diagnose; however, because of the poor prognosis prompt medical intervention must be initiated as early as possible. Therefore, more information and discussion about uterine laceration in early pregnancy is needed.

Declaration of Competing Interest

The authors declare that they have no conflict of interest regarding the publication of this case report.

Sources of funding

No funding from an external source supported the publication of this case report.

Ethical approval

Case reports exempt from ethical approval from institution.

Consent

Written informed consent was obtained from the patient for publication of this case report and accompanying images. A copy of the written consent is available for review by the Editor-in-Chief of this journal on request.

Author contribution

Kaori Iino, study concept or design, data collection, writing the paper.

Kanji Tanaka, study concept or design, data collection, reviewing the paper.

Yoshihiko Yokoyama, study concept or design, data collection, reviewing the paper.

Anna Takabayashi, data collection, reviewing the paper.

Asami Akaishi, data collection, reviewing the paper.

Kana Ishihara, data collection, reviewing the paper.

Registration of research studies

Our study does not require registration.

Guarantor

Kaori Iino.

Provenance and peer review

Not commissioned, externally peer-reviewed.

References

- [1] G.J. Hofmeyr, L. Say, A.M. Gulmezoglu, WHO systematic review of maternal mortality and morbidity: the prevalence of uterine rupture, *BJOG* 112 (2005) 1221–1228.
- [2] J.J. Zwart, J.M. Richters, F. Ory, et al., Uterine rupture in the Netherlands: a nationwide population-based cohort study, *BJOG* 116 (2009) 1069–1078, discussion 78–80.
- [3] K.E. Fitzpatrick, J.J. Kurinczuk, Z. Alfirevic, et al., Uterine rupture by intended mode of delivery in the UK: a national case-control study, *PLoS Med.* 9 (2012), e1001184.
- [4] M. Hayashi, Y. Mori, K. Nogami, et al., A hypothesis to explain the occurrence of inner myometrial laceration causing massive postpartum hemorrhage, *Acta Obstet. Gynecol. Scand.* 79 (2000) 99–106.
- [5] G.H. Page, A.S. Page, Management of persistent postpartum hemorrhage caused by inner myometrial lacerations, *Obstet. Gynecol.* 126 (2015) 1307.
- [6] M. Kaplanoglu, D. Kaplanoglu, M. Bulbul, B. Dilbaz, Inner myometrial laceration – an unusual presentation of antepartum and postpartum hemorrhage: case reports and review of the literature, *J. Matern. Fetal. Neonatal. Med.* 29 (2016) 2621–2624.
- [7] K. Hishikawa, R. Watanabe, K. Onuma, et al., Spontaneous uterine laceration in labor: a type of intrapartum uterine injury different from the classical uterine rupture, *J. Matern. Fetal. Neonatal. Med.* 31 (2018) 401–403.
- [8] R.A. Agha, M.R. Borrelli, R. Farwana, K. Koshy, A. Fowler, D.P. Orgill, For the SCARE Group, The SCARE 2018 statement: updating consensus Surgical Case Report (SCARE) guidelines, *Int. J. Surg.* 60 (2018) 132–136.
- [9] K.I. Dibbs, R.H. Ball, P.C. Huettner, Spontaneous uterine rupture and hemoperitoneum in the first trimester, *Am. J. Perinatol.* 12 (1995) 439–441.
- [10] N. Abdalla, M. Reinholz-Jaskolska, M. Bachanek, et al., Hemoperitoneum in a patient with spontaneous rupture of the posterior wall of an unscarred uterus in the second trimester of pregnancy, *BMC Res. Notes* 8 (2015) 603.
- [11] L. Mannini, F. Sorbi, V. Ghizzoni, et al., Spontaneous unscarred uterine rupture at 15 weeks of pregnancy: a case report, *Ochsner J.* 16 (2016) 545–547.
- [12] M.C.I. Lier, R.F. Malik, J.C.F. Ket, et al., Spontaneous hemoperitoneum in pregnancy (SHiP) and endometriosis – a systematic review of the recent literature, *Eur. J. Obstet. Gynecol. Reprod. Biol.* 219 (2017) 57–65.

Open Access

This article is published Open Access at [sciencedirect.com](https://www.sciencedirect.com). It is distributed under the [IJSCR Supplemental terms and conditions](#), which permits unrestricted non commercial use, distribution, and reproduction in any medium, provided the original authors and source are credited.