

## Abdominal cavity myolipoma presenting as an enlarging incisional hernia

Mark O Moore, Michael L Richardson, Brian P Rubin, Geoffrey S Baird

We present a case of an abdominal cavity myolipoma which herniated through a low transverse abdominal (Pfannenstiel) incision, and presented as an enlarging abdominal wall mass. Magnetic resonance imaging (MRI) prior to surgery demonstrated an encapsulated solid tumor mass demonstrating fat signal and increased T2-weighted signal. Postsurgical histological tissue diagnosis was myolipoma. Recognition of the intra- and extraperitoneal location of this abdominal tumor was essential for accurate surgical planning.

### Introduction

Myolipoma is a benign soft tissue neoplasm composed of a mixture of smooth muscle and mature adipose tissue (1, 2). It is a rare lesion that can occur at many anatomical locations, including the spinal cord (3), retroperitoneum (4-6), abdominal cavity (6), uterus and adnexae (7-11), eyelid (12), pericardium (13), and breast (14). To our knowledge, a case of myolipoma within an incisional hernia has not previously been described in the literature. We report such a case, and review the computed tomography, magnetic resonance imaging and histological findings of myolipoma.

### Case Report

A 55-year old woman presented to our institution with a 6-month history of progressively enlarging abdominal mass with concomitant right lower quadrant discomfort and right leg pain.

One year prior to this admission, a 6 cm right adnexal mass had been noted on pelvic exam as part of a preoperative workup for symptomatic cholelithiasis at another institution. Computed tomography (CT) exam at that time demonstrated a fibrotic-appearing 7 cm mass around a 2 cm ovary. This mass extended anteriorly to the posterior margin of the right abdominal musculature (Figure 1).

She underwent an uncomplicated laparoscopic cholecystectomy, with concomitant excisional biopsy of the right

---

**Citation:** Moore MO, Michael L Richardson, Brian P Rubin, Geoffrey S Baird. Abdominal cavity myolipoma presenting as an enlarging incisional hernia: a case report. *Radiology Case Reports*. [Online] 2006;1:5.

**Copyright:** © Michael L. Richardson. This is an open-access article distributed under the terms of the Creative Commons Attribution-NonCommercial-NoDerivs 2.5 License, which permits reproduction and distribution, provided the original work is properly cited. Commercial use and derivative works are not permitted.

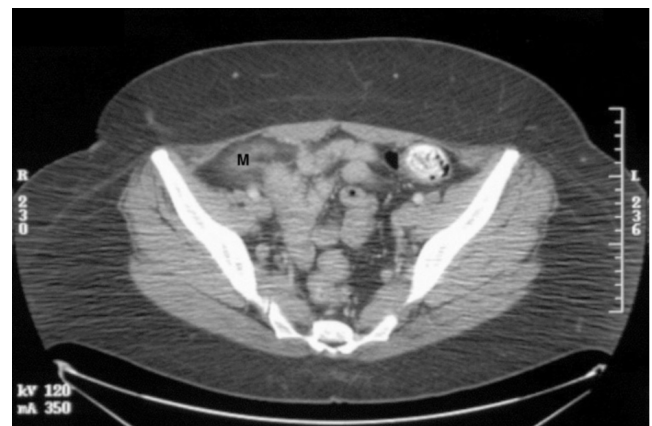Abbreviations: CT, computed tomography, MRI, magnetic resonance imaging, 3D, three dimensional, MB, megabyte, STIR, short tau inversion recovery

Mark O. Moore is in the School of Medicine, University of Washington School of Medicine, Seattle, Washington, United States of America.

Michael L. Richardson is in the Department of Radiology, University of Washington School of Medicine, Seattle, Washington, United States of America. E-mail: [mrich@u.washington.edu](mailto:mrich@u.washington.edu)

Brian P. Rubin and Geoffrey S. Baird are in the Department of Anatomic Pathology, University of Washington School of Medicine, Seattle, Washington, United States of America.

DOI: 10.2484/rcr.v1i1.5

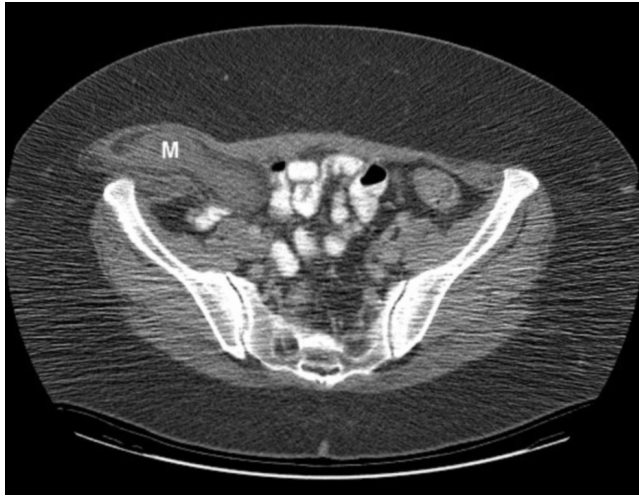


**Figure 1.** Initial CT examination, demonstrating a mass (M) posterior to the right abdominal wall.

## Abdominal Cavity Myolipoma Presenting as an Enlarging Incisional Hernia

adnexal mass and right ovary through a preexisting Pfannenstiel incision. Initial pathology was consistent with benign scar tissue and inflammatory adhesions.

The next few months were marked by worsening right leg pain, which had been present prior to initial removal of the mass. She characterized this pain as a deep nagging pain, starting in her right buttock and radiating down to her right groin and the lateral side of her right thigh. In addition to this pain, she reported worsening gastrointesti-



**Figure 2.** Repeat CT scan, showing a dumbbell-shaped right lower quadrant mass (M) in contact with the psoas muscle, extending through the abdominal wall into the overlying subcutaneous tissue.

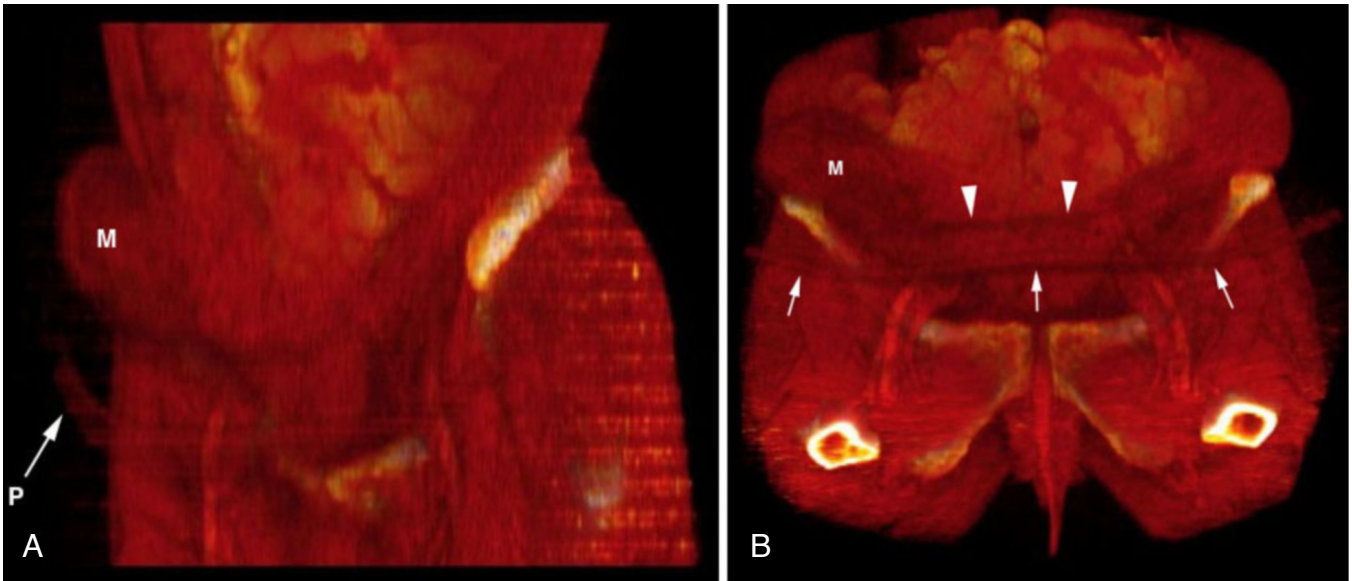
nal symptoms over the same time period, including nausea, constipation, and a sensation of postprandial fullness that required her to stand in order to finish eating a meal. She also noted that she could feel the mass again, and felt that it had begun to enlarge. On physical examination, a large firm mass was palpated in the right lower abdominal wall in the region underlying the Pfannenstiel incision. Laboratory studies were within normal limits.

Repeat CT scan of the pelvis (Figures 2 and 3) now demonstrated a 9.4 x 2.3 cm dumbbell-shaped right lower quadrant mass in contact with the psoas muscle, and extending through the abdominal wall into the overlying subcutaneous tissue. It was shown to abut the right iliac wing, external iliac vessels, and urinary bladder. No calcifications were noted within the mass.

Magnetic resonance imaging (MRI) of the pelvis (Figure 4) demonstrated a large extraperitoneal mass occupying the right hemipelvis, extending through the abdominal wall musculature at the lateral aspect of the prior Pfannenstiel incision.

The small bowel and cecum were compressed by the mass, and the urinary bladder was displaced medially. A thin well-demarcated capsule surrounding the lesion demonstrated increased signal intensity on short-tau inversion recovery (STIR) and decreased signal intensity on T1-weighted MRI (Figure 5).

The interior of the lesion revealed a mixture of fat signal and increased T2-weighted signal. Also noted was an additional tissue component that was of increased signal intensity on STIR-weighted imaging and heterogeneous on T1-weighted imaging, either hypodense to muscle or isodense

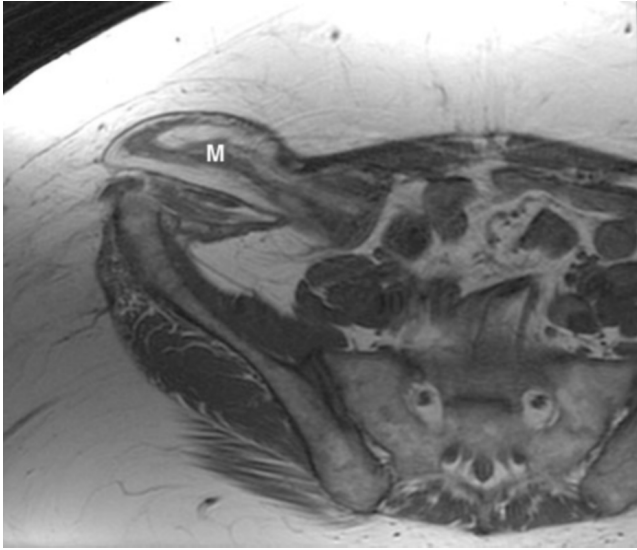


**Figure 3.** Three-dimensional (3D) reconstruction of lower abdomen from repeat CT scan data, showing mass (M) protruding through abdominal wall.

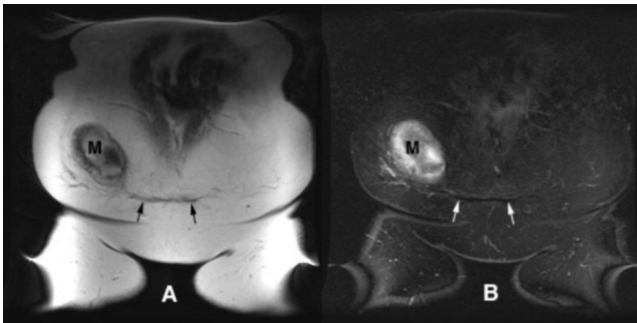
A. Left anterior oblique view from a [horizontally rotating 3D movie](#) (QuickTime, 9.4 MB) shows the mass, as well as the subcutaneous scar from the prior Pfannenstiel incision site (P).

B. Cephalically angled view from a [vertically rotating 3D movie](#) (QuickTime, 11.5 MB) showing mass (M), subcutaneous scar (arrows) and anterior abdominal wall scar (arrowheads) from prior Pfannenstiel incision site.

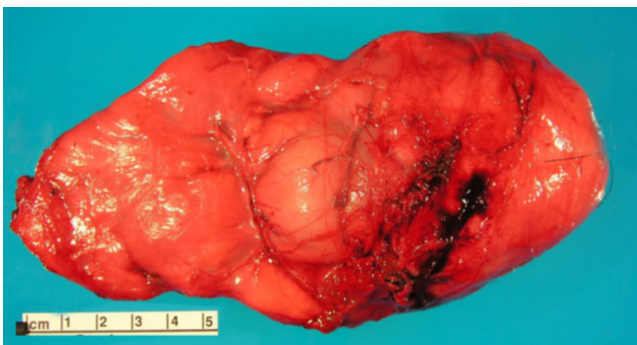
## Abdominal Cavity Myolipoma Presenting as an Enlarging Incisional Hernia



**Figure 4.** Axial T1-weighted image of lower abdomen, showing dumbbell-shaped right lower quadrant mass adjacent to the psoas muscle, extending through the abdominal wall into the overlying subcutaneous tissue.



**Figure 5.** Coronal T1-weighted (A) and STIR (B) images of anterior abdomen, demonstrating mass (M) herniating through anterior abdominal wall at the lateral margin of the Pfannenstiel incision (arrows).



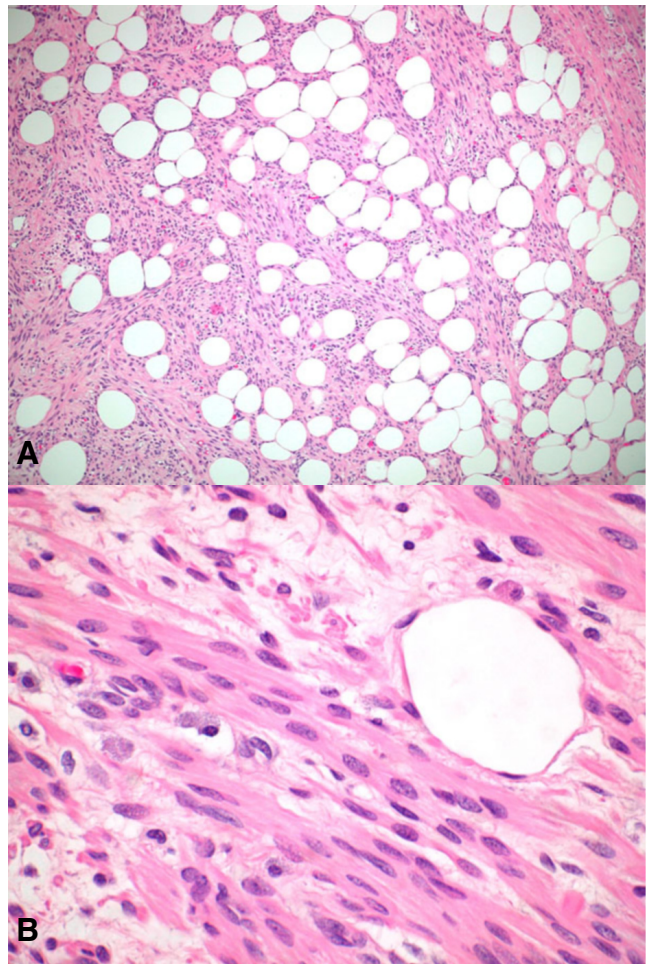
**Figure 6.** Gross photograph of the excised mass shows a large, lobulated lesion surrounded by a thin, well-vascularized and fibrous pseudocapsule.

to it. Liposarcoma, malignant fibrous histiocytoma, desmoid tumor, and leiomyosarcoma were considered in the

differential diagnosis prior to surgery.

Surgical total excision was performed for symptomatic relief. At operation, the tumor was found to herniate through the lateral aspect of the patient's prior Pfannenstiel incision in the right lower quadrant of the abdominal wall. With further investigation, it became apparent that the neoplastic process extended into the peritoneal cavity, which was subsequently explored. A mobile mass with loose fibrinous attachments to the intraperitoneal abdominal wall and loops of small bowel was present.

The pathologic specimen had a maximal diameter of 16 cm (Figure 6). Macroscopic examination showed a pink, multilobulated soft tissue mass, with a glistening, membranous capsule covering the entire exterior surface.



**Figure 7.** Photomicrographs of the tumor with hematoxylin and eosin stain.

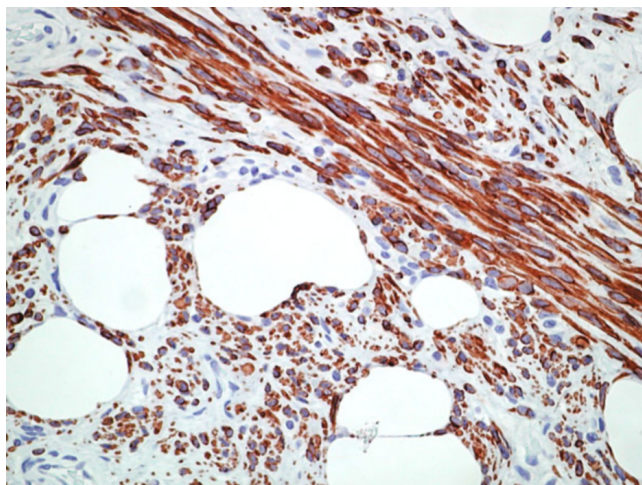
A. Low power photomicrograph of the tumor showing an admixture of mature adipose tissue and benign-appearing spindle cells with brightly eosinophilic cytoplasm.

B. High power photomicrograph showing cytologic features of spindle cell proliferation. These spindle cells have elongated nuclei with tapered ends and abundant eosinophilic cytoplasm.

## Abdominal Cavity Myolipoma Presenting as an Enlarging Incisional Hernia

Numerous fine blood vessels coursed over the surface of the mass, emanating from a vascular pedicle. On fresh cut section, the tissue was homogeneous and pale yellow in color, and a 3.0 cm fluid-filled cyst was present in the center of the mass.

On histologic examination (Figures 7 and 8), the mass was composed of fascicles of benign appearing spindle cells admixed with mature adipose tissue. The spindle cells had elongated nuclei with tapering ends and brightly eosinophilic cytoplasm.



**Figure 8.** High-power microscopic section of the tumor with immunohistochemical stain for desmin. The brown areas shown here denote lesional cells which are diffusely and strongly positive for desmin. Similar lesional cells were also diffusely and strongly positive for smooth muscle actin (not shown).

Cytologic pleomorphism, mitotic figures and necrosis were not identified. On immunohistochemical studies (Figure 8), spindle cells were diffusely and strongly positive for smooth muscle actin and desmin.

All 20 cells examined contained a balanced translocation between chromosomes 12 and 14 [46, XX, t(12,14)(q15;q23)], and 5 of these cells contained multiple additional abnormalities. Final histological diagnosis was compatible with myolipoma.

The patient made an uneventful recovery and was discharged from the hospital 6 days after surgery. At 2 weeks postoperative follow-up she was symptom-free.

### Discussion

Myolipoma is an exceedingly rare but benign soft tissue tumor that is composed of smooth muscle cells and adipocytes (1, 2). It may occur in many anatomic sites throughout the body including spinal cord (3), retroperitoneum (4-6), abdominal cavity (6), uterus and adnexae (7-11), eyelid (12), pericardium (13), and breast (14). The majority of lesions arise in the deeply located soft tissues of the retroperitoneum and abdomen where prompt clinical detection is difficult. Consequently, they are usually large at initial

presentation with a greatest diameter of more than 10 cm (2). Complete surgical resection of a myolipoma is considered to be curative, with no known reports or local recurrence, metastatic disease or malignant transformation (2).

The gross pathologic appearance of myolipoma is that of a completely or partially encapsulated soft tissue mass. Histologically, it is composed of bundles and sheaths of smooth muscle interspersed with islands of mature adipose tissue. The tissue components may be present in varying proportions, but there is typically a regular distribution of adipose tissue mixed throughout the lesion. In our case, the tumor exhibited the distinct microscopic appearance of myolipoma, with bland, well-differentiated smooth muscle and adipose tissue. Both of these components lacked any features suggestive of malignancy, such as cytologic atypia, mitotic figures, or necrosis. The immunohistochemical appearance in our case was characteristic as well, with smooth muscle elements that were strongly positive for smooth muscle actin and desmin.

Radiologic features reflect the dual tissue composition revealed at pathologic examination. The CT and MRI imaging appearances therefore vary along a spectrum, representing varying proportions of intermixed adipose tissue and smooth muscle components. On CT, both fat and soft-tissue attenuation areas are noted.

On T1-weighted MRI imaging, smooth muscle elements appear as areas of intermediate signal intensity. T2-weighted images of these regions are of intermediate to high signal intensity. Calcifications are variably present, though they more commonly occur in large-sized lesions. Our patient's lesion did not exhibit evidence of calcification by CT or MRI, but was otherwise typical for myolipoma.

Incisional hernias generally present as a bulge in the abdominal wall in the area of a prior surgical incision. This is a relatively common occurrence following midline abdominal operations, with a reported prevalence of at least 10% of patients undergoing these procedures (15, 16). Incisional hernias are much less likely following a Pfannenstiel incision, with a reported prevalence of 2.1% in one large series (15). Though the type of incision utilized is important, there are also a variety of predisposing biological and mechanical factors that play a role in hernia development. Constitutional variables including diabetes, obesity, malnutrition, and metabolic or lung disease (16, 17), as well as technical variables such as suture material and wound closure technique (16) may impair the normal healing response and are therefore thought to be important risk factors.

Only a few instances have been described of intraabdominal tumors protruding into an incisional hernia of the anterior abdominal wall. Delpero et al. (18) reported a case of primary fibrosarcoma of the peritoneum presenting as a huge pedunculated abdominal mass protruding into a large incisional hernia of the anterior abdominal wall in an elderly female patient. Marshall et al. (19) reported an enlarging incisional hernia of the lower abdomen attributable to benign cystic mesothelioma of the peritoneum. They noted a tendency for this tumor to recur locally, with diffuse

## Abdominal Cavity Myolipoma Presenting as an Enlarging Incisional Hernia

multicystic involvement of the abdominal and pelvic peritoneal surfaces. Sataloff et al. (20) reported a case of abdominal wall scar endometriosis that presented as a tender lump beneath the site of a prior cesarean section. Huber-Bucholz et al. (21) documented the occurrence of metastatic Fallopian tube carcinoma in an incisional hernia 15 years after initial surgical intervention.

Of these four cases, three involved aggressive tumors with an inherent capacity for recurrence or metastasis. The case of scar endometriosis is an exception, since it does not represent invasion by an uncontrolled neoplastic process. Instead, it is explained by direct intraoperative transfer of endometrial cells or peritoneal metaplasia (20). However, the tendency for spread of endometrial implants to extrapelvic sites, especially following surgical procedures, has been well-documented. The case we describe here differs from these prior reports in that it involves a characteristically non-aggressive disorder that is not known to recur following excision.

Although myolipoma frequently originates in the abdominal cavity, we are unaware of one presenting as an enlarging incisional hernia. This unusual behavior raises the possibility that the patient's initial adnexal mass was not entirely removed at excisional biopsy and that its remnants within the abdomen later infiltrated the lower abdominal wall. It is also possible that fragments of the original tumor were unknowingly sutured into her Pfannenstiel incision during the process of wound closure. Alternatively, the presently expanding mass may not represent a recurrence of tumor encountered at past operation, but an entirely new and unrelated process. There is no clear-cut answer to these issues because biopsy of the original lesion showed inflammatory adhesions at final pathology, a finding that may accurately depict the lesion or reflect an unproductive biopsy attempt.

In conclusion, we present a case of abdominal cavity myolipoma with characteristic pathology and imaging findings. Myolipoma is a rare soft tissue tumor that is frequently large and deeply located, but clinically benign. This case was unusual in that it herniated through the abdominal wall via a prior Pfannenstiel incision into the subcutaneous tissue. Recognition of the intra- and extraperitoneal location of this abdominal tumor was essential for accurate surgical planning.

### References

1. Mentzel T, Fletcher CD. Lipomatous tumours of soft tissues: an update. *Virchows Arch* 1995; 427:353-363. [[PubMed](#)]
2. Murphey MD, Carroll JF, Flemming DJ, Pope TL, Gannon FH, Kransdorf MJ. From the archives of the AFIP: benign musculoskeletal lipomatous lesions. *Radiographics* 2004; 24:1433-1466. [[PubMed](#)]
3. Knierim DS, Wacker M, Peckham N, Bedros AA. Lumbosacral intramedullary myolipoma. Case report. *J Neurosurg* 1987; 66:457-459. [[PubMed](#)]
4. Michal M. Retroperitoneal myolipoma. A tumour mimicking retroperitoneal angiomyolipoma and liposarcoma with myosarcomatous differentiation. *Histopathology* 1994; 25:86-88. [[PubMed](#)]
5. Takahashi Y, Imamura T, Irie H, et al. Myolipoma of the retroperitoneum. *Pathol Int* 2004; 54:460-463. [[PubMed](#)]
6. Meis JM, Enzinger FM. Myolipoma of soft tissue. *Am J Surg Pathol* 1991; 15:121-125. [[PubMed](#)]
7. Lehrman BJ, Nisenbaum HL, Glasser SA, Najjar D, Rosen M. Uterine myolipoma. Magnetic resonance imaging, computed tomographic, and ultrasound appearance. *J Ultrasound Med* 1990; 9:665-668. [[PubMed](#)]
8. Ekici E, Vicdan K. Uterine myolipoma: diagnosis by ultrasound. *Int J Gynaecol Obstet* 1993; 42:167-171. [[PubMed](#)]
9. Villanueva AJ, Martinez-Noguera A, Perez C, Clotet M, Oliva E. Uterine myolipoma: CT and US. *Abdom Imaging* 1993; 18:402-403. [[PubMed](#)]
10. Fernandez-Aguilar S, Saint-Aubain N, Dargent JL, Fayt I, Noel JC. Myolipoma of soft tissue: an unusual tumor with expression of estrogen and progesterone receptors. Report of two cases and review of the literature. *Acta Obstet Gynecol Scand* 2002; 81:1088-1090. [[PubMed](#)]
11. Sonobe H, Ohtsuki Y, Iwata J, Furihata M, Ido E, Hamada I. Myolipoma of the round ligament: report of a case with a review of the English literature. *Virchows Arch* 1995; 427:455-458. [[PubMed](#)]
12. Sharara N, Lee WR, Weir C. Myolipoma of the eyelid. *Graefes Arch Clin Exp Ophthalmol* 1998; 236:630-634. [[PubMed](#)]
13. Ben-Izhak O, Elmalach I, Kerner H, Best LA. Pericardial myolipoma: a tumour presenting as a mediastinal mass and containing oestrogen receptors. *Histopathology* 1996; 29:184-186. [[PubMed](#)]
14. McGregor DK, Whitman GJ, Middleton LP. Myolipoma of the breast: mammographic, sonographic, and pathologic correlation. *Breast J* 2004; 10:259-260. [[PubMed](#)]
15. Luijendijk RW, Jeekel J, Storm RK, et al. The low transverse Pfannenstiel incision and the prevalence of incisional hernia and nerve entrapment. *Ann Surg* 1997; 225:365-369. [[PubMed](#)]
16. Yahouchy-Chouillard E, Aura T, Picone O, Etienne JC, Fingerhut A. Incisional hernias. I. Related risk factors. *Dig Surg* 2003; 20:3-9. [[PubMed](#)]
17. Franchi M, Ghezzi F, Buttarelli M, Tateo S, Balestreri D, Bolis P. Incisional hernia in gynecologic oncology patients: a 10-year study. *Obstet Gynecol* 2001; 97:696-700. [[PubMed](#)]
18. Delpero JR, Lieutaud R, Dominguez C, Guerinel G, Carcassonne Y. Primary pedunculated fibrosarcoma of the peritoneum: a case report. *J Surg Oncol* 1984; 25:178-185. [[PubMed](#)]
19. Marshall RM, Gould VE, King ME, Jensik S, Chejfec G. Multicystic abdominal peritoneal tumor presenting as an enlarging incisional hernia. *Ultrastruct Pathol* 1985; 8:249-256. [[PubMed](#)]

## Abdominal Cavity Myolipoma Presenting as an Enlarging Incisional Hernia

20. Sataloff DM, La Vorgna KA, McFarland MM. Extrapelvic endometriosis presenting as a hernia: clinical reports and review of the literature. *Surgery* 1989; 105:109-112. [[PubMed](#)]
21. Huber-Buchholz MM, Buchholz NP. Late recurrence of fallopian tube carcinoma in an incisional hernia. *Arch Gynecol Obstet* 1994; 255:55-56. [[PubMed](#)]