

ORIGINAL RESEARCH

Hydraulic dissection technique during endoscopic sinus surgery using a novel balloon sinus dilation device

Isaac L. Schmale MD¹  | William C. Yao MD²  | Martin J. Citardi MD²

¹Department of Otolaryngology Head and Neck Surgery, University of Rochester Medical Center, Rochester, New York, USA

²Department of Otorhinolaryngology, McGovern Medical School, The University of Texas Health Science Center at Houston, Houston, Texas, USA

Correspondence

Isaac L. Schmale, MD, Department of Otorhinolaryngology-Head & Neck Surgery, University of Rochester Medical Center, 601 Elmwood Avenue, Box 629, Rochester, NY 14642, USA.
Email: isaac_schmale@urmc.rochester.edu

Funding information

Dalent Medical

Abstract

Background: More than a decade after its introduction, some rhinologic surgeons have incorporated the technique of balloon sinus dilation (BSD) technology into “hybrid” endoscopic sinus surgery (ESS) procedures. A novel BSD device which can be placed over standard surgical instruments, including surgical navigation instruments, has recently been introduced. We present a case series in which this device was used as a hydraulic dissection tool to aid safe efficient surgery in difficult-to-access locations of the paranasal sinuses during hybrid ESS procedures.

Objective: Highlight the potential role of hydraulic dissection techniques during ESS utilizing BSD.

Methods: Retrospective case series of patients who underwent ESS performed in part with a novel BSD device.

Results: A total of 10 patients who underwent hybrid ESS with BSD were reviewed. In all 10 cases, the novel BSD device was used without complication. The device was used over straight and curved suctions while being tracked with surgical navigation in all cases. Thirteen posterior ethmoid dissections, 12 sphenoidotomies, and 8 frontal sinusotomies were assisted with the device. For the selected dissections in which the balloon was utilized, the operating surgeon found it to be helpful in creating more space in difficult to access areas which allowed for continued safe surgical dissection.

Conclusions: Sinus balloon devices can be used as a hydraulic dissection tool and may be a useful adjunct during ESS. The novel dilation system used in this study, which deploys a sinus balloon device over standard surgical instruments with surgical navigation, provides even more opportunity to accurately dissect difficult areas of the paranasal sinuses safely and efficiently. Further studies evaluating the exact role of sinus balloon devices used as a hydraulic dissection tool during ESS are warranted.

Level of Evidence: 4.

KEYWORDS

balloon, balloon sinus dilation, endoscopic sinus surgery, ethmoid, frontal, hybrid, hybrid endoscopic sinus surgery, hydraulic dissection, navigation, sphenoid

This manuscript was accepted for poster presentation at the 2020 American Rhinologic Society Annual Meeting (Boston, MA, September 12, 2020).

This is an open access article under the terms of the Creative Commons Attribution-NonCommercial-NoDerivs License, which permits use and distribution in any medium, provided the original work is properly cited, the use is non-commercial and no modifications or adaptations are made.

© 2021 The Authors. *Laryngoscope Investigative Otolaryngology* published by Wiley Periodicals LLC on behalf of The Triological Society.

1 | INTRODUCTION

Chronic rhinosinusitis (CRS) affects millions of people in the United States with direct yearly costs in the billions of dollars.¹⁻³ First-line treatment for CRS is medical therapy. For those who have failed medical therapy, endoscopic sinus surgery (ESS) remains a mainstay of treatment. Since 2005, balloon sinus dilation (BSD) procedures have become increasingly common for the treatment of CRS.⁴ In addition to standalone BSD procedures, balloon devices have been utilized in “hybrid” ESS procedures in an estimated 7.7% of sinus surgery cases.⁴ Proposed advantages of BSD as a standalone procedure or used in a hybrid balloon/ESS fashion are: improved mucosal preservation, decreased operating room time, and improved access in otherwise difficult sinonasal compartments (ie, posterior ethmoid, sphenoid, and frontal recess).⁵ Multiple studies have included analysis of BSD use during hybrid ESS procedures; however, these mostly refer to instances in which balloon devices and standard ESS techniques were utilized separately in the same patient.^{4,6-14} In few studies, BSD has been implemented in a “true” hybrid fashion, in which balloon dilation is used as another surgical instrument to help achieve safe and efficient dissection of the paranasal sinuses.¹⁵⁻¹⁸

Recently, a novel BSD device, Sinusleeve (Dalent Medical, Miami, Florida), which can be placed over standard surgical instruments including surgical navigation instruments, has become commercially available (Figure 1). We propose that in specific surgical situations such as difficult frontal anatomy, tight posterior ethmoid/sphenoethmoid recess dissection, and in inflammatory cases with increased mucosal bleeding, a hybrid technique utilizing a BSD device placed over suction navigation instruments could be helpful. In this study, we report the first case series of 10 patients utilizing this novel BSD device in hybrid ESS procedures and detail several methods that its use may aid in improved visualization and surgical access.

2 | METHODS

After approval from the University of Texas Health Science Center at Houston Institutional Review Board, we retrospectively reviewed 10 patients who underwent ESS for CRS in which the Sinusleeve (Dalent Medical, Miami, Florida) device was utilized during the 4 months ending December 31, 2019. For each use, the surgeon

assessed the value of the BSD device to aid in opening diseased sinus compartments and to facilitate continued ESS. The Sinusleeve balloon was placed over straight or curved navigation suctions in all instances. After placement under direct endoscopic visualization, the balloon was inflated to 8 to 10 atm of pressure for 5 to 10 seconds. The balloon was then deflated and the surgical site assessed for increased space allowing for continued dissection, improved access to next sinus compartment to be addressed and improved visibility. In each location, the balloon was used one to three times to achieve desired results. ESS would then proceed with standard surgical instruments until completion of the procedure. The Sinusleeve specifications include a 7 mm outer diameter and a 20 mm working balloon length. The device is compatible with most standard ENT instruments within a 7F to 10F diameter.

3 | RESULTS

A total of 10 patients (two women, eight men; ages 33-65) who underwent hybrid ESS procedures with the Sinusleeve device were reviewed. All patients had a diagnosis of refractory CRS confirmed by nasal endoscopy and CT scan after medical treatment. In all cases, the BSD system was used in combination with traditional ESS techniques. The device was used over straight and curved suctions while being tracked with surgical navigation in all cases. In total, 13 posterior ethmoid dissections, 12 sphenoid ostium dissections, and 8 frontal sinusotomies were assisted with the device. Patient information and summary of BSD applications are shown in Table 1. In one instance, although the balloon accomplished the goal of increasing the frontal sinus outflow tract diameter, the balloon broke on a sharp piece of bone within the frontal recess. In all other balloon applications, the balloon remained intact throughout the procedure.

For the selected dissections in which the balloon was utilized, the operating surgeons found that: utilizing the balloon could increase working room within the posterior ethmoid (Figure 2), sphenoid ostium (Figure 3) and frontal recess (Figure 4) which facilitated further natural pathway surgery. Furthermore, surgeons rated the device as especially helpful in cases in which inflammation led to increased mucosal bleeding during sharp dissection. In these situations, BSD allowed for continued surgical progress with minimal further bleeding while creating a larger well for subsequent blood loss leading to an



FIGURE 1 Sinusleeve balloon sinus dilation device loaded over (from left to right) straight, short curved and long curved suctions. (Images provided by Dalent Medical, Miami, FL)

TABLE 1 Patient characteristics and balloon use summary

ID#	Age	Gender	Lund-Mackay Score (0-24)	Sites in which the BSD device was used
1	59	Female	23	Bilateral posterior ethmoid, bilateral sphenoid, left frontal recess
2	56	Male	13	Bilateral posterior ethmoid, bilateral sphenoid, bilateral frontal recess
3	60	Female	2	Bilateral sphenoid
4	44	Male	12	Left posterior ethmoid, right sphenoid
5	55	Male	11	Bilateral posterior ethmoid
6	54	Male	12	Bilateral posterior ethmoid, left sphenoid, left frontal recess
7	33	Male	8	Bilateral sphenoid
8	53	Male	10	Bilateral posterior ethmoid, bilateral sphenoid, bilateral frontal recess
9	45	Male	13	Bilateral posterior ethmoids
10	65	Male	10	Bilateral frontal recess

FIGURE 2 Hydraulic dissection of the posterior ethmoid utilizing the Sinusleeve device loaded over straight navigation suctions (from left to right: pre-dilation, during dilation, post-dilation)

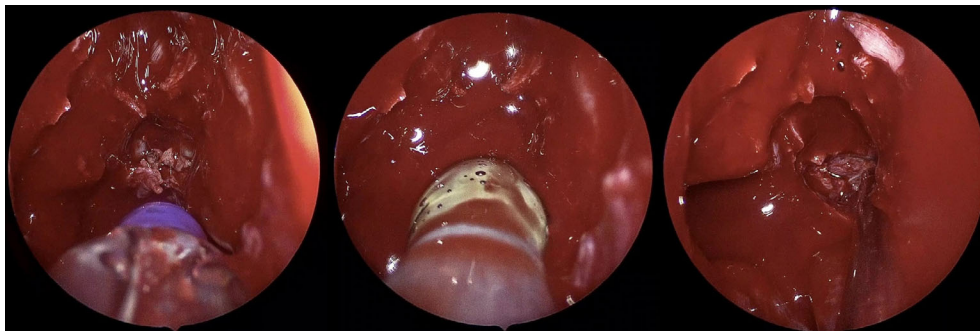

FIGURE 3 Hydraulic dissection of the sphenoid sinus utilizing the Sinusleeve device loaded over straight navigation suctions (from left to right: pre-dilation, during dilation, post-dilation)

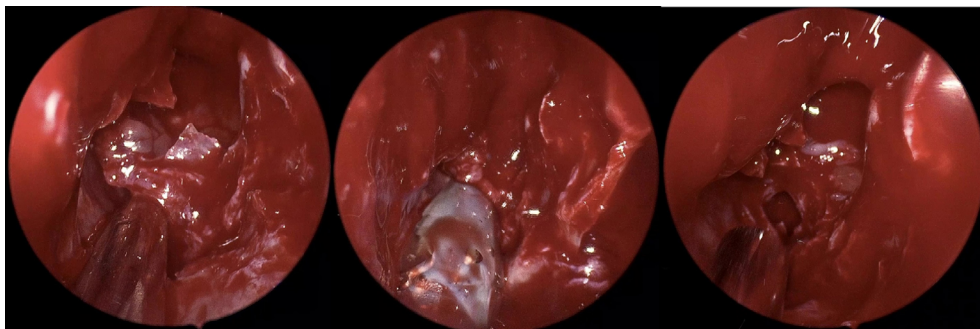
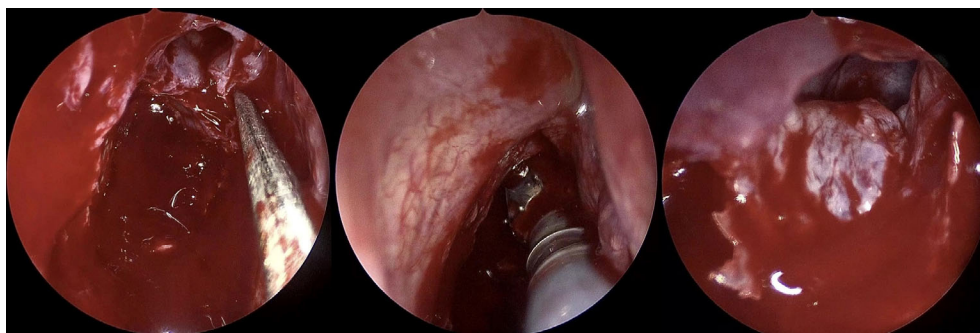


FIGURE 4 Hydraulic dissection of the frontal recess utilizing the Sinusleeve device loaded over curved frontal navigation suctions (from left to right: pre-dilation, during dilation, post-dilation)



improved operative field. There were no intraoperative complications. All patients were discharged on the same day as surgery with no patients experiencing postoperative complications such as hemorrhage, infection, cerebrospinal fluid leak, or traumatic entry into the orbit.

4 | DISCUSSION

Since BSD systems were approved for use in the United States in 2005, standalone BSD procedures as well as hybrid BSD-ESS procedures have gained increasing acceptance.^{4,6,19} In difficult situations where surgical access or visualization is an issue, utilizing BSD as a hydraulic dissection tool provides a technique which may aid surgeons during these more challenging portions of ESS. The majority of the published data to date has focused on hybrid BSD procedures in which balloon dilation was used to address specific sinuses, whereas remaining diseased sinuses in the same patient were addressed by traditional ESS techniques.^{4,6-14} A few prior studies have reported true “hybrid” BSD ESS procedures, in which balloon dilation has been used as another dissection tool during ESS. In total, three reports have investigated the use of BSD during frontal sinus ESS,^{15,16,18} and one study has reported use of balloon dilation within the ethmoid sinuses as a tool during ESS.¹⁷

In our study, the Sinusleeve device was used in 10 patients in a variety of operative scenarios. Specifically, in situations where inflammation made dissection in the posterior ethmoid difficult and the operative field was bloody, BSD was then utilized over tracked suction instruments and allowed for continued safe and efficient surgery, while improving the operative field for subsequent progress. In this situation, the BSD device was loaded over straight navigation suctions, and placed medially in the posterior ethmoid cavity to fracture obstructing bony partitions and compress polypoid inflammation laterally away from the sphenoid os. Balloon expansion thus created more space for pooling of blood and instrument placement. Then further dissection with sharp instruments continued more easily. Similarly, the BSD device was found to be useful when anatomic and patient specific constraints made sphenoid os identification or enlargement difficult. Again, the BSD device was loaded over straight navigation suctions, and placed into the natural sphenoid os. Placement was confirmed with surgical navigation, and then the device was inflated one to three times until the desired effect had been achieved. Dissection then continued with clearance of diseased mucosa and fractured pieces of bone with standard instruments.

For difficult frontal recess dissections, BSD with suction navigation capability allowed for surgical progress with mucosal preservation (see Video S1 for demonstration). For each use in the frontal recess, the natural drainage pathway was identified using a small frontal sinus seeker and then confirmed after placement of the BSD device over a navigation frontal suction. The balloon was used to fracture the agger nasi cell, supra agger cells, and supra bullar cells. After one to three dilations, the pathway into the frontal sinus was successfully enlarged in all uses. Stray fragments of bone and mucosa were then removed

and additional dissection until completion of the frontal sinusotomy was carried out with standard endoscopic sinus instruments. Surgeons found use of the BSD device especially helpful for use in the natural frontal sinus drainage pathway. This device may provide another tool to help improve the operative field and assist in mucosal sparring, minimally traumatic dissection within the frontal recess, which is of heightened importance in this region.²⁰

During discussions of adjunctive technology as an aid during sinus surgery, it is important to consider the relative advantages compared to the alternatives. One such factor is cost. The Sinusleeve device costs approximately \$900 per device and can be used to dilate multiple sinuses (six sites during a single case in this study). Other balloon dilation devices are commercially available with variable costs, but frequently quoted up to 50% or 100% more than the device utilized in our study. Another specific advantage of the Sinusleeve device is ergonomics of use during ESS. The device is loaded over standard ESS instruments, allowing surgeons to choose whatever instrument they feel most comfortable with to guide the balloon to the desired location. Additionally, having a balloon loaded over sinus surgery instruments potentially allows for dual functionality, which theoretically could improve efficiency, where as other current balloon devices only serve as a dilation tool.

Of note, this report summarizes initial experiences with a new device deployed in a tertiary rhinology practice. Limitations of retrospective reviews are readily apparent. Nonetheless, the device was used successfully in all 10 cases, and clearly offered the specific advantages. As mentioned previously, during one application of the device a sharp piece of bone cut the balloon and required a replacement to be used. This was not surprising as the area addressed had osteitic bony fragments and this is an inherent possibility with all balloon technology. Overall, in our study, the rate of balloon failure was 1 out of 33 sites utilized, and at each site, the balloon was deployed 1 to 3 times. It should also be noted that the Sinusleeve does alter the geometry of the distal tip of the navigation tool. For a pre-calibrated instrument, the surgeon must recognize this difference in interpretation of the navigation views. Real-time calibration of instruments obviously would eliminate this issue. Additionally, the Sinusleeve device adds to the inherent diameter of any suction or navigation instrument in use. As such, in certain anatomic locations where space may be at a premium, such as during dissection of very narrow frontal outflow tracts or in areas of closely packed ethmoid cells, the device may have limited utility until more working room has been created via standard ESS techniques. Further prospective studies that evaluate the exact role and potential benefits of BSD as an adjunct during hybrid ESS procedures are warranted.

5 | CONCLUSIONS

This Sinusleeve sinus balloon device may be a useful adjunct during hybrid ESS procedures. This novel dilation system, which deploys a sinus balloon device over standard surgical instruments, including instruments with surgical navigation, provides even more opportunity

to accurately dissect difficult areas of the paranasal sinuses safely and efficiently. Further studies evaluating the exact role of sinus balloon devices as a hydraulic dissection tool during FESS are warranted.

ACKNOWLEDGMENT

Dalent Medical (Miami, Florida) provided Sinusleeve devices at no cost as part of product assessment at the facility where the procedures were performed and also funded article processing charges as required for publication.

DISCLOSURE OF INTERESTS

Isaac L. Schmale has no disclosures. William C. Yao serves as a consultant for Stryker (Kalamazoo, Michigan) and is part of the Speaker's Bureau for Optinose, Inc (Yardley, Pennsylvania). Martin J. Citardi serves as a consultant for Acclarent (Irvine, California), Medical Metrics (Houston, Texas) MicroGenDX (Lubbock, Texas) and Stryker (Kalamazoo, Michigan).

ORCID

Isaac L. Schmale  <https://orcid.org/0000-0001-8199-7428>

William C. Yao  <https://orcid.org/0000-0002-9845-2165>

BIBLIOGRAPHY

- Bhattacharyya N. Contemporary assessment of the disease burden of sinusitis. *Am J Rhinol Allergy*. 2009;23(4):392-395.
- Blackwell DL, Lucas JW, Clarke TC. Summary health statistics for U.S. adults: national health interview survey. *Vital Health Stat* 10. 2012;2014(260):1-161.
- Orlandi RR, Kingdom TT, Hwang PH, et al. International consensus statement on allergy and rhinology: Rhinosinusitis. *Int Forum Allergy Rhinol*. 2016;6(Suppl 1):S22-S209.
- Chaaban MR, Rana N, Baillargeon J, Baillargeon G, Resto V, Kuo YF. Outcomes and complications of balloon and conventional functional endoscopic sinus surgery. *Am J Rhinol Allergy*. 2018;32(5):388-396.
- Melroy CT. The balloon dilating catheter as an instrument in sinus surgery. *Otolaryngol Head Neck Surg*. 2008;139(Suppl 3):S23-S26.
- Jang DW, Abraham C, Cyr DD, Schulz K, Abi Hachem R, Witsell DL. Balloon catheter dilation of the sinuses: a 2011-2014 MarketScan analysis. *Otolaryngol Head Neck Surg*. 2018;159(6):1061-1067. <http://10.1177/0194599818791811>. Epub ahead of print.
- Hathorn IF, Pace-Asciak P, Habib AR, Sunkaraneni V, Javer AR. Randomized controlled trial: hybrid technique using balloon dilation of the frontal sinus drainage pathway. *Int Forum Allergy Rhinol*. 2015;5(2):167-173.
- Brodner D, Nachlas N, Mock P, et al. Safety and outcomes following hybrid balloon and balloon-only procedures using a multifunction, multisinus balloon dilation tool. *Int Forum Allergy Rhinol*. 2013;3(8):652-658.

- Tomazic PV, Stammler H, Braun H, et al. Feasibility of balloon sinuplasty in patients with chronic rhinosinusitis: the Graz experience. *Rhinology*. 2013;51(2):120-127.
- Plaza G, Eisenberg G, Montojo J, Onrubia T, Urbasos M, O'Connor C. Balloon dilation of the frontal recess: a randomized clinical trial. *Ann Otol Rhinol Laryngol*. 2011;120(8):511-518.
- Levine HL, Sertich AP 2nd, Hoisington DR, Weiss RL, Pritikin J. Multi-center registry of balloon catheter sinusotomy outcomes for 1,036 patients. *Ann Otol Rhinol Laryngol*. 2008;117(4):263-270.
- Garvey CM. Sinus balloon dilators: one surgeon's experience and proposed indications for their use. *Ear Nose Throat J*. 2009;88(4):E12-E16.
- Catalano PJ, Payne SC. Balloon dilation of the frontal recess in patients with chronic frontal sinusitis and advanced sinus disease: an initial report. *Ann Otol Rhinol Laryngol*. 2009;118(2):107-112.
- Weiss RL, Church CA, Kuhn FA, Levine HL, Sillers MJ, Vaughan WC. Long-term outcome analysis of balloon catheter sinusotomy: two-year follow-up. *Otolaryngol Head Neck Surg*. 2008;139(3 Suppl 3):S38-S46.
- Fleischman GM, Miller JD, Kim GG, Zanation AM, Ebert CS. Treatment of chronic frontal sinusitis with difficult anatomy: a hybrid balloon technique in four cases. *Allergy Rhinol (Providence)*. 2014;5(3):120-124.
- Christmas DA, Mirante JP, Yanagisawa E. Hybrid frontal sinus surgery with balloon dilation and microdebrider resection. *Ear Nose Throat J*. 2015;94(8):304-305.
- Kutluhan A, Bozdemir K, Cetin H, et al. Endoscopic balloon dilation sinuplasty including ethmoidal air cells in chronic rhinosinusitis. *Ann Otol Rhinol Laryngol*. 2009;118(12):881-886.
- Askar MH, El-Sherif HS, Tomoum MO, Senior BA. Use of a Foley catheter balloon as a tool during endoscopic frontal sinus surgery in a resource-poor environment. *Ann Otol Rhinol Laryngol*. 2015;124(3):194-197.
- Koester LK, Goyal P. Utilization and reimbursements for sinus procedures: a five-year analysis. *Laryngoscope*. 2019;129(10):2224-2229.
- Kuhn FA, Javer AR. Primary endoscopic management of the frontal sinus. *Otolaryngol Clin North Am*. 2001;34(1):59-75.

SUPPORTING INFORMATION

Additional supporting information may be found in the online version of the article at the publisher's website.

How to cite this article: Schmale IL, Yao WC, Citardi MJ. Hydraulic dissection technique during endoscopic sinus surgery using a novel balloon sinus dilation device. *Laryngoscope Investigative Otolaryngology*. 2021;6(5):899-903. doi:10.1002/lio2.638