

Clinico-immunological response to intratumoral versus intravenous neoadjuvant chemotherapy in advanced pediatric solid malignancies

Vijayendra Kumar,
Nandini Ramaswami¹,
Anand Pandey,
Ram Chandra Shukla²,
Maloy Ranjan Sen³,
Shiv Prasad Sharma,
Dinesh Kumar Gupta,
Ajay Narayan Gangopadhyay

Department of Pediatric Surgery,
¹General Surgery, ²Radiodiagnosis,
and ³Microbiology, Institute of
Medical Sciences, Banaras Hindu
University, Varanasi,
Uttar Pradesh, India

Address for correspondence:

Prof. A. N. Gangopadhyay,
Departments of Pediatric Surgery,
Institute of Medical Sciences,
Banaras Hindu University,
Varanasi, Uttar Pradesh, India
E-mail: gangulybhu@rediffmail.com

ABSTRACT

Background: There is minimal literature on the use of intralesional chemotherapy in the pediatric age group. We undertook this present study to evaluate the two modalities (intratumoral and intravenous) of giving chemotherapy in terms of toxicity of chemotherapy, hematological parameters, efficacy of chemotherapy in reduction in volume of the tumor as well as resectability of tumor with special emphasis on immunological parameters. **Materials and Methods:** Advanced cases of Wilms' tumor and Neuroblastoma were included in the study. Intratumoral chemotherapy was given through 25 G spinal needle under aseptic precautions and ultrasound guidance in the same dose as in systemic chemotherapy. Intravenous group was given chemotherapy in the usual way. Reassessment was carried out after every course of chemotherapy. **Results:** Group A included 16 cases of Wilms' tumor and 6 cases of neuroblastoma. In group B, there were 14 cases of Wilms' tumor and 8 of neuroblastoma. Vomiting, diarrhea, mucositis, and thrombophlebitis were more common in the intravenous group ($P < 0.05$). The fall in Immunoglobulin A, Immunoglobulin G, Immunoglobulin M, and T-cell rosetting was more common in the intravenous group ($P < 0.05$). Seventy percent of patients had completely resectable tumor at the end of 6 doses of intratumoral chemotherapy as compared to 50% resectability in the intravenous group ($P < 0.05$). **Conclusion:** Intratumoral chemotherapy, besides causing less of the adverse effects and increasing the resectability rate, also causes less suppression of the immune system. This may be offered as an alternative safe and effective modality of treatment for advanced solid tumors.

Key words: Chemotherapy, intratumoral chemotherapy, intravenous chemotherapy, pediatric solid tumors

INTRODUCTION

Pediatric malignancies are only second to trauma as the leading cause of morbidity and mortality in developed countries.^[1] With an increasing control of infections, the malignant diseases are fast catching up to take the lead in developing countries.^[2] In a developed country, the percentage of patients with an advanced disease (Stage III and IV) is 30-35%; in our country, it is 65-70%.^[3] This poses a challenge to our health-care system, as these advanced cases invariably are candidates for neo-adjuvant chemotherapy.

To increase tolerance and to reduce the toxicity of chemotherapy, several authors have demonstrated that intra-arterial and intra-peritoneal modes of giving anticancer drugs are more effective than conventional intravenous mode.^[4-7]

There is minimal literature on the use of intralesional chemotherapy in the pediatric age group. We undertook this present study to evaluate the two modalities (intratumoral and intravenous) of giving chemotherapy in terms of toxicity of chemotherapy, hematological parameters, efficacy of chemotherapy in reduction in volume of the tumor as well as resectability of tumor with the special emphasis on immunological parameters.

MATERIALS AND METHODS

This prospective study was conducted in the Department of Pediatric Surgery of the University Hospital from

Access this article online

Quick Response Code:



Website:
www.ijmpo.org

DOI:
10.4103/0971-5851.116183

July 2004 to June 2010. It was approved by the Institute ethical committee. The parents were informed about the study, and written consent was taken from them. The study included patients with advanced (stage III and IV) Neuroblastoma or Wilms' tumor.

Advanced cases of Wilms' tumor and Neuroblastoma, proven by Fine needle aspiration cytology, which were not amenable to primary surgery and fresh cases with no previous treatment, were included in the study. The non-feasibility of surgical resection was decided by two senior consultants. The patients were allocated to 2 groups on a random basis: Study group (Group A) receiving intratumoral chemotherapy and Control group (Group B) receiving intravenous chemotherapy. Forty four children were included in the study. We had 22 patients in each group, of which group A included 16 cases of Wilms' tumor and 6 cases of neuroblastoma. In group B, there were 14 cases of Wilms' tumor and 8 of neuroblastoma. The age and sex was comparable in both groups. Patients were randomized on the basis of a random number table using the Strata-9 software (44 random numbers from 1 to 44 without replacement were randomized into two groups, or blocks, on the basis of the random number table).

The neo-adjuvant chemotherapy regimen followed was Vincristine, Adriamycin, Actinomycin D Vincristine, Adriamycin, Actinomycin regime containing Vincristine 1.5 mg/m² weekly for 6 weeks, Adriamycin 50 mg/m² (on day 1 in group A and in 3rd week in group B) and D actinomycin 45 µg/kg (on day 1 in group A in 3 divided doses, day 1-3 in group B).

Intravenous group was given chemotherapy in the usual way by a peripheral venous access.

Procedure

Intratumoral chemotherapy was given through 25 G spinal needle under aseptic precautions and ultrasound (USG) guidance in the same dose as in systemic chemotherapy. Injection hyaluronidase was given along with the chemotherapeutic agent in a study group to enhance the local distribution of the drug in tumor mass. Supportive therapy in the form of whole blood, platelets concentrate, and fresh frozen plasma was given as and when required.

Reassessment was carried out after every course of chemotherapy. The following parameters were studied: clinical toxicity, hematological parameter, immunological parameter, efficacy in terms of volume reduction, and resectability of tumor.

Clinical Toxicity was recorded in terms of nausea, vomiting,

diarrhea, alopecia, fever, mucositis, pain, phlebitis, and skin necrosis.

Hematological parameters were recorded in terms of hemoglobin, total leucocyte count and platelet count.

Immunological parameters were recorded as level of IgG, IgA, IgM, and T-cell rosetting.

Efficacy of Treatment was recorded as a reduction of volume and resectability of tumor. Reduction of volume was assessed clinically and by USG (Volume of the tumor = 0.523 × Product of all dimensions of the tumor). The volume reduction was categorized as >50% size reduction, 25-50% size reduction and <25% size reduction for easy comparison between the two groups, i.e., systemic and intratumoral group.

The grading of toxicity was in accordance with National Cancer Institute-common toxicity criteria-version 2.

For hematological parameters, grading was carried out in accordance to the Common toxicity criteria-2; given by the National institute of clinical excellence.

The method used to detect immunoglobulins was Single Radial Immunodiffusion. This method was described by Fahey in 1968.

Detection of Viable T-Cells was determined by the percentage of T-cells that form rosettes with sheep erythrocytes. A true rosette comprised three or more sheep Red blood cells RBCs, clustered around a lymphocyte.

The pre-chemotherapy value of IgG, IgM, IgA, and T-cell rosette was taken as 100%. The weekly assessment was carried out. The value obtained was then compared to the pre-chemotherapy value to calculate a fall in percentage from the pre-chemotherapy value.

The data obtained for each group was statistically analyzed by Chi-square test, Fisher's exact test, and Student T-test. *P* value < 0.05 was taken as significant.

RESULTS

All patients in the intratumoral group completed the 6 doses of chemotherapy in 6 weeks, except two patients, who expired after 1st week. The cause was unknown and probably they died due to advanced disease process. In intravenous group, 4 children expired and 2 were lost to follow-up. Hence, there were 20 patients in group A and 16 in group B.

Initially, no patient had vomiting. By 6th week, 2/20 (9%) had grade 2 nausea and 2/20 (9%) had grade 3 nausea in intratumoral group whereas 10/16 (62.5%) had grade 2 nausea and 2/16 (12.5%) had grade 3 nausea in the intravenous group ($P<0.05$).

There was no patient had diarrhea at the time of presentation. By 6th week, in intratumoral group, 2/20 (10%) had grade 1 diarrhea, and 2/20 (10%), had grade 2 diarrhea, whereas in the intravenous group, 8/16 (50%), had grade 2 diarrhea ($P<0.05$).

By 6th week, in intratumoral group, 2/20 (10%) had grade 2 mucositis, whereas in intravenous group, 4/8 (50%) had grade 1 mucositis, and 3/8 (37.5%) had grade 2 mucositis, and 1/8 (12.5%) had grade 3 mucositis ($P<0.01$).

By 3rd week, in intravenous group, all children had thrombophlebitis, and it was difficult to cannulate them. Only 1 child in the intratumoral group developed phlebitis in the 5th week ($P<0.001$). No child in the intratumoral group had skin necrosis whereas in the intravenous group, 6/16 (37.5%) had necrosis ($P<0.05$). Pain was experienced more by all patients receiving intratumoral chemotherapy, and the difference was statistically significant. Regarding the total leukocyte or platelet count, the difference was not statistically significant ($P = NS$).

The fall in IgA, from pre-chemotherapy values, was higher for intravenous group as compared to intratumoral group. By the completion of 6 cycles of chemotherapy, serum IgA had fallen from 100% to 52.58% of its pre-chemotherapy value in intratumoral group, whereas in the intravenous group it had fallen from 100% to 38.98% of its pre-chemotherapy value ($P<0.01$) [Figure 1].

The fall in IgG, from pre-chemotherapy values, were higher for intravenous group as compared to intratumoral group. By the completion of 6 cycles of chemotherapy, serum IgG had fallen from 100% to 82.39% of its pre-chemotherapy value in intratumoral group, whereas in the intravenous group it had fallen from 100% to 63.91% of its pre-chemotherapy value ($P<0.001$).

The fall in IgM, from pre-chemotherapy values, was higher for intravenous group as compared to intratumoral group. By the completion of 6 cycles of chemotherapy, serum IgM had fallen from 100% to 73.54% of its pre-chemotherapy value in intratumoral group whereas in the intravenous group it had fallen from 100% to 66.47% of its pre-chemotherapy value.

The fall was significant in the first 4 weeks; maximum in the 1st week.

The fall in T-cell rosette from pre-chemotherapy values, were higher for intravenous group as compared to intratumoral group. By the completion of 6 cycles of chemotherapy, T-cell rosetting capacity had fallen from 100% to 75.36% of its pre-chemotherapy value in intratumoral group, whereas in the intravenous group it had fallen from 100% to 57.86% of its pre-chemotherapy value ($P<0.001$).

At the completion of 6 cycles of chemotherapy, more than 50% reduction in tumor volume was attained in 14/22 (63.64%) of patients in the intratumoral group, as compared to 4/22 (18.18%) in the intravenous group ($P<0.05$) [Figure 2].

70% of patients had completely resectable tumor at the end of 6 doses of intratumoral chemotherapy as compared to 50% resectability in the intravenous group. This difference in resectability was statistically significant.

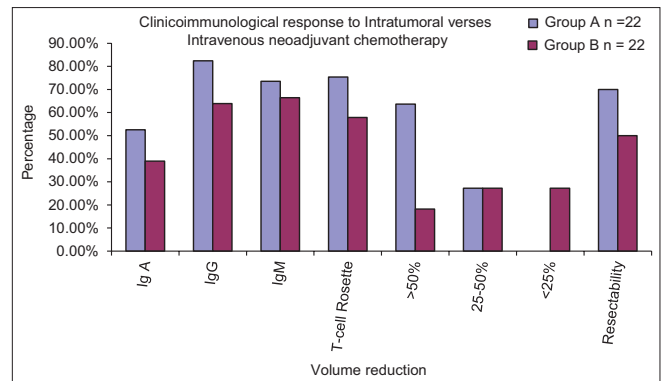


Figure 1: Graphical comparison of the two treatment modalities. Immunosuppression is less in intratumoral chemotherapy

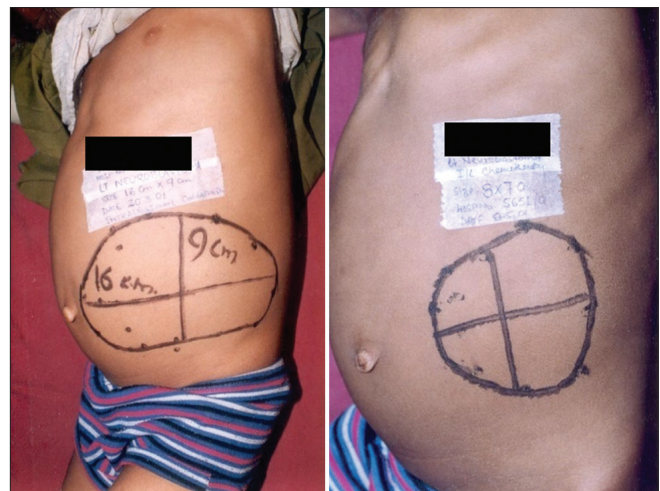


Figure 2: Results both before and after the administration of intratumoral chemotherapy. There is a visible reduction in size of the lump

DISCUSSION

In spite of advances in cancer research, advanced solid pediatric malignancies are difficult to manage mainly because of the advanced disease process, leading to poor general condition, and intolerance to multimodal therapy.

Wilms' tumor is a common solid malignant neoplasm of childhood.^[8] It is used as a model disease in Pediatric Oncology for multimodality treatment,^[9] which is standardized by the Wilms' tumor study group. Chemotherapy with actinomycin D was begun in 1954 and vincristine was added in 1963.^[10] The survival, which was less than 50% in 1950's is now approaching 80-90%.^[11] Vincristine and D actinomycin do not need hepatic metabolism for their activation. However, clearance is done by the liver. Hence, dose alteration may be needed in hepatic derangement.^[12,13] Adriamycin is metabolized to adriamycinol by the liver.^[14] In patients with normal hepatic function, Adriamycin has been found to be the principal agent, which is responsible for therapeutic effect. However, in patients with liver disease, adriamycinol tends to be more important, as it has been reported that total adriamycinol plasma concentrations are higher than total Adriamycin plasma concentrations.^[14]

The response to conventional intravenous chemotherapy in advanced disease is varied due to the systemic spread of drugs and poor tolerance of the already malnourished patient to these highly toxic drugs leading to postponement of chemotherapy in between. This has led to further extensive search for an alternative route of chemotherapy in advanced pediatric solid malignancies (e.g., Wilms' tumor and neuroblastoma) to improve tolerance and response rate. Intraarterial or intraperitoneal chemotherapy have better response, along with less complications, but they are more expensive, require better skill and adequate set up. There have been only sporadic studies regarding intratumoral injection of chemotherapeutic drugs in the pediatric age group.^[15]

The International Society of Pediatric Oncology (SIOP) has promoted the use of preoperative treatment of children with Wilms' tumor with chemotherapy, without histologic confirmation of the diagnosis before therapy is initiated. By following this protocol, a decrease in rupture rate from 33% to 4% and a lower surgical complication rate has been reported.^[16] The pre-operative treatment may significantly decrease the apparent stage of the children's disease.^[17]

It has been showed that pre-operative chemotherapy is useful in patients who represent a particularly high-risk for surgical intervention owing to a very large locally invasive primary tumor, extensive metastatic disease, massive ascitis,

or unstable metabolic status.^[18-20] However, the toxicity of conventional systemic chemotherapy affords limited effectiveness and frequently compromises the quality of life for patients. In this context, it should be noticed that targeted or localized drug delivery should be the major goal of chemotherapy.^[21] Despite the wide-spread use of chemotherapy, there is only limited clinical use of intratumoral chemotherapy for even those cancers, which have well-defined primary lesions.^[21]

Studies have shown that there is stimulation of tumor-specific systemic immune response, which eradicates metastasis. It results from processing of tumor specific antigen expressed by the tumor cell debris in immune competent individuals following intratumoral chemotherapy.^[21] The present study suggests that intratumoral chemotherapy causes less suppression of the immune system as compared to the intravenous chemotherapy. As no other study has been carried out, until now in this regard, it is not possible to have a comparative evaluation of the same. The effect of tumor spillage is not of much concern in an advanced stage; however, it was not seen in this study.

There is a limitation to this study. We have only compared the regression in the tumor size and immunological response on the basis of therapy, which was the basis of this study. The overall effect on survival and follow-up was not a part of this study. This has been assessed in other studies by our group, which shows a favorable outcome to this modality of treatment.^[15,22]

To conclude, intratumoral chemotherapy, besides causing less of the adverse effects and increasing the resectability rate, also causes less suppression of the immune system. This may be offered as an alternative safe and effective modality of treatment for advanced solid tumors. However, its mechanism of action and release in the systemic circulation needs to be evaluated in future study.

REFERENCES

1. Arias E, MacDorman MF, Strobino DM, Guyer B. Annual summary of vital statistics-2002. *Pediatrics* 2003;112:1215-30.
2. Kusumakumary P, Jacob R, Jothirmayi R, Nair MK. Profile of pediatric malignancies: A ten year study. *Indian Pediatr* 2000;37:1234-8.
3. Gupta DK, Sharma S, Agarwala S, Carachi R. Saga of Wilms' tumor: Lessons learnt from the past. *J Indian Assoc Pediatr Surg* 2005;10:217-28.
4. Ansfield FJ, Ramirez G, Davis HL Jr, Wirtanen GW, Johnson RO, Bryan GT, *et al.* Further clinical studies with intrahepatic arterial infusion with 5-fluorouracil. *Cancer* 1975;36:2413-7.
5. Balch CM, Urist MM, McGregor ML. Continuous regional chemotherapy for metastatic colorectal cancer using a totally implantable infusion pump. A feasibility study in 50 patients. *Am J Surg* 1983;145:285-90.

6. Jaffe N, Robertson R, Ayala A, Wallace S, Chuang V, Anzai T, *et al.* Comparison of intra-arterial cis-diamminedichloroplatinum II with high-dose methotrexate and citrovorum factor rescue in the treatment of primary osteosarcoma. *J Clin Oncol* 1985;3:1101-4.
7. King ME, Pfeifle CE, Howell SB. Intraperitoneal cytosine arabinoside therapy in ovarian carcinoma. *J Clin Oncol* 1984;2:662-9.
8. Breslow NE, Langholz B. Childhood cancer incidence: Geographical and temporal variations. *Int J Cancer* 1983;32:703-16.
9. Green DM, Jaffe N. Wilms' tumor—Model of a curable pediatric malignant solid tumor. *Cancer Treat Rev* 1978;5:143-72.
10. Macmahon HE, Bedizel M, Ellis CA. Vincristine (leurocristine) sulfate in the treatment of children with metastatic Wilms' tumor. Pediatric division, Southwest cancer chemotherapy group. *Pediatrics* 1963;32:880-7.
11. Tagge EP, Thomas PB, Othersen HB Jr. Wilms' tumor. In: Grosfeld JL, O'Neill JA Jr, Fonkalsrud EW, Coran AG, editors. *Pediatric Surgery*. 6th ed. Philadelphia PA: Mosby Elsevier; 2006. p. 445-66.
12. Veal GJ, Cole M, Errington J, Parry A, Hale J, Pearson AD, *et al.* Pharmacokinetics of dactinomycin in a pediatric patient population: A United Kingdom Children's Cancer Study Group Study. *Clin Cancer Res* 2005;11:5893-9.
13. Groninger E, Meeuwssen-de Boar T, Koopmans P, Uges D, Sluiter W, Veerman A, *et al.* Pharmacokinetics of vincristine monotherapy in childhood acute lymphoblastic leukemia. *Pediatr Res* 2002;52:113-8.
14. Greene RF, Collins JM, Jenkins JF, Speyer JL, Myers CE. Plasma pharmacokinetics of adriamycin and adriamycinol: Implications for the design of *in vitro* experiments and treatment protocols. *Cancer Res* 1983;43:3417-21.
15. Apte AV, Kumar V, Sharma SP, Arya NC, Gangopadhyay AN, Gupta DK, *et al.* How safe and effective is preoperative intratumoral chemotherapy in advanced Inoperable pediatric solid malignancies? *J Indian Assoc Pediatr Surg* 2001;6:119-24.
16. Tournade MF, Com-Nougué C, Voûte PA, Lemerle J, de Kraker J, Delemarre JF, *et al.* Results of the Sixth International Society of Pediatric Oncology Wilms' Tumor Trial and Study: A risk-adapted therapeutic approach in Wilms' tumor. *J Clin Oncol* 1993;11:1014-23.
17. Godzinski J, Tournade MF, De Kraker J, Ludwig R, Weirich A, Voute PA, *et al.* The role of preoperative chemotherapy in the treatment of nephroblastoma: The SIOP experience. *Societe Internationale d'Oncologie Pediatrique. Semin Urol Oncol* 1999;17:28-32.
18. Kogan SJ, Marans H, Santorineau M, Schneider K, Reda E, Levitt SB. Successful treatment of renal vein and vena caval extension of nephroblastoma by preoperative chemotherapy. *J Urol* 1986;136:312-7.
19. Bray GL, Pendergrass TW, Schaller RT Jr, Kiviat N, Beckwith JB. Preoperative chemotherapy in the treatment of Wilms' tumor diagnosed with the aid of fine needle aspiration biopsy. *Am J Pediatr Hematol Oncol* 1986;8:75-8.
20. Ritchey ML, Pringle KC, Breslow NE, Takashima J, Moksness J, Zuppan CW, *et al.* Management and outcome of inoperable Wilms tumor. A report of National Wilms Tumor Study-3. *Ann Surg* 1994;220:683-90.
21. Goldberg EP, Hadba AR, Almond BA, Marotta JS. Intratumoral cancer chemotherapy and immunotherapy: Opportunities for nonsystemic preoperative drug delivery. *J Pharm Pharmacol* 2002;54:159-80.
22. Gangopadhyay AN, Rajeev R, Sharma SP, Upadhyaya VD, Arya NC, Kumar V, *et al.* Anterior intratumoural chemotherapy: A newer modality of treatment in advanced solid tumours in children. *Asian J Surg* 2008;31:225-9.

How to cite this article: Kumar V, Ramaswami N, Pandey A, Shukla RC, Sen MR, Sharma SP, *et al.* Clinico-immunological response to intratumoral versus intravenous neoadjuvant chemotherapy in advanced pediatric solid malignancies. *Indian J Med Paediatr Oncol* 2013;34:80-4.

Source of Support: Nil, **Conflict of Interest:** None declared.