



Puerarin reduces impairment of intestinal and adipose immune responses to influenza virus infection in mice

Mao-Seng Zeng¹ · Wen-Di Yu¹ · Hui-Xian Wang¹ · Pei-Ping Xu¹ · Jin-Yuan Liu²

Received: 14 January 2021 / Accepted: 5 April 2021 / Published online: 10 June 2021
© The Author(s), under exclusive licence to Springer-Verlag GmbH Austria, part of Springer Nature 2021

Abstract

Influenza is an acute viral respiratory disease that can also cause gastroenteritis-like symptoms, such as abdominal pain, nausea, vomiting, and diarrhea. Immune dysfunction of adipose tissue is involved in the occurrence and prognosis of influenza viral pneumonia. In this study, we analyzed intestinal and adipose immune responses in mice infected with influenza virus and found that the impairment of intestinal and adipose immunity to influenza virus infection could be reversed by treatment with puerarin, a medicinal compound isolated from *Pueraria lobata* (called “gegen” in Chinese). We found that the lungs, small intestines (duodenum, ileum, jejunum) and large intestines (colon and rectum) of infected mice showed obvious inflammatory lesions, with significantly increased levels of virus, inflammatory cytokines (interleukin [IL]-6, IL-17, and tumor necrosis factor- α), Toll-like receptors 3, 4, and 9, and integrin $\alpha\beta$ 3 and α 4, and a decreased level of secreted IgA compared to the normal control group (NC) ($P < 0.05$ – 0.001). Influenza virus infected mesenteric lymph nodes and adipose tissue, and adipokines (leptin, visfatin, “chemerin”, and adiponectin) of lung and mesenteric adipose tissue were dysregulated. Puerarin treatment reversed the impairment of the intestinal and adipose immune responses in mice infected with influenza virus. Our findings suggest that influenza virus can infect adipose tissue and lead to intestinal adipose immune dysfunction in normal-weight mice and that the impairment of the intestinal and adipose immune response to influenza virus infection can be reversed by puerarin treatment.

Introduction

Influenza is an acute respiratory disease caused by influenza A virus (IAV), with symptoms of fever, headache, stuffy nose, and sore throat [1]. In addition to these typical symptoms, it can also cause abdominal pain, diarrhea, nausea, vomiting, and other symptoms similar to gastroenteritis [2, 3]. Studies have shown that IAV (e.g., H1N1, H7N2, and H5N1) infection can cause immune damage involving the

small and large intestines, which indicates that influenza virus infection can spread to tissues and organs outside the respiratory tract [4]. Influenza virus infection can cause structural damage to the small intestine [2].

Immune function disorder of adipose tissue in obese patients affects their antiviral immunity. During the 2009 H1N1 pandemic, obesity was considered an independent risk factor for the increase in incidence and mortality of influenza [5]. Obese patients were most likely to be infected with IAV (71.0%) and were at high risk of severe cases of influenza [6]. There is an accumulation of inflammatory cells and overexpression of cytokines in adipose tissue, which can participate in the inflammatory response to influenza by releasing inflammatory factors [7]. It can be seen that immune dysfunction of adipose tissue is involved in the occurrence and prognosis of influenza viral pneumonia. However, the underlying mechanism of these clinical manifestations in the gut during infection is not known. In this study, we analyzed the intestinal and adipose immune responses in mice infected with IAV.

We discovered that influenza virus can infect mesenteric lymph nodes (MLNs) and adipose tissue of mice and that

Handling Editor: Ayato Takada.

✉ Pei-Ping Xu
xupei ping@gzucm.edu.cn

✉ Jin-Yuan Liu
cszxb@gzucm.edu.cn

¹ Institute of Tropical Medicine, Guangzhou University of Chinese Medicine, 12 Jichang Rd., San Yuanli St., Bai Yun Dist., Guangzhou 510405, Guangdong, People's Republic of China

² Basic Medical College, Guangzhou University of Chinese Medicine, 12 Jichang Rd., San Yuanli St., Bai Yun Dist., Guangzhou 510405, Guangdong, People's Republic of China

adipokines (leptin, visfatin, “chemerin”, and adiponectin) of lung and mesenteric adipose tissue are dysregulated. The impairment of the intestinal and adipose immune responses in mice infected with IAV could be reversed by treatment with puerarin, a medicinal compound isolated from *Pueraria lobata* (called “gegen” in Chinese) that is used to treat fever, cough, cold, and other diseases in China [8].

Materials and methods

Viruses and animals

Influenza virus strain A/FM/1/47(H1N1) was maintained as described previously [9]. Four-week-old BALB/c mice, half male and half female, weighing 13–15 g, were purchased from Guangdong Medical Experimental Animal Center (Guangzhou, China). The dose of IAV used for infection was selected based on previous studies [9]. Except for the normal control group, mice were infected intranasally with 50 μ L of a virus suspension containing 15 times the median lethal dose (MLD₅₀) of IAV. In the experiments, 3% pentobarbital (10 ml/kg body weight) was used to anesthetize mice for euthanasia, and the virus inoculation was performed under ether inhalation anesthesia. The study was approved by the Animal Care and Use Committee of Guangzhou University of Chinese Medicine (Guangzhou, China). Humane endpoints for euthanasia were chosen for the experimental animals (e.g., in the survival study), and the use of anesthesia was in compliance with the Regulations for the Administration of Affairs Concerning Experimental Animals of Guangdong Province (2010, no. 41).

Compounds

Puerarin was purchased from Shanghai Yuanye Biotechnology Co. (batch number: S02M9B54875, Shanghai, China). Puerarin was dissolved in 0.5% Tween 80 and diluted to the required concentration.

In vivo experiments

Mice were divided into three groups, with 10 in each group: the normal control group (NC), the IAV control group (IAV-C), and the puerarin group (IAV + puerarin [100 mg/kg]). The dose of influenza virus was as described above [10]. Puerarin was administered orally 4 hours after infection “and daily” for 5 days. On the sixth day after infection, the mice were killed and tissue samples were collected.

Lung index

The lung index was calculated as described previously [11]: Lung index = $A/B \times 100$, where A is the lung weight and B is the body weight.

Histological analysis

The lung, duodenum, ileum, jejunum, colon, rectum, MLN, and mesenteric fat were quickly removed, washed with 10% PBS buffer, dehydrated with formaldehyde and graded ethanol, and embedded in paraffin. The lungs were cut into 5- μ m pieces and stained with hematoxylin and eosin (H&E). As described previously [12], the histopathological score was determined in a blinded manner to determine the degree of pulmonary inflammation.

Analysis of viral load

Quantitative polymerase chain reaction (qPCR) was used to determine the viral load in the lung, duodenum, ileum, jejunum, colon, rectum, MLN, and mesenteric fat. The mRNA expression level of the H1N1 M gene was determined by qT-PCR as described previously (??REFERENCE??). Relative quantitation of PCR products was done by the $2^{-\Delta\Delta CT}$ method.

Secreted IgA in mucosal washes from IAV-infected mice

On the sixth day postinfection, mice were killed to collect samples (intestinal and bronchoalveolar washes) and to measure the level of secreted IgA (sIgA). The total IgA in serum and intestinal, nasal, and bronchoalveolar lavage fluid were determined by enzyme-linked immunosorbent assay (ELISA) using a Mouse IgA ELISA Kit (Shanghai Enzyme-linked Biotechnology Co., Ltd. Shanghai, China). The ELISA was performed essentially according to the manufacturer’s instructions. Samples were tested at a dilution of 1:10² for bronchoalveolar washings and 1:10⁶ for gut washings. The optical density at 450 nm was read by an ELISA plate reader (model ELx800, Bio-Tek Instruments, Inc., Winooski, VT). The standard curve for IgA determination was made using purified mouse IgA.

Cytokines in lung and intestinal tissue in IAV-infected mice

The concentrations of interleukin (IL)-6, IL-17, tumor necrosis factor (TNF)- α and interferon (IFN)- γ in lung

and intestinal tissue homogenate were measured using a Mouse ELISA Kit (Shanghai Enzyme-linked Biotechnology Co., Ltd.) according to the manufacturer's instructions.

Adipokines in lung and mesenteric fat tissue of IAV-infected mice

The concentrations of leptin, adiponectin, "chemerin" and visfatin in lung and mesenteric fat homogenate were measured using a Mouse ELISA Kit (Shanghai Enzyme-linked Biotechnology Co., Ltd.) according to the manufacturer's instructions.

Assessment of immune function in lungs and intestinal mucosa

Lung and mesenteric fat were collected, and the levels of Toll-like receptor (TLR 3, 4, and 9) and integrin ($\alpha V\beta 3$, $\alpha 4$) were determined using a Mouse ELISA Kit (Shanghai Enzyme-linked Biotechnology Co., Ltd., Shanghai, China) according to the manufacturer's instructions.

Statistical analysis

PASW (Windows, ver.18.0, SPSS, Chicago, IL, USA) was used for statistical analysis. The data were expressed as the mean \pm SD. One-way analysis of variance (ANOVA) and the least significant difference test were used to compare differences among the groups. $P < 0.05$ indicates statistical significance.

Results

Changes in lung inflammation in IAV-infected mice

Most of the infected mice developed disease three days after infection, with clinical signs including dull, ruffled fur, reduced activity and food intake, weight loss, rapid breathing, and loose stools. In the NC group, the lung tissue structure was normal, and no inflammatory lesions were found (Fig. 1A, D, and E). The lung tissue in the IAV-C group showed different degrees of inflammatory lesions, such as inflammatory cell infiltration, bronchiolitis with edema, and perivascular interstitial edema. The lung index in the IAV-C group was significantly higher than that in the NC group ($p < 0.01$) (Fig. 1B, D, and E). Compared to the IAV-C group,

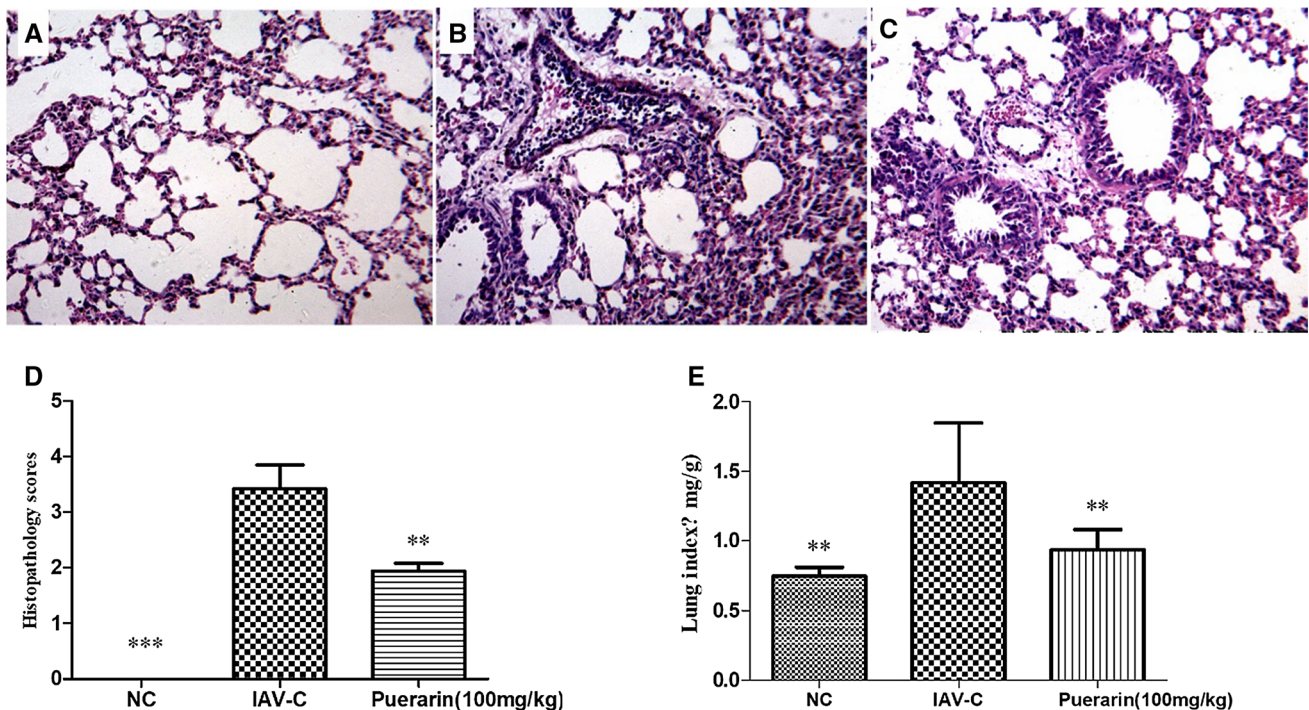


Fig. 1 Pathological changes of lungs in IAV-infected mice at day 6 after infection (HE, $\times 100$; $n = 6-10$). (A) Pathological changes in the NC group. (B) Pathological changes in the IAV-C group. (C) Pathological changes in the puerarin group. (D) Pathological scores: 0, no pneumonia; 1, mild interstitial pneumonia (<25 % of the lung);

2, moderate interstitial pneumonia (25-50% of the lung); 3, severe interstitial pneumonia (50-75% of the lung); 4, very severe interstitial pneumonia (>75% of the lung). (E) Lung index. Data are presented as the mean \pm SD. Asterisks denote the significance level: **, $p < 0.01$; ***, $p < 0.001$, compared with the IAV-C group

mice in the puerarin group had significantly less inflammatory pathology in the lung and a lower lung index ($p < 0.01$) (Fig. 1C-E).

Pathological changes in the intestinal tract of IAV-infected mice

HE staining showed that inflammatory lesions were present in the small and large intestines of IAV-infected mice, especially in the ileum and colon (Fig. 2, IAV-C). Compared with the NC group, there were different degrees of inflammatory lesions in the duodenum, jejunum, ileum, colon, and rectum in the virus-infected group, especially in the jejunum, ileum, and colon (Fig. 2, NC and IAV-C). The local mucosal epithelial cells of the duodenum were necrotic and exfoliated, intestinal villi were destroyed, inflammatory cell infiltration was seen in the mucosal layer, no obvious atrophy was found in the glands in the lamina propria, inflammatory cell infiltration was seen, and some edema was found in the submucosa (Fig. 2, IAV-C, duodenum). The local mucosal epithelial cells of the jejunum were necrotic, and the glands in the lamina propria disappeared and were replaced by new connective tissue. Inflammatory cell infiltration was obvious, the submucosal structure was loose, and edema was present (Fig. 2, IAV-C, jejunum). The mucosal epithelial cells of the ileum were necrotic and exfoliated, with local mucosal defects, and the glands in the lamina propria disappeared and were replaced by connective tissue (Fig. 2, IAV-C, ileum). Inflammatory cell infiltration was seen in the submucosa. Some of the colonic mucosal epithelial cells were necrotic and exfoliated, with the local mucosal epithelial layer defective, lamina propria glands missing, the missing mucosal epithelial cells replaced by new connective tissue, and inflammatory cell infiltration in the new tissue (Fig. 2, IAV-C, colon). Local villous epithelial cells of the rectal mucosa were necrotic and exfoliated, mucosal structure was

destroyed, inflammatory cell infiltration was visible in the mucosal layer, the gland structure of the lamina propria was damaged, the submucosal structure was loose, and there was some edema (Fig. 2, IAV-C, rectum). Influenza virus infection can lead to inflammation of mesenteric adipose tissue in mice. The MLNs were significantly enlarged, and the germinal center was obvious (Fig. 2, IAV-C, mesenteric lymph nodes). In the germinal center, there was proliferation of lymphoblasts and some thickening of the cap-like area. Some atrophy of adipose tissue was observed in mesenteric fat, with a decrease in the number of adipocytes, and a large number of inflammatory cells infiltrated around the fat (Fig. 2, IAV-C, mesenteric adipose tissue). The inflammatory lesions in the puerarin group were lighter than those in the IAV-C group, especially in the ileum and colon (Fig. 2, IAV-C, puerarin).

Changes in viral load in the lung and intestine of IAV-infected mice

Six days after the mice were infected with influenza virus, viral RNA was found in the lung, duodenum, jejunum, ileum, colon, rectum, MLNs, and mesenteric adipose tissue in the IAV-C group. The amount of viral RNA was significantly higher than in the NC group (Fig. 3A-H). Compared with the IAV-C group, the pulmonary enterovirus titer in the puerarin group was significantly lower ($P < 0.01$) (Fig. 3A-H).

Changes in inflammatory cytokine levels in the lung and intestine of IAV-infected mice

On the sixth day of influenza virus infection, the levels of inflammatory cytokines TNF- α , IL-6, and IL-17 in the lung, duodenum, jejunum, ileum, and rectum in the IAV-C group were significantly increased (Fig. 4B-D), and the levels

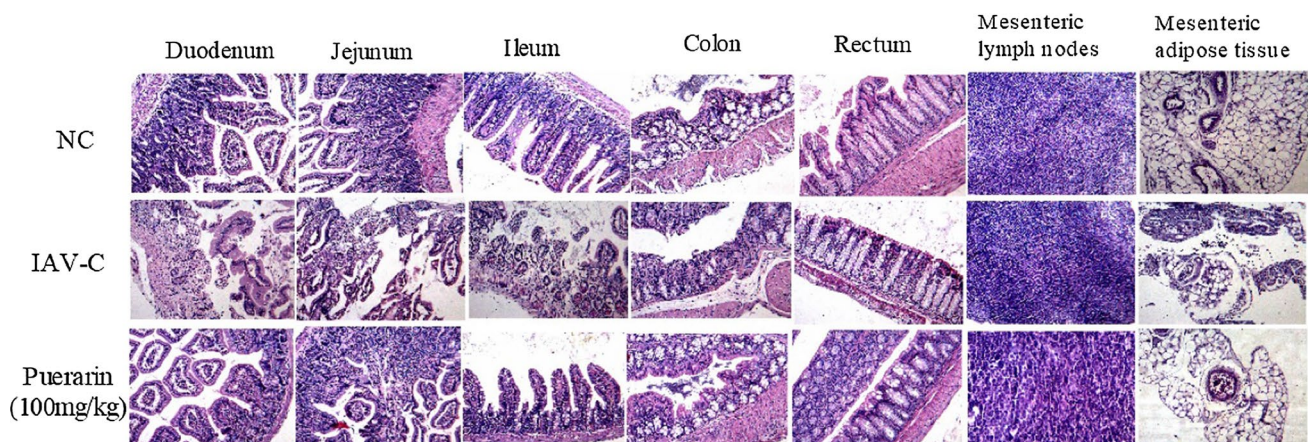


Fig. 2 Pathological changes of intestine in IAV-infected mice virus at day 6 after infection (n = 6–10) (HE, $\times 100$)

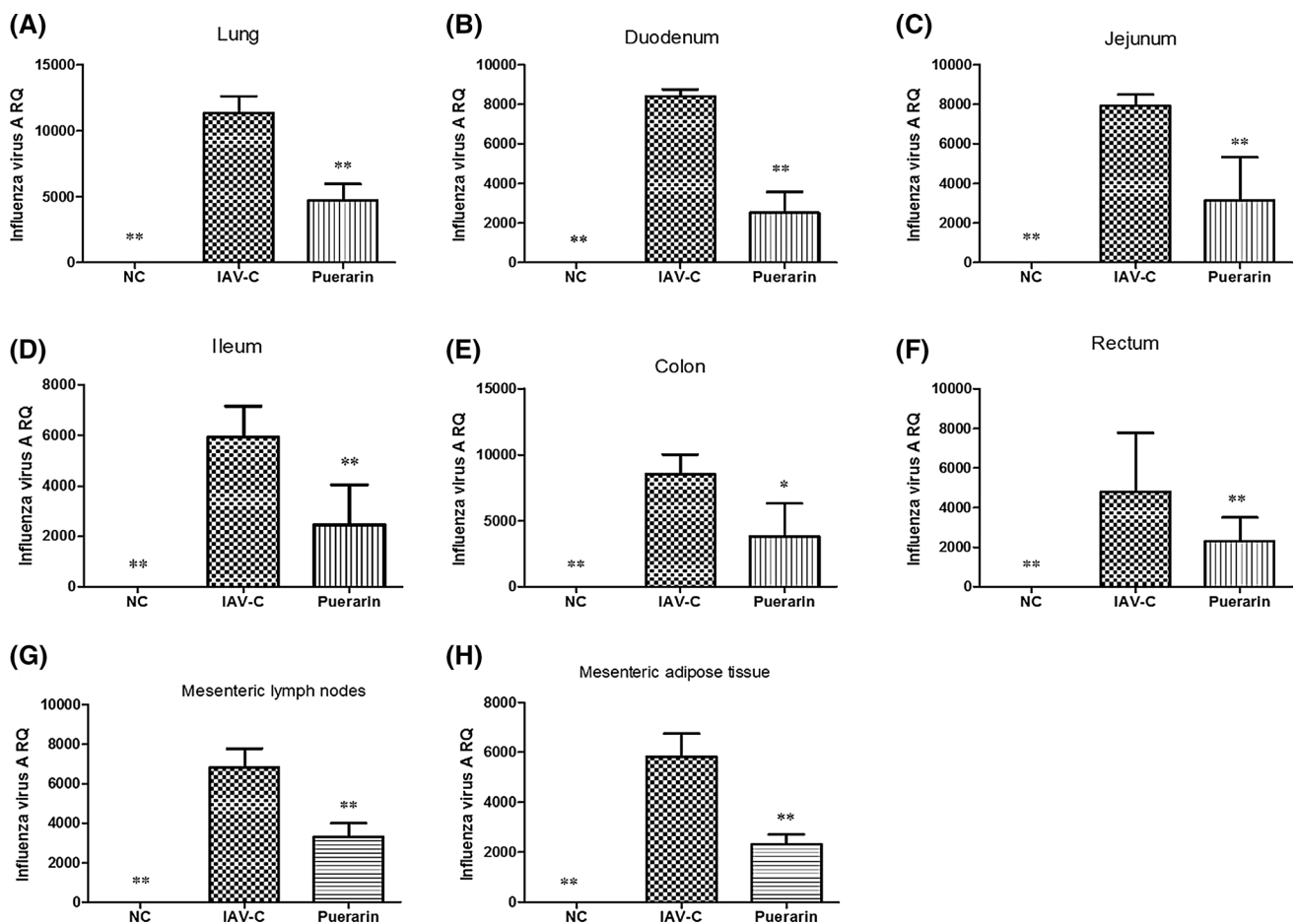


Fig. 3 Changes in the viral RNA level after intranasal infection of influenza virus in mice ($n = 6-10$) in the (A) lung, (B) duodenum, (C) jejunum, (D) ileum, (E) colon, (F) rectum, (G) MLNs, (H) mes-

enteric adipose tissue. Data are presented as the mean \pm SD. Asterisks denote the significance level: *, $p < 0.05$; **, $p < 0.01$, compared with the IAV-C group

of TNF- α and IL-6 in the colon were significantly higher than in the NC group (Fig. 4B and D). Puerarin treatment significantly reduced the above-mentioned tissue cytokine levels (Fig. 4B-D). The level of IFN- γ was not significantly increased in the lung and intestine tissues, and there was no significant difference between the IAV-C group and puerarin group (Fig. 4A).

Changes of adipokines in lung and intestine of IAV-infected mice

The levels of leptin, visfatin, and “chemerin” in lung, mesenteric lymph node, and mesenteric adipose tissue in the IAV-C group were significantly higher than those in the NC group ($P < 0.05-0.001$) (Figs. 5, 6, 7). Puerarin treatment significantly reduced the levels of leptin, “visfatin”, and “chemerin”, and increased the level of adiponectin ($P < 0.01$) (Figs. 5, 6, 7, 8). The analysis showed that the adiponectin levels in lung, mesenteric lymph node, and mesenteric adipose tissue decreased significantly after 5 days

of infection compared to the NC group (Fig. 8). Puerarin (100 mg/kg) inhibited the “decrease” of adiponectin in lung, mesenteric lymph node, and mesenteric adipose tissue (Fig. 8A-C, $p < 0.05-0.01$).

Changes in SIgA levels in lungs and intestines of IAV-infected mice

The mucosal immune response was evaluated to determine the effects of puerarin. IgA levels in bronchoalveolar lavage and intestinal lavage fluids were measured on the sixth day postinfection. The sIgA levels in bronchoalveolar lavage fluid and small intestinal lavage fluid were significantly lower in the IAV-C group than in the NC group ($P < 0.01-0.001$) (Fig. 9). The levels of sIgA in the bronchoalveolar lavage fluid and small intestinal lavage fluid of the puerarin group were significantly higher than in the IAV-C group (Fig. 9A-B).

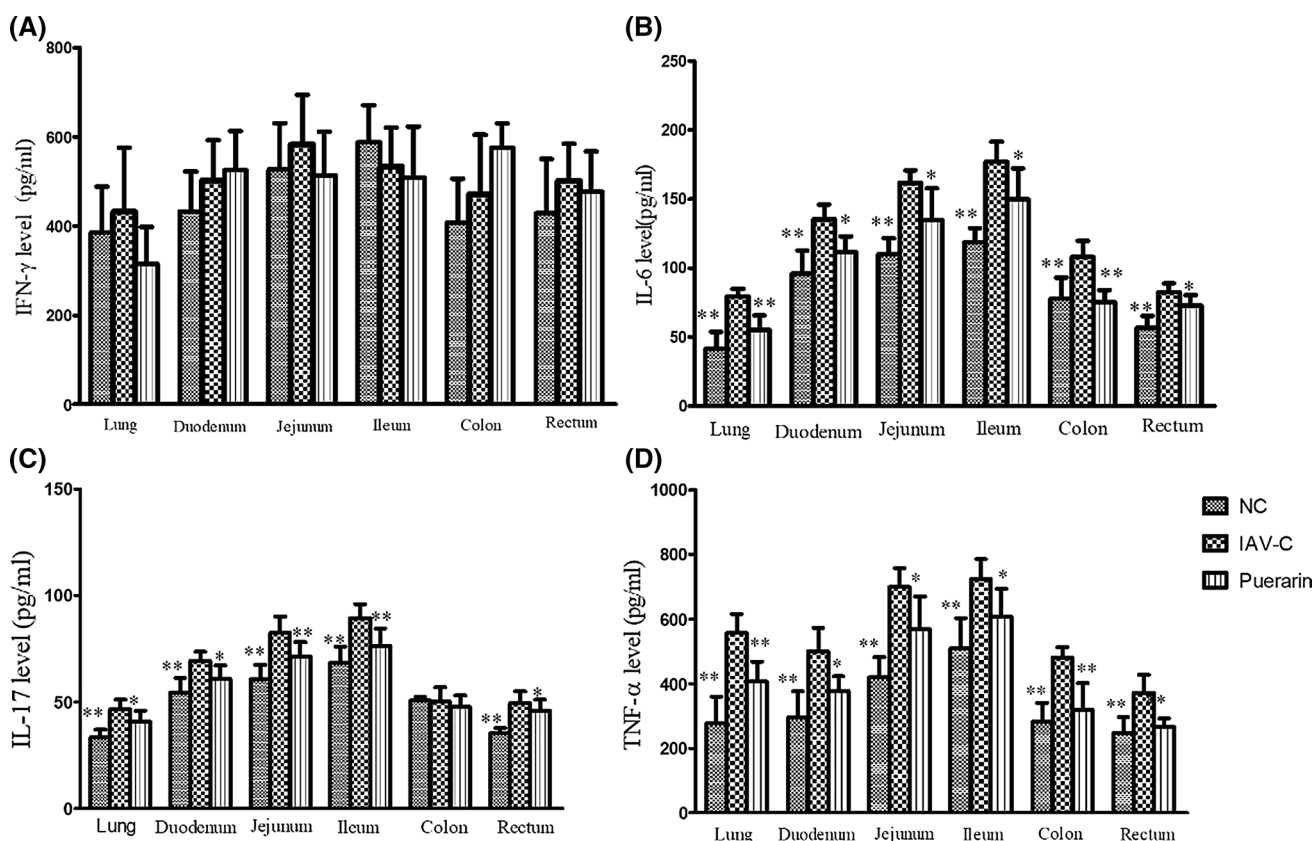


Fig. 4 Changes in inflammatory cytokine levels in the lung and intestine of IAV-infected mice ($n = 10$). Proinflammatory cytokine levels were analyzed by ELISA on day 6 after infection. (A) IFN-gamma.

(B) IL-6. (C) IL-17. (D) TNF-alpha. Data are presented as the mean \pm SD. Asterisks denote the significance level: *, $p < 0.05$; **, $p < 0.01$, compared with the IAV-C group

Changes in mucosal immune function in IAV-infected mice

On the sixth day after influenza virus infection, the levels of TLR 3, 4, and 9 and integrin ($\alpha V\beta 3$, $\alpha 4$) in the lung, duodenum, jejunum, ileum, colon, and rectum of the IAV-C group were significantly higher than in the NC group ($P < 0.05-0.001$, Fig. 10A-E). Puerarin treatment significantly increased the levels of TLRs and integrin in the above tissues ($P < 0.05-0.001$, Fig. 10 A-E).

Discussion

Influenza patients often have diarrhea, nausea, and other extra-respiratory clinical manifestations [13]. The lungs and large intestine are not only related physiologically but also affect each other pathologically. Diseases of the lungs and intestines can be transmitted to each other and even form a vicious circle. In this study, we found that influenza virus caused inflammatory lesions not only in the lungs but also in the small intestine (duodenum, jejunum, and ileum), large intestine (colon and rectum), MLNs, and mesenteric adipose

tissue, especially in the ileum and colon. Influenza-virus-infected mice exhibited anorexia, emaciation, and loose stools. Treatment with puerarin inhibited the inflammatory changes in IAV-infected mice and improved the immune function of the lungs, intestines, and adipose tissue.

Puerarin is a medicinal compound isolated from *Pueraria lobata* (called "gegen" in Chinese), which has been used as a source of food and medicine in China [14]. Puerarin has been used to treat fever, cold, cough, and flu [8, 15], and it has been shown to inhibit the NA activity of influenza virus *in vivo* and *in vitro* [10].

In this study, puerarin was found to significantly reduce inflammatory pathology of the lung and decrease the lung index. In a previous study, we showed that puerarin exhibits a protective effect against lethal influenza virus infection (up to about 70% protection) [16].

Gastrointestinal symptoms, such as diarrhea and nausea, usually occur in IAV-infected patients [17]. In this study, anorexia, emaciation, loose stools, and other gastrointestinal symptoms were observed in mice infected with influenza virus. In addition to lung inflammation, influenza virus caused inflammatory lesions in the small intestine (duodenum, jejunum, ileum) and large intestine (colon, rectum),

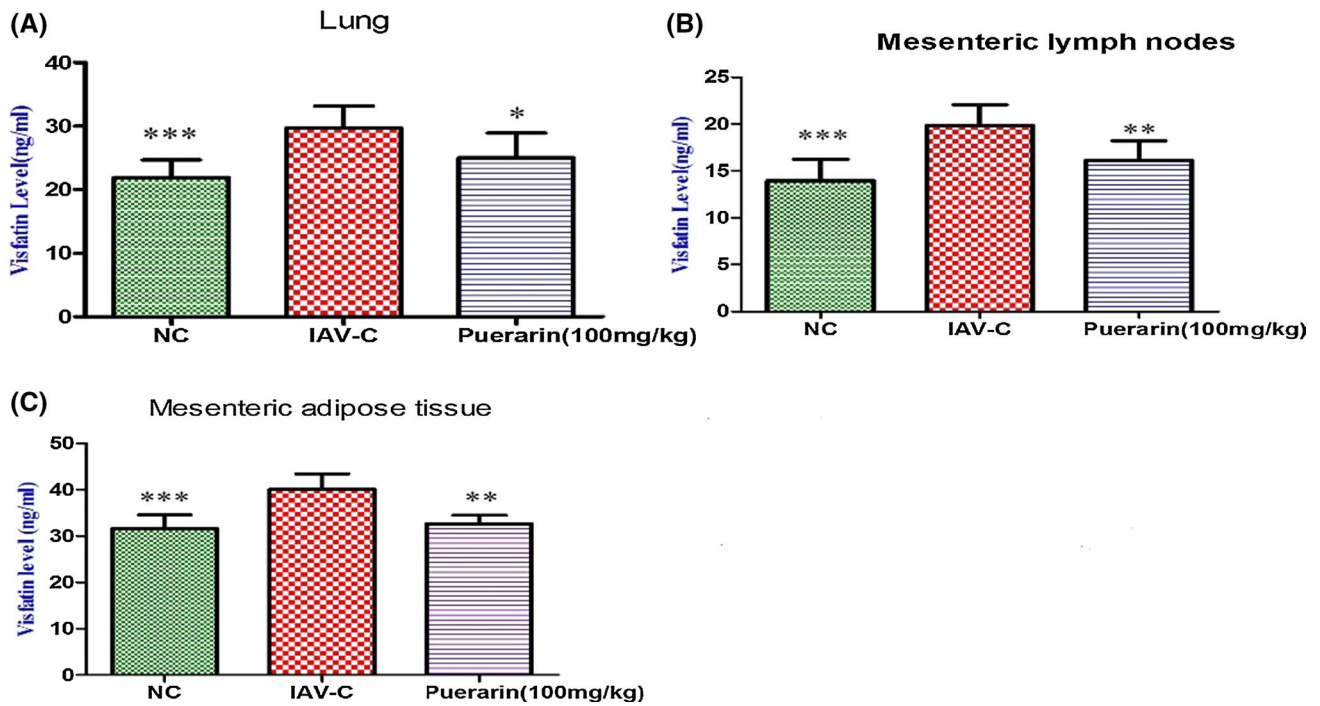


Fig. 5 Changes in visfatin levels in the lungs and intestines of IAV-infected mice ($n = 10$). Visfatin levels were analyzed by ELISA on day 6 after infection. (A) Visfatin in lungs. (B) Visfatin in MLNs. (C)

Visfatin in mesenteric adipose tissue. Data are presented as the mean \pm SD. Asterisks denote the significance level: *, $p < 0.05$; **, $p < 0.01$; ***, $p < 0.001$, compared with the IAV-C group

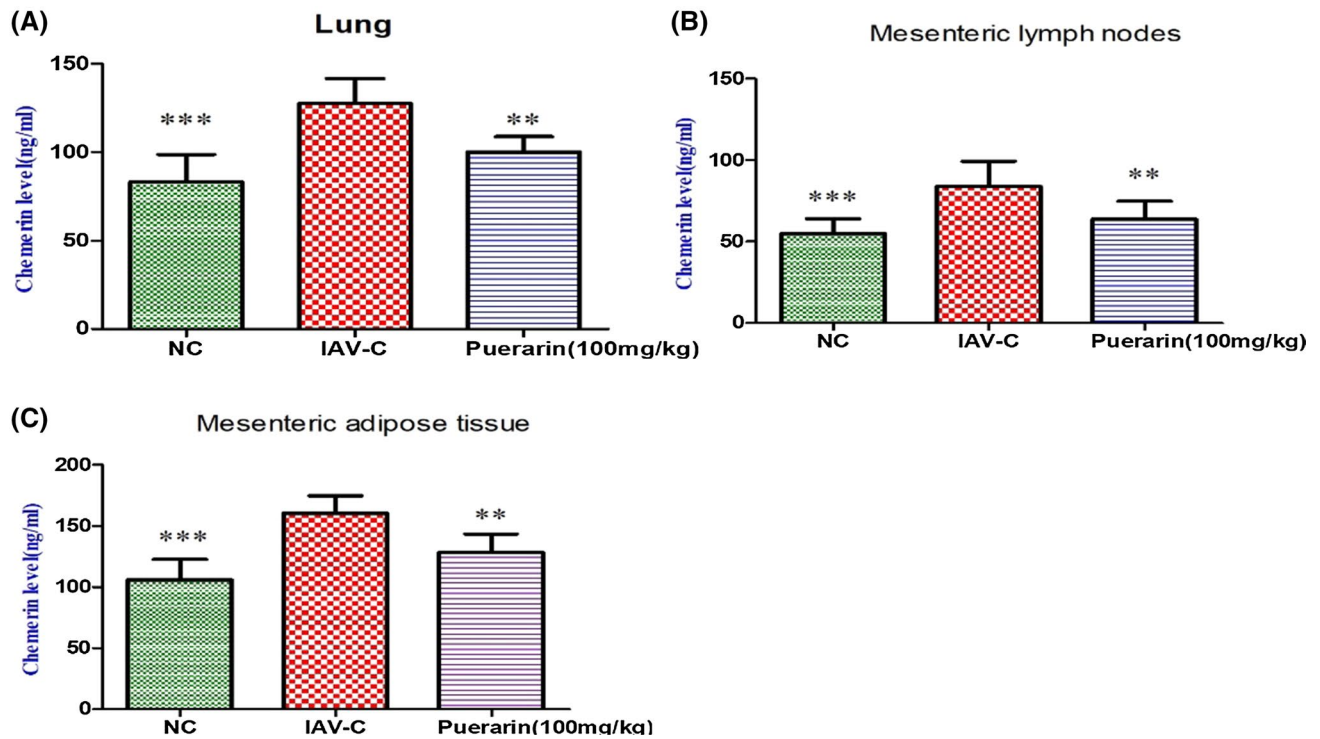


Fig. 6 Changes in chemerin levels in the lungs and intestines of IAV-infected mice ($n = 10$). Chemerin levels were analyzed by ELISA on day 6 after infection. (A) Chemerin in lungs. (B) Chemerin in MLNs.

(C) Chemerin in mesenteric adipose tissue. Data are presented as the mean \pm SD. Asterisks denote the significance level: **, $p < 0.01$; ***, $p < 0.001$, compared with the IAV-C group

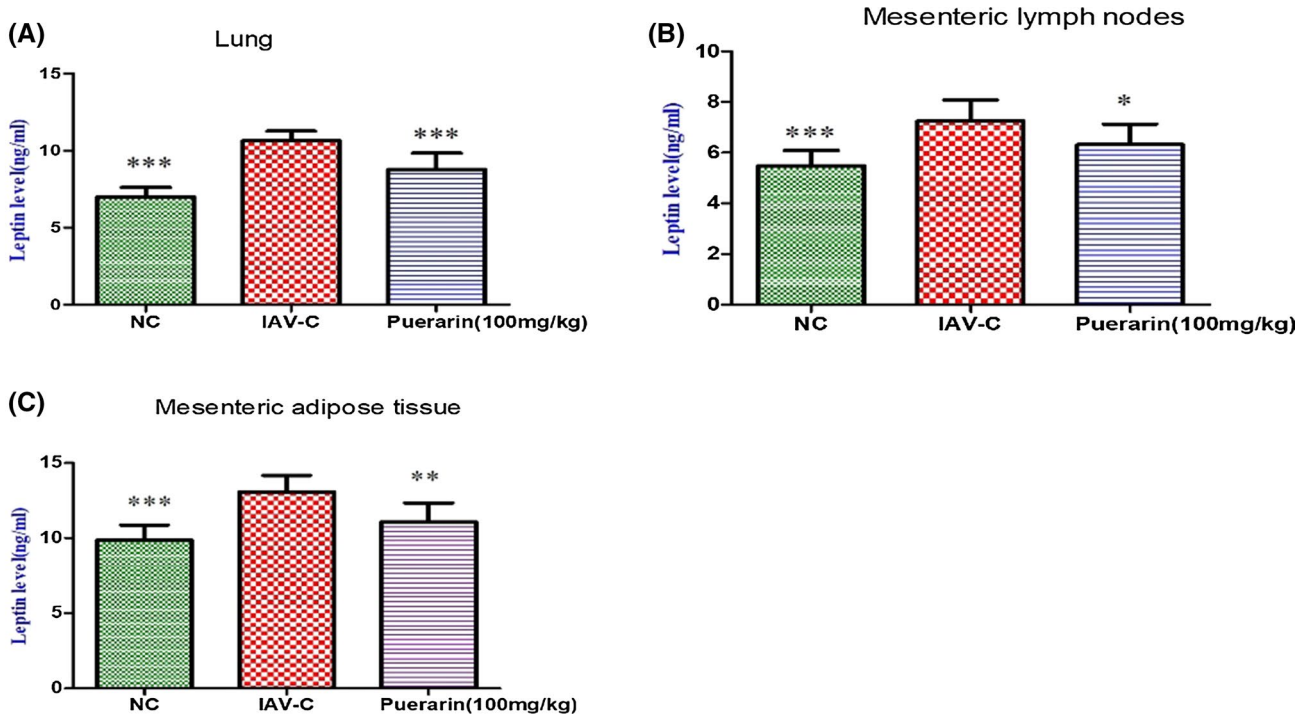


Fig. 7 Changes in leptin levels in the lungs and intestines of IAV-infected mice ($n = 10$). Leptin levels were analyzed by ELISA on day 6 after infection. (A) Leptin in lungs. (B) Leptin in MLNs. (C) Lep-

tin in mesenteric adipose tissue. Data are presented as the mean \pm SD. Asterisks denote the significance level: *, $p < 0.05$; **, $p < 0.01$; ***, $p < 0.001$, compared with the IAV-C group

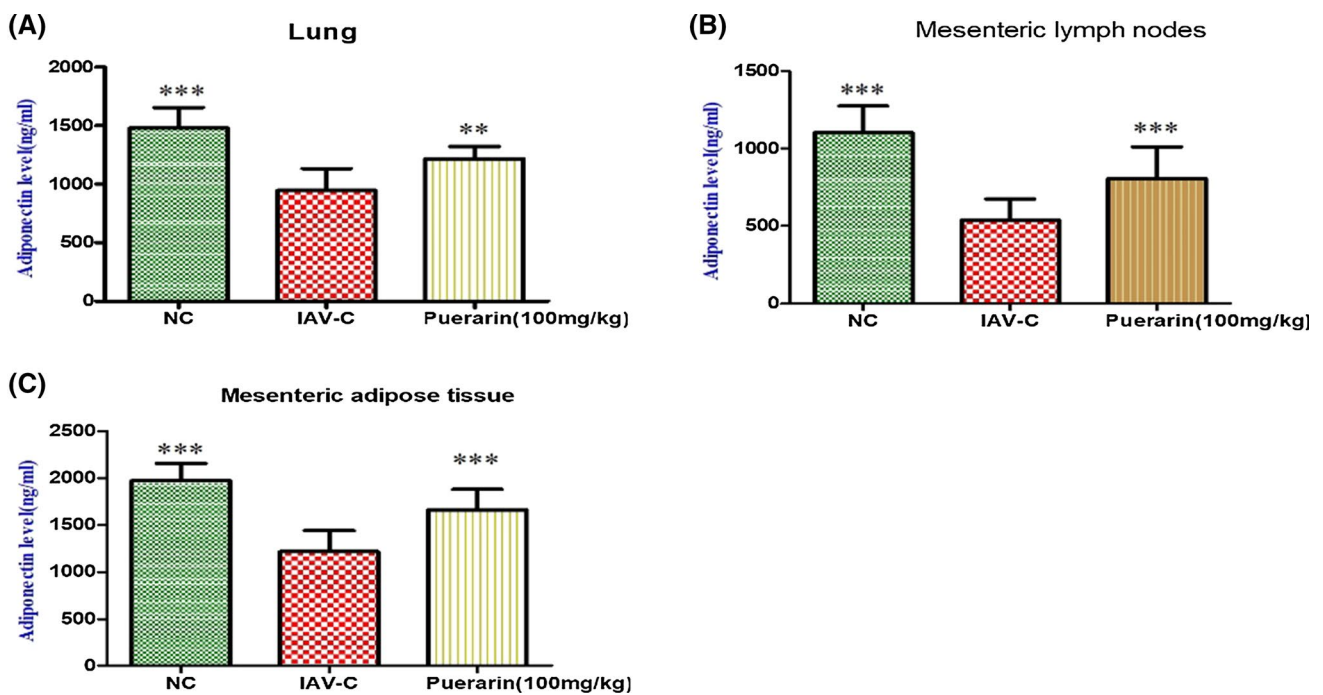


Fig. 8 Changes in adiponectin levels in the lungs and intestines of IAV-infected mice ($n = 10$). Adiponectin levels were analyzed on by ELISA day 6 after infection. (A) Adiponectin in lungs. (B) Adiponec-

tin in MLNs. (C) Adiponectin in mesenteric adipose tissue. Data are presented as the mean \pm SD. Asterisks denote the significance level: **, $p < 0.01$; ***, $p < 0.001$, compared with the IAV-C group

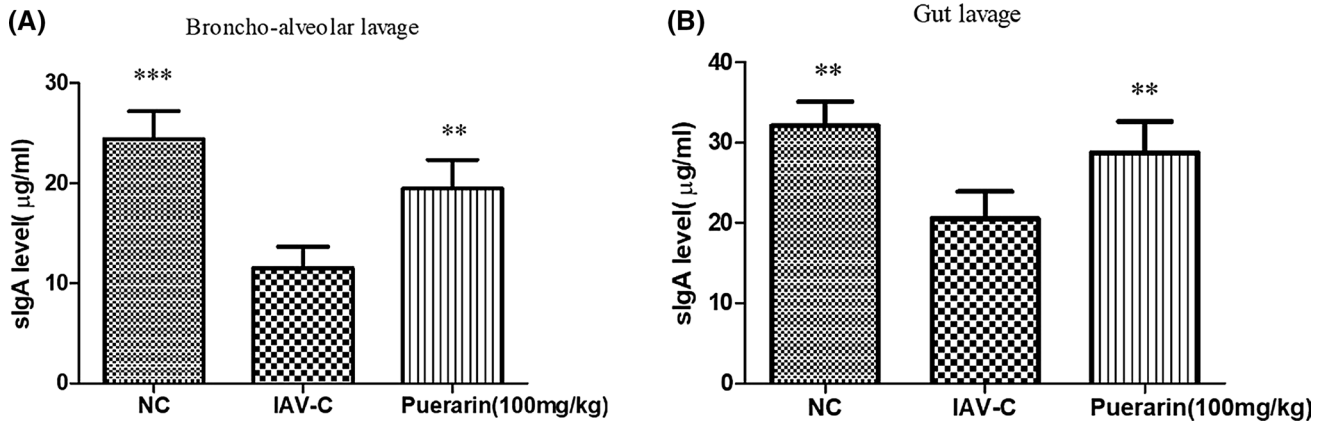


Fig. 9 IgA levels in bronchoalveolar lavage and intestinal lavage fluids ($n = 10$). The samples were collected before infection and on the sixth day postinfection. ELISA was used to determine mucosal IgA antibody levels in bronchoalveolar lavage (A) and gut lavage (B).

Data are presented as the mean \pm SD. Asterisks denote the significance level: **, $p < 0.01$; ***, $p < 0.001$, compared with the IAV-C group

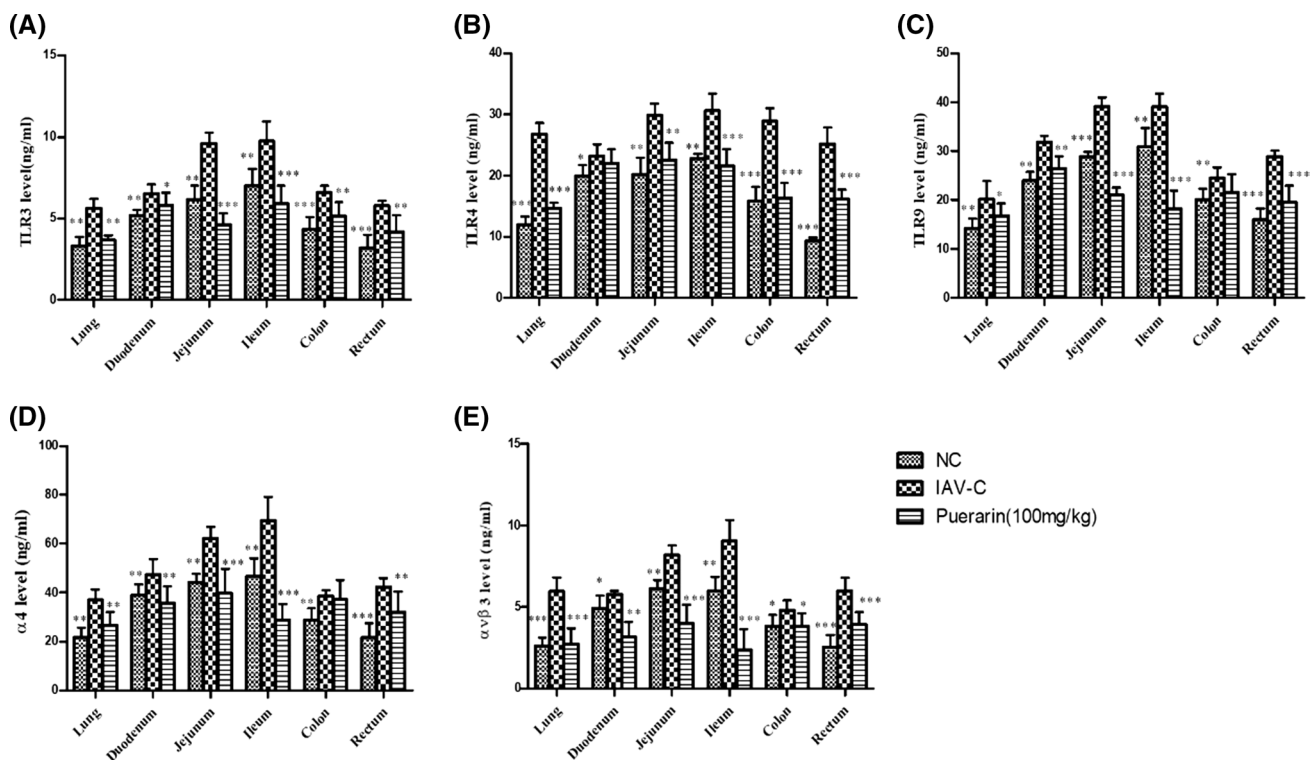


Fig. 10 Changes in mucosal immune function of lungs and intestines of IAV-infected mice ($n = 10$). (A) TLR3. (B) TLR4. (C) TLR9. (D) $\alpha 4$. (E) $\alpha v \beta 3$. Data are presented as the mean \pm SD. Asterisks denote

the significance level: *, $p < 0.05$; **, $p < 0.01$; ***, $p < 0.001$, compared with the IAV-C group

especially in the ileum and colon. In addition, the level of IAV RNA was significantly increased in both the small intestine and large intestine, indicating that influenza virus can infect intestinal tissue.

Influenza virus often causes viral pneumonia through respiratory tract mucosal infection. The intestinal and

bronchopulmonary lymphoid tissues are important components of the mucosal immune system. sIgA is the main immune molecule of the mucosal immune system that resists invasion by foreign pathogens. Influenza virus infection often leads to immunosuppression and secondary infection by bacteria, often accompanied by gastrointestinal

inflammation [4]. This study showed that influenza virus can inhibit the secretion of sIgA in bronchoalveolar lavage fluid and intestinal lavage fluid, while puerarin can increase the secretion level of sIgA in lung and intestinal mucosa. There is also an immune correlation between the lung and the large intestine. As one of the important mucosal immune activities, mucosal lymphocyte homing has directional selectivity. This selectivity of mucosal lymphocytes is related to the specific recognition of the related receptors on their surface and on the vascular endothelial cells of mucosal sites, such as integrin $\alpha4\beta3$. In this study, we found that the levels of integrin $\alpha\nu\beta3$ and $\alpha4$ in the lung and intestine tissues of IAV-infected mice increased and that the level of TNF- α in bronchoalveolar lavage fluid and intestinal lavage fluid also increased. Inflammation-related injury is induced by the binding of lung- and gut-associated integrin with the TNF- α receptor and directional homing migration of immune cells.

TLRs are important in the regulation of inflammatory signal transduction. TNF- α is a proinflammatory cytokine with extensive biological activity that can be produced by a variety of cells [18]. It can induce vascular endothelial cells to express adhesion molecules, promote the infiltration and activation of inflammatory cells, and stimulate the synthesis of inflammatory mediators such as platelet-activating factor, prostaglandins, and leukotrienes. In this study, the levels of TLR3, 4, and 9 in the lungs and intestines of IAV-infected mice were significantly elevated, together with increased levels of IL-6, IL-17, and TNF- α , which caused or aggravated the pathological inflammation of the lungs and intestines. Puerarin reduced the levels of TLRs and inflammatory factors in the lungs and intestines and alleviated inflammatory damage.

As a part of the intestinal immune system, intestinal fat immunity plays a major role in the pathogenesis of influenza virus pulmonary enteritis [19]. We found that influenza virus infection can cause inflammation of mesenteric adipose tissue in mice. At the same time, the levels of adipokines in lung and mesenteric adipose tissue were altered (leptin, visfatin, and “chemerin” levels increased, and the adiponectin level decreased). Puerarin can modulate adipokine dysregulation and slow down injury of the lungs and intestines. Adipose tissue, especially intestinal adipose tissue, is generally considered to be an endocrine organ. Adipocytes secrete a variety of hormones and cytokines, such as leptin, adiponectin, and resistin, and at the same time, adipose tissue is also an immune organ that plays a major regulatory role in the immune system [20]. Adipocytes can secrete TNF- α , IL-6, and other inflammatory factors, and their expression and plasma level are related to the amount of body fat [21]. Many adipokines, including leptin, adiponectin, visfatin, and resistin, not only mediate innate immune defense by activating a variety of innate immune cells but also

participate in adaptive immunity by mediating the proliferation and activation of immune cells and B lymphocytes [22]. The adipose tissue of obese patients has low-grade inflammation, and the immune function of intestinal fat may be impaired, making obese patients more likely to be infected with IAV. Obese patients with IAV infection have more severe symptoms and higher mortality. Adipose immune dysfunction is involved in the occurrence and prognosis of influenza virus pneumonia [7]. Leptin, as a proinflammatory mediator, plays a major role in innate and acquired immune responses [23]. Adiponectin is a cytokine synthesized almost entirely by adipocytes that has an anti-inflammatory effect [24]. Visfatin is produced in large quantities by adipocytes and can affect the production of pro-inflammatory (IL-6, TNF- α , and IL-1 β) and anti-inflammatory cytokines (IL-10) [25]. “Chemerin” can regulate the production of adipocytes. Through the G-protein-coupled receptor and chemokine-like receptor (CMKLR)-1 signaling pathway, with the participation of chemokine receptors, it acts on immune cells (e.g., monocytes, dendritic cells and natural killer cells) and exerts its chemotactic activity [26].

Mice infected with influenza virus have a low degree of adipose tissue inflammatory damage and immune dysfunction. When influenza virus invades the body, the inflammatory cells in the infected mice are easily activated and secrete a large number of inflammatory mediators and adipokines, which further promote the activation of inflammatory cells, gradually leading to a cascade of inflammatory factors [27]. In this study, the levels of leptin, visfatin, and “chemerin” in the lungs and intestines of IAV-infected mice were significantly increased, together with decreased levels of adiponectin, which resulted in pathological inflammation of the lungs and intestines. Puerarin can regulate the immune function disorder of adipose tissue.

In conclusion, influenza virus can infect adipose tissue and lead to intestinal adipose immune dysfunction in normal-weight mice. Impairment of the intestinal and adipose immune response to influenza virus infection in mice could be reversed by puerarin treatment. However, the specific mechanism of intestinal immune damage caused by influenza virus infection of the respiratory tract is still unclear, and further research is needed.

Acknowledgements We thank International Science Editing (Co. Clare, Ireland) for editing this manuscript. This work was partly supported by a Natural Science Foundation of China grant (81470186).

Declarations

Conflict of interest None of the authors have any financial interests or conflict of interest related to this article.

References

- Mauad T, Hajjar LA, Callegari GD, da Silva LF, Schout D, Galas FR, Alves VA, Malheiros DM, Auler JO Jr, Ferreira AF et al (2010) Lung pathology in fatal novel human influenza A (H1N1) infection. *Am J Respir Crit Care Med* 181:72–79
- Shu Y, Li CK, Li Z, Gao R, Liang Q, Zhang Y, Dong L, Zhou J, Dong J, Wang D et al (2010) Avian influenza A(H5N1) viruses can directly infect and replicate in human gut tissues. *J Infect Dis* 201:1173–1177
- Zhang S, Wei T, Tianv H, Cheng J, Xiao J, Wang M, Hu Y (2015) Small intestinal injury in mice infected with respiratory influenza A virus: evidence for virus induced gastroenteritis. *Biotech Lett* 37:1585–1592
- Wang J, Li F, Wei H, Lian ZX, Sun R, Tian Z (2014) Respiratory influenza virus infection induces intestinal immune injury via microbiota-mediated Th17 cell-dependent inflammation. *J Exp Med* 211:2397–2410
- Louie JK, Acosta M, Samuel MC, Schechter R, Vugia DJ, Harri-man K, Matyas BT (2011) A novel risk factor for a novel virus: obesity and 2009 pandemic influenza A (H1N1). *Clin Infect Dis* 52:301–312
- Dawood FS, Jain S, Finelli L, Shaw MW, Lindstrom S, Garten RJ, Gubareva LV, Xu X, Bridges CB, Uyeki TM (2009) Emergence of a novel swine-origin influenza A (H1N1) virus in humans. *N Engl J Med* 360:2605–2615
- Green WD, Beck MA (2017) Obesity impairs the adaptive immune response to influenza virus. *Ann Am Thorac Soc* 14:S406–S409
- Wu MS, Yen HR, Chang CW, Peng TY, Hsieh CF, Chen CJ, Lin TY, Horng JT (2011) Mechanism of action of the suppression of influenza virus replication by Ko-Ken Tang through inhibition of the phosphatidylinositol 3-kinase/Akt signaling pathway and viral RNP nuclear export. *J Ethnopharmacol* 134:614–623
- Ye Y, Wang H, Liu J, Zhao F, Xu P (2020) Polygalasaponin F treats mice with pneumonia induced by influenza virus. *Inflammopharmacology* 28:299–310
- Wu F, Zhao S, Yu B, Chen YM, Wang W, Song ZG, Hu Y, Tao ZW, Tian JH, Pei YY et al (2020) A new coronavirus associated with human respiratory disease in China. *Nature* 579:265–269
- Li Y, Lai YN, Wang Y, Liu N, Zhang FX, Xu PP (2016) 1, 8-Cineol protect against influenza-virus-induced pneumonia in mice. *Inflammation* 39:1582–1593
- Parsey MV, Tuder RM, Abraham E (1998) Neutrophils are major contributors to intraparenchymal lung IL-1 beta expression after hemorrhage and endotoxemia. *J Immunol* 160:1007–1013
- Ison MG (2013) Clinical use of approved influenza antivirals: therapy and prophylaxis. *Influenza Other Respir Viruses* 7(Suppl 1):7–13
- Prasain JK, Jones K, Kirk M, Wilson L, Smith-Johnson M, Weaver C, Barnes S (2003) Profiling and quantification of iso-flavonoids in kudzu dietary supplements by high-performance liquid chromatography and electrospray ionization tandem mass spectrometry. *J Agric Food Chem* 51:4213–4218
- Zhou YX, Zhang H, Peng C (2014) Puerarin: a review of pharmacological effects. *Phytother Res* 28:961–975
- Wang HX, Zeng MS, Ye Y, Liu JY, Xu PP (2021) Antiviral activity of puerarin as potent inhibitor of influenza virus neuraminidase. *Phytother Res* 35:324–336
- Zhang SP, Wei TT, Tianv HY, Cheng JL, Xiao J, Wang M, Hu YX (2015) Small intestinal injury in mice infected with respiratory influenza A virus: evidence for virus induced gastroenteritis. *Biotechnol Lett* 37:1585–1592
- Hodge G, Hodge S, Chambers D, Reynolds PN, Holmes M (2007) Acute lung transplant rejection is associated with localized increase in T-cell IFN γ and TNF α proinflammatory cytokines in the airways. *Transplantation* 84:1452–1458
- Moschen AR, Kaser A, Enrich B, Mosheimer B, Theurl M, Niederegger H, Tilg H (2007) Visfatin, an adipocytokine with proinflammatory and immunomodulating properties. *J Immunol* 178:1748–1758
- Weidinger C, Ziegler JF, Letizia M, Schmidt F, Siegmund B (2018) Adipokines and their role in intestinal inflammation. *Front Immunol* 9:1974
- Moorthy AN, Tan KB, Wang S, Narasaraju T, Chow VT (2016) Effect of high-fat diet on the formation of pulmonary neutrophil extracellular traps during influenza pneumonia in BALB/c mice. *Front Immunol* 7:289
- Fernandez-Real JM, Pickup JC (2012) Innate immunity, insulin resistance and type 2 diabetes. *Diabetologia* 55:273–278
- Lago F, Dieguez C, Gomez-Reino J, Gualillo O (2007) Adipokines as emerging mediators of immune response and inflammation. *Nat Clin Pract Rheumatol* 3:716–724
- Kong Y, Zhang S, Wu R, Su X, Peng D, Zhao M, Su Y (2019) New insights into different adipokines in linking the pathophysiology of obesity and psoriasis. *Lipids Health Dis* 18:171
- Sawicka K, Michalska-Jakubus M, Potembska E, Kowal M, Pietrzak A, Krasowska D (2019) Visfatin and chemerin levels correspond with inflammation and might reflect the bridge between metabolism, inflammation and fibrosis in patients with systemic sclerosis. *Postepy dermatologii i alergologii* 36:551–565
- Alshaikh EM, Omar UM, Alsufiani HM, Mansouri RA, Tarbiah NI, Alshaikh AA, Rahimulddin SA, Al Doghathier HA (2019) The potential influence of hyperthyroidism on circulating adipokines chemerin, visfatin, and omentin. *Int J Health Sci* 13:44–47
- Branmark C, Kay EI, Ortegren Kugelberg U, Chanclon B, Shrestha MM, Wernstedt Asterholm I, Stralfors P, Olofsson CS (2020) Adiponectin is secreted via caveolin 1-dependent mechanisms in white adipocytes. *J Endocrinol* 247:25–38

Publisher's Note Springer Nature remains neutral with regard to jurisdictional claims in published maps and institutional affiliations.