

Salwa Kamourieh, MBBS,  
PhD  
Kohilan Gananandan,  
MBBS  
Joel Raffel, MBCh  
Richard Nicholas, MBBS,  
PhD

*Neurol Neuroimmunol  
Neuroinflamm*  
2017;4:e384; doi: 10.1212/  
NXI.0000000000000384

## NATALIZUMAB GRANULE CELL NEURONOPATHY: FDG-PET IN DIAGNOSIS AND IMMUNE RECONSTITUTION WITH G-CSF

### OPEN

Granule cell neuronopathy (GCN) is a rare presentation of JC virus (JCV) infection targeting the cerebellum.<sup>1</sup> To date, 2 cases have been described in patients prescribed natalizumab for MS.<sup>2,3</sup> Recent case reports have acknowledged the importance of controlled reconstitution of host immunity in treating JCV-related neurologic disorders.<sup>4</sup> In particular, granulocyte-colony stimulating factor (G-CSF) has emerged as a potential treatment.<sup>5</sup>

Here, we report a case of natalizumab-associated GCN where diagnosis was aided by the novel use of FDG-PET, and immune reconstitution driven by G-CSF lead to disease stabilization and subsequent improvement.

**Case report: clinical course.** A 31-year-old Caucasian female diagnosed in 1990 with relapsing-remitting MS on natalizumab since 2008 was admitted twice between July and September 2015, with progressive unsteadiness, dysarthria, and diplopia. Her serum anti-JCV antibody index was 2.41. Following concerns about possible progressive multifocal leukoencephalopathy (PML), her natalizumab was stopped in July 2015 (figure, A). She was treated with IV methylprednisolone, and the second course was followed up with oral prednisolone, to reduce her risk of immune reconstitution inflammatory syndrome (IRIS). Despite unchanged imaging (figure, B), in September 2015, a lumbar puncture found JCV-DNA viral load measured at 5,000 copies/mL.

Her clinical condition deteriorated and she became bedbound, and, in November 2015, her Expanded Disability Status Scale (EDSS) measured 8.0 on admission. A repeat CSF sample measured a viral load of 17,000 copies/mL of JCV-DNA. Repeat MRI did not identify features consistent with PML but did show progressive cerebellar volume loss (figure, B.b). A fluorodeoxyglucose-PET (FDG-PET) demonstrated patchy hypometabolism in the cerebellum (figure, C). Based on these results, a diagnosis of GCN without PML was made. Mirtazapine was started, and prednisolone was stopped. Although

not traditionally used, a 5-day trial of G-CSF was prescribed. Over the next 6 weeks, she showed progressive improvement in speech and mobility, and her EDSS improved to 7.0. A repeat CSF in January 2016 showed that the viral load had dropped to 250 copies/mL JCV-DNA.

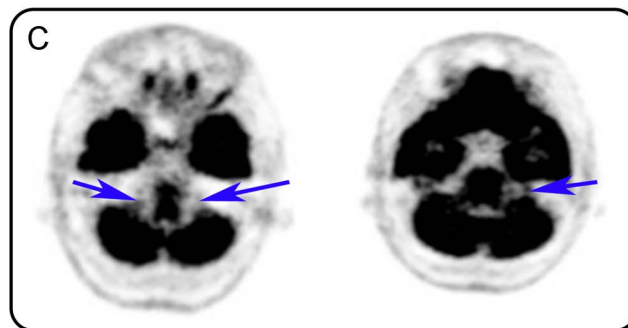
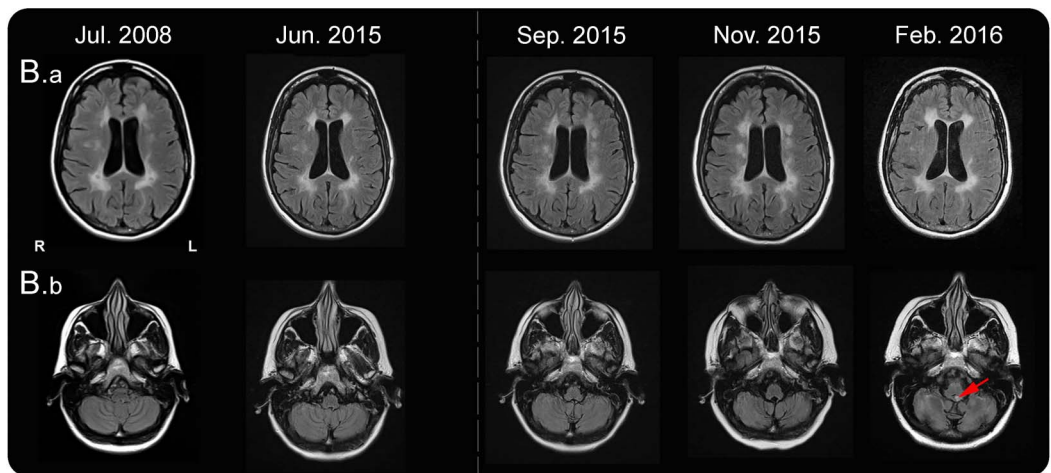
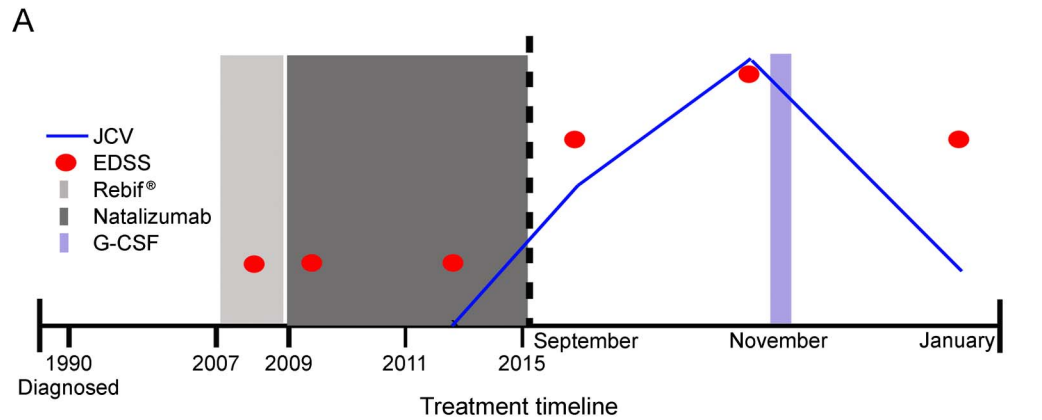
In February 2016, she experienced severe nausea. Her MRI showed high signal in the brainstem, in particular the pons (figure, B.b red arrow), felt to be consistent with IRIS. She declined steroids feeling this treatment was not warranted, given her overall clinical improvement. To date, her most recent imaging demonstrated a stable appearance and her latest EDSS is 6.5 (figure, A).

**Discussion.** This is the first case to describe the use of FDG-PET to aid diagnosis and the use of G-CSF to promote immune reconstitution in an MS patient with GCN. Although our understanding of PML after natalizumab is improving, our understanding of GCN after natalizumab is limited.

Difficulty in diagnosing early GCN is highlighted here, where progressive cerebellar atrophy was identified retrospectively, long after JCV-DNA was confirmed in the CSF. The presence of early cerebellar symptoms in patients treated with natalizumab requires early and regular imaging for cerebellar atrophy, in particular progression of atrophy,<sup>6</sup> with or without lumbar punctures for JCV-DNA detection.<sup>7</sup> The use of FDG-PET here is novel, demonstrating hypometabolism within both hemispheres of the cerebellum and enabling clear anatomical localization of the problem. Hypometabolism is an expected finding given the pathologic findings of neuronal cell loss in GCN, whereas in IRIS one may have expected more activity resulting from influx of immune cells. Limitations of this include the delay in performing the scan and the absence of serial imaging. FDG-PET could potentially be useful if used earlier; however, further studies into the utility of FDG-PET in this context are needed.

This patient was not a candidate for plasmapheresis because she had been off natalizumab for 3 months and it would have been cleared from her system. In addition, plasma exchange has been shown to be ineffective in natalizumab-associated PML cases.<sup>8</sup> Faced with progressive clinical deterioration and rising JCV-DNA in the CSF despite steroids, it was decided to start G-CSF,

**Figure (A)** Diagrammatic representation of disease course, EDSS, JCV CSF viral load, and treatments



(A) The disease was managed with interferon beta-1a (Rebif®) (2007-2009), but this was changed to monthly infusions of natalizumab in January 2009 because of disease breakthrough while on treatment. On starting natalizumab, her EDSS was 2.5; despite testing positive for anti-JCV antibody, her treatment was continued until July 2015, with a stable EDSS 2.0 and no further relapses. Her EDSS went up to 6.0 in July and to 8.0 in November. After treatment with G-CSF, her EDSS decreased to 6.5. (B) Diagram showing sequential MRI slices. Axial slices of T2 FLAIR sequences. Upper panel (B.a) demonstrates the unchanged multiple foci of abnormal signal in the cerebral white matter. Lower panel (B.b) demonstrates progressive cerebellar volume loss in particular between September 2015 and November 2015. The red arrow identifies an area of high signal in the pons. (C) FDG-PET. Brain PET FDG identifying small patches of hypometabolism (blue arrows) in the left inferior cerebellar cortex and right posterior cerebellar cortex, performed on December 31, 2015. EDSS = Expanded Disability Status Scale; FDG-PET = fluorodeoxyglucose PET; FLAIR = Fluid attenuation inversion recovery; G-CSF = granulocyte-colony stimulating factor; JCV = JC virus.

a glycoprotein, which primarily stimulates the production, mobilization, and survival of neutrophils, to initiate immune reconstitution in December 2016. Stefoski highlighted the clinical benefit of G-CSF in PML in 8/16 patients, with the desired response of immune-boosting leukocytosis and lymphocytosis resulting in

IRIS in 16/18 patients.<sup>5</sup> This is the first case to describe the use of G-CSF in the treatment of GCN but similar to its prior use, our patient developed IRIS approximately 6 months after natalizumab and 2 months after G-CSF. This was managed conservatively because of no significant clinical worsening.

This case highlights that the use of a novel diagnostic tool in GCN and hypometabolism on FDG-PET in the cerebellum could be used to support the early diagnosis of GCN. We also demonstrate as had been shown in preliminary case reports in PML that the use of G-CSF in these patients may be helpful in GCN.

*From the Department of Neurology (S.K., J.R., R.N.), Imperial College NHS Trust, London; and Department of Medicine (K.G.), Ealing Hospital, Southall, United Kingdom.*

*Author contributions: S. Kamourieh, K. Gananandan, J. Raffel, and R. Nicholas—write up of clinical note.*

*Study funding: No targeted funding reported.*

*Disclosure: S. Kamourieh and K. Gananandan report no disclosures. J. Raffel received research support from GE Healthcare and National Multiple Sclerosis Society. R. Nicholas served on the scientific advisory board for Biogen, Roche, Novartis, and Genzyme; received travel funding and/or speaker honoraria from Biogen; and received research support from Multiple Sclerosis Society. Go to [Neurology.org/nn](http://Neurology.org/nn) for full disclosure forms. The Article Processing Charge was funded by Imperial College London.*

*This is an open access article distributed under the terms of the Creative Commons Attribution-NonCommercial-NoDerivatives License 4.0 (CC BY-NC-ND), which permits downloading and sharing the work provided it is properly cited. The work cannot be changed in any way or used commercially without permission from the journal.*

*Received February 24, 2017. Accepted in final form May 30, 2017.*

*Correspondence to Dr. Kamourieh: [salwa.kamourieh@imperial.nhs.uk](mailto:salwa.kamourieh@imperial.nhs.uk)*

1. Tan CS, Koralnik IJ. Progressive multifocal leukoencephalopathy and other disorders caused by JC virus: clinical features and pathogenesis. *Lancet Neurol* 2010;9:425–437.
2. Agnihotri SP, Dang X, Carter JL, et al. JCV GCN in a natalizumab-treated MS patient is associated with mutations of the VP1 capsid gene. *Neurology* 2014;83:727–732.
3. Schippling S, Kempf C, Buchele F, et al. JC virus granule cell neuronopathy and GCN-IRIS under natalizumab treatment. *Ann Neurol* 2013;74:622–626.
4. Brew BJ, Davies NW, Cinque P, Clifford DB, Nath A. Progressive multifocal leukoencephalopathy and other forms of JC virus disease. *Nat Rev Neurol* 2010;6:667–679.
5. Stefoski D, Balabanov R, Ko M, Strong J, Javed A. Lessons learned from eighteen non-fatal outcomes in natalizumab-associated PML: an evolving therapeutic approach in settings of varied presentations. *Mult Scler J* 2015;21:586–587.
6. Wijburg MT, Siepman D, van Eijk JJ, Killestein J, Wattjes MP. Concomitant granule cell neuronopathy in patients with natalizumab-associated PML. *J Neurol* 2016;263:649–656.
7. Wattjes MP, Vennegoor A, Mostert J, et al. Diagnosis of asymptomatic natalizumab-associated PML: are we between a rock and a hard place? *J Neurol* 2014;261:1139–1143.
8. Landi D, De Rossi N, Zagaglia S, et al; Italian PML study group. No evidence of beneficial effects of plasmapheresis in natalizumab-associated PML. *Neurology* 2017;88:1144–1152.