

# Technique for Arthroscopic Long Head of Biceps Tenodesis Using Anchor With Fork Tip Eyelet

Jack Daoud, M.D., Dany Aouad, M.D., Hisham Abdelnour, M.D., Robert Hanna, P.T., and Georges El Rassi, M.D.

**Abstract:** This article describes a method of arthroscopic subscapular tenodesis of the long head of the biceps tendon using a single anterolateral portal, making it a minimally invasive procedure. This method is done by using the Swivelock tenodesis anchor with forked tip PEEK Eyelet from Arthrex, which enables anatomically stable fixation of the biceps tendon with a relatively decreased rate of complications.

**B**iceps tendinopathy is a common pathology mostly affecting young athletes performing repetitive lifting activities. It rarely presents as an isolated pathology. In most cases, it is associated with a SLAP tear, chronic inflammation, and partial or complete tear with subluxation of the biceps tendon itself outside the groove in rotator cuff tears involving the subscapularis.<sup>1</sup>

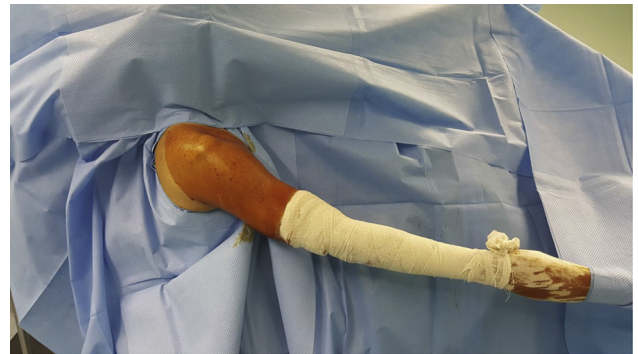Tenodesis of the long head of the biceps is a procedure commonly used to treat biceps tendinopathy. Some of these procedures are technically demanding with possible complications and a long recovery time.<sup>2,3</sup>

## Surgical Technique

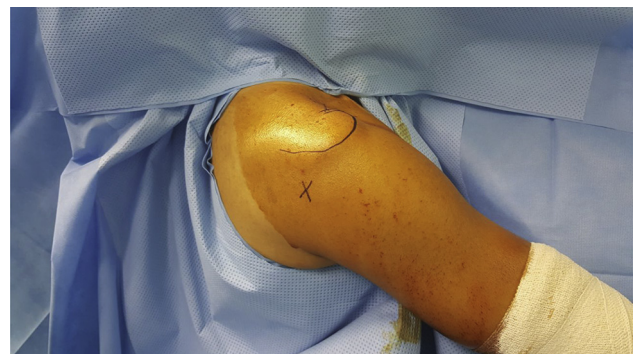
The surgery is performed under combined nerve block and general anesthesia. The patient is put into beach chair position with the arm in approximately 45° of flexion and 30° of abduction while maintaining elbow extension and applying traction with 5 kg of weight (Fig 1).

The procedure starts by palpating the posterior soft spot formed by the interval between the infraspinatus and the teres minor muscle located approximately 2

finger breadths below and 2 finger breadths medial to the posterolateral corner of the acromion (Fig 2). An 8-mm incision is made over the soft spot after which the introducer is passed into the shoulder joint by



**Fig 1.** Beach chair position with arm in 45° of flexion and 30° of abduction.



**Fig 2.** Beach chair position. The posterior soft spot, located 2 finger breadths below and 2 finger breadths medial to the posterolateral corner of the acromion, is palpated and marked by X.

From St. Georges University Medical Center, Beirut, Lebanon.

The authors report that they have no conflicts of interest in the authorship and publication of this article. Full ICMJE author disclosure forms are available for this article online, as [supplementary material](#).

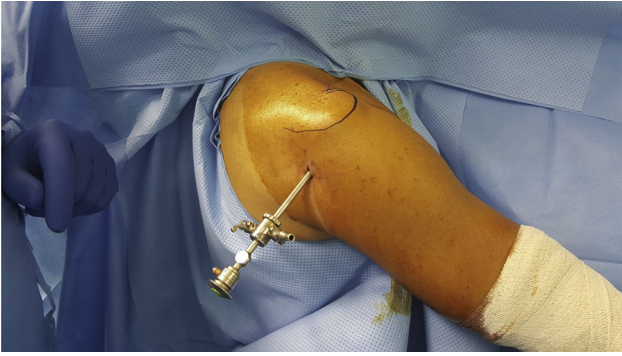
Received July 25, 2017; accepted September 18, 2017.

Address correspondence to Jack Daoud, M.D., St. Georges University Medical Center, St. Georges Street, Beirut, Achrafieh, Lebanon. E-mail: [jack.c.daoud@gmail.com](mailto:jack.c.daoud@gmail.com)

© 2017 by the Arthroscopy Association of North America. Published by Elsevier. This is an open access article under the CC BY-NC-ND license (<http://creativecommons.org/licenses/by-nc-nd/4.0/>).

2212-6287/17900

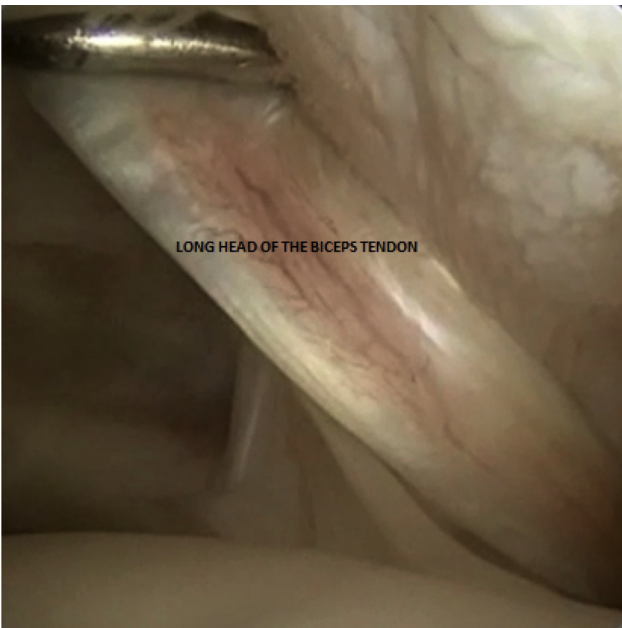<https://doi.org/10.1016/j.eats.2017.09.005>



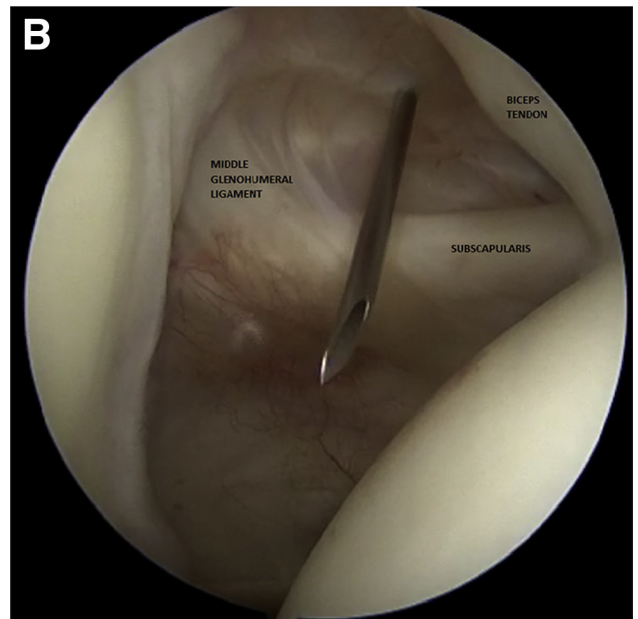
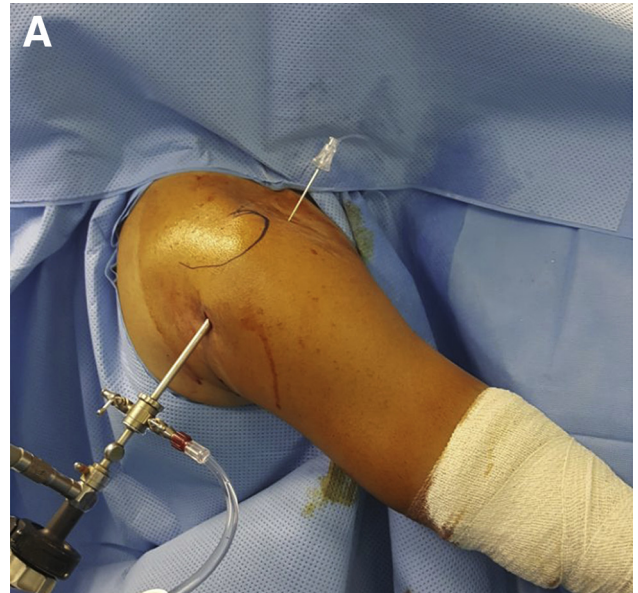
**Fig 3.** Beach chair position. The introducer is inserted into the glenohumeral joint by aiming toward the coracoid process through the soft spot.

aiming toward the coracoid process (Fig 3). The 30° scope (Arthrex, Naples, FL) is introduced, and a diagnostic arthroscopy is performed by inspecting the joint. If the diagnosis is indicative for isolated biceps tenodesis (Fig 4), we proceed by creating the anterior portal.

Under direct vision (Fig 5A), a spinal needle is introduced lateral to the coracoid process through the rotator interval as a guide for creating the anterior portal (Fig 5B). The rotator interval is the triangular space between the tendons of the subscapularis and the supraspinatus and the base of the coracoid process. Next, a lateral portal is created 1 to 2 cm lateral to the lateral edge of the acromion through which subacromial bursectomy is done (Fig 6; Video 1). Extended subacromial bursectomy is done using the shaver (Dissector, Arthrex) in order to facilitate both extra-articular identification and exposure of the long head of the biceps tendon.

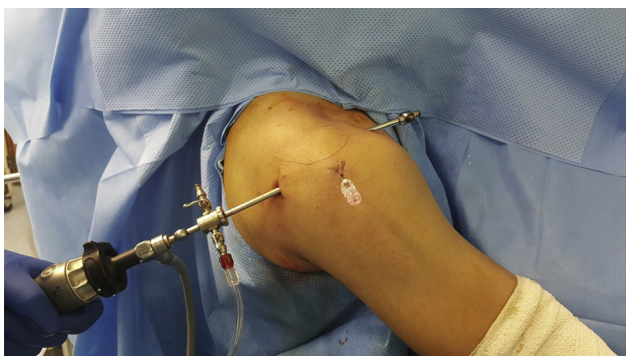

**Fig 4.** Intra-articular diagnostic arthroscopy showing inflammation of the long head of the biceps tendon.



**Fig 5.** (A) Spinal needle introduced lateral to the coracoid process through the rotator interval under direct vision. (B) Rotator interval bound superiorly by the supraspinatus and inferiorly by the subscapularis with the long head of the biceps tendon forming its roof.

At this point, the arm is put into 90° of flexion with the elbow in extension and the forearm in full supination (Fig 7). This is done to maintain tension on the biceps tendon, which helps in identifying and marking the site of extra-articular tenodesis. To localize the biceps tendon extra-articularly we move the scope to the lateral portal and keep the anterior portal for instrumentation. The shaver, introduced through the anterior portal, is used for localizing the biceps tendon outside the groove by sliding its tip over the tendon (Fig 8).

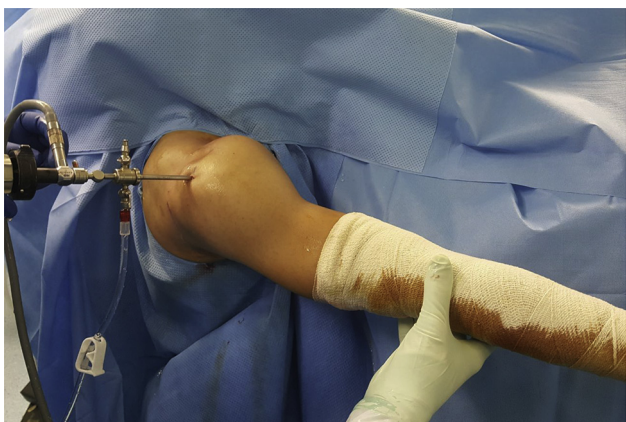

**Fig 6.** Beach chair position. A spinal needle is introduced 1 to 2 cm distal to the lateral acromial edge as a guide to create the lateral portal.

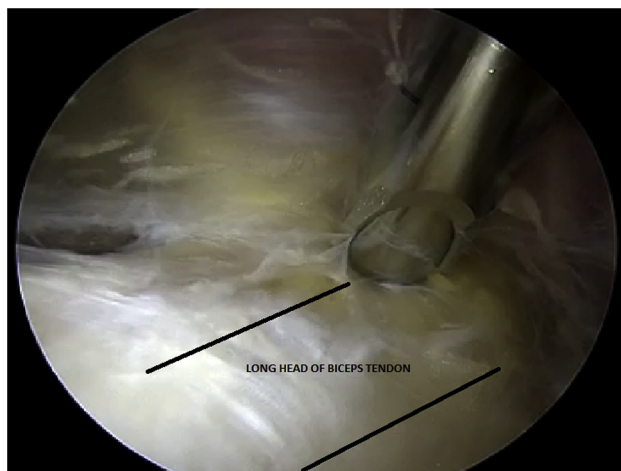
After identifying the location of the tendon, the shaver is used to clear the tendon maintaining its full exposure (Fig 9). Through the anterior portal, the electrocautery (ApolloRF MP90, Aspirating Ablator 90°, Multi-Port; Arthrex) is used to mark the border of the biceps tendon with its corresponding level on the humerus for tenodesis site (Fig 10). This step is crucial to maintain tenodesis under anatomical tension.

At this point, we flex the elbow into 90° (Fig 11) and approach the intra-articular space for biceps tenotomy (Fig 12). By doing this we decrease the tension on the tendon and avoid excessive retraction after the tenolysis. This position is maintained until completion of the procedure.

Now we move back to the subacromial space, and under direct vision using a spinal needle as guidance, we create an anterolateral portal that is perpendicular to the humeral shaft overlying the planned site for tenodesis (Fig 13). This portal is used for preparing the tunnel and engaging the anchor. A piloted head reamer (Arthrex) is introduced through the anterolateral portal.



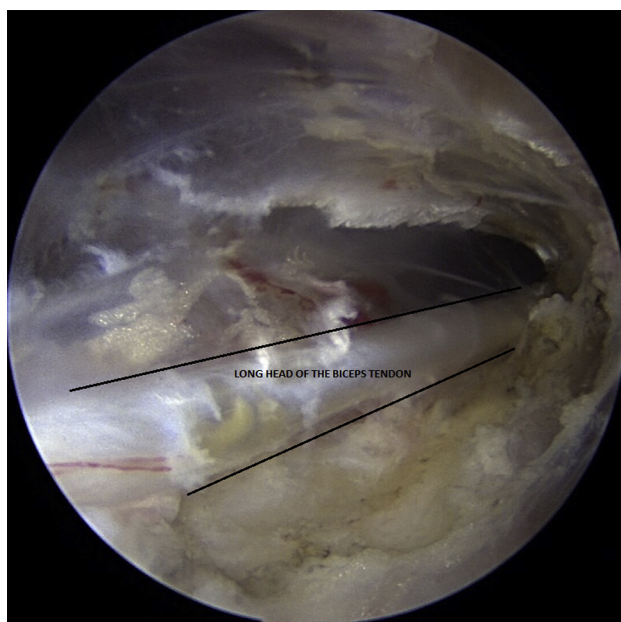
**Fig 7.** Beach chair position. The arm is put into 90° of flexion with the elbow in extension and the forearm in full supination in order to keep tension on the biceps tendon facilitating its identification.



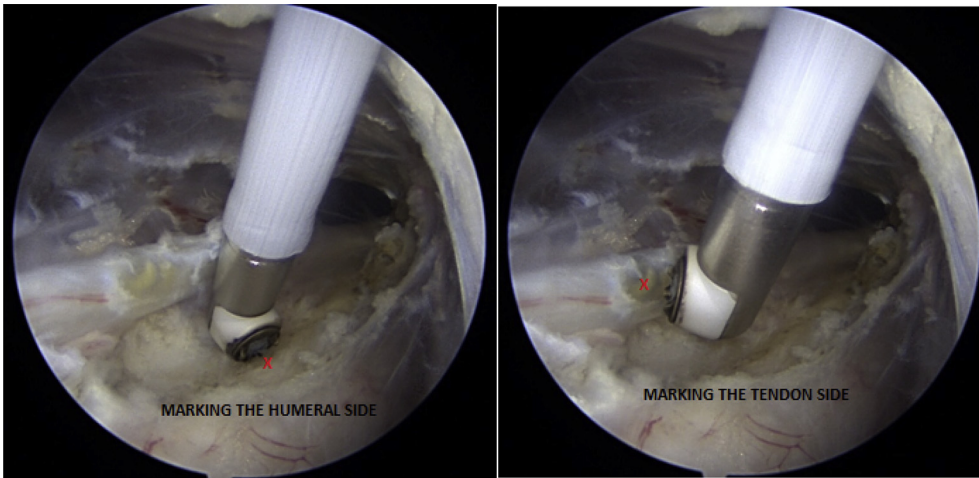
**Fig 8.** Sliding the tip of the shaver over the long head of the biceps tendon enabling identification of its location.

The tip of the reamer is placed at the desired tenodesis site by moving the biceps tendon using the reamer itself (Fig 14). This is so as not to worry about damaging the tendon while drilling, even if the tendon is in direct contact with the drilling tip, since the piloted head reamer has no sharp edges. A 20-mm depth hole is created at 90° of angulation to the shaft with care not to break the metaphysis (Fig 15; Video 1).

The tenodesis anchor is introduced through the anterolateral portal (Fig 16), using its forked tip to trap the biceps tendon and enable manipulation (Fig 17). The anchor with the biceps tendon is then introduced into the bony canal and tightened (Fig 18). Any remnants of the tendon are debrided using the electrocautery (Fig 19). The portal sites are closed with simple



**Fig 9.** By clearing the surrounding tissue, the shaver is used to obtain full exposure of the biceps tendon.



**Fig 10.** The electrocautery is used to mark the border of the biceps tendon with its corresponding level on the humerus for tenodesis site.

stitches and covered with dressing. An arm sling is applied for immobilization as a first stage of rehabilitation. As a rehabilitation protocol, the first phase starts from 7 to 10 days postop up to 4 weeks and includes passive range of motion of the shoulder and the elbow without any active range of motion. The aim of this phase is to minimize pain and inflammation with gradual restoration of passive range of motion.

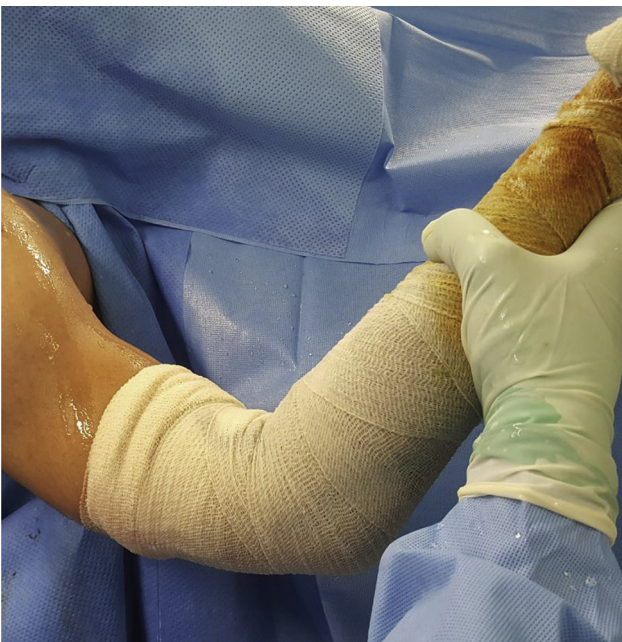In the second phase (from week 4 to week 6), we progress to active assisted range of motion around the shoulder with active elbow flexion/extension and forearm supination/pronation without resistance. This aims to achieve gradual restoration of the active range of motion. The last phase consists of initiating biceps

curls and forearm pronation/supination with light resistance, progressing as tolerated until reaching normal strength and endurance.

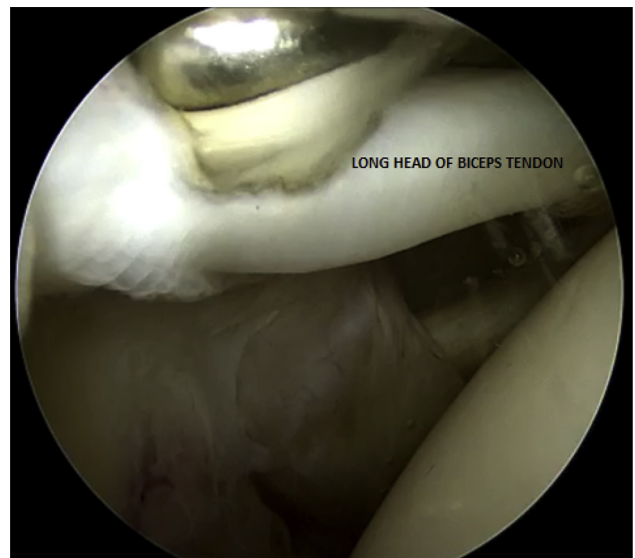
### Discussion

Although tenodesis is often preferred in athletic population, it is still technically demanding<sup>4</sup> with long-term recovery<sup>2,3</sup> specifically in centers lacking arthroscopic facilities where procedures require extensive dissection.<sup>4</sup>

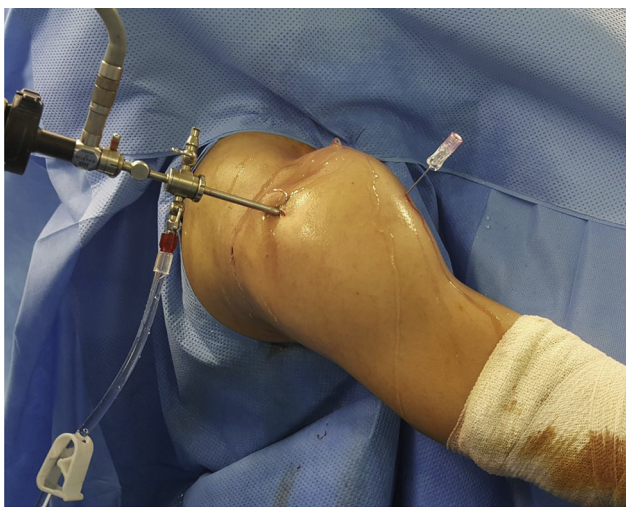
The long recovery time and the anterior shoulder pain commonly seen in proximal biceps tenodesis<sup>2</sup> done inside the bicipital groove are ameliorated in this technique because it is minimally invasive using a single anterolateral portal with fixation outside the bicipital groove (Table 1).



**Fig 11.** Beach chair position. Elbow flexed to 90° in order to avoid retraction of the long head of the biceps tendon after intra-articular tenotomy.



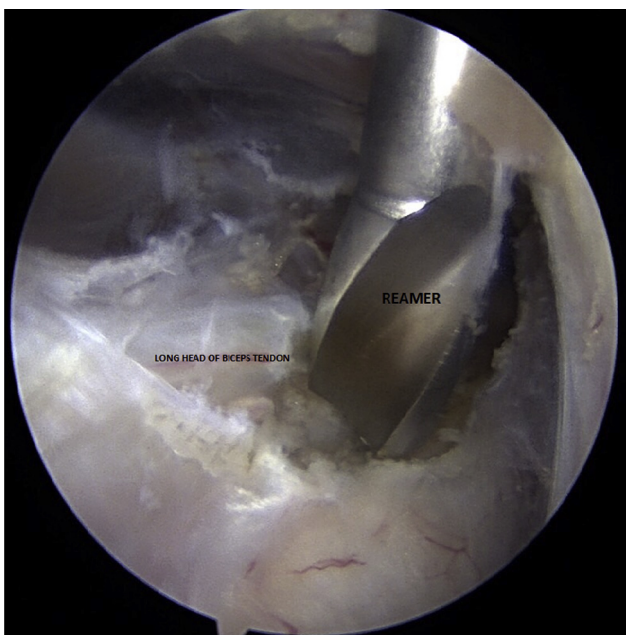
**Fig 12.** Intra-articular tenotomy of the long head of the biceps.



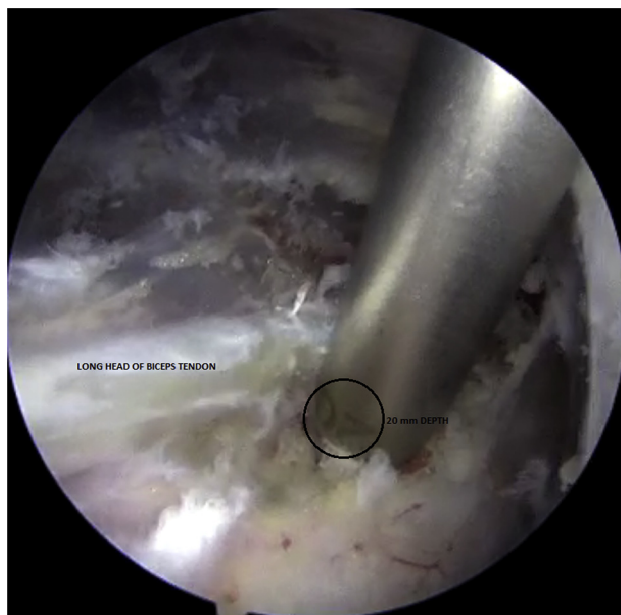**Fig 13.** Beach chair position. Under direct vision, the anterolateral portal is created, overlying the biceps tendon at the planned tenodesis site.

Furthermore, since the site of fixation of the tendon in this technique is in a low-risk zone, there is decrease in the risk of neurovascular injury mainly of the axillary branches<sup>2,3</sup> seen in proximal biceps tenodesis (Table 1).

In addition, when compared with subscapular biceps tenodesis, our technique offers the same clinical results and advantages without the complications seen in subpectoral biceps tenodesis.<sup>5</sup> Some of these complications described in the literature are risk of fracture of the humerus at the site of tenodesis,<sup>5</sup> which is decreased in this technique by drilling the bony canal more proximal than the latter technique, conserving a



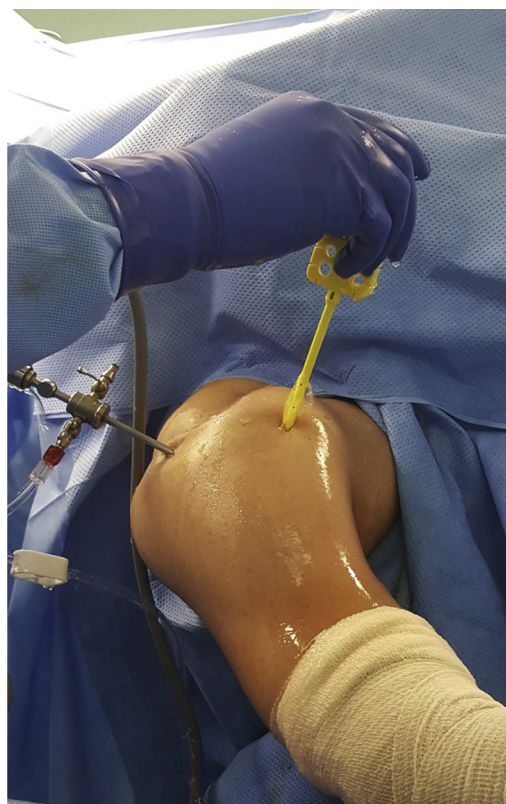**Fig 14.** Through the anterolateral portal, the piloted head reamer is introduced and placed over the site of tenodesis.



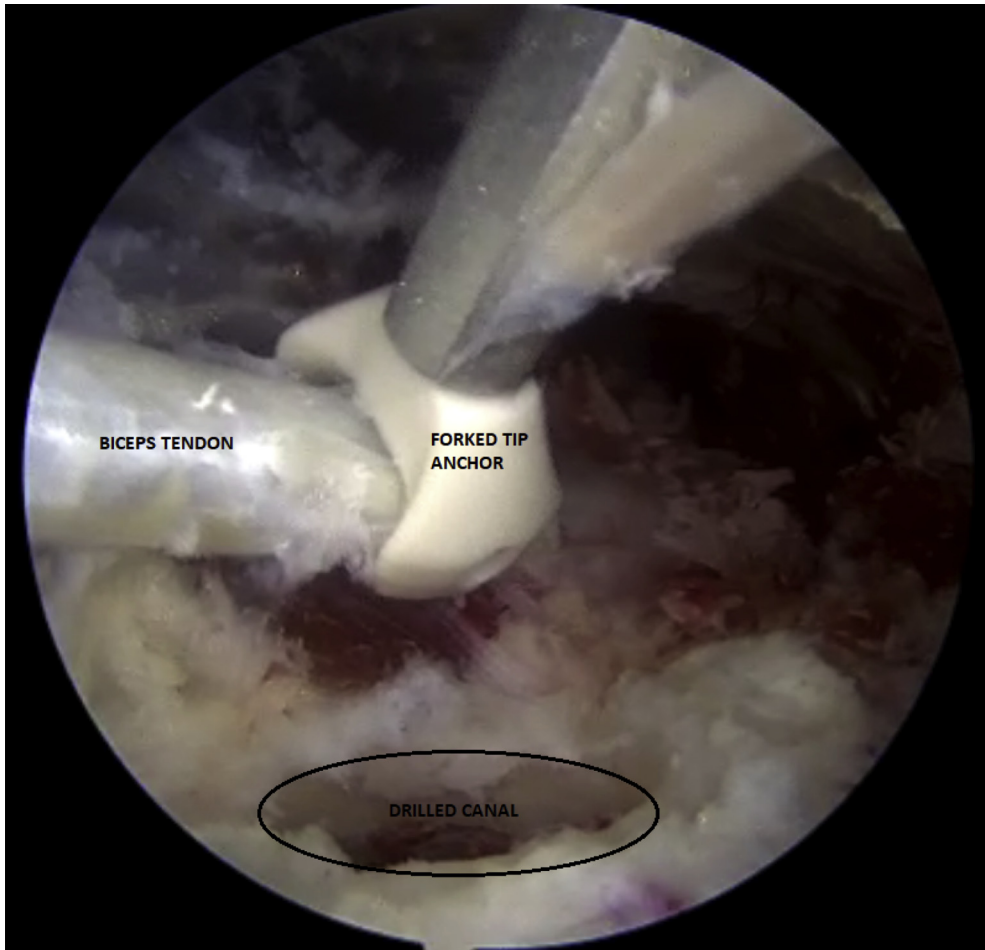
**Fig 15.** Drilling of a 20 mm depth hole for tenodesis angled at 90° to the humeral shaft.

sufficient diameter of the humerus and preventing subsequent fracture (Table 1).

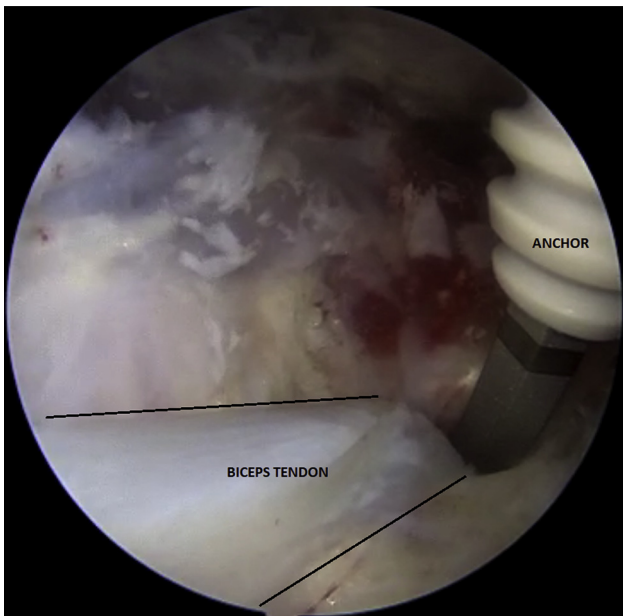
Furthermore, the risk of rupture of the tendon at the fixation site seen in subpectoral biceps tenodesis<sup>5</sup> is



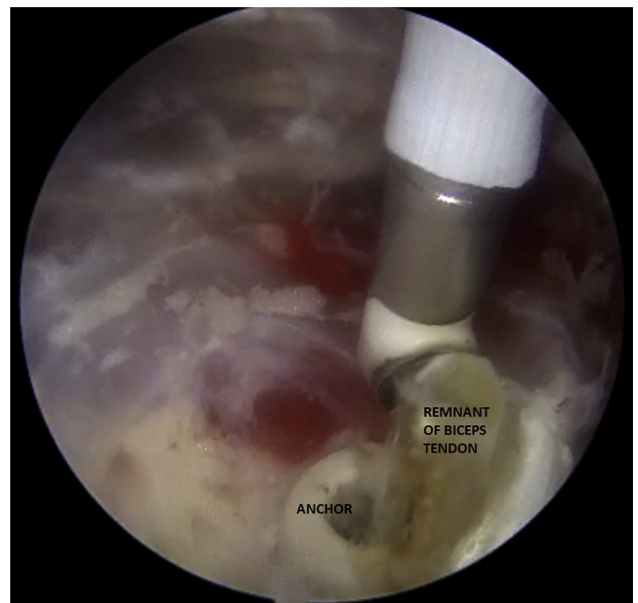
**Fig 16.** Beach chair position. The tenodesis anchor is introduced through the anterolateral portal.



**Fig 17.** Forked tip anchor used to trap and manipulate the long head of the biceps tendon toward the drilled bony canal.



**Fig 18.** Anchor along with the biceps tendon are introduced into the bony canal.



**Fig 19.** After completing tenodesis, the remnants of the biceps tendon are debrided using the electrocautery.

**Table 1.** Advantages and Disadvantages

Advantages	Disadvantages
Minimal dissection using a single anterolateral portal. Stable fixation due to insertion of the tendon into cancellous bone, decreasing the risk of tendon rupture. Decreased risk of humeral fracture due to the large diameter of the humerus at the level of fixation. Relatively short recovery time. Site of fixation is in a low-risk zone, therefore there is decreased risk of neurovascular injury.	Failure of fixation of the tendon mainly in elderly osteoporotic patients.  Requires different intraoperative positioning of the upper limb to facilitate localization of the biceps tendon in its groove with optimal exposure during tenodesis under anatomical tension.

decreased in this technique since the biceps tendon is integrated in fully cancellous bone increasing power of fixation with lower risk of rupture.

In this technique we described an efficient method for anatomical biceps tenodesis in both genders, despite gender-related anatomical variations,<sup>6</sup> with minimal dissection through a single anterolateral portal resulting in a relatively decreased recovery period with decreased postoperative pain.

### References

1. Brady PC, Narbona P, Adams CR, et al. Arthroscopic proximal biceps tenodesis at the articular margin: evaluation of outcomes, complications, and revision rate. *Arthroscopy* 2015;31:470-476.
2. Virk MS, Nicholson GP. Complications of proximal biceps tenotomy and tenodesis. *Clin Sports Med* 2016;35:181-188.
3. Sethi PM, Vadasdi K, Greene RT, Vitale MA, Duong M, Miller SR. Safety of open suprapectoral and subpectoral biceps tenodesis: an anatomic assessment of risk for neurologic injury. *J Shoulder Elbow Surg* 2015;24:138-142.
4. Prabhu J, Faqi MK, Awad RK, Alkhalifa F. Modified open suprapectoral endobutton tension slide tenodesis technique of long head of biceps with restored tendon tension-length. *Open Orthopaed J* 2017;11:281-290.
5. Rios D, Martetschläger F, Horan MP, Millett PJ. Complications following subpectoral biceps tenodesis with interference screw fixation. *J Shoulder Elbow Surg* 2013;22:e26.
6. Kovack TJ, Idoine JD, Jacob PB. Proximal biceps tenodesis: an anatomic study and comparison of the accuracy of arthroscopic and open techniques using interference screws. *Orthopaed J Sports Med* 2014;2: 2325967114522198.