

Case report: Unusual presentation of haemopericardium with haemodynamic instability secondary to a coronary graft pseudoaneurysm treated by an endovascular approach

Arvin Haghighat¹, Thomas H. Burke², John W. D. Speirs^{3*}, and Anthony E. Glanz⁴

¹Schulich School of Medicine and Dentistry, Western University, London, ON, Canada; ²MicroVention-Terumo, Tustin, CA, USA; ³Division of Interventional Radiology, Department of Radiology, Windsor Regional Hospital, Windsor, ON, Canada; and ⁴Division of Cardiology, Department of Medicine, Windsor Regional Hospital, Windsor, ON, Canada

Received 22 June 2018; accepted 12 November 2018; online publish-ahead-of-print 7 December 2018

Background

We report the successful endovascular treatment of a coronary graft pseudoaneurysm using a technique often seen in intracranial aneurysm coiling.

Case summary

We present an unusual case of a patient who presents with haemopericardium and haemodynamic instability after saphenous vein bypass grafting. A pseudoaneurysm rapidly expanded from 5 cm to 7 cm over the follow-up period producing compressive mass effect on the lateral right ventricle with transient haemodynamic instability. The patient's declining clinical condition did not warrant a redo thoracotomy and sternotomy, so an endovascular approach was deemed to be the best treatment option.

Discussion

The use of endovascular embolization techniques is indeed a technically viable alternative with positive outcomes without the need for thoracotomy and sternotomy.

Keywords

Cardiac pseudoaneurysm • Haemopericardium • Endovascular coiling • Case report

Learning points

- In the setting of venous grafts to coronary vessels, a pseudoaneurysm arising from the graft itself remains to be a rare complication but certainly needs to be addressed if clinically symptomatic.
- The use of endovascular embolization techniques is indeed a technically viable alternative with positive outcomes for treatment of specific cases of haemopericardium without the need for thoracotomy and sternotomy.

* Corresponding author. Tel: 1-519 566-4687, Fax 1-519 979-5611, Email: jwdspeirs@gmail.com

Handling Editor: Riccardo Liga

Peer-reviewers: Mohamed Hassan and Subhi Akleh

Compliance Editor: Mohammed Akhtar

Supplementary Material Editor: Peregrine Green

© The Author(s) 2018. Published by Oxford University Press on behalf of the European Society of Cardiology.

This is an Open Access article distributed under the terms of the Creative Commons Attribution Non-Commercial License (<http://creativecommons.org/licenses/by-nc/4.0/>), which permits non-commercial re-use, distribution, and reproduction in any medium, provided the original work is properly cited. For commercial re-use, please contact journals.permissions@oup.com

Introduction

Ischaemic coronary artery disease can be treated by surgical bypass or an endovascular approach. When utilizing an open surgical approach, the most common vessels utilized for bypass would be the internal mammary artery (IMA) or a harvest vein such as the greater saphenous vein (SVG). Common vein graft complications include stenosis and occlusion. However, a pseudoaneurysm arising from the graft itself remains a rare complication but certainly needs to be addressed if clinically symptomatic and at risk of rupture. Indeed, given that mostly symptomatic aneurysms are reported, the overall incidence of these pseudoaneurysms is difficult to assess (estimated <1%).¹

We report a case of a patient who presents with a large expanding pseudoaneurysm (7 cm × 5 cm). The aetiology of this pseudoaneurysm was iatrogenic in nature, secondary to previous endovascular interventions (PCI). The mechanism was most likely a fracture of a stent tine through the graft wall into the pericardial space causing acute extravasation of blood resulting in haemopericardium, culminating into a mass effect along the lateral wall of the right ventricle with transient haemodynamic instability.

Timeline

1991	Patient had four vessel bypass surgery with a right internal mammary artery and three venous grafts.
Between 1991 and 2011	Patient underwent multiple endovascular interventions including previous endovascular intervention to the previously placed saphenous vein graft to the obtuse marginal artery
2011	One of the above interventions led to a dissection with subsequent vein graft pseudoaneurysm formation. Pseudoaneurysm was being observed.
2015	Sized of pseudoaneurysm noted to be 5 × 5 cm. Patient remained asymptomatic.
2016 September	Patient presents with symptoms. Endovascular coiling procedure takes place. Patient tolerates it well and has no complications or new onset of symptoms.
2017 July	Patient remains asymptomatic and clinically stable. Repeat CTA performed demonstrating no filling of the pseudoaneurysm and good flow.
2017 September	1-year follow-up, patient remains asymptomatic and with good exercise tolerance and no recurrence of chest pain.

Case presentation

The patient is an 80-year-old male patient with a longstanding history of coronary artery disease (CAD), hypertension, dyslipidaemia, and permanent atrial fibrillation on anticoagulation, with a past surgical

history of four vessel bypass surgery in 1991 with a right IMA graft and three venous grafts. Post-coronary bypass surgery, he developed stable angina, treated on multiple occasions with percutaneous interventions, including PCI to the previously placed saphenous vein graft to the obtuse marginal artery (SVG-OM). In 2011, during the deployment of a 3.0 × 9.0 mm bare metal driver stent in the SVG-OM, a dissection occurred with subsequent vein graft pseudoaneurysm formation. The stent potentially fractured through the graft causing the formation of the pseudoaneurysm, which was being observed since then and was last noted to be over 5 cm on a chest computed tomography (CT) scan in 2015.

The patient remained asymptomatic and the pseudoaneurysm remained stable until his presentation in September 2016 with acute onset of retrosternal chest heaviness and diaphoresis. Initial examination showed blood pressure (BP) measurements of 93/60 mmHg with chest pain. Physical examination demonstrated normal jugular venous pressure, clear lung fields, no murmurs, normal heart sounds, and weak radial pulses. The electrocardiogram (ECG) demonstrated non-specific T-wave changes in the inferolateral leads (*Figure 1*). The initial troponin I level was 0.17 mcg/L (N < 0.10 mcg/L). Shortly after admission, the patient developed hypotension which was initially corrected with a fluid bolus to 127/73 mmHg with a heart rate of 78. His O₂ saturations were 96% on room air, and his chest pain improved following sublingual nitroglycerine administration. Immediately prior to transfer to the telemetry ward, he re-developed worsening chest pain with a drop in systolic BP to 70 mmHg. A repeat ECG demonstrated new and dynamic ST elevation in leads I and aVL with deep reciprocal ST depression in the inferior leads that were not present on his initial presentation (*Figure 2*), prompting activation of a code STEMI. Aspirin and ticagrelor were administered and the patient was emergently transferred to the cardiac catheterization lab.

An echo was performed that showed pericardial fluid measuring up to 1.9 cm in diameter, but there was no right ventricular collapse and no other signs of tamponade (*Figure 3*). Cardiac catheterization revealed normal left ventricular function with an ejection fraction of 60%, visually estimated from a left ventricular angiogram. The previously placed cardiac stents within the proximal right coronary artery (RCA) as well as the distal RCA remained patent without any significant narrowing. However, the saphenous vein graft to the second obtuse marginal branch of the circumflex artery demonstrated a large pseudoaneurysm. No intervention was initially felt possible given the size of the pseudoaneurysm.

Several hours post-catheterization, the patient experienced recurrent chest pain with transient lateral ST elevation. A CT angiography (CTA) scan of the chest demonstrated expansion of the pseudoaneurysm from 5.2 cm in 2016 to 7 cm in maximum dimension (7 cm × 5 cm). It also demonstrated that the pseudoaneurysm had ruptured into the pericardium with the presence of a moderate size haemopericardium producing compressive mass effect along the lateral right ventricular surface (*Figure 4*).

After consultation between cardiology, cardiovascular surgery, and interventional radiology, it was felt that the patient was not a good candidate for redo sternotomy nor for PCI; thus an endovascular coiling of the SVG-OM graft circumflex was performed by interventional radiology.

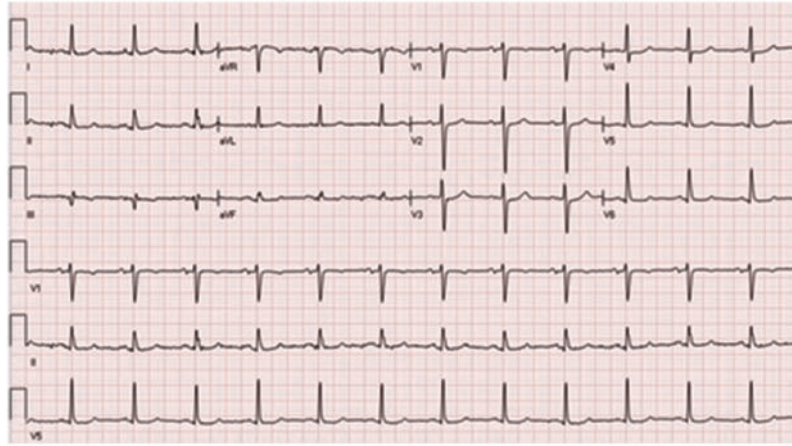


Figure 1 Initial electrocardiogram demonstrating normal sinus rhythm and some non-specific ST abnormalities in the inferior leads.

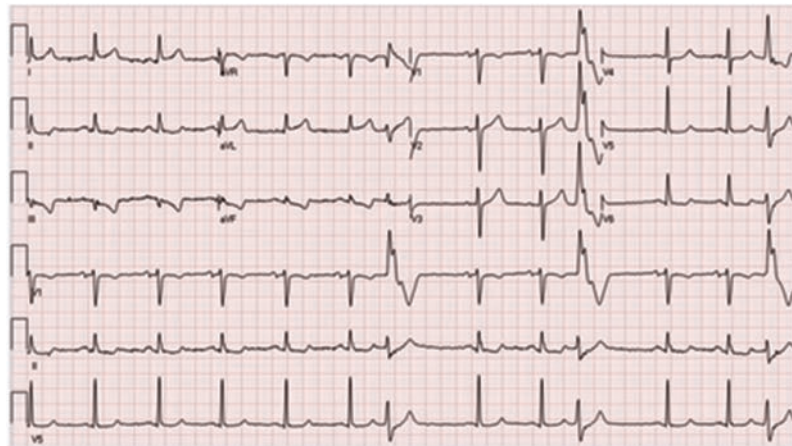


Figure 2 Electrocardiogram following patient's worsening hypotension, demonstrating signs of acute ischaemic injury notably in leads I and AVL.

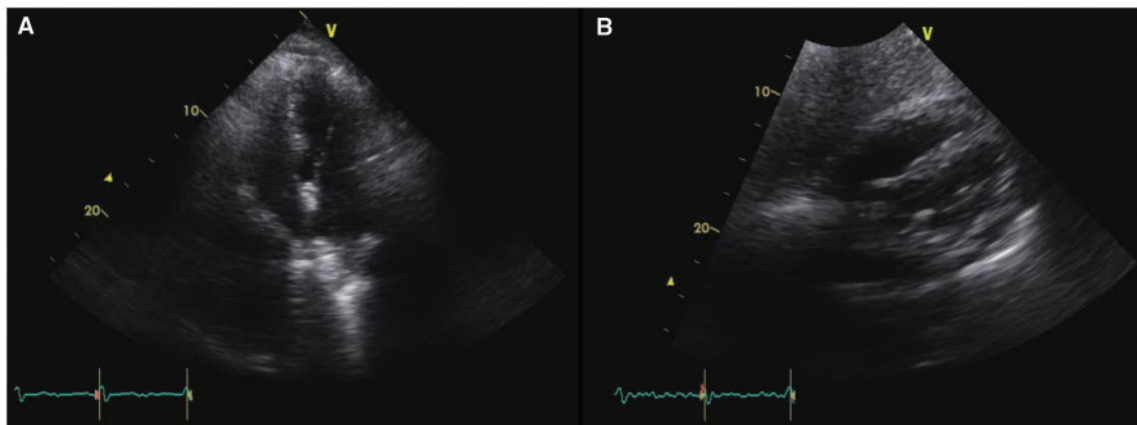


Figure 3 (A) Four chamber view showing a small pericardial effusion. (B) Subcostal view showing again a small pericardial effusion without echo signs of tamponade.

Utilizing a right femoral artery approach and placement of a 6 F sheath, a 6 F Burke Chaperon guidecatheter (Microvention-Terumo, Aliso Viejo, CA, USA) was advanced into the ascending aorta. With the 6 F Burke placed into the origin of the SVG-OM graft, an initial angiogram demonstrated the previously placed stent at the origin of the venous bypass as well as a second stent in the mid-portion of the graft in association with the pseudoaneurysm. There appeared to be a small tear with extravasation of contrast through the proximal interstices of the stent, but little flow into the distal outflow vessel. A 2-tip Headway microcatheter (Microvention-Terumo) was coaxially advanced into the proximal portion of the neck of the

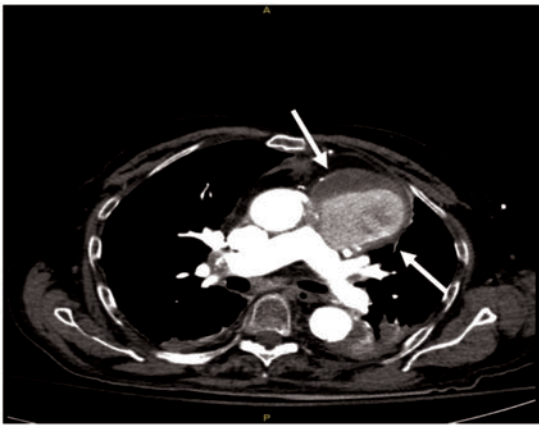

Figure 4 CTA imaging demonstrates the expanding pseudoaneurysm with layering of contrast in the true lumen in transverse view. The aforementioned compression on the lateral wall of the right ventricle can be observed with addition of bibasilar atelectatic changes. White arrow indicates the SVG pseudoaneurysm filled with ~70% contrast.

pseudoaneurysm (Figure 5A). Delivery of multiple HydroFrame coils (Microvention-Terumo) (two 7 mm × 28 cm, one 6 mm × 19 cm, two 5 mm × 15 cm, two 4 mm × 8 cm) and a single 4 mm × 10 cm HydroSoft coil was performed producing slowing of flow into the pseudoaneurysm sac (Figure 5B). A post embolization control angiogram demonstrated near complete occlusion of the sac with patency of the proximal graft (Figure 5C). A 16 h follow-up CTA was performed and, although there did appear to be flow into the distal outflow of the graft, there was none into the pseudoaneurysm sac.

The patient tolerated the procedure well, with no new onset of symptoms, no ECG changes, no arrhythmias. There was a small rise in the troponin I level to 3 mcg/L ($N < 0.10$ mcg/L) noted post procedure. No further haemodynamic or electrical instability was

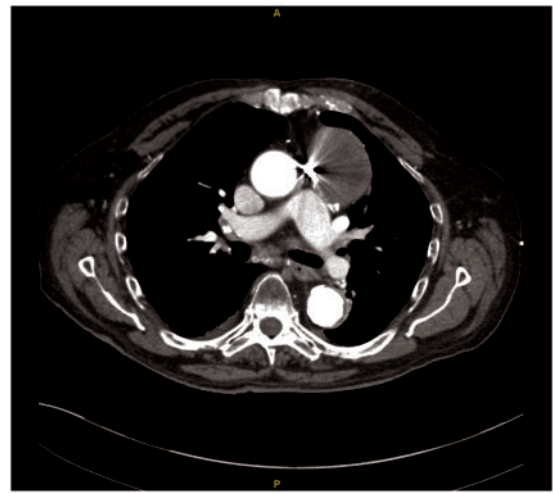


Figure 6 Follow-up 10 month CTA. The previously seen and coiled pseudoaneurysm is completely thrombosed.

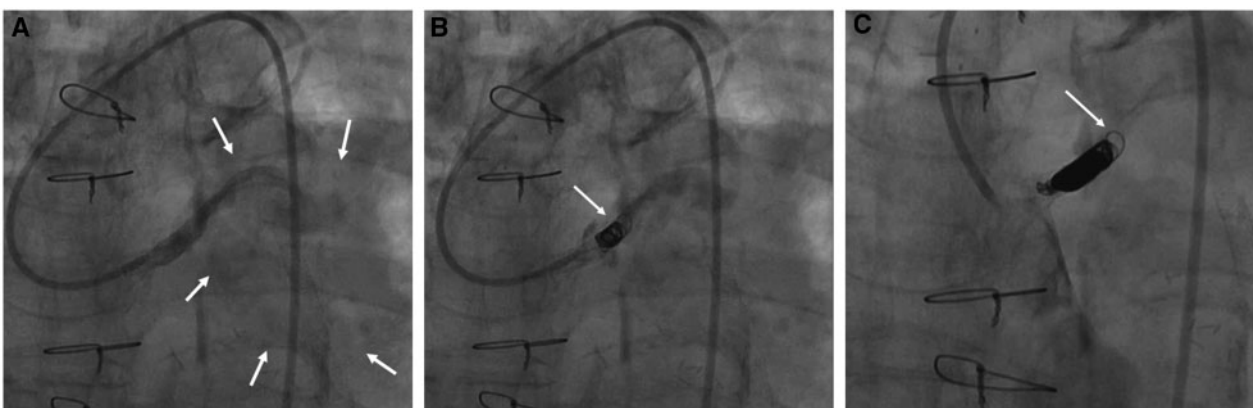


Figure 5 Single static images of angiogram recordings. (A) Injection of contrast demonstrates filling of a very large pseudoaneurysm (grossly outlined by arrows). (B) Contrast flow from the tip of the microcatheter into the origin of the pseudoaneurysm. Image was taken during the embolization process (arrow) with hydroframe coils of the proximal portion of the neck of the pseudoaneurysm. (C) Very limited flow (arrow) is seen into the residual portion of the pseudoaneurysm.

observed. Mild congestive heart failure developed that responded to medical therapy. Repeat echo and CT scan showed no changes in the pericardial effusion. The patient was ultimately restarted on anticoagulation and discharged from the hospital in stable condition on post-operative Day 7. At clinical follow-up at 1 month, the patient was clinically stable. A repeat CTA at 10 months (Figure 6), demonstrated no filling of the pseudoaneurysm and good flow into the distal outflow territory. At a 1-year clinical follow-up visit, the patient remained asymptomatic, with good exercise tolerance and no recurrence of chest pain.

Discussion

Saphenous vein graft pseudoaneurysm formation post-PCI with subsequent rupture is a rare complication. Emergent open surgical treatment for these patients is high risk and should be avoided, especially in patients who are unstable at presentation.^{2,3} The use of endovascular embolization techniques is indeed a technically viable alternative with positive outcomes without the need for thoracotomy and sternotomy.^{4,5}

HydroFrame and HydroSoft coils have an inert hydrogel material within the construct of the coil which swells in the presence of blood creating a better mechanical and stable framework with long-term occlusion. Furthermore, the use of coaxially placed microcatheters directly at the target lesion, with the controlled deployment of hydrogel type coils, produces a better long-term outcome than that of fibred coils because of a more stable framework.^{6,7} These coils often used in intracranial aneurysm coiling procedures are retrievable, repositionable, and mechanically detached only when properly placed. Given its advantages and its success seen with both ruptured and unruptured intracranial aneurysms especially on long-term follow-up,⁶ its use was favourable for this case. Although this is a single case presentation, it demonstrates, along with a recent case report,⁷ that superselective hydrogel coil embolization of very difficult lesions can achieve technical success with positive clinical outcomes. Moreover, to the best of our knowledge, this is the first treatment of

a coronary pseudoaneurysm treated with the use of the neuro-designated hydrogel coils.

Local Research Ethics Board reviewed this brief report and has determined that it did not require ethics approval. Informed consent for publication was obtained from the patient.

Supplementary material

Supplementary material is available at *European Heart Journal - Case Reports* online.

Slide sets: A fully edited slide set detailing this case and suitable for local presentation is available online as [Supplementary data](#).

Consent: The author/s confirm that written consent for submission and publication of this case report including image(s) and associated text has been obtained from the patient in line with COPE guidance.

Conflict of interest: A.H., J.W.D.S., and A.E.G. declare no conflict of interest related to this publication. T.H.B. is an employee of MicroVenton/Terumo.

References

- Ramirez FD, Hibbert B, Simard T, Pourdjabbar A, Wilson KR, Hibbert R, Kazmi M, Hawken S, Ruel M, Labinaz M, O'Brien ER. Natural history and management of aortocoronary saphenous vein graft aneurysms: a systematic review of published cases. *Circulation* 2012;**126**:2248–2256.
- Prêtre R, Linka A, Jenni R, Turina MI. Surgical treatment of acquired left ventricular pseudoaneurysms. *Ann Thorac Surg* 2000;**70**: 553–557.
- Van de Wal RMA, van Werkum JW, le Cocq d'Armandville MC, Plokker HWT, Morshuis WJ. Giant aneurysm of an aortocoronary venous bypass graft compressing the right ventricle. *Neth Heart J* 2007;**15**: 252–254.
- Dimitri WR, Reid AW, Dunn FG. Leaking false aneurysm of right coronary saphenous vein graft: successful treatment by percutaneous coil embolisation. *Br Heart J* 1992;**68**:619–620.
- Katoh H, Nozue T, Michishita I. A case of giant saphenous vein graft aneurysm successfully treated with catheter intervention. *Catheter Cardiovasc Interv* 2016;**87**: 83–89.
- Speirs JWD, Burke TH, Lee SY, Ala BD. The next generation HydroCoil: initial clinical experience with the HydroFill embolic coil. *J Neurointerv Surg* 2013;**5**: iii72–iii75.
- Aleman CJA, Dyer J, Billing JS. HydroCoil embolization of an infected ascending aortic pseudoaneurysm. *J Vasc Interv Radiol* 2017;**28**:1059–1061.