

Tubercular Osteomyelitis of Cuboid

Naveen Jeyaraman¹, Madhan Jeyaraman², Sathish Muthu³, R P Packkyarathinam⁴

Learning Point of the Article:

Tubercular osteomyelitis of the cuboid is a rare entity which needs high degree of suspicion and medical management is sufficient for complete cure without complications.

Abstract

Introduction: Tuberculosis (TB) affection of foot appears to be a rare clinical entity and accounts for <10% and 0.1-0.3% of osteoarticular and extrapulmonary TB, respectively. In TB foot, tarsal joints and calcaneum are more commonly affected followed by talus, distal end of first metatarsal, navicular, cuneiforms, and cuboid bones.

Case Report: A 24-year-old female presented with pain and swelling over dorsum of the left foot from the past 8 months. On examination, there was a diffuse round shaped, solitary swelling measuring about 3.5 cm × 2.5 cm (approx.) with its surface smooth, non-pulsatile, non-fluctuant, non-transilluminant, non-compressible, and non-reducible present over dorsum of the left foot. Radiographic investigations revealed osteolytic lesion over the base of 3rd, 4th, and 5th metatarsals, middle and lateral cuneiforms and cuboid bones along with soft tissue swelling and diffuse transient osteopenia. Under spinal anesthesia, tricut biopsy of the mass revealed paucibacillary type of TB in histopathological examination. The patient was provided with ATT drugs in the form of intensive phase drugs (HRZE) daily for 4 months and continuation phase drugs (HRE) daily for 10 months according to the weight of the patient. The patient was followed up with erythrocyte sedimentation rate and C-reactive protein every 2 months once. The patient achieved a normal range of movements in the midtarsal joints except for the painful terminal range of movements. The patient was still under our follow-up.

Conclusion: The cuboid is the second most involved tarsal bone. The diagnosis is not always frankly evident, and a high index of suspicion has to be maintained. Surgical intervention should be limited to biopsy only as multidrug chemotherapy alone is sufficient to achieve complete healing.

Keywords: Cuboid, osteomyelitis, tuberculosis, anti-tuberculous therapy, tarsal bone.

Introduction

Tuberculosis (TB) is a major health concern especially in developing countries like India which has a population of 1.39 billion, second largest in the world [1]. India has a prevalence rate of 193/100,000 population [2]. Of this, extra pulmonary TB (EPTB) constitutes 10-15% [3]. Musculoskeletal TB constitutes 1-5% of all forms of TB and 10-18% of EPTB [4, 5]. TB affection of foot appears to be a rare clinical entity and accounts for <10% and 0.1-0.3% of osteoarticular and extrapulmonary TB, respectively [6, 7]. In TB foot, tarsal joints and calcaneum are

more commonly affected followed by talus, distal end of first metatarsal, navicular, cuneiforms, and cuboid bones [8]. Plenty of studies are available for pulmonary TB, but studies pertaining to EPTB especially musculoskeletal TB are scanty. In this study, we report a case of TB osteomyelitis in cuboid bone, an unusual location for musculoskeletal TB. We report this case due to its rarity, as there were only 15 reported cases of TB osteomyelitis of cuboid bone in the literature.

Author's Photo Gallery



Dr. Naveen Jeyaraman



Dr. Madhan Jeyaraman



Dr. Sathish Muthu



Dr. R P Packkyarathinam

Access this article online

Website:
www.jocr.co.in

DOI:
10.13107/jocr.2021.v11.i12.2542

¹Department of Orthopaedics, Atlas Hospitals, Tiruchirappalli, Tamil Nadu, India,

²Department of Orthopaedics, Faculty of Medicine - Sri Lalithambigai Medical College and Hospital, Dr. MGR Educational and Research Institute, Chennai, Tamil Nadu, India,

³Department of Orthopaedics, Government Dindigul Medical College and Hospital, Dindigul, Tamil Nadu, India,

⁴Department of Orthopaedics, Government Medical College, Omandurar Government Estate, Chennai, Tamil Nadu, India.

Address of Correspondence:

Dr. R.P Packkyarathinam,
Department of Orthopaedics, Government Medical College, Omandurar Government Estate, Chennai, Tamil Nadu, India.
E-mail: packkyarathinam@gmail.com

Submitted: 16/09/2021; Review: 14/10/2021; Accepted: November 2021; Published: December 2021

DOI:10.13107/jocr.2021.v11.i12.2542

This is an open access journal, and articles are distributed under the terms of the Creative Commons Attribution-NonCommercial-ShareAlike 4.0 License <https://creativecommons.org/licenses/by-nc-sa/4.0/>, which allows others to remix, tweak, and build upon the work non-commercially, as long as appropriate credit is given and the new creations are licensed under the identical terms



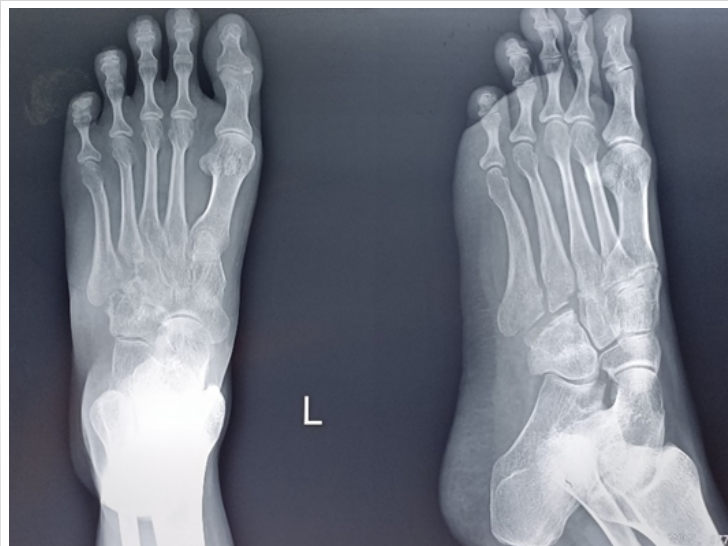

Figure 1: Plain radiograph of the left foot showing osteolytic lesion over the base of 3rd, 4th, and 5th metatarsals, middle and lateral cuneiforms and cuboid bones along with soft tissue swelling and diffuse transient osteopenia.

Case Report

A 24-year-old female was presented with pain and swelling over dorsum of the left foot from the past 8 months. The pain was insidious in onset and dull aching in nature. The swelling was insidious in onset and slowly increasing in size to attain the present size. There was no history of injury, infection, sinus, or other swellings on her left foot. On examination, there was a diffuse round shaped, solitary swelling measuring about 3.5 cm × 2.5 cm (approx.) with its surface smooth, edges being indistinct, non-pulsatile, non-fluctuant, non-transilluminant, non-compressible and non-reducible present over dorsum of left foot. Muscle wasting was present. There was no arterial bruits and venous hum on auscultation. The distal neurovascular status was intact. The range of motions of left foot was painful and restricted. There was no regional lymphadenopathy.

Plain radiograph of left foot revealed osteolytic lesion over the base of 3rd, 4th, and 5th metatarsals, middle and lateral cuneiforms and cuboid bones along with soft tissue swelling and

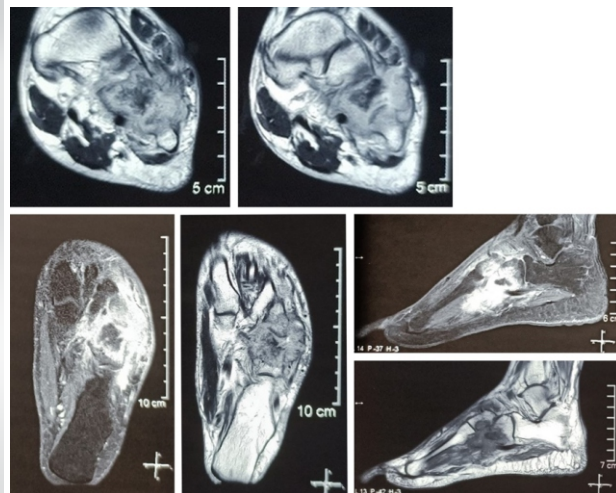


Figure 2: Magnetic resonance imaging of the left foot (T1W SE, T2W TSE and STIR sequences of axial, coronal, and sagittal sections) revealing osteomyelitis involving base of 4th and 5th metatarsals, lateral aspect of lateral cuneiform and cuboid with hypointense signals on T1W images and hyperintense signals on T2W images within the tarsal and metatarsal bones which show homogeneous enhancement after contrast. The sclerotic bony fragment within the soft tissue which was consistent with chronic osteomyelitis.

diffuse transient osteopenia as shown in (Fig. 1). Magnetic resonance imaging of the left foot (T1 SE, T2 TSE and STIR sequences of sagittal, coronal and axial sections) revealed osteomyelitis involving base of 4th and 5th metatarsals, lateral aspect of lateral cuneiform and cuboid with hypointense signals on T1W images and hyperintense signals on T2W images within the tarsal and metatarsal bones which show homogeneous enhancement after contrast. Multiple erosions are seen with the evidence of joint effusion and soft tissue abscess formation on the antero-lateral aspect of the tarso-metatarsal joint. The soft tissue component also shows homogeneous enhancement with two pockets of central non-enhancing necrotic component in them. Evidence of tiny sclerotic bony fragment within the soft tissue which was consistent with chronic osteomyelitis (Fig. 2).

Under spinal anesthesia, trucut biopsy of the mass was taken along with the drainage of the pus with an uneventful postoperative period. Gene Xpert of the pus sample revealed no resistance to either isoniazid (H) or rifampicin[®]. AFB staining revealed paucibacillary type of TB. Histopathology of the

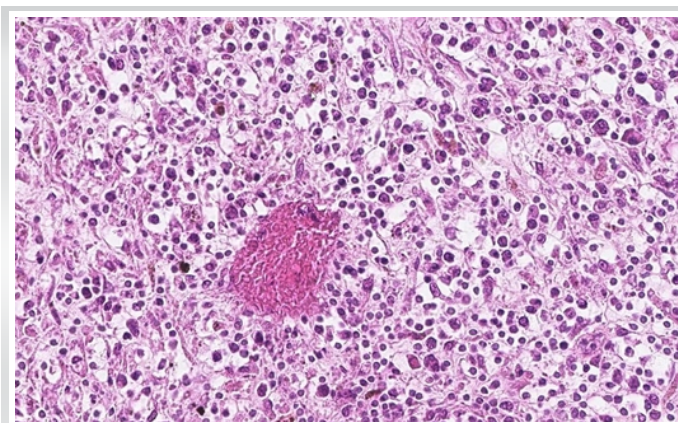


Figure 3: Histopathology of trucut biopsy shows a lymphocytic infiltrate with region of caseating necrosis with occasional Langhans giant cells.

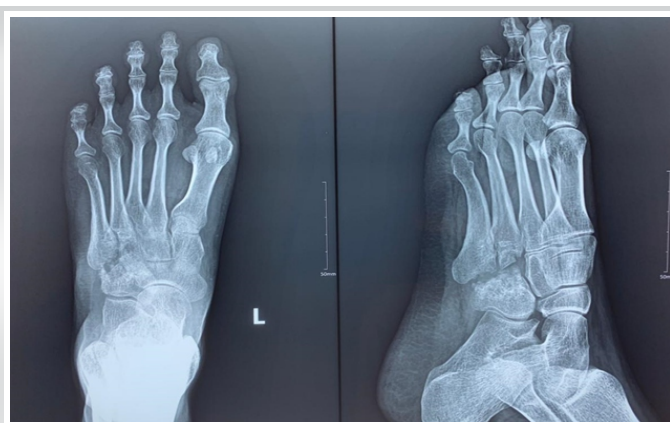

Figure 4: 14 months follow-up radiograph of the left foot showing resolution of the infection and consolidation of the lesion in the cuboid.

Table 1: Review of TB osteomyelitis of cuboid from 1990 to 2021.

Author (year)	Case details	Primary tarsal bone involved	Involvement of other tarsal bones	Investigations	Microbiology and Pathology	Management
Dhillon et al. [15]	28/F with pain and swelling over foot for 7 months	Cuboid	Tarsometatarsal joint	X ray of involved foot – Decreased joint space, sclerosis and severe osteoporosis with well-defined osteolytic lesion and feathery sequestrum	Mantoux test – Positive Raised ESR and CRP Aspiration biopsy – Chronic granulomatous lesion of tubercular origin AFB staining – Positive	2[HR]E ₁
	40/F with pain and swelling over foot for 6 months	Calcaneocuboid joint	Tarsometatarsal joint			9[HR]E ₃ At the end of 9 months follow up, patient developed a painful stiff foot
Miron et al. [23]	11/M with swelling and redness of left foot for 1 week	Cuboid			Gram's staining – Gram-positive filamentous branched organisms AFB staining – Positive for M. fortuitum/M. peregrinum	Combination of 2 or more of the drugs 4-6 weeks [amikacin, imipenem, meropenem, ciprofloxacin and clarithromycin]
Dhillon et al. [6]	39/F	Cuboid		X ray showed significant sclerosis around the osteolytic area of cuboid	Mantoux test – Positive Raised ESR and CRP CT/USG guided aspiration – Evidences of caseation ± tubercle Culture – Variable	3[HR]E ₃ + 12[HR]E ₃
Dhillon et al. [18]	24/M			CT scans – Well defined osteolytic lesion with feathery or coke-like sequestrum		4[HR]ZE ₃ + 14[HR]E ₃
	33/F			T1W MRI – Significant hypointensity of the cuboid marrow T2W MRI – Marked increase in signal intensity of cuboid		4[HR]ZE ₃ + 13[HR]E ₃
	20/F			Evidences of cortical breaks and abscesses were observed		3[HR]ZE ₃ + surgical debridement and mini external fixator for 2 months
Agarwal et al. [24]	4/M	Right cuboid	Right 5th metatarsal	X ray of involved foot – Severe osteopenia with collapse of the involved bone MRI scan – Severe bone marrow edema with fluid accumulation around the involved tarsal bones	Raised ESR and CRP FNAC/trocar bone biopsy/open biopsy/edge biopsy of sinuses – Evidences of granulomatous lesion with caseation AFB staining – Positive Culture – M. tuberculosis and M. fortuitum	Splintage and ATT drugs (2[HR]ZE ₃ + 10[HR]E ₃)
	9/M	Left cuboid	T9-T11			
	12/F	Right cuboid				
Ferguson et al. [25]	66/M with left midfoot pain for 6 months	Cuboid	All cuneiforms and navicular	X ray left foot – Erosion of the involved tarsal bones MRI of left foot – Extensive erosion of 3 cuneiform, navicular and cuboid with fluid collection around the bones	Raised ESR and CRP Biopsy – Granulomatous lesion AFB staining – Negative Culture – Negative	9 months of ATT [HR]Z ₃ At the end of 9 months follow-up, the patient reported with resolution of symptoms.
Upadhaya et al. [26]	43/M, with hind foot pain for 4 months	Cuboid	Calcaneum	X-ray right foot - Periarticular osteopenia, narrowing of joint space with osteolytic destruction of adjoining calcaneum and cuboid CT scan of right foot – Lytic lesion over calcaneum and cuboid bone extending across joint with sequestrum formation seen in cuboid bone	Raised ESR and CRP CT guided biopsy – Caseating granuloma suggestive of TB. AFB staining of the aspirated material – Negative Culture of the aspirated material – Positive for M. tuberculosis	2[HR]E ₃ + 4[HR]E ₃ At the end of 2 years follow-up, the patient gained near normal movements of right foot
Jeyaseelan et al. [27]	44/F with pain in left foot for 12 months	Cuboid	Lateral cuneiform, navicular	X-ray left foot – Erosions over cuboid, navicular and lateral cuneiform MRI left foot – Marked signal intensity from involved tarsal bones	Mantoux test – Positive Raised ESR and CRP USG guided cuboid biopsy – Granulomas with caseous necrosis. AFB staining – Positive	2[HR]ZE ₃ + 4[HR]E ₃ Patient reported pain free by the end of 8 weeks of ATT therapy
Vijay et al. [28]	30/F with right foot pain for 8 months	Cuboid	Calcaneum	X-ray of right foot – Well defined osteolytic lesion over cuboid and calcaneum with areas of osteolysis and diffuse osteoporosis MRI of right foot – Erosive arthritis of C-C joint with mild fluid collection and with increased signal intensity on T2W images	Raised ESR and CRP Open biopsy – Caseating granulomatous inflammation with Langhans' type giant cell reaction AFB staining – Positive	2[HR]ZE ₃ + 3[HR]E ₃ + 12[HR]E ₃ along with below knee cast Complete resolution achieved at end of 2 years
Our case (2021)	24/F with pain and swelling over left foot for 8 months	Cuboid	Base of 3rd, 4th and 5th metatarsals, middle and lateral cuneiforms	X-ray of left foot – Well defined osteolytic lesion over cuboid and base of 3rd, 4th and 5th metatarsals, middle and lateral cuneiforms, with soft tissue swelling and transient osteopenia MRI of the left foot – Hyperintense signals within the tarsal and metatarsal bones with homogeneous enhancement after contrast	Raised ESR and CRP Open biopsy – Lymphocytic infiltration along with caseating necrosis and with an occasional langhans giant cells scattered in between the lymphocytic infiltrates AFB staining of the biopsied material – Negative Culture – MOTS group of organisms	2[HR]ZE ₃ + 10[HR]E ₃ along with boot cast Patient reported pain relief during the course of continuation phase treatment. The patient is still under follow up

TB: Tuberculosis, MRI: Magnetic resonance imaging



Table 2: Classification of foot and ankle TB by Martini et al. [22]

Stage	Description
1	Local osteoporosis without accompanying bony changes
2	Existence of erosions or cavities within the bone
3	Involvement of the whole joint without major destruction
4	Gross destruction

TB: Tuberculosis

biopsied mass revealed lymphocytic infiltration along with caseating necrosis and with an occasional langhans giant cells scattered in between the lymphocytic infiltrates (Fig. 3). The culture of pus was attempted and found to be positive for MOTS group of mycobacteria. The patient was provided with high protein diet, Vitamin D and calcium supplementation and ATT drugs in the form of intensive phase drugs (HRZE) daily for 4 months according to the weight of the patient. The patient was followed up with erythrocyte sedimentation rate (ESR) and C-reactive protein (CRP) every 2 months once. During intensive phase, the patient experienced pain relief and decrease in the size of the swelling. The patient achieved a normal range of movements in the midtarsal joints except for the painful terminal range of movements. The continuation phase drugs (HRE) daily for 12 months have been given with ESR and CRP follow-up once in every 2 months. No recurrence of pain and swelling were reported during the continuation phase follow-up. The patient was still under our follow-up.

Discussion

Musculoskeletal TB (approx. 20%) occurs as an extrapulmonary manifestation with or without pulmonary involvement and is of paucibacillary in nature [9, 10, 11]. The most common form of musculoskeletal TB occurs in spine (50-70%) (thoracic 50% > cervical 25% > lumbar 25%) followed by pelvis (12%), hip and femur (10%), knee and tibia (10%), ribs (7%), ankle/foot or shoulder (2%), elbow or wrist (2%), and multiple sites (3%) [12, 13, 14].

TB affection of foot appear to be a rare clinical entity and accounts for <10% and 0.1% to 0.3% of osteoarticular and extrapulmonary TB, respectively [6, 7]. Hindfoot TB is more common in occurrence than midfoot TB [15]. In TB foot, tarsal joints and calcaneum are more commonly affected followed by talus, distal end of first metatarsal, navicular, cuneiforms and cuboid bones [8]. Musculoskeletal TB of foot has four forms of presentation namely (1) periarticular osseogranuloma, (2) central osseogranuloma, (3) primary hematogenous synovitis, and (4) tenosynovitis and bursitis [16, 17].

Dhillon et al. encountered a diagnostic delay ranged from 2 months to 2 years in their TB foot and ankle series cases due to

misdiagnosis of a tumor condition or acute pyogenic condition [7, 18]. Our case was diagnosed in the time span of 8 months since the onset of disease pathology. The diagnostic tests of ESR and CRP are not assisting to arrive at a conclusion since they are non-specific and increased in various disorders. Although no specific clinical or radiological modalities are available for diagnosis of TB, the relevant radiological and histopathological examination will help in diagnosing the clinical condition. Various authors have performed biopsy of the lesion and confirmed the diagnosis of TB of foot and ankle [19, 20, 21]. For more specific diagnosis, the demonstration of organism either in staining or culture must be done from the biopsy specimens.

To date, we found a total of 15 cases (11 adults and 4 pediatric cases) on tubercular osteomyelitis of cuboid were found on literature search which were tabulated (Table 1). The classification of foot and ankle TB was proposed by Martini et al as tabulated (Table 2) [22].

Treatment of foot and ankle TB were medical management if the cases were mild to moderate degree and respond to the course of ATT drugs or medical with surgical if the cases were severe degree and do not respond to conservative methods. Many surgeons preferred long-term ATT drugs for managing TB foot and ankle [6, 7, 20, 29]. For severe and non-responding cases, surgical modalities such as debridement and curettage, debridement, sequestrectomy, bone grafting, fistulectomy, synovectomy, arthrodesis, and resection [18, 30, 31]. The reported literature shows very low or no recurrence of TB foot and ankle disease pattern in the follow-up period [19].

Our case of TB cuboid and associated tarsal and metatarsals belong to the variety of periarticular osseogranuloma of TB foot. According to Martini et al classification, our patient had the presence of erosions and cavities within base of 3rd, 4th, and 5th metatarsals, middle and lateral cuneiforms, and cuboid bones of left foot. During 14th month of follow-up, the radiograph of the left foot shows consolidation of the lesion in the cuboid (Fig. 4).

Conclusion

Due to rarity of foot and ankle TB, the published results show the limited long-term results. Biopsy and histopathological evaluation and culture and staining of the organism from the lesion remain the most standard diagnostic modality in the cases of suspected osseous TB. Long-term administration of ATT drugs with or without surgical intervention prevents the residual deformity associated with osseous TB.



Clinical Message

Tuberculosis should be considered in the differential diagnosis for any unexplained lesions in the endemic regions and medical management gives successful outcome on histopathological confirmation of the lesion.

Declaration of patient consent : The authors certify that they have obtained all appropriate patient consent forms. In the form, the patient's parents have given their consent for patient images and other clinical information to be reported in the journal. The patient's parents understand that his names and initials will not be published and due efforts will be made to conceal their identity, but anonymity cannot be guaranteed.

Conflict of interest: Nil **Source of support:** None

References

- Huddart S, Singh M, Jha N, Benedetti A, Pai M. Case fatality and recurrent tuberculosis among patients managed in the private sector: A cohort study in Patna, India. *PLoS One* 2021;16:e0249225.
- TB Facts TB Statistics, India. TB Facts; 2020. Available from: <https://tbfacts.org/tb-statistics-india> [Last accessed on 2021 Oct 20].
- Lee JY. Diagnosis and treatment of extrapulmonary tuberculosis. *Tuberc Respir Dis* 2015;78:47-55.
- Leonard MK, Blumberg HM. Musculoskeletal tuberculosis. *Microbiol Spectr* 2017;5:1128.
- Gambhir S, Ravina M, Rangan K, Dixit M, Barai S, Bomanji J. Imaging in extrapulmonary tuberculosis. *Int J Infect Dis* 2017;56:237-47.
- Dhillon MS, Singh P, Sharma R, Gill SS, Nagi ON. Tuberculous osteomyelitis of the cuboid: A report of four cases. *J Foot Ankle Surg* 2000;39:329-35.
- Dhillon MS, Nagi ON. Tuberculosis of the foot and ankle. *Clin Orthop Relat Res* 2002;398:107-13.
- Vijay V, Sud A, Mehtani A. Multifocal bilateral metatarsal tuberculosis: A rare presentation. *J Foot Ankle Surg* 2015;54:112-5.
- Procopie I, Popescu EL, Huplea V, Pleșea RM, Ghelase SM, Stoica GA, et al. Osteoraticular tuberculosis-brief review of clinical morphological and therapeutic profiles. *Curr Health Sci J* 2017;43:171-90.
- Piccini P, Chiappini E, Tortoli E, de Martino M, Galli L. Clinical peculiarities of tuberculosis. *BMC Infect Dis* 2014;14:S4.
- Chen ST, Zhao LP, Dong WJ, Gu YT, Li YX, Dong LL, et al. The clinical features and bacteriological characterizations of bone and joint tuberculosis in China. *Sci Rep* 2015;5:11084.
- Talbot J, Bismil Q, Saralaya D, Newton D, Frizzel R, Shaw D. Musculoskeletal tuberculosis in Bradford a 6-year review. *Ann R Coll Surg Engl* 2007;89:405-9.
- Watts HG, Lifeso RM. Current concepts review tuberculosis of bones and joints. *J Bone Joint Surg Am* 1996;78:288-99.
- Zhang L, Wang J, Feng X, Tao Y, Yang J, Zhang S, et al. Multifocal skeletal tuberculosis: A case report. *Exp Ther Med* 2016;11:1288-92.
- Dhillon MS, Sharma S, Gill SS, Nagi ON. Tuberculosis of bones and joints of the foot: an analysis of 22 cases. *Foot Ankle* 1993;14:505-13.
- Natsis K, Grammatikopoulou D, Kokkinos P, Fouka E, Totlis T. Isolated tuberculous arthritis of the ankle: A case report and review of the literature. *Hippokratia* 2017;21:97-100.
- Gursu S, Yildirim T, Ucpinar H, Sofu H, Camurcu Y, Sahin V, et al. Long-term follow-up results of foot and ankle tuberculosis in Turkey. *J Foot Ankle Surg* 2014;53:557-61.
- Dhillon MS, Aggarwal S, Prabhakar S, Bachhal V. Tuberculosis of the foot: An osteolytic variety. *Indian J Orthop* 2012;46:206-11.
- Mittal R, Gupta V, Rastogi S. Tuberculosis of the foot. *J Bone Joint Surg Br* 1999;81:997-1000.
- Muratori F, Pezzillo F, Nizogorodcew T, Fantoni M, Visconti E, Maccauro G. Tubercular osteomyelitis of the second metatarsal: A case report. *J Foot Ankle Surg* 2011;50:577-9.
- Jain VK, Kumar D, Arya RK, Sinha S, Naik AK. Tubercular osteomyelitis of the first metatarsal bone as a cause of forefoot pain. *Foot Edinb Scotl* 2016;27:19-21.
- Martini M, Benkeddache Y, Medjani Y, Gottesman H. Tuberculosis of the upper limb joints. *Int Orthop* 1986;10:17-23.
- Miron D, El AL, Zuker M, Lumelsky D, Murph M, Floyd MM, et al. Mycobacterium fortuitum osteomyelitis of the cuboid after nail puncture wound. *Pediatr Infect Dis J* 2000;19:483-5.
- Agarwal A, Qureshi NA, Khan SA, Kumar P, Samaiya S. Tuberculosis of the foot and ankle in children. *J Orthop Surg Hong Kong* 2011;19:213-7.
- Ferguson KB, Jones CE, Thomson AG, Moir JS. A rare case of tuberculosis of the midfoot. *Foot Ankle Spec* 2012;5:327-9.
- Upadhya GK, Jain VK, Sinha S, Naik AK. Isolated calcaneocuboid joint tuberculosis: A rare case report. *Foot (Edinb)* 2013;23:169-71.
- Jeyaseelan L, Williams D, Tibrewal S, Ali SA, Hassan M, Vemulapalli K. Tuberculosis of the cuboid: A case report and review of the literature. *J Foot Ankle Surg* 2015;54:713-6.
- Vijay V, Vaishya R. Isolated C-C joint tuberculosis a diagnostic dilemma. *Foot (Edinb)* 2015;25:182-6.
- Baveja CP, Gumma VN, Jain M, Jha H. Foot ulcer caused by multidrug-resistant Mycobacterium tuberculosis in a diabetic patient. *J Med Microbiol* 2010;59 Pt 10:1247-9.
- Rasool MN. Osseous manifestations of tuberculosis in children. *J Pediatr Orthop* 2001;21:749-55.
- Gavaskar AS, Chowdary N. Tibiotalocalcaneal arthrodesis using a supracondylar femoral nail for advanced tuberculous arthritis of the ankle. *J Orthop Surg Hong Kong* 2009;17:321-4.



Conflict of Interest: Nil

Source of Support: Nil

Consent: The authors confirm that informed consent was obtained from the patient for publication of this case report

How to Cite this Article

Jeyaraman N, Jeyaraman M, Muthu S, Packkyarathinam RP. Tubercular Osteomyelitis of Cuboid. Journal of Orthopaedic Case Reports 2021 December;11(12):5-10.