

# Pyoderma gangrenosum of the breast in a patient with a history of silicone augmentation mastopexy and suction-assisted lipectomy of the trunk

Margit L. W. Juhász, MSc,<sup>a</sup> Daniel Y. Maman, MD,<sup>b</sup> Joel M. Levin, MD,<sup>c</sup> and Ellen S. Marmur, MD<sup>a,d</sup>  
*New York, New York, and Miami, Florida*

**Key words:** erythema; pyoderma gangrenosum; silicone augmentation mastopexy; ulcer.

## CASE REPORT

A 22-year-old woman with no history of autoimmune disease, inflammatory bowel disease, or malignancy presented to the emergency department with well-demarcated erythema of both breasts, right worse than left. Five days before she underwent cosmetic bilateral augmentation mastopexy with 150-mL smooth round silicone gel implants and suction-assisted lipectomy of the anterior and posterior trunk and thighs, receiving appropriate perioperative antibiotic prophylaxis with a first-generation cephalosporin. Sites of liposuction were not affected.

Erythema began on the third day after the operation, advancing from the lower pole of each breast to the inferior nipple progressing to wound dehiscence and destruction, with bloody, purulent drainage. Erythema was accompanied by fever (40.5°C), headache, increased C-reactive protein level, elevated platelet level, and left-shift leukocytosis. She had negative serologies for anti-nuclear antibodies, anticytoplasmic neutrophil antibodies and rheumatoid factor. Thyroid function tests and serum glucose were within normal limits. She underwent emergency surgery to remove both implants, debridement and irrigation of necrotic wounds with antibiotic solution, and placement of bilateral drains; samples for culture were collected (Fig 1).

Preliminary diagnosis was severe cellulitis and acute breast implant infection after augmentation mastopexy. Despite infectious disease consultation and the commencement of vancomycin, daptomycin, clindamycin, cefepime, and micafungin,

### Abbreviation used:

PG: pyoderma gangrenosum

progressive breast skin necrosis continued. There was rapid destruction on the lower pole of each breast from the areola inferiorly with wound disruption and necrotic ulcerations. Fever continued (40°C-40.6°C), and her condition did not improve. Culture specimens were negative for bacteria, acid-fast bacilli, and fungus. She was taken back to the operating room to irrigate wounds with antibiotic solution and placement of new drains; further specimens were taken for culture and pathology. Her condition continued to deteriorate.

Cultures remained sterile; pathologic tests found acute and chronic inflammation with neutrophils, fat necrosis, and stromal fibrosis. Because of her declining state and failure to respond to antibiotics, it was suspected that her condition was caused by an autoimmune phenomenon. Subsequent administration of intravenous methylprednisolone over the next 2 days caused improvement and halted progress of the lesions. She underwent one last debridement, irrigation with antibiotic solution, and placement of new drains. Lack of response to antibiotics, positive response with steroids, positive pathologic findings, and negative culture supported the diagnosis of *pyoderma gangrenosum* (PG).

Erythema and ulcerations continued to improve with administration of steroids, there was no further destruction of the skin, and

From the Department of Dermatology, Icahn School of Medicine at Mount Sinai, New York<sup>a</sup>; 5th Avenue Millennium Aesthetic Surgery, New York<sup>b</sup>; Private Practice, Miami<sup>c</sup>; and Marmur Medical, New York<sup>d</sup>

Funding sources: None.

Conflicts of interest: None declared.

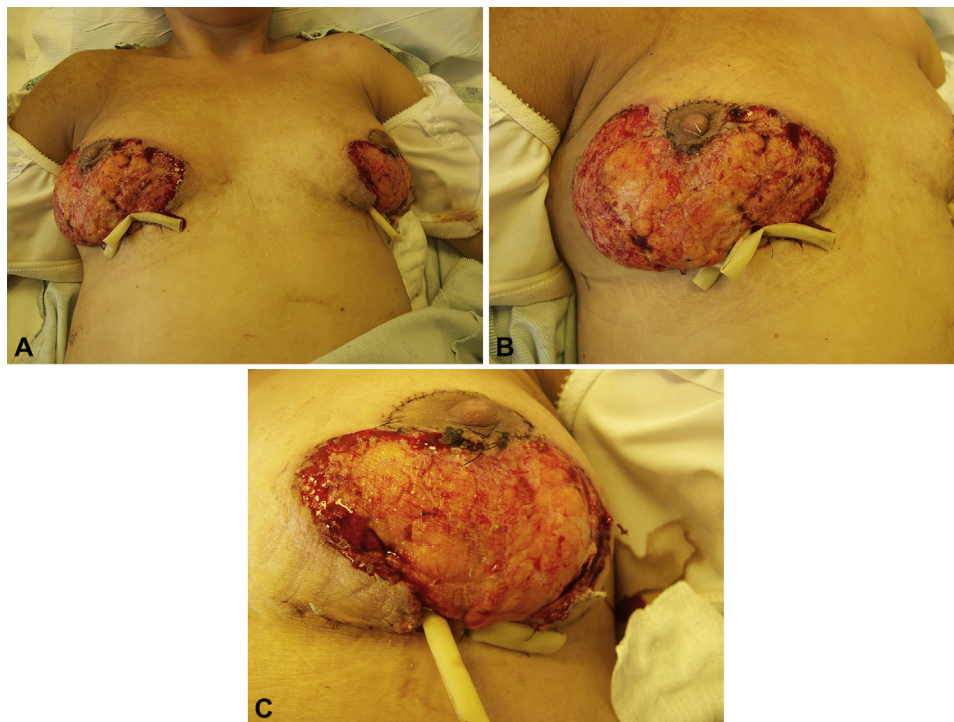
Correspondence to: Margit L. W. Juhász, MSc, 12 East 87th St, Suite 1A, New York, NY 10128. E-mail: [margit.juhasz@mssm.edu](mailto:margit.juhasz@mssm.edu).

JAAD Case Reports 2015;1:329-32.

2352-5126

© 2015 by the American Academy of Dermatology, Inc. Published by Elsevier, Inc. This is an open access article under the CC BY-NC-ND license (<http://creativecommons.org/licenses/by-nc-nd/4.0/>).

<http://dx.doi.org/10.1016/j.jidcr.2015.07.013>



**Fig 1.** Pyoderma gangrenosum of the breast after bilateral mastopexy and liposuction. After initial presentation in the emergency room, the patient underwent emergency surgery to remove the silicone gel implants, debride necrotic tissue, irrigate with antibiotic solution, and place drains. However, even when the patient was placed on broad-spectrum antibiotics and antifungals, the wounds continued to show signs of necrosis and lacked signs of granulation tissue.

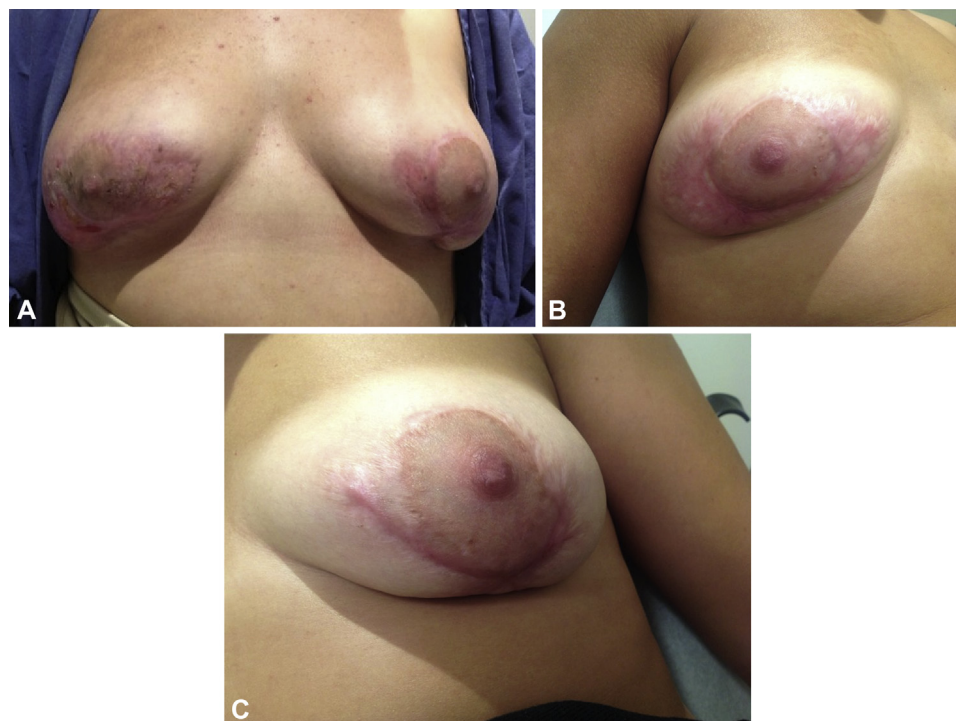granulation tissue developed. She was discharged from the hospital 9 days after admission with 30 mg oral prednisone once daily for 7 days followed by a 5-mg taper every 3 days with wet-to-dry soaks daily. Three days after discharge, drains were removed; at 6 days the patient's left breast wound sealed; and by 17 days, the right breast defect closed.

The patient was seen by the dermatology department, for the first time, 2 months later for presumed early PG of the left perioareolar breast, left areola, and the right outer breast. The patient was prescribed triamcinolone acetonide 0.1% topical cream applied twice a day 2 to 3 times a week, and mupirocin 2% topical cream applied twice daily to avoid secondary bacterial infection. A month later, the reactive area decreased and was limited to the left outer breast; the patient continued taking mupirocin with the addition of chlorhexidine 4% topical liquid to cleanse the wound twice daily. Three months later, PG of the left breast had resolved with a well-healed scar (Fig 2).

## DISCUSSION

PG is an idiopathic, destructive inflammatory disorder characterized by painful ulcerative lesions with neutrophilic infiltration in response to immune complex deposition.<sup>1-4</sup> Histopathology of full-thickness biopsies of lesions yields nonspecific findings such as edema, follicular pustules, necrosis, sterile dermal neutrophilia, mixed inflammation, hemorrhage, and lymphocytic/neutrophilic vasculitis<sup>1,2,5</sup>; wound cultures by definition are sterile; however, they may be contaminated by secondary infection.<sup>1,5</sup> Often a history suggesting pathergy, evidence of cribriform scarring, lesion progression, failure to respond to antibiotics, and response to systemic steroids are clues for diagnosis.<sup>1</sup>

PG of the breast is not uncommon postsurgically; it must be recognized early and treated appropriately to avoid associated physical and psychological morbidity (Fig 3). PG often affects breasts bilaterally and symmetrically sparing the nipple-areola complex, presumably because of differing histologic characteristics. Differential diagnosis includes



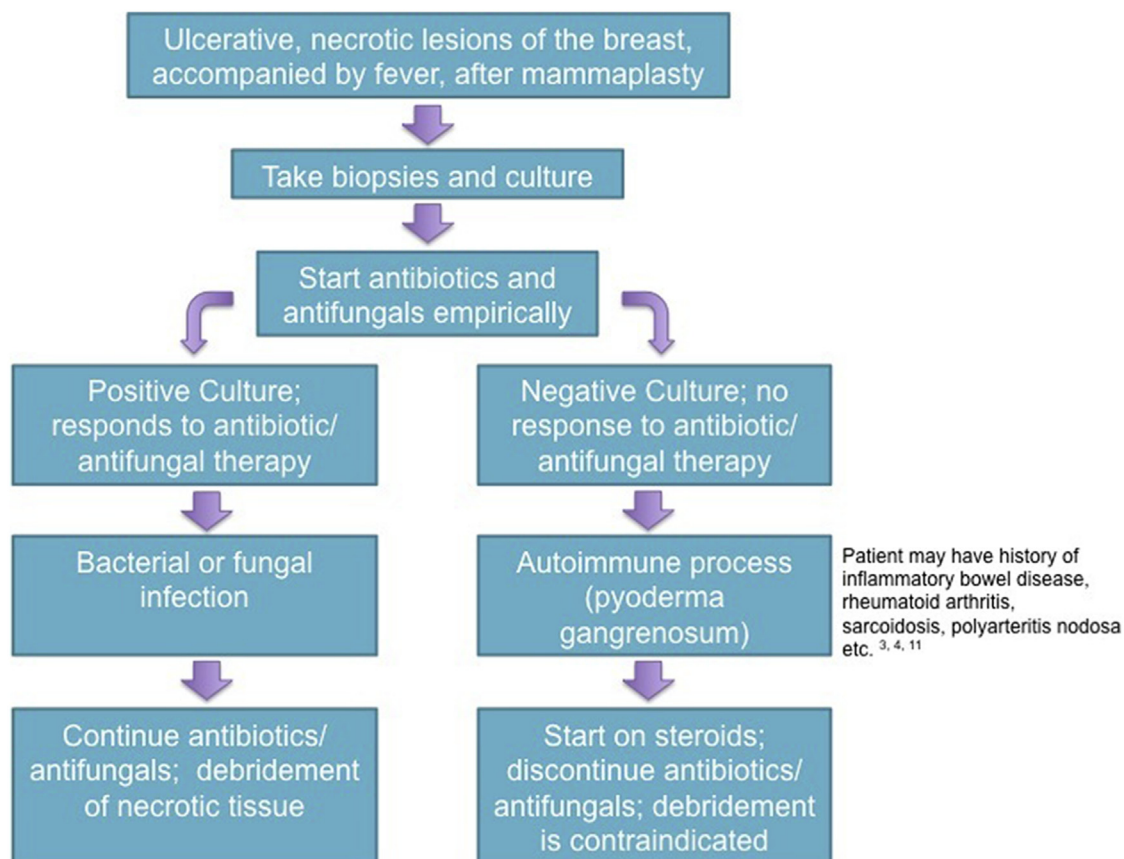
**Fig 2.** Pyoderma gangrenosum resolution. The patient's PG resolved over the course of 5 months: shown at 3 months (A) and 5.5 months (B and C) after treatment with triamcinolon acetonide 0.1% topical cream, mupirocin 2% topical cream, and chlorhexidine 4% topical liquid.

necrotizing fasciitis (positive wound cultures, crepitus, and systemic toxicity) and breast carcinoma.<sup>6</sup> Although there has been no estimate on the incidence of PG of the breast after surgery in the literature, it is widely assumed that the rate is significantly less than infection (estimated at 1%-12% after reduction mammoplasty).<sup>7-9</sup>

Of the 32 cases of PG after breast surgery reported to date, 17 have arisen from reduction mammoplasty.<sup>10</sup> It is unclear why pathergy is more common in breast reduction, but it is thought that decreased blood supply to hypertrophic breast tissue, increased skin trauma during surgical reconstruction, and growing incidence of surgery all play a role.<sup>6</sup> There is only one reported case of PG after silicone implants in the breast.<sup>11</sup> Silicone is an unlikely source instigating PG; rather, the trauma to the breast tissue during surgery causes a destructive, inflammatory reaction. Although sample size is small, trauma inflicted to the breast during surgery plays a role in the amount of time it takes for PG to develop; for instance, breast biopsies have 3 to 4 months between surgical insult and PG versus 4 to 42 days observed with reduction mammoplasty.<sup>6</sup>

PG treatment consists of 4 approaches: suppression of the exacerbating inflammation, promoting

healing, controlling pain, and treating the underlying cause (if such exists). First-line therapy consists of systemic corticosteroids or cyclosporine<sup>3,4</sup>; treatment with other immunosuppressive drugs such as mycophenolate mofetil, tacrolimus, dapsone, and azathioprine has also been described in the literature.<sup>3,12</sup> PG responds well, almost immediately halting progression. Unfortunately, lesions already present take weeks to months to heal. Antibiotics such as mezlocillin, rifampin, tetracycline, and vancomycin have been used to prevent secondary bacterial superinfection and modulate PG course secondarily as anti-inflammatories.<sup>3,4</sup> There are reports of treating PG with topical or intralesional injection of corticosteroids and other topical immunosuppressants.<sup>3</sup> One study used hydrocolloid dressing and allograft installation; however, sample size was small, and no further conclusions can be made at this time regarding their use.<sup>3</sup> Debridement is contraindicated; if a patient does require further surgery, it is suggested they be immunosuppressed and without evidence of active disease to prevent recurrence.<sup>5,10</sup> Treatment using antiseptic and dressings combined with systemic immunosuppression is advised for cases of PG.



**Fig 3.** Treatment flow for ulcerative, necrotic breast lesions after breast mammoplasty. Although infection is a much more common adverse effect after breast surgery than PG, the diagnosis of PG must still be on the forefront of surgeon's and dermatologist's minds when patients present with necrotizing ulcerations. Cultures and biopsies must be performed immediately to diagnose the lesion properly.

#### REFERENCES

- Su WP, Davis MD, Weenig RH, Powell FC, Perry HO. Pyoderma gangrenosum: clinicopathologic correlation and proposed diagnostic criteria. *Int J Dermatol*. 2004;43(11):790-800.
- Crowson AN, Mihm Jr MC, Magro C. Pyoderma gangrenosum: a review. *J Cutan Pathol*. 2003;30(2):97-107.
- Hasselmann DO, Bens G, Tilgen W, Reichrath J. Pyoderma gangrenosum: clinical presentation and outcome in 18 cases and review of the literature. *J Dtsch Dermatol Ges*. 2007;5(7):560-564.
- Duke G, Al Samaraee A, Husain A, Meggitt S, Fasih T. Pyoderma gangrenosum: a rare cause of breast ulceration. *Ochsner J*. 2012;12(2):155-158.
- Goshtasby PH, Chami RG, Johnson RM. A novel approach to the management of pyoderma gangrenosum complicating reduction mammoplasty. *Aesthet Surg J*. 2010;30(2):186-193.
- Mansur AT, Balaban D, Goktay F, Takmaz S. Pyoderma gangrenosum on the breast: a case presentation and review of the published work. *J Dermatol*. 2010;37(1):107-110.
- Stutman RL, Codner M, Mahoney A, Amei A. Comparison of breast augmentation incisions and common complications. *Aesthetic Plast Surg*. 2012;36(5):1096-1104.
- Fischer JP, Cleveland EC, Shang EK, Nelson JA, Serletti JM. Complications following reduction mammoplasty: a review of 3538 cases from the 2005-2010 NSQIP data sets. *Aesthet Surg J*. 2014;34(1):66-73.
- Hardwicke JT, Bechar J, Skillman JM. Are systemic antibiotics indicated in aesthetic breast surgery? A systematic review of the literature. *Plast Reconstr Surg*. 2013;131(6):1395-1403.
- Costa J, Monteiro D, Valenca-Filipe R, Reis J, Silva A. Pyoderma gangrenosum after breast reduction: a rare complication. *J Plast Reconstr Aesthet Surg*. 2013;66(11):e336-e337.
- Bonamigo RR, Behar PR, Beller C, Bonfa R. Pyoderma gangrenosum after silicone prosthesis implant in the breasts and facial plastic surgery. *Int J Dermatol*. 2008;47(3):289-291.
- Reichrath J, Bens G, Bonowitz A, Tilgen W. Treatment recommendations for pyoderma gangrenosum: an evidence-based review of the literature based on more than 350 patients. *J Am Acad Dermatol*. 2005;53(2):273-283.