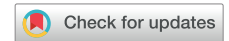

Snaring a newly placed His-bundle lead to prevent dislodgement after superiorly performed atrioventricular node ablation



Kamal Kotak, MD, FHRS, Ravi Mandapati, MD, FHRS, Jalaj Garg, MD, FHRS, Tahmeed Contractor, MD

From the Department of Cardiology, Arrhythmia Program, Loma Linda University, Loma Linda, California.

Introduction

While a staged, inferior approach is commonly utilized for atrioventricular node (AVN) ablation after device implants or upgrades, concomitant ablation via a superior approach (from the device pocket) at the time of lead placement can also be safely performed.¹ The latter strategy can shorten the overall procedure duration and laboratory occupancy time as well as prevent the need for additional vascular access.² However, lead dislodgement can rarely occur owing to interaction of the ablation catheter or sheaths with the freshly placed lead.³

Case report

A 69-year-old woman with ischemic cardiomyopathy and a dual-chamber implantable cardioverter-defibrillator underwent upgrade to a biventricular device with a His bundle (HB) lead and concomitant AVN ablation given uncontrolled heart rates with persistent atrial fibrillation. The patient was critically ill with acute renal failure and lactic acidosis; as such, to reduce the procedure duration and avoid femoral access complications, we decided to perform AVN ablation via the superior approach. After placement of the HB lead, AVN ablation was performed via the superior approach with the support of a large-curve Agilis® sheath (Abbott, Abbott Park, IL) for catheter stability. Upon attempted removal of the catheter and the sheath after ablation, there was significant interaction between the sheath and the lead; the lead would simultaneously pull back

KEY TEACHING POINTS

- Atrioventricular node ablation can be performed via a superior approach simultaneously at the time of lead placement, resulting in a shorter procedure duration with avoidance of femoral access-related complications.
- Lead dislodgement can occur if there is significant interaction between the ablation catheter or sheath and the newly placed lead. This is especially relevant in the setting of device upgrades where fibrotic tissue around existent leads can increase the likelihood of interaction.
- In cases where there is significant interaction, snaring the newly placed lead via a femoral approach can prevent lead dislodgement while removing the ablation catheter and sheath.

with attempted removal of the sheath. To prevent lead dislodgement, we used a needle's-eye snare (Cook Medical Inc, Bloomington, IN) to secure the loop of the HB lead in the right atrium (Figure 1A). Upon pulling back the Agilis sheath, the proximal lead body started to pull back; however, the snare did not allow the slack to change between the snared aspect of the lead and the tip (Figure 1B, Supplemental Video 1). The sheath was then completely removed, with no change in distal lead tip slack or lead tip position. Follow-up electrocardiogram showed nonselective his bundle capture (Supplemental Figure S1A and S1B) with stable position on echocardiography (Supplemental Figure S1C) and acceptable thresholds at 6-month follow-up (Supplemental Figure S1D).

KEYWORDS Snaring; His bundle pacing; Lead dislodgement; Atrioventricular node ablation; Superior approach
(Heart Rhythm Case Reports 2022;8:301–302)

Funding Sources: The authors have no funding sources to disclose. Conflict of Interest: Tahmeed Contractor receives speakers' honorarium from Medtronic. **Address reprint requests and correspondence:** Dr Tahmeed Contractor, Department of Cardiology, Loma Linda University, 12354 Anderson St, Loma Linda, CA 91101. E-mail address: tahmeedcontractor@gmail.com.

Discussion

While concomitant superiorly performed AVN ablation at the time of device implants is feasible,¹ fibrotic tissue around pre-existent leads in the setting of device upgrades can increase the likelihood of lead dislodgement. This is the first

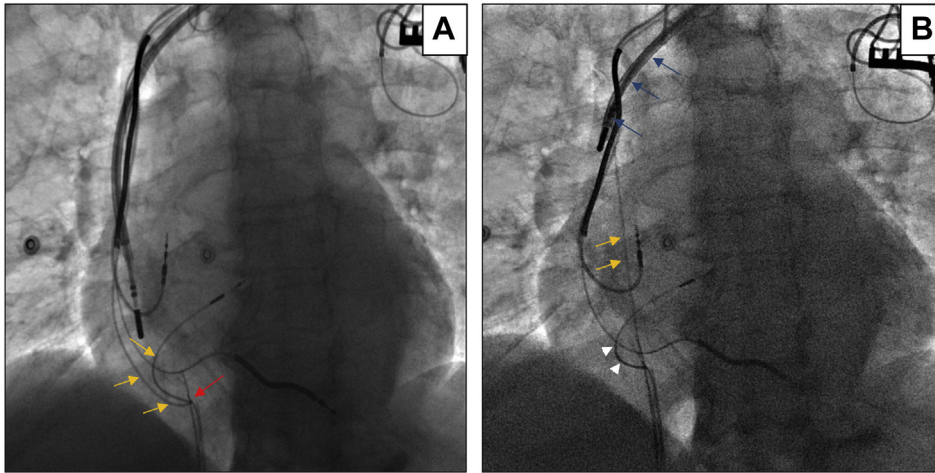


Figure 1 Removal of sheath while snaring the lead. **A:** Needle's-eye snare (*red arrow*) grasping right atrial loop of His bundle lead (*yellow arrows*). **B:** Upon pulling back the Agilis sheath (*blue arrow*), the lead also pulls back with straightening of the proximal portion of the lead until the snared aspect (*yellow arrows*), but slack is maintained between the needle's-eye snare and the lead tip (*white arrowheads*).

report of using a snare on a newly placed HB lead that prevented lead dislodgement after AVN ablation.

Appendix Supplementary data

Supplementary data associated with this article can be found in the online version at <https://doi.org/10.1016/j.hrccr.2021.12.012>.

References

1. Issa ZF, Amr BS, Laham H. Long-term follow-up in AV junction ablation via the SVC in patients undergoing concurrent device implantation: a single center experience. *Pacing Clin Electrophysiol* 2015;38:254–258.
2. Gadler F, Valzania C, Linde C. Current use of implantable electrical devices in Sweden: data from the Swedish pacemaker and implantable cardioverter-defibrillator registry. *Europace* 2014;17:69–77.
3. Worden NE, Joseph L, Iqbal OJ, et al. Outcomes with AV node ablation from the pacemaker pocket. *Ann Cardiovasc Dis* 2016;1:1003.