

[CASE REPORT]

Central Nervous System Lymphoma Harboring the JAK2 V617F Mutation That Developed after a 20-year History of Polycythemia Vera

Natsuki Kajikawa^{1,2}, Yoshimoto Seki¹, Takayuki Fujio³, Yasushi Okoshi^{3,4}, Mitsuo Hori³, Hitoaki Saito⁵, Tatsuo Iijima⁵ and Hiroshi Kojima^{4,6}

Abstract:

A 78-year-old man who had a 20-year history of polycythemia vera (PV) with a JAK2 V617F mutation presented with gradually progressive disturbance of consciousness. Hyper-intense lesions in the peri-lateral ventricular area and left cerebellar hemisphere were observed by T2-weighted and fluid-attenuated inversion recovery magnetic resonance imaging. Cytologic and genetic analyses of the lymphoma cells obtained from his cerebrospinal fluid established the diagnosis of B-cell lymphoma. No lesions outside of the brain were recognized. Because of his poor general condition, he was not treated actively. A postmortem analysis revealed a JAK2 V617F mutation in the lymphoma cells, suggesting their origin was a PV clone.

Key words: polycythemia vera, primary central nervous system lymphoma, B-cell lymphoma, JAK2 V617F mutation

(Intern Med 57: 3293-3297, 2018)

(DOI: 10.2169/internalmedicine.1093-18)

Introduction

Polycythemia vera (PV), a Philadelphia chromosome (Ph)-negative chronic myeloproliferative neoplasm (MPN), is characterized by the overproduction of mature red blood cells. The discovery of the JAK2 V617F mutation, which is detectable in more than 95% of patients with PV, has clarified the molecular pathogenesis of this disorder (1-5). Although this mutation is also detectable in approximately half of patients with essential thrombocythemia and primary myelofibrosis, the assay of V617F mutation has made the diagnosis of PV more straightforward and accurate. The V617F mutation constitutively activates the JAK-STAT, Ras-MAPK, and PI3K-Akt signaling pathways, which results in an increased expression of a class of proteins contributing to mitosis, cell-cycle progression, and anti-apoptosis (6). It is therefore generally accepted that JAK2 V617F is a gain-of-

function mutation leading to abnormal clonal proliferation of hematopoietic stem cells.

In the natural course of chronic MPNs, transformation to acute myeloid leukemia is observed in 2.3% at 10 years and 7.9% at 20 years and is associated with an extremely poor prognosis (7). Some researchers consider that therapeutic intervention with chlorambucil or hydroxyurea may affect its occurrence. Recent epidemiological studies have further revealed that the risk for developing a second malignancy, such as solid cancer and lymphoproliferative neoplasm, is increased in patients with MPN (8-10). However, the precise mechanism underlying the occurrence of second malignancy in MPN has not been well elucidated.

We herein report a patient in whom primary central nervous system lymphoma (pCNSL) developed after a 20-year history of PV with a fatal clinical course. A genetic analysis of the autopsied brain confirmed that the pCNSL observed in this patient originated from a malignant PV clone harbor-

¹Department of General Medicine, Ibaraki Prefecture Central Hospital, Japan, ²Department of Primary Care and Medical Education, Faculty of Medicine, University of Tsukuba, Japan, ³Department of Hematology, Ibaraki Prefectural Central Hospital, Japan, ⁴Ibaraki Clinical Educational and Training Center, University of Tsukuba Hospital, Japan, ⁵Department of Pathology, Ibaraki Prefecture Central Hospital, Japan and ⁶Department of Clinical Oncology, Ibaraki Prefectural Central Hospital, Japan

Received: February 28, 2018; Accepted: April 8, 2018; Advance Publication by J-STAGE: July 6, 2018

Correspondence to Dr. Hiroshi Kojima, h-kojima@chubyoin.pref.ibaraki.jp

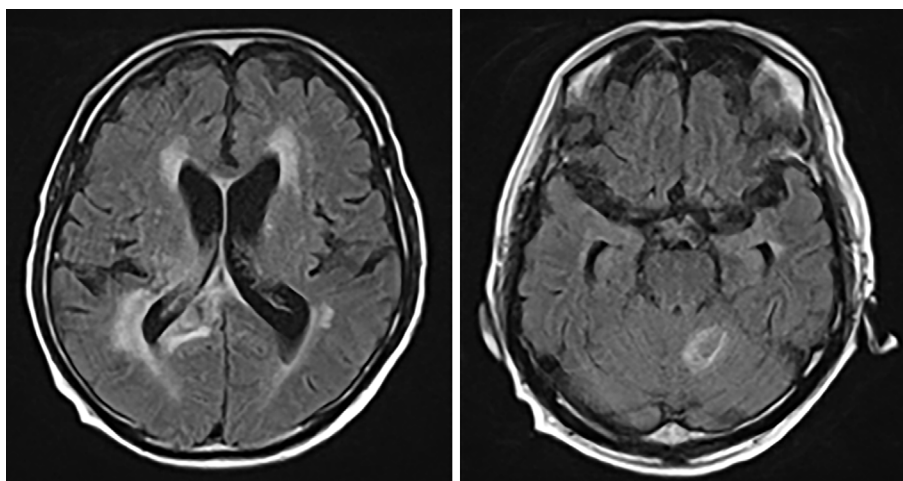


Figure 1. Brain MRI using FLAIR on admission.

ing a JAK2 V617F mutation.

Methods

Detection of the JAK2 V617F mutation

DNA was extracted from a paraffin-embedded formalin-fixed tissue block using the Maxwell[®] automated tissue DNA purification system (Promega, Madison, USA). Extracted tissue DNA or peripheral blood sample without DNA extraction was subjected to a JAK2 V617F mutation assay using the i-densy[™] fully-automated genotyping system (ARKRAY, Kyoto, Japan) following the manufacturer's instructions. The forward and reverse polymerase chain reaction (PCR) primers (5'-tgaagcagcaagtatgagcaagc-3' and 5'-gctctgagaaaggcattagaaagcctg-3') and quenching probe [5'-agta tgtttctgtggagac-(TAMRA)-3'] were prepared by Nihon Gene Research Laboratories (Sendai, Japan) and Nippon Steel & Sumikin Eco-Tech (Tokyo, Japan), respectively.

Case Report

A 78-year-old man was admitted to Ibaraki Prefectural Central Hospital because of disturbance of consciousness. He had been exhibiting headache, lightheadedness, nausea, and gradually progressive disturbance of consciousness for two weeks before admission. He had a 20-year history of PV with a JAK2 V617F mutation, which was treated with either phlebotomy or drug therapy with hydroxyurea. His medical history also included well-controlled hypertension and diabetes mellitus. His consciousness level on admission was II-30 according to the Japan Coma Scale.

A physical examination revealed an elevated body temperature (37.8°C) with no other abnormal findings. According to laboratory tests, he had a white blood cell count of 23,800/ μ L with 93.6% neutrophils, 1.7% monocytes, 4.2% lymphocytes, and 0.5% basophils; a hemoglobin level of 16.8 g/dL; a platelet count of 48.4 \times 10⁴/ μ L; a lactate dehydrogenase (LDH) level of 707 U/L (normal range: 110-240); and a CRP level of 0.40 mg/dL (normal range: less than 0.16). Analyses of the cerebrospinal fluid (CSF) demon-

strated mononuclear pleocytosis (28/ μ L), an elevated protein level (215 mg/dL), and normal glucose level (88 mg/dL). A cytological examination of the CSF revealed the infiltration of medium-size to large lymphoid cells with unevenly distributed nuclei that had the CD19+, CD56-, CD38-, and CD45- phenotype as confirmed by flow cytometry.

A hyper-intense lesion in the bilateral peri-lateral ventricular area was observed by both T2-weighted and fluid-attenuated inversion recovery magnetic resonance imaging (MRI) of the brain (Fig. 1). A similar hyper-intense lesion with a diameter of 12 mm was also observed in the left cerebellar hemisphere. Neither of these lesions exhibited contrast enhancement. Computed tomography of the chest, abdomen, and pelvis demonstrated only mild splenomegaly.

Under the tentative diagnosis of infectious encephalitis, he was treated with anti-bacterial and anti-viral drugs. However, neither culture of the CSF to detect bacterial and fungal pathogens nor PCR for herpes simplex virus or varicella-zoster virus were positive. As the immunoglobulin heavy chain gene was rearranged in cellular DNA obtained from the CSF, he was diagnosed with CNS lymphoma. An HIV test was negative. Due to his poor general condition, he was not treated actively and died on the 28th day of admission.

An autopsy was performed, which revealed the infiltration of monomorphic large-sized lymphocytes with moderately abundant cytoplasm in right peri-ventricular white matter and left cerebellar cortex (Fig. 2). The infiltrating cells were CD20(+), CD79a(+), CD3(-), CD5(-), CD10(-), κ (-), λ (+), Bcl-2(+), Bcl-6(-), and c-Myc(-) according to immunohistochemistry and Epstein-Barr virus (EBV)-encoded RNA (EBER)(+) according to fluorescence *in situ* hybridization (FISH), suggesting non-germinal center type B-cell lymphoma. As lymphoma cells were not detectable in any other organs or lymph nodes, the clinical diagnosis of pCNSL was confirmed.

To gain insight into the pathogenesis of the lymphoma, the JAK2 V617F mutation in lymphoma cells was analyzed using the i-densy[™] fully-automated genotyping system by applying the quenching probe method. A sample for the

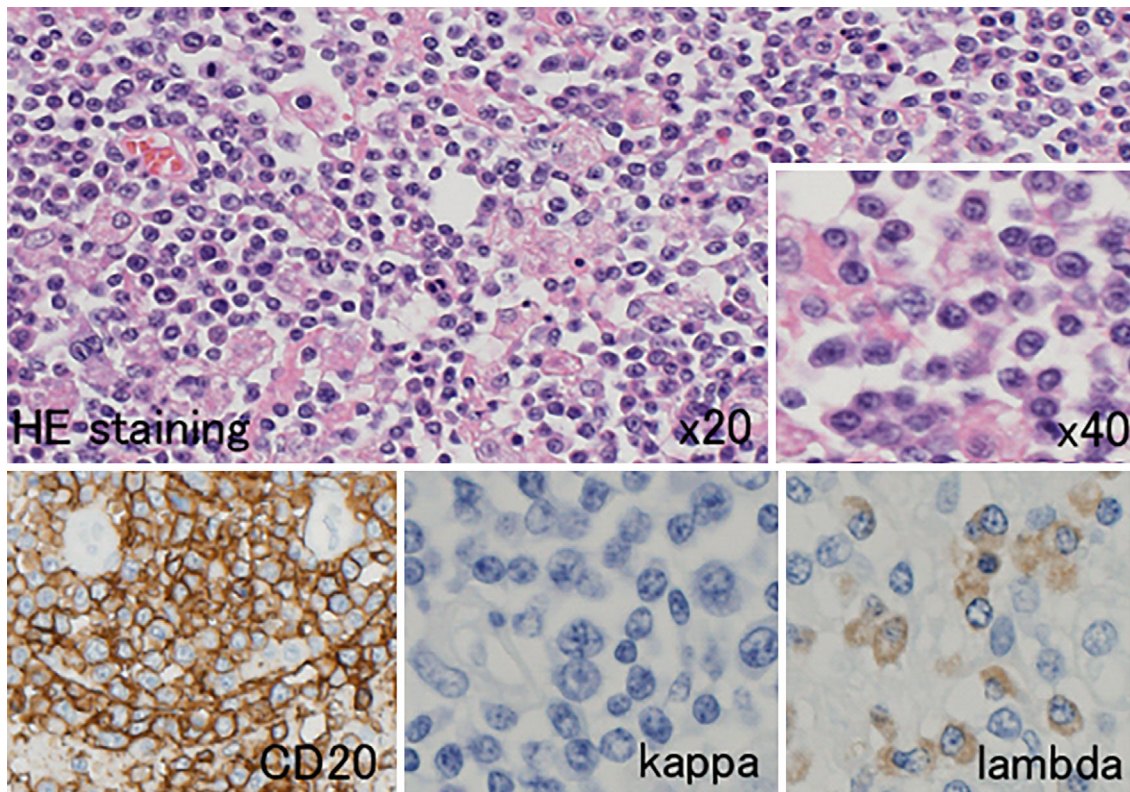


Figure 2. Pathomorphological findings of the autopsied brain. The autopsied brain sample was subjected to Hematoxylin and Eosin staining (upper panel) and immunohistochemistry (lower panel).

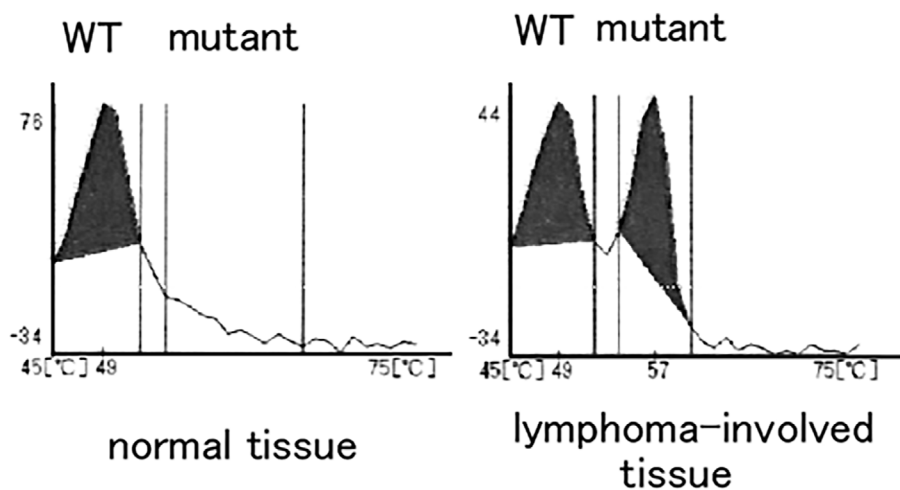


Figure 3. A JAK2 V617F mutation analysis in the lymphoma-involved brain tissue. The results of the melting curve analysis are shown. WT: wild type

negative control was obtained from the neighboring brain area with no obvious infiltration of lymphoma cells. Although we cannot completely deny the possibility of contamination with peripheral blood, the analysis by i-densyTM showed that it was highly likely that the lymphoma cells were positive for the JAK2 V617F mutation (Fig. 3).

Discussion

We report a patient with pCNSL that manifested after a 20-year history of PV with the JAK2 V617F mutation. To

gain insight into the pathogenesis of the lymphoma observed in this patient, we performed postmortem analyses of the lymphoma cells obtained from his brain. A PCR analysis revealed that the lymphoma cells possessed the JAK2 V617F mutation, suggesting that the lymphoma had originated from a lymphoid/lymphomyeloid progenitor, which was likely derived from a V617F-positive stem cell.

PV is a hematological malignancy arising from hematopoietic stem cells and was previously detected by analyzing the glucose-6-phosphate dehydrogenase isoenzymes and X-chromosome inactivation patterns (11). Whether or not

lymphoid/lymphomyeloid progenitors, as well as myeloid progenitors, are involved in the oncogenic event responsible for the development of PV remains controversial. The discovery of the JAK2 V617F mutation as a pivotal oncogenic event in PV has enabled researchers to investigate this issue. Thus far, several lines of evidence have suggested that lymphoid/lymphomyeloid progenitors with the JAK2 V617F mutation are involved in a subgroup of patients with PV (12-14). We consider our present observation to further support this conclusion.

A previous study retrospectively analyzing 9,866 patients with Ph-negative MPN found that the association with a lymphoid neoplasm is an extremely rare event, occurring in 0.3% of patients with Ph-negative MPN (15). However, a recent epidemiological study reported that the cumulative risk for developing lymphoid neoplasms in patients with Ph-negative MPN is 0.93% at 5 years and 2.96% at 10 years (16). This indicates that the risk for lymphoid neoplasm in Ph-negative MPN is 3.44-fold higher than in the general population. An increased risk of lymphoid neoplasm in patients with MPN was also confirmed by another group analyzing a different cohort (17). Notably, in JAK2 V617F-mutated MPN, the risk was reported to be even higher, reaching 5.46-fold (16). The authors of that report precisely analyzed the lymphoma cells obtained from a patient with associated mediastinal diffuse large B-cell lymphoma and V617F-mutated PV and found that the lymphoma cells also possessed this mutation, which is consistent with our present observation.

As the JAK2 V617F mutation was not detectable in a series of 117 patients with *de novo* non-Hodgkin lymphoma (18), it is unlikely that this mutation *per se* contributes to malignant transformation leading to the development of lymphoma. Although the role of the JAK2 V617F mutation in the development of lymphoid neoplasm has not been well elucidated, this gain-of-function mutation may facilitate signal transduction contributing to the proliferation of lymphoid cells. However, as the existence of the JAK2 V617F mutation in lymphoma associated with V617F-mutated MPD seems to be relatively rare, there may be another as-yet-unclarified mechanism contributing to the development of lymphoma. From this standpoint, some researchers hypothesize that chronic inflammation provoked by MPN can be a trigger and driver of malignant clonal evolution (19, 20). Indeed, a recent study further demonstrated that the incidence of non-hematological solid malignancy, irrespective of the type of cancer, is increased in patients with MPN compared to those without MPN (21). As the lymphoma cells were positive for EBER according to the FISH assay in the present patient, we also cannot deny the possibility that EBV reactivation may have contributed to the development of pCNSL.

In conclusion, we herein report the existence of the JAK2 V617F mutation in pCNSL associated with PV. Our present observation suggests the involvement of lymphoid/lymphomyeloid progenitors with the JAK2 V617F mutation in pa-

tients with MPN harboring this same mutation.

The authors state that they have no Conflict of Interest (COI).

Acknowledgement

The authors are grateful to Ms. A. Tsukui, Mr. K. Nagasu, and Ms. K. Abe for their expert technical assistance.

References

- Baxter EJ, Scott LM, Campbell PJ, et al; Cancer Genome Project. Acquired mutation of the tyrosine kinase JAK2 in human myeloproliferative disorders. *Lancet* **365**: 1054-1061, 2005.
- James C, Ugo V, Le Couédic JP, et al. A unique clonal JAK2 mutation leading to constitutive signaling causes polycythemia vera. *Nature* **434**: 1144-1148, 2005.
- Jones AV, Kreil S, Zoi K, et al. Widespread occurrence of the JAK2 V617F mutation in chronic myeloproliferative disorders. *Blood* **106**: 2162-2168, 2005.
- Kralovics R, Passamonti F, Buser AS, et al. A gain-of-function mutation of JAK2 in myeloproliferative disorders. *N Engl J Med* **352**: 1779-1790, 2005.
- Levine RL, Wadleigh M, Cools J, et al. Activating mutation in the tyrosine kinase JAK2 in polycythemia vera, essential thrombocythemia, and myeloid metaplasia with myelofibrosis. *Cancer Cell* **7**: 387-397, 2005.
- Grinfeld J, Godfrey AL. After 10 years of JAK2V617F: disease biology and current management strategies in polycythemia vera. *Blood Rev* **31**: 101-118, 2017.
- Tefferi A, Rumi E, Finazzi G, et al. Survival and prognosis among 1545 patients with contemporary polycythemia vera: an international study. *Leukemia* **27**: 1874-1881, 2013.
- Kissova J, Ovesna P, Penka M, Bulikova A, Kiss I. Second malignancies in philadelphia-negative myeloproliferative neoplasms-single-center experience. *Anticancer Res* **34**: 2489-2496, 2014.
- Khanal N, Giri S, Upadhyay S, Shostrom VK, Pathak R, Bhatt VR. Risk of second primary malignancies and survival of adult patients with polycythemia vera: a United States population-based retrospective study. *Leuk Lymphoma* **57**: 129-133, 2016.
- Masarova L, Cherry M, Newberry KJ, et al. Secondary solid tumors and lymphoma in patients with essential thrombocythemia and polycythemia vera -single center experience. *Leuk Lymphoma* **57**: 237-239, 2016.
- Pearson TC, Messinezy M, Westwood N, et al. A polycythemia vera updated: diagnosis, pathobiology, and treatment. *Hematology Am Soc Hematol Educ Program* **2000**: 51-68, 2000.
- Delhommeau F, Dupont S, Tonetti C, et al. Evidence that the JAK2 G1849T (V617F) mutation occurs in a lymphomyeloid progenitor in polycythemia vera and idiopathic myelofibrosis. *Blood* **109**: 71-77, 2007.
- Ishii T, Bruno E, Hoffman R, Xu M. Involvement of various hematopoietic-cell lineages by the JAK2V617F mutation in polycythemia vera. *Blood* **108**: 3128-3134, 2006.
- Larsen TS, Christensen JH, Hasselbalch HC, Pallisgaard N. The JAK2 V617F mutation involves B- and T-lymphocyte lineages in a subgroup of patients with Philadelphia-chromosome negative chronic myeloproliferative disorders. *Br J Haematol* **136**: 745-751, 2007.
- Masarova L, Newberry KJ, Pierce SA, et al. Association of lymphoid malignancies and Philadelphia-chromosome negative myeloproliferative neoplasms: clinical characteristics, therapy and outcome. *Leuk Res* **39**: 822-827, 2015.
- Vannucchi AM, Masala G, Antonioli E, et al. Increased risk of lymphoid neoplasms in patients with Philadelphia chromosome-negative myeloproliferative neoplasms. *Cancer Epidemiol Biomarkers Prev* **18**: 2068-2073, 2009.

17. Rumi E, Passamonti F, Elena C, et al. Increased risk of lymphoid neoplasm in patients with myeloproliferative neoplasm: a study of 1,915 patients. *Haematologica* **96**: 454-458, 2011.
18. Lee JW, Soung YH, Kim SY, et al. JAK2 V617F mutation is uncommon in non-Hodgkin lymphomas. *Leuk Lymphoma* **47**: 313-314, 2006.
19. Hasselbalch HC. Perspectives on chronic inflammation in essential thrombocythemia, polycythemia vera, and myelofibrosis: is chronic inflammation a trigger and driver of clonal evolution and development of accelerated atherosclerosis and second cancer?. *Blood* **119**: 3219-3225, 2012.
20. Skov V, Larsen TS, Thomassen M, et al. Molecular profiling of peripheral blood cells from patients with polycythemia vera and related neoplasms: identification of deregulated genes of significance for inflammation and immune surveillance. *Leuk Res* **36**: 1387-1392, 2012.
21. Frederiksen H, Farkas DK, Christiansen CF, Hasselbalch HC, Sørensen HT. Chronic myeloproliferative neoplasms and subsequent cancer risk: a Danish population-based cohort study. *Blood* **118**: 6515-6520, 2011.

The Internal Medicine is an Open Access journal distributed under the Creative Commons Attribution-NonCommercial-NoDerivatives 4.0 International License. To view the details of this license, please visit (<https://creativecommons.org/licenses/by-nc-nd/4.0/>).