



## Case report

## Unusual complication of bronchoscopy



Darius Kang Lie Aw<sup>a</sup>, Matthew Zhen Wei Tan<sup>b</sup>, Anthony Chau Ang Yii<sup>c</sup>,  
Dorothy Hui Lin Ng<sup>b,\*</sup>

<sup>a</sup> Department of General Surgery, Singapore General Hospital, Singapore

<sup>b</sup> Department of Internal Medicine, Singapore General Hospital, Singapore

<sup>c</sup> Department of Respiratory and Critical Care Medicine, Singapore General Hospital, Singapore

## ARTICLE INFO

## Article history:

Received 9 August 2016

Received in revised form

16 September 2016

Accepted 17 September 2016

## Keywords:

Bronchoscopy

Complications

Facial petechiae

## ABSTRACT

In the last twenty years, the field of bronchoscopy has become increasingly more complex and invasive. It is now widely used in the management of pulmonary diseases and has the benefit of low mortality and complication rates. Overall incidence of complications and mortality reported ranges around 1% and 0.02% respectively. Common complications of bronchoscopy include pulmonary haemorrhage, desaturation, pneumothorax, and pulmonary oedema. However, facial and neck petechiae associated with subcutaneous hemorrhage post-bronchoscopy has not been reported before in the literature.

We hereby report two novel cases of facial/neck petechiae post-bronchoscopy as a complication to be recognized by bronchoscopists.

It is essential that bronchoscopists recognise such phenomenon as the clinical presentation is visually alarming to both the patient and clinician. It is usually self-resolving. However such presentation after bronchoscopy may trigger extensive and unnecessary investigations from the physician.

© 2016 The Authors. Published by Elsevier Ltd. This is an open access article under the CC BY-NC-ND license (<http://creativecommons.org/licenses/by-nc-nd/4.0/>).

## 1. Introduction

In the last twenty years, the field of bronchoscopy has become increasingly more complex and invasive. It is now widely used in the diagnosis and management of pulmonary diseases and has the benefit of low mortality and complication rates. Complication and mortality rates range from 1.1% to 32% and 0%–0.8% respectively depending on studies [1]. Potential complications of bronchoscopy may include bleeding, desaturation, and rarely pneumothorax [1]. However, facial and neck petechiae associated with subcutaneous hemorrhage post-bronchoscopy has not been reported before in the literature.

We hereby report two unusual cases of facial/neck petechiae post-bronchoscopy as a complication to be recognized by bronchoscopists. The clinical presentation was visually alarming but

self-resolving phenomenon. We discuss the possible etiology of this complication and how it can be prevented in the future.

## 2. Case 1

A 60-year old lady, a non-smoker, non-drinker, was admitted with an exacerbation of asthma. Past medical history included allergic rhinitis, asthma with no known allergies. She was not on any anticoagulation or antiplatelet therapy.

She initially responded to nebulisation, prednisolone 30 mg daily and intensive chest physiotherapy. However, she developed a right lower lung lobe collapse was transferred to a high dependency unit for bronchoscopy to rule out foreign body obstruction and for airway toilet to re-expand the right lower lobe.

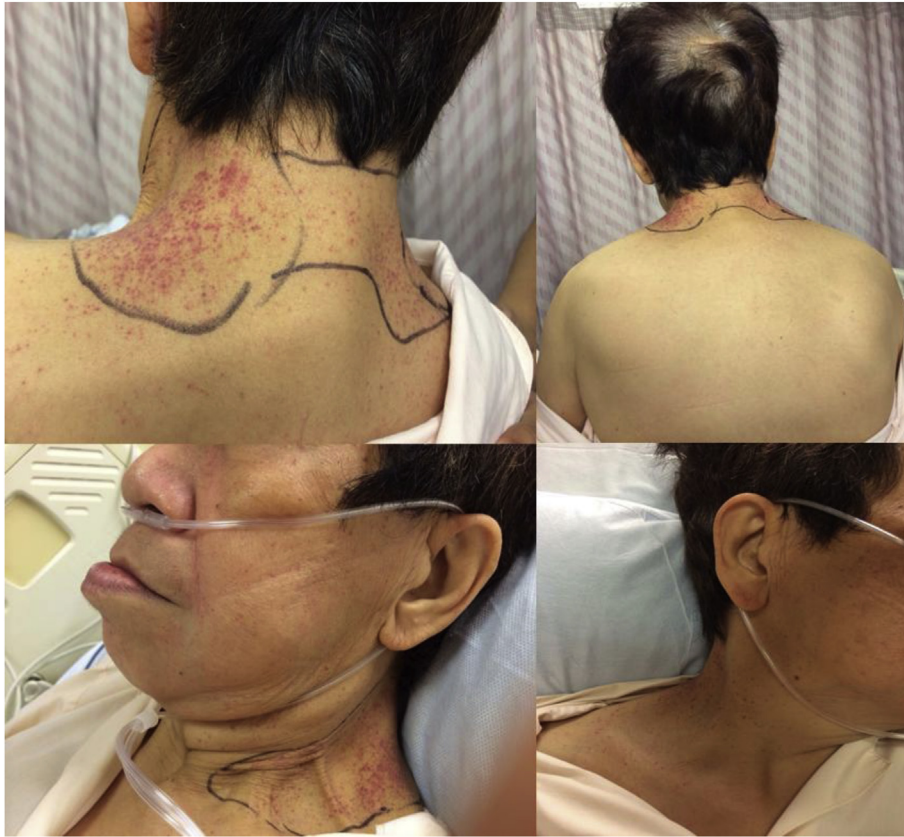Bronchoscopy via nasal intubation was performed with 5mg of intravenous midazolam, 50mcg of fentanyl. No intra-nasal lignocaine spray was used during the intubation. Dynamic airway collapse in the trachea and bronchus with copious clear mucoid secretions was seen throughout with no evidence of foreign body or stricture. The procedure took 10 minutes and was uncomplicated, apart from usual minor retching and coughing.

An hour after the bronchoscopy, a non-blanching petechial rash appeared over the face and neck, not affecting the rest of her body

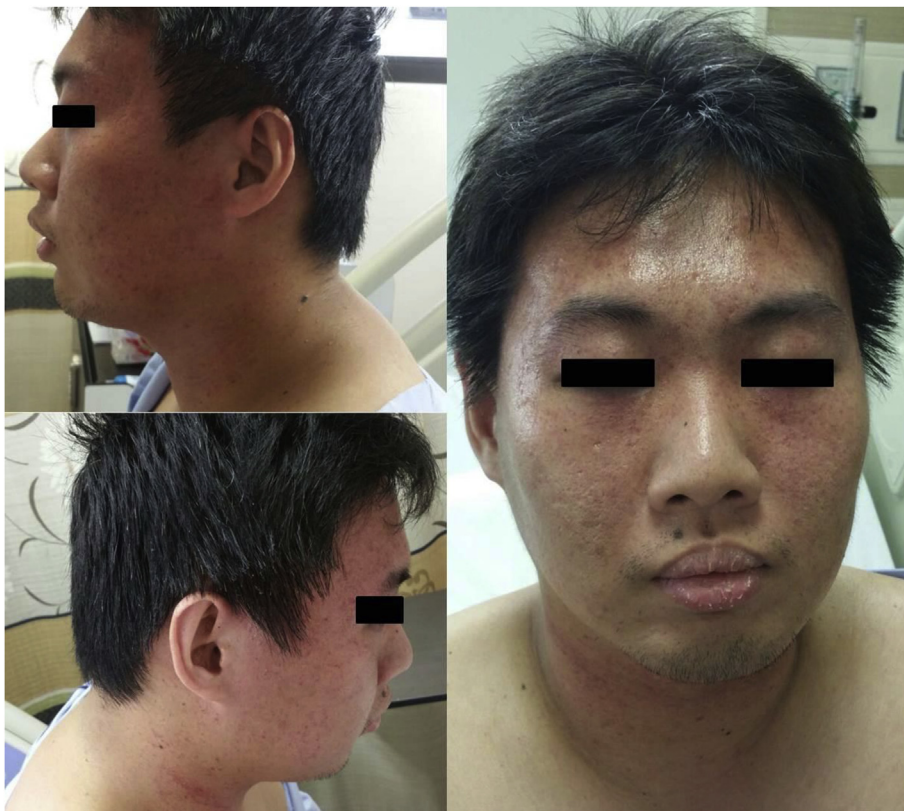
Abbreviations: COX, Cyclooxygenase; OGD, Oesophageal-gastro-duodenoscopy; FBC, Full blood count; PT, Prothrombin time; PTT, Partial thromboplastin time; Hb, Haemoglobin; INR, International normalised ratio; NSAID, Non Steroidal Anti-inflammatory Drug; CT, Computed Tomography; BAL, Bronchoalveolar lavage.

\* Corresponding author. Department of Internal Medicine, Singapore General Hospital, Outram Road, 169608, Singapore.

E-mail address: [huilin.ng@mohh.com.sg](mailto:huilin.ng@mohh.com.sg) (D.H.L. Ng).



**Fig. 1.** Non-blanching petechial rash appearing on the neck and face an hour after bronchoscopy.



**Fig. 2.** Facial and neck petechiae 2 h post-bronchoscopy in a 27-year old gentleman.

**Table 1**  
Common characteristics of endoscopic procedures that lead to report of facial or neck purpura/petechiae or subconjunctival haemorrhage.

	Pappas et al., 1984 [3]	Tóth et al., 1998 [11]	Rajvanshi and McDonald 2001 [2]	Adişen et al., 2007 [10]	Ozaslan et al., 2010 [9]	Christou et al., 2011	Yüksel et al., 2012	Balta et al., 2014
Age	32	35	59	43	31	60	73	60
Gender	Female	Female	Male	Female	Male	Male	Female	Male
Pre-existing comorbidities	None	Left sided migraine – normal CT scan	Agnoggenic myeloid metaplasia, myelofibrosis, portal hypertension	None	None	None	None	None
Procedure and indication	Gastroscopy for intermittent dysphagia of solids and liquids – antral gastritis detected	Gastroscopy for suspected haematemesis	OGD for oesophageal varices	OGD for gastritis	OGD for dyspeptic complaints	OGD for persistent dyspepsia	OGD for anaemia – antral gastritis detected	OGD
Complications	Minimal gagging	Moderate retching	Moderate retching	Aborted procedure due to appearance of rash	Repeated retching and coughing	Looked mildly strained	Coughing and retching	Not stated
Sedation	Meperidine and diazepam	Not stated	IV Midazolam (4mg) and fentanyl (100µg)	Not stated	None	IV Midazolam (2mg)	Oral lidocaine spray	Oral lidocaine spray
Use of antiplatelet /anticoagulant /NSAID	Several days' history of aminosalicic acid ingestion	None	None	None	None	None	None	None
Clotting profile	Normal platelet count, PT, bleeding time, Rumpel-Leede test	Not stated	Platelets $22 \times 10^6/\mu\text{L}$ before transfusion, $67 \times 10^6/\mu\text{L}$ after	Normal FBC, PT, PTT	Normal FBC, biochemistry, PT, PTT	Normal platelets, PT, PTT	Hb 10.3 g/, normal PT, PTT, INR	Normal FBC, PT, PTT
Characteristic of lesion	Bilateral subconjunctival haemorrhage and diffuse facial and neck petechiae	Orbital haematoma causing displacement of the left eye; ecchymosis of eyelid on left side	Bloody tears from subconjunctival haemorrhage	Facial and neck purpura; subconjunctival haemorrhage	Multiple petechiae, diffuse oedema on face, subconjunctival haemorrhage	Facial petechiae	Facial ecchymosis and purpura	Facial purpura and subconjunctival haemorrhage
Time started	'Shortly after'	Immediately after	Immediately after	During endoscopy	Immediately after	A few minutes after	A few hours after	During endoscopy
Time to resolution	10 days	By 3 weeks' follow up	7 days (at follow up)	4 days	5 days	Not stated, gradually subsided	10 days (at follow up)	5 days
Treatment	None	None	None	None	Steroid ointment on 2nd day at patient's request	Not stated	None	None

(Fig. 1). Pemberton's test was negative. She remained haemodynamically stable. Investigations revealed normal clotting, bleeding profile with stable Hb. The patient was reassured after an explanation of its benign nature. The rash had almost fully disappeared in two days.

### 3. Case 2

A 27-year old, non-smoking, non-drinking gentleman was admitted with a persistent cough and dysphonia. Three weeks prior to admission, he suffered chemical burns from a chemical leak composing of hydrogen peroxide, acetic acid and peracetic acid, which had caused inhalational injury with vocal cord chemical injury, complicated with persistent moderate to severe dysphonia.

His past medical history included hypertension controlled with oral anti-hypertensives and had no known allergies. He was not on any anti-coagulation or anti-platelet therapy.

He was treated with naproxen for cough-induced pleuritic chest pain. High-resolution CT scan showed pneumonitis and nodular infiltrates in the right lower lobe, suggestive of infection. Pulmonary function testing showed a restrictive picture. He was then started on tapering high-dose prednisolone starting from 30mg for treatment of pneumonitis. Both naproxen and prednisolone were served in the morning of bronchoscopy.

Bronchoscopy and BAL was then performed to re-inspect the airway and to rule out infection. Bronchoscopy via nasal intubation was performed with 5mg of intravenous midazolam and 5 sprays of 4.5% intra-nasal lignocaine. The vocal cords were noted to be sloughy with cord irregular nodularity but no ulceration or erythema was noted in the major tracheobronchial trees. Patient's blood pressure was stable during the procedure and was kept sedated with a mean sedation score of 2. The procedure lasted 15 mins and was uncomplicated.

Two hours after bronchoscopy, a non-blanching, non-palpable petechial rash appeared over the face and neck, with the rest of his body remaining unaffected (Fig. 2). The patient remained well and haemodynamically stable. Blood tests revealed normal clotting and bleeding profile with stable Hb. A platelet aggregation test were performed on the patient and was mildly impaired, likely secondary to the use of naproxen. Naproxen was immediately stopped. The rash subsequently improved over the next seven days.

### 4. Discussion

This case series report presents two unusual cases of facial petechiae developing in patients after bronchoscopy.

Diagnosis of endoscopy-related bleeding involves the exclusion of vasculitic, coagulopathic, neoplastic, infectious, and other causes. Common characteristics pointing to endoscopy-related bleeding include no history of vasculitis or coagulopathies; normal blood works; superficial lesions such as petechiae; predominantly facial and/or neck distribution during or soon after endoscopic procedure or natural regression of lesion within 7–10 days etc (Table 1).

COX-inhibitors prevent the formation of thromboxane A2 [13], thereby impairing thromboxane-dependent platelet aggregation and prolonging bleeding time. Both patients were given either a NSAID or COX inhibitor before the bronchoscopy.

It therefore may be a consideration to be stop short-acting NSAIDs at least one day before surgery (14,15) However, as the complication of petechiae is relatively benign, the risks of suspending these medications may outweigh any potential risk

reduction. The British Thoracic Society guidelines currently state that aspirin can be continued during diagnostic endoscopic procedures [1].

We cannot exclude other factors which would have increased their risk of facial capillary rupture during aggravation by bronchoscopy. The first patient had been undergoing intensive chest physiotherapy shortly before bronchoscopy, and the second patient was mildly hypertensive during the bronchoscopy and had poorly-controlled pre-existing cough from pneumonitis. We postulate that factors such as hypertension and incessant coughing can potentially aggravate capillary pressure. Attempts to achieve optimal control prior to bronchoscopy may be helpful in lowering the risk. Bronchoscopy can also be timed in elective cases in which procedures involving Valsalva manoeuvres, such as pulmonary function testing, should not be too closely scheduled. Using adequate sedation and local anaesthesia to suppress the gag or cough reflex may potentially reduce this risk, although this must be balanced with the risks of sedation and anaesthesia.

Although facial and neck petechiae post bronchoscopy is a rather dramatic clinical presentation, the natural history is relatively benign, self-limiting and patient would recover spontaneously and hence both physicians and patients need not be unduly alarmed. It might be a useful exercise to consider factors which could potentially contribute to this phenomenon though it is beyond the scope of this report to ascertain if this rare phenomenon can be completely pre-empted and prevented.

### Conflict of interest

The authors declare that there are no conflicts of interest.

### Source of funding

The authors received no specific funding for this work.

### Consent

Both patients gave informed consent during the hospital admission prior to their inclusion in the case reports.

### Acknowledgements

We thank the two patients for their written consent for use of their photographs.

### References

- [1] I.A. Du Rand, J. Blaikley, R. Booton, N. Chaudhuri, V. Gupta, S. Khalid, S. Mandal, J. Martin, J. Mills, N. Navani, N.M. Rahman, J.M. Wrightson, M. Munavvar, British Thoracic Society bronchoscopy guideline group. British Thoracic Society guideline for diagnostic flexible bronchoscopy in adults accredited by NICE, *Thorax* 68 (Suppl 1) (2013 Aug) i1–i44.
- [2] P. Rajvanshi, G.B. McDonald, Subconjunctival hemorrhage as a complication of endoscopy, *Gastrointest. Endosc.* 53 (2001) 251–253.
- [3] D. Pappas, J. Romeu, J. Messer, et al., Postendoscopy subconjunctival hemorrhage, *Gastrointest. Endosc.* 30 (1984) 375.
- [9] E. Ozaslan, T. Purnak, E. Senel, Facial petechiae as a complication of diagnostic endoscopy, *Acta Dermatoven APA* 19 (2010).
- [10] E. Adışen, N. Eroglu, M. Oztaş, et al., A rare cause of facial purpura: endoscopy, *Endoscopy* 39 (2007). E216–E216.
- [11] E. Tóth, U. Havelius, F. Fork, Orbital hemorrhage as a complication of gastroscopy, *Endoscopy* 30 (1998). S89–S89.
- [13] E. Liverani, S. Banerjee, W. Roberts, et al., Prednisolone exerts exquisite inhibitory properties on platelet functions, *Biochem. Pharmacol.* 83 (2012) 1364–1373.