

Therapeutic effects of CO₂ laser therapy of linear nevus sebaceous in the course of the Schimmelpenning-Feuerstein-Mims syndrome

Magdalena Kiedrowicz¹, Anna Kacalak-Rzepka¹, Andrzej Królicki¹, Romuald Maleszka¹, Stanisława Bielecka-Grzela²

¹Department of Dermatology and Venereology, Pomeranian Medical University, Szczecin, Poland

Head of Department: Prof. Romuald Maleszka MD, PhD

²Division of Aesthetic Dermatology, Pomeranian Medical University, Szczecin, Poland

Head of Division: Stanisława Bielecka-Grzela MD, PhD

Postep Derm Alergol 2013; XXX, 5: 320–323

DOI: 10.5114/pdia.2013.38363

Abstract

The Schimmelpenning-Feuerstein-Mims (SFM) syndrome is a rare phakomatosis which comprises a nevus sebaceous of Jadassohn, seizures and developmental delay associated with a wide spectrum of extracutaneous abnormalities including neurological, skeletal, ocular, cardiovascular and urogenital defects. We are presenting a case of an 18-year-old patient with systemic features of the SFM syndrome and an extensive linear nevus sebaceous partially removed with a carbon dioxide (CO₂) laser. The treatment options of skin lesions in patients with SFM are discussed.

Key words: Schimmelpenning-Feuerstein-Mims syndrome, nevus sebaceous, carbon dioxide (CO₂) laser.

Introduction

The Schimmelpenning-Feuerstein-Mims (SFM) syndrome is one of well-defined epidermal nevus syndromes, a group of disorders characterized by the association of various epidermal nevi [1]. The genetic background is still unknown. Most of the cases are sporadic without any occurrence in relatives of affected patients and without gender predominance [2]. The syndrome results from the alterations of the ectodermal and mesodermal blastoderm in initial stages of embryogenesis and the survival of the altered lethal autosomal gene in a mosaic state [3, 4]. The discordance of the SFM syndrome in monozygotic twins suggests the hypothesis of postzygotic mutation [5]. Carlson *et al.* found evidence of genomic integration of human papilloma virus (HPV) DNA in nevus sebaceous, suggesting maternal transmission of HPV and the infection of an ectodermal stem cell leading to an epigenetic mosaic and the development of skin lesions along Blaschko's lines [6].

The hallmark of the SFM syndrome is congenital, often linear nevus sebaceous, an organoid nevus showing epidermal acanthosis and hyperplasia or structural abnormalities of sebaceous glands and hair follicles [4]. The usu-

al location of nevus sebaceous is the head and neck, however, it may appear in multiple body localizations, with a midline separation and following the lines of Blaschko [3, 4, 7]. It can be present at birth or develop within the first months of life. In children, the lesion is small, flat and hairless, with a tendency to the regression of size in some cases. During puberty androgen hormones influence sebaceous gland hyperplasia and verrucous epidermal hypertrophy. The third dermatologic stage of the nevus is connected with a possibility of its malignant transformation [8].

Skin lesions are associated with a broad spectrum of systemic defects. The classic triad of symptoms, described by Schimmelpenning in 1957 and Feuerstein and Mims in 1962 includes the presence of nevus sebaceous, epilepsy and mental retardation [3]. Since these original reports, several cases have been described under distinct names, e.g. linear nevus sebaceous syndrome, SFM syndrome and Solomon syndrome [1]. Due to the coexisting multiple extracutaneous disorders, including neurologic, skeletal, cardiovascular, ocular and urologic defects, the management of patients with the SFM syndrome requires a multidisciplinary approach, including electroencephalogram, computed tomography (CT) scan or magnetic resonance imaging (MRI) of the central nervous system, radi-

Address for correspondence: Magdalena Kiedrowicz MD, Department of Skin and Veneral Diseases, Pomeranian Medical University, al. Powstańców Wlkp. 72, 70-111 Szczecin, Poland, phone/fax: +48 91 466 12 56, e-mail: magkied@poczta.onet.pl

Received: 21.10.2012, **accepted:** 10.02.2013.

ologic analysis of the entire skeleton, calcium and phosphate levels in blood and urine, analysis of the renal and liver function, followed by thorough ophthalmologic, neurologic and dermatologic examinations [4, 9].

Case report

An 18-year-old man was admitted to the department due to the extensive epidermal nevus localized on the trunk and the upper and lower extremities. The lesions were localized symmetrically, on both sides of the trunk, following the lines of Blaschko with a midline separation. The nevus has been present since his infancy and visibly continued to grow and spread with age.

The patient's mental development was delayed and as a result he was mentally challenged and handicapped to some extent. During childhood, the patient was diagnosed with Asperger's syndrome, an autism spectrum disorder, characterized by significant difficulties in social interactions, alongside restricted and repetitive patterns of behavior and interests [10]. The patient was repeatedly hospitalized in a psychiatric department due to verbal and physical acts of aggression against family members. In addition, he experienced tonic-clonic seizures from time to time, which were well-controlled by treating him with conventional antiepileptic drugs.

On admission, a linear verrucous nevus following the lines of Blaschko with concomitant pruritic erythematous and erosive lesions on the trunk and extremities was observed (Figure 1 A). A physical examination showed asthenic and the marfanoid habitus and the extension of transverse measurement of neurocranium.

On admission, the serum activity of aminotransferases, creatinine and urea levels, calcium and phosphate levels in serum and urine were normal. For the purpose of metabolic screening, several dozens of various inherited metabolic disorders and organic acidurias were excluded. The levels of lactic acid and ammonia in the serum were within normal range, succinyl purines in urea were not found, the profile of organic acids in his urea was normal.

Molecular analysis of human papilloma virus DNA in the skin sample taken from the nevus gave a negative result.

The X-ray examination of the spinal column revealed deepening of physiological cervical lordosis, thoracic scoliosis and the occurrence of *spina bifida occulta* of the first sacral vertebra. Echocardiography showed a tricuspid valve insufficiency. An ophthalmologic examination confirmed binocular myopia and astigmatism. An electroencephalogram demonstrated a generalized paroxysmal activity. The result of electromyographic examination of selected muscles suggested a mild inherited or metabolic myopathy. Magnetic resonance imaging of the brain demonstrated asymmetric vascularisation with an excessively developed right internal carotid artery and the hypoplasia of the left one.

The histopathological examination of skin lesions confirmed the diagnosis of nevus sebaceous with epidermal

hypertrophy, elongation of rete ridges with hypoplastic hair follicles, the presence of epidermal cysts and overgrown sebaceous glands (Figure 1 B).

Due to the extensiveness of skin lesions, the decision was made to remove the overgrown, frequently irritated part of the nevus from the right groin (Figure 2 A). The procedure was performed under local anesthesia with lignocaine and epinephrine. Hypertrophic tissues were partially removed with shave excision. The overgrown nodular parts of nevus were evaporated with 15-watt, 30 ms impulse duration, 30 ms impulse frequency laser beam using Normal Dream Pulse tribe. More superficial lesions were removed with 261-watt, 400 μ s impulse duration and 30 ms impulse frequency laser beam using Ultra Dream Pulse tribe. A prophylactic antibacterial topical therapy with mupirocin was performed for 2 weeks. The wound was completely healed after 3 weeks (Figure 2 B).

Discussion

The epidermal nevus syndrome comprises a group of disorders that features the presence of different epidermal nevi. In some syndromes, the type of heritability may be established, however in most cases a sporadic occurrence is found. In 1975, Solomon *et al.* analyzed the linear nevus sebaceous syndromes and their concomitant systemic disorders classifying them into one category under the com-

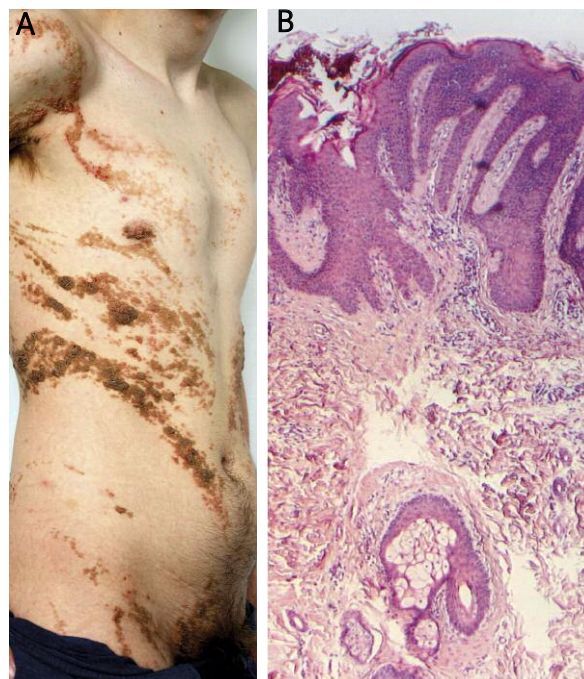


Figure 1. A – A linear verrucous nevus sebaceous following the lines of Blaschko on the trunk and extremities. B – The histopathological examination of nevus sebaceous with epidermal hypertrophy, elongation of rete ridges with hypoplastic hair follicles, the presence of epidermal cysts and sebaceous glands

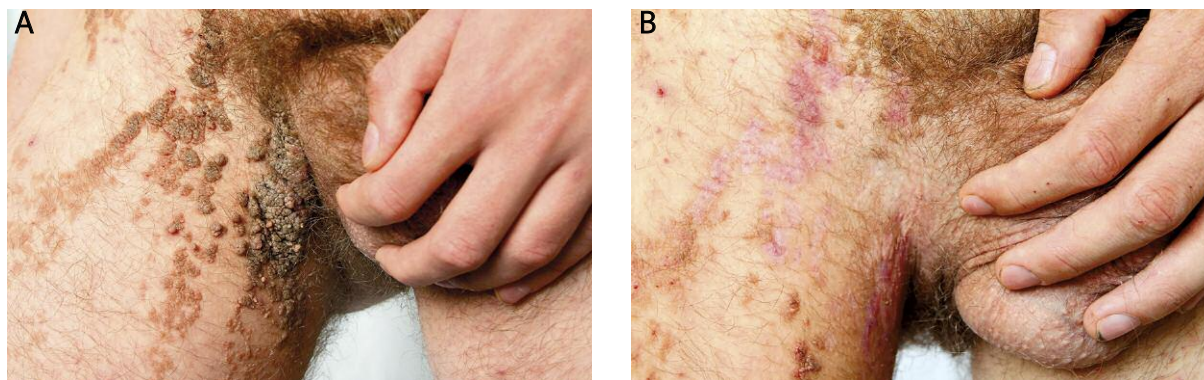


Figure 2. A – An overgrown part of the nevus sebaceous within the right groin. **B** – The partial evaporation of the nevus performed with the use of Ultra Dream Pulse CO₂ laser

mon name of epidermal nevus syndrome. A revision of the previous division was presented by Happle, with a suggestion to classify the epidermal nevus syndromes into two groups. Schimmelpenning-Feuerstein-Mims syndrome, phacomatosis pigmentokeratolica, nevus comedonicus syndrome, angora hair nevus syndrome, and Becker nevus syndrome, which feature the presence of organoid epidermal nevi were categorized into well-defined phenotypes. This category also comprises the syndromes characterized by keratinocytic nevi, including CHILD syndrome (congenital hemidysplasia with ichthyosiform nevus and limb defects), type 2 segmental Cowden disease, Proteus syndrome and fibroblast growth factor receptor 3 epidermal nevus syndrome (García-Hafner-Happle syndrome) [1].

The group of less well-defined phenotypes associated with epidermal nevi includes nevus trichilemmocysticus syndrome, didymosis aplasticosebacea, SCALP syndrome (sebaceous nevus, central nervous system malformations, aplasia cutis congenita, limbal dermoid and pigmented nevus), Gobello syndrome, Bäfverstedt syndrome, NEVADA syndrome (nevus epidermicus verrucosus with angiodysplasia and aneurysms), and CLOVE syndrome (congenital lipomatous overgrowth, vascular malformations, and epidermal nevus) [11].

The SFM syndrome comprises a nevus sebaceous and the coexistence of brain, skeletal, ocular and more rarely cardiovascular and urogenital defects. Among others, major neurological abnormalities include hemimegalencephaly, mental deficiency, cognitive deficiency, seizures, cerebral heterotopia and dysplasia of brain vessels. Bone defects comprise craniofacial abnormalities, kyphoscoliosis, dislocation of limbs and deformities of limbs. Some patients develop hypophosphatemic vitamin D-resistant rickets, which should be suspected in children older than 2 years with leg pains or who are bowlegged [1, 2, 12]. The typical ocular disorders include coloboma, corneal opacity or defects of the optic nerve. From among the extracutaneous abnormalities, tonic-clonic seizures, mental and cognitive deficiency, marfanoid habitus and the extension of trans-

verse measurement of neurocranium, thoracic scoliosis and the occurrence of *spina bifida occulta* of the first sacral vertebra, as well as the hypoplasia of the left internal carotid artery were found in our patient. Except binocular myopia and astigmatism no significant ocular abnormalities were found.

Histopathologic examination of linear nevus sebaceous reveals a wide spectrum of dermal and epidermal disturbances. The changes within the epidermis include its hyperplasia classified either as slight or prominent. Moreover, it can be subdivided as simple, verrucous, seborrheic keratosis-like and acrochordon types. Hair follicles may be absent, scant or normal in number. They may be embryotic or completely developed. Sebaceous glands may be present or absent, immature, normal in development or hyperplastic. The overgrowth of sebaceous glands was subdivided as simple, sebaceous hyperplasia-like or piriform types. Apocrine glands are present or absent [13]. In our patient the pathologist confirmed the diagnosis of nevus sebaceous on the basis of histopathological features of lesional skin biopsy specimens. However, the prominent epidermal hypertrophy and elongation of rete ridges could closely resemble that of verrucous epidermal nevus. Another misleading histological hallmark in our case was that sebaceous glands were only few in number. In the SFM syndrome the associated epidermal nevus sebaceous hyperplasia may be minimal or even absent for some reasons. The sebaceous glands may be immature before puberty because of lack of stimulating influence of androgen hormones [8]. Moreover, hyperplasia of sebaceous glands may be minimal or absent in skin biopsies of sebaceous nevus localized beyond the head and neck [14]. In one study, a verrucous pattern of epidermal hyperplasia was found in 27% of histologically examined sebaceous nevi of Jadassohn, whereas in 26% of this series the sebaceous glands were either decreased, underdeveloped or absent [13]. In the presented case, the scant number of sebaceous glands could result from localization of the tissue biopsy site (the part of nevus on the trunk) and a young age of the patient.

The removal of nevus sebaceous in the SFM syndrome remains controversial. The linear nevus sebaceous has a low malignant potential with a higher risk of the development of benign tumors, such as trichoblastoma, syringocystadenoma papilliferum, tricholemmoma, sebomatricoma, apocrine hidrocystoma or apocrine poroma, mainly in the aged patients [1, 4, 13]. The reports on basal cell carcinoma have been only sporadically documented [4]. Therefore, the cosmetic excision should be considered for aesthetic and psychological reasons, not as a cancer prophylaxis [1, 13]. A clinical observation remains an alternative to an early surgical removal of skin lesions. Various treatment methods, e.g. photodynamic therapy, dermabrasion, laser therapy and cryotherapy have been recommended, however, the only method providing a total excision and oncologic safety is a surgical removal [4, 8]. In our patient, we chose carbon dioxide laser therapy due to the extensiveness of skin lesions and the effectiveness and accessibility of the method. However, the selection of this therapeutic option requires an additional follow-up due to the risk of local relapses and malignant transformation with residual lesions.

References

1. Happle R. The group of epidermal nevus syndromes Part I. Well defined phenotypes. *J Am Acad Dermatol* 2010; 63: 1-22.
2. Menascu S, Donner EJ. Linear nevus sebaceous syndrome: case reports and review of the literature. *Pediatr Neurol* 2008; 38: 207-10.
3. Warnke PH, Hauschild A, Schimmelpenning G, et al. The sebaceous nevus as part of the Schimmelpenning-Feuerstein-Mims syndrome – an obvious phacomatosis first documented in 1927. *J Cutan Pathol* 2003; 30: 470-2.
4. Eisen DB, Michael DJ. Sebaceous lesions and their associated syndromes: part I. *J Am Acad Dermatol* 2009; 61: 549-60.
5. Rijntjes-Jacobs EG, Lopriore E, Steggerda SJ, et al. Discordance for Schimmelpenning-Feuerstein-Mims syndrome in monozygotic twins supports the concept of a postzygotic mutation. *Am J Med Genet* 2010; 152A: 2816-9.
6. Carlson JA, Cribier B, Nuovo G, Rohwedder A. Epidermodysplasia verruciformis-associated and genital-mucosal high-risk human papillomavirus DNA are prevalent in nevus sebaceous of Jadassohn. *J Am Acad Dermatol* 2008; 59: 279-94.
7. Vidaurri-de la Cruz H, Tamayo-Sánchez L, Durán-Mckinster C, et al. Epidermal nevus syndromes: clinical findings in 35 patients. *Pediatr Dermatol* 2004; 21: 432-9.
8. Sugarman JL. Epidermal nevus syndromes. *Semin Cutan Med Surg* 2007; 26: 221-30.
9. van de Warrenburg BP, van Gulik S, Renier WO, et al. The linear naevus sebaceous syndrome. *Clin Neurol Neurosurg* 1998; 100: 126-32.
10. Noterdaeme M, Wriedt E, Höhne C. Asperger's syndrome and high-functioning autism: language, motor and cognitive profiles. *Eur Child Adolesc Psychiatry* 2010; 19: 475-81.
11. Happle R. The group of epidermal nevus syndromes. Part II. Less well defined phenotypes. *J Am Acad Dermatol* 2010; 63: 25-30.
12. Happle R. Gustav Schimmelpenning and the syndrome bearing his name. *Dermatology* 2004; 209: 84-7.
13. Jaqueti G, Requena L, Sánchez Yus E. Trichoblastoma is the most common neoplasm developed in nevus sebaceous of Jadassohn: a clinicopathologic study of a series of 155 cases. *Am J Dermatopathol* 2000; 22: 108-18.
14. Happle R. Epidermal nevus syndromes. *Semin Dermatol* 1995; 14: 111-21.