



Anterior vitrectomy, phacoemulsification cataract extraction and irido-zonulo-hyaloid-vitrectomy in protracted acute angle closure crisis

Xiaowei Yu · Zhenni Zhao · Dandan Zhang · Xue Yang · Nannan Sun ·
Yixiu Lin · Jiamin Zhang · Zhigang Fan

Received: 6 January 2021 / Accepted: 19 April 2021 / Published online: 27 April 2021
© The Author(s), under exclusive licence to Springer Nature B.V. 2021

Abstract

Purpose To describe a modified surgical approach with anterior vitrectomy, phacoemulsification (phaco) cataract extraction and irido-zonulo-hyaloid-vitrectomy (IZHV) in protracted acute angle closure crisis (AACC).

Patients and methods Non-comparative, retrospective case series including 21 eyes in 19 consecutive cases of protracted AACC, which persists for at least 7 days despite maximal medical and laser therapies, were included in this study. All patients underwent a modified surgical procedure with anterior vitrectomy, phaco cataract extraction, IOL implantation, goniosynechialysis (GSL) and IZHV, using modest phaco dynamic parameters with intraocular pressure (IOP) set at 30 mmHg through the procedure using Centurion® Vision System equipped with active fluidics while the anterior vitrectomy was set at 4000

or 5000 rpm. IOP and anterior chamber space were maintained through the procedure using ophthalmic viscosurgical device (OVD) injected through paracentesis whenever the Phaco or I/A probe was withdrawn from within the anterior chamber. Medical history, visual acuity (VA), IOP and anterior and posterior segment findings were recorded and compared before and after surgical treatment.

Results The average age of all patients was 60.05 years old, while the average period of persistent AACC was 20.05 days. Preoperatively, the average IOP of all included eyes was 44.40 ± 8.42 mmHg despite maximal topical and systemic anti-glaucoma medications and/or laser surgeries, while the average VA was 1.46 ± 0.88 (log MAR). Postoperatively, IOP was well controlled in all patients with an average IOP at 12.06 ± 3.07 mmHg without any anti-glaucoma medications at follow-ups, which was decreased significantly from that in preoperative measurements ($P < 0.001$). Visual acuity was improved significantly at final follow-up with an average postoperative VA at 0.74 ± 0.77 (log MAR, $P < 0.001$). Anterior segment inflammation was surprisingly mild with no or minimal inflammatory cells or exudates. Anterior segment configuration was resolved in all the cases. There was no recurrent IOP spike, anterior chamber shallowing or severe complications during an average follow-up of 5.38 months (ranging from 3 to 6 months).

Conclusions Protracted AACC is a complex situation while a modified surgical strategy of anterior

Xiaowei Yu and Zhenni Zhao authors contributed equally to this work.

X. Yu · Z. Zhao · D. Zhang · X. Yang ·
N. Sun · Y. Lin · J. Zhang · Z. Fan
State Key Laboratory of Ophthalmology, Zhongshan
Ophthalmic Center, Sun Yat-Sen University,
Guangzhou 510060, China

Z. Fan (✉)
Tongren Eye Center, Beijing Tongren Hospital, Capital
Medical School, Beijing 100730, China
e-mail: fanzhigang@mail.ccmu.edu.cn

vitrectomy, phaco cataract extraction and IZHV provides a safe and efficient solution.

Keywords Acute angle closure crisis (AACC) · Anterior vitrectomy · Phacoemulsification · Goniosynechialysis (GSL) · Irido-zonulo-hyaloid-vitrectomy (IZHV)

Introduction

Acute angle closure crisis (AACC) is a sight-threatening ophthalmic emergency [1]. If the attack is alleviated immediately within 48 h as in most developed countries or major cities within a developing country, the conditions usually are resolved promptly. In this situation, intraocular pressure (IOP) is usually well controlled. When a phacoemulsification (phaco) cataract extraction with or without goniosynechialysis (GSL) is performed at a later timing when inflammation consequent to the AACC episode fades away, a complete recovery with good visual prognosis is achieved in most cases [2]. However, in some less privileged areas in a developing country, patients may not receive adequate or prompt treatments, due to financial stress or lack of quality medical services. We here define the term protracted AACC as an AACC that is persistent for least seven days despite medical and laser treatments [3]. During the recent Covid-19 epidemics, there is a significant increase in protracted AACC due to community seclusion and serious concerns on the risk of virus infection.

When these protracted AACC patients were referred to Zhongshan Ophthalmic Center, they are usually characterized by a very serious visual function loss, corneal edema, very shallow anterior chamber, a complete angle closure and a significantly elevated and persistent IOP plateau at the range of 40–50 mmHg despite maximal medical and laser treatments or repeated anterior chamber paracentesis. Very interestingly, a flat iris configuration under ultrasound biomicroscope (UBM) is identified in these cases, indicating a balanced pressure over the anterior and posterior chambers and excluding the presence of pupillary block. Therefore, essentially it is an overall anterior displacement of lens-iris diaphragm. Besides, anteriorly positioned ciliary processes are also observed in most cases.

In this situation, IOP stays at a significantly elevated plateau even though maximal medical treatments and/or anterior chamber paracentesis were performed. Since there is a complete obstruction of the trabecular meshwork (TM) by peripheral iris and a synechia angle occlusion due to accompanying inflammation subsequent to the AACC attack, no aqueous access is present toward the angle. Instead, aqueous can only seep backward into the vitreous cavity, misdirected and trapped, forming aqueous pockets which increase pressure of the posterior segment, condensing the anterior vitreous and pushing lens-iris diaphragm forward. Together with inflammatory infiltration subsequent to significantly elevated IOP, the formation of pathological complex pursues, which includes anterior vitreous, hyaloid, zonula and inflammatory infiltrates, and presents misdirected vitreous within the vitreous cavity from moving forward toward the angle. This is a situation of preoperative malignant glaucoma [4, 5].

To address this complicated situation of protracted AACC, we have designed a surgical strategy, which includes and follows the sequence of anterior pars plana vitrectomy (aPPV) to reduce posterior segment pressure, phaco cataract extraction and IOL implantation, GSL, in combination with IZHV [6].

Patients and methods

This was a non-comparative, retrospective case series. Twenty-one eyes of 19 protracted AACC patients were treated with surgical ophthalmic surgery in Zhongshan Ophthalmic Center from January 2019 to August 2020. The diagnosis of protracted AACC was established based on the following criteria: 1, presence of IOP with more than 21 mmHg. 2, presence of at least two of the following symptoms: ocular or periocular pain, nausea, vomiting, and antecedent history of intermittent blurred vision. 3, presence of at least three of the following signs: conjunctival congestion, corneal edema, mid-dilated non-reactive pupil and shallow anterior chamber. 4, at least 7 days of unrelieved IOP elevation despite traditional treatments, including primary laser iridotomy/iridoplasty. 5, absence of lens dislocation or serious zonulopathy, which were excluded through clinical and UBM scrutiny. 6, absence of other secondary angle closure, previous intraocular surgery or other ocular disease

histories including uveitis, retinal degeneration, retinal vascular diseases, ocular trauma and endophthalmitis. All the patients included in this study met all the criteria mentioned above.

Demographics, ocular disease history and treatment history were recorded. Visual acuity, IOP, anterior segment findings on slit-lamp examination and UBM, posterior segment findings on fundus examination and B-scan ultrasonography, visual field, axial length were evaluated, respectively. After the informed consent was obtained, all patients underwent a modified surgical procedure set, as described in more detail below. After surgery, all patients were followed up, on postoperative day one, week one, month one and at a non-standardized interval thereafter.

Surgical procedure

Prior to surgery, we prescribed systemic prednisone at 1 mg/kg, qd and topical Pred Forte (Prednisolone Acetate Ophthalmic Suspension) q2h for 3–5 days to reduce intraocular inflammation due to AACC attack, while maximum anti-glaucoma medications are used to reduce IOP. If IOP remains overly elevated, an anterior chamber (AC) paracentesis is performed in a slow and “step-by-step” fashion [7]. Using all these measurements, we maintain IOP as low as we could, though not possible in a normal or close-to-normal level prior to surgical interventions.

Usually, an intravenous infusion of 250 ml mannitol was used around 30 min before surgery. Retrobulbar blocking anesthesia is preferred in these cases to reduce intraoperative pain and further reduce IOP moderately. While temporal clear cornea incision is planned for phaco, one 23-gauge (G) pars plana cannula is placed at around 5 o'clock, 3.5 mm (not using 4 mm routinely) away from the limbus, as patients with AACC always had a shorter axial length (average 21.90 mm in our study). It should be noted that in patients with short axial length of less than 20 mm (nanophthalmos), the entry distance should be further reduced as the axial length decreases. aPPV was performed without infusion (dry vitrectomy) at 4000 or 5000 rpm and a modest phacodynamic parameters with IOP set at 30 mmHg through the procedure using Centurion® Vision System (Alcon Laboratories, Inc., USA) equipped with active fluidics, with low vacuum, and low flow parameters at double linear mode. Vitrector should always be visible under

direct microscope viewing through the lens during the entire procedure. The vitrector should move toward the vitreous and move in a circle fashion, avoiding pulling the vitreous to cause traction on the retina. Usually, a 5-s' vitrectomy was enough to reduce IOP to a normal range, which considerably eased the technical difficulty of subsequent phaco procedure. The deepening in anterior chamber was closely observed when aPPV was performed. A gentle touch on the cornea was used to confirm the endpoint of IOP. It was imperative to remember in plugging the trocar cannula or using a valved trocar prior to phaco. Sudden deepening of anterior chamber, vitreous incarceration, and potentially serious complications may occur if this critical detail was neglected. Subsequently, a 2.2-mm clear temporal corneal incision was made and 0.2 ml Trypan Blue was injected to stain the anterior lens capsule in selected cases with significantly opaque/edematous cornea. Continuous curvilinear capsulorhexis (CCC) was performed to create a 5.5 mm round and central opening under Dueviscoat. A standard procedure of phaco and intraocular lens implantation was performed using low IOP (30–36 mmHg), low flow and low vacuum settings with Alcon Centurion® Vision System. It is noted that IOL power needed to be adjusted slightly toward the overpower spectrum (adding 0.5 to 1.0 diopters) as anterior vitrectomy and restoration of IOL-iris diaphragm through IZHV made the IOL-capsule complex sit slightly backward. Carbachol was used for pupil miosis, and subsequently a viscoelastic-assisted blunt GSL was accomplished to reopen the angle. Vitrectomy at low speed (100–500 rpm) was used to make a PI opposite to the cannula-trocar entry site. The diameter of the iris opening was large enough (about 1–1.5 mm in diameter) to allow 23G vitrector cut posteriorly through zonule, hyaloid, and anterior vitreous under direct microscopic visualization. At the moment when a competent connection between anterior and posterior segments was accomplished through IZVH, it was frequently observed that inflammatory debris swarms out from behind the lens. 23G aPPV at 4000 or 5000 rpm was performed briefly through the trocar to connect the vitrectomized cavities created from the pars plana entry site and the IZHV route, allowing complete drainage of trapped aqueous inside vitreous. A bimanual I/A was performed using the 23G vitrector at cutter-off mode to clear up all inflammatory debris and viscoelasticity

left within the anterior chamber. Additionally, IOP and anterior chamber space were maintained through the procedure using ophthalmic viscosurgical device (OVD, DisCoVisc, Alcon Laboratories, Inc., USA) injected through paracentesis whenever the Phaco or I/A probe was withdrawn from within the anterior chamber. Trocar was removed and the incision was inspected for self-sealing status, with crossing suturing added using 8–0 absorbable suture if necessary. The surgery was considered successful when IOP is normal and anterior chamber is deep and stable at the end of the procedures. All surgeries were performed by one surgeon, Dr. Zhigang Fan.

Statistical analysis

All analyses were performed with SPSS version 20 (SPSS, Inc., Chicago, IL, USA). Data were presented as mean \pm standard deviation (SD). Comparison of continuous data is examined by paired-samples *t* test in normal distribution, while Mann–Whitney *U* test was used in non-normally distributed data. For all tests, *P*-values < 0.05 is considered statistically significant.

Results

Twenty-one eyes of 19 patients were included in our study at the average age of 60.05 years, six of which are males. All the patients had persistent IOP elevation prior to being referred to Zhongshan Ophthalmic Center (average 20.05 ± 15.74 days). No history of other ocular disorders was detected. Despite maximal topical and systemic IOP-lowering medications were performed in these patients, their IOP remained at a relatively elevated plateau (average 44.40 ± 8.42 mmHg) before surgical interventions. Besides, even though anterior chamber paracentesis was performed in three patients' eyes, their IOP remained at significantly elevated plateau (average 43.63 ± 9.36 mmHg). Uncontrolled IOP indicated that no aqueous access was present toward the angle in these protracted AACC patients. Visual acuity preoperatively of these patients was seriously damaged at average of 1.46 ± 0.88 in the formation of logMAR [8]. It was observed that the axial lengths of all eyes included in our study are moderately short, average at 21.90 ± 0.99 mm, and the anterior

chamber was shallow (average 1.58 ± 0.27 mm). The contralateral eyes had a significantly deeper anterior chamber (average 1.74 ± 0.28 mm, $P < 0.05$).

Postoperatively, IOP was well controlled (12.06 ± 3.07 mmHg, $P < 0.001$, Fig. 1) and VA improved significantly (0.74 ± 0.77 , $P < 0.001$, Fig. 2) in all cases at final follow-up (5.38 ± 1.16 months). No serious complications such as malignant glaucoma, choroid detachment, suprachoroidal hemorrhage, exudative retinal detachment, iris posterior synechia, endophthalmitis, or macular edema were observed during the entire follow-up periods (range 3–6 months). Detailed information is summarized in Tables 1 and 2.

Representative case (Patient 16)

This patient was a 49-year-old man, who suffered from severe ocular pain, redness, and vision loss in both eyes, accompanied by headache and vomiting. The symptoms had persisted for about 2 weeks without relief despite using anti-glaucoma eye drops prescribed at the local hospital. This was the first attack on

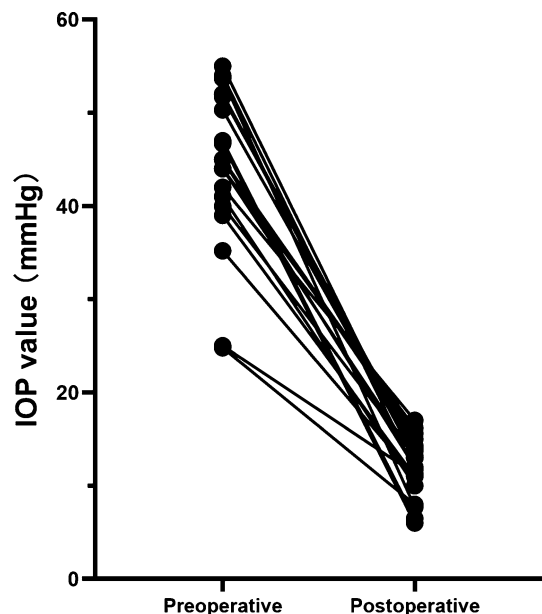


Fig. 1 The change of IOP value at preoperative and postoperative stages. The Y-axis represents IOP (mmHg) and the X-axis represent time points before (left) and after (right) surgery. Each line in the figure shows IOP change of each patient. The IOP decreased significantly for all 21 eyes after surgery at final follow-up ($P < 0.001$)

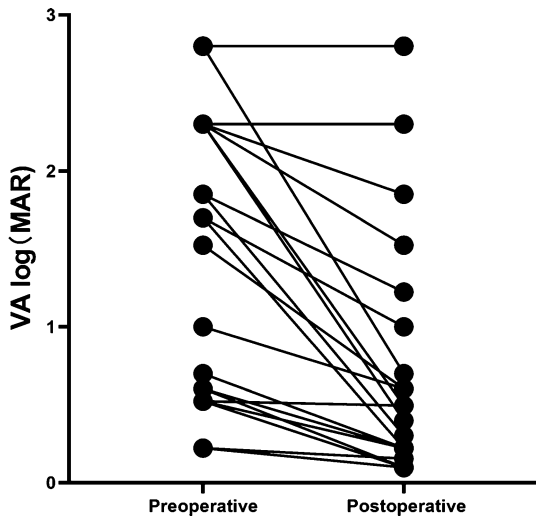


Fig. 2 The change of visual acuity (VA) at preoperative and postoperative stages. The Y-axis represents VA (logMAR) and the X-axis represents time points before (left) and after (right) surgery. Each line in the figure shows the VA change of each patient. Visual acuity improves significantly for 21 eyes postoperatively at final follow-up ($P < 0.001$)

his left eye, and he denied any medications or trauma histories of the ocular. We diagnosed him as primary AACC. The IOPs of both eyes were over 40 mmHg under maximal topical and systemic medications. Congested conjunctiva, edematous cornea, very shallow anterior chamber with optically closed peripheral angle, dilated pupil at about 7×7 mm with a dull light reflex response and lens opacity were observed. The anterior chamber depth was 1.86 mm for the right eye and 1.79 mm for the left eye, measured by UBM. No abnormality in the lens was found except cataract. Axial length was 20.03 and 20.00 mm, respectively, recorded by A-scan. VA was 0.16 and 0.1, respectively. Topical and systemic steroids were added in addition to maximal anti-glaucoma therapies. Despite all these interventions, the IOPs were still over 30 mmHg. The modified surgical intervention was performed eventless on consecutive days in each eye. On a postoperative day one, IOP was normal without anti-glaucoma medications and anterior chamber was deep with surprisingly very little or no inflammatory exudates. VAs was at 0.25 and 0.4, respectively, which improved continuously up to 0.6 in both eyes at the most recent follow-up (month 6). IOP remained normal at all postoperative follow-ups (12 mmHg

for the right eye and 13.2 mmHg for the left eye on month 6).

Discussion

Protracted AACC, defined as an AACC that is persistent for least seven days despite medical and laser treatments [3], is an ophthalmic emergency. If not adequately and promptly treated, protracted AACC finally leads to serious complications and permanent visual impairment. In this current study, to manage these complicated cases, we have designed a modified surgical strategy, which includes and follows the sequence of aPPV to reduce posterior segment pressure, phaco cataract extraction and IOL implantation, GSL, in combination with IZHV. A very modest phaco dynamic parameters with intraocular pressure (IOP) set at 30 mmHg was selected through the procedure. With this modified surgery strategy, all patients received full recovery. Elevated IOP, concurring anterior segment inflammation and structural abnormality were resolved in all the cases. Besides, no recurrences of IOP elevation or severe complications were observed after a follow-up of 3–6 months.

The protracted AACC was a unique situation in patients from less privileged regions, who was unable to get immediate and adequate medical attentions [9, 10]. In some parts of developing countries, with the latest coronavirus breakout, the number of such cases had been significantly increased, probably due to less readily available medical resources and patients' reluctance in seeking medical attention concerning virus infections. Retrospectively, we have looked into cases records of AACC from July 2017 to July 2018 in ZOC. We identified altogether 41 patients referred to us, who were treated with standard surgical intervention of phaco and intraocular lens implantation with/without GSL or trabeculectomy. Besides common findings of quite serious postoperative inflammation within anterior chamber, 6 out of those 41 patients experience postoperatively a recurrent IOP spike with persistent shallowing of anterior chamber (unpublished data). Aqueous misdirection (malignant glaucoma) was diagnosed, and at least one intervention with anterior vitrectomy was needed to correct the pathology. Upon further analyzing these 6 patients, we found that they all fell into our definition of "protracted AACC".

Table 1 Details of demographics and clinical characteristics of 21 eyes in 19 AACCC patients

No	Age (years)	Gender	Eye	Period	Axial length (mm)	ACD (mm)	Paracentesis	IOP- preoperative (mmHg)	IOP- postoperative (mmHg)	VA- preoperative	VA- postoperative	Complicants	follow-up (months)
1	61	F	L	7d	22.36	1.65	Y	42	17	0.02	0.6	N	6
2	53	F	L	7d	21.86	1.97	N	25	11.3	CF/50CM	0.06	N	6
3	56	M	R	30d	22.07	1.8	Y	53.7	7.7	0.1	0.25	N	6
4	65	M	L	7d	22.6	1.97	N	44	16.2	HM/20 cm	0.4	N	6
5	63	F	L	12d	20.34	1.41	N	47	6.5	0.02	0.1	N	6
6	66	F	L	7d	24.06	1.22	Y	35.2	11	CF/50CM	0.5	N	6
7	71	M	R	9d	22.55	1.45	N	24.8	8	HM/30 cm	CF/10 cm	N	6
8	52	F	L	12d	22.11	1.47	N	45	15.6	0.25	0.8	N	6
9	63	F	L	14d	22.48	1.74	N	55	13	0.25	0.6	N	6
10	61	F	R	31d	20.7	1.48	N	46.7	6	HM/20 cm	0.32	N	6
10	61	F	L	30d	20.67	1.86	N	51.7	14.3	LP	LP	N	6
11	59	F	R	60d	22.89	1.61	N	52	13	0.03	0.25	N	6
12	48	M	L	60d	22.45	1.71	N	52	14	0.2	0.6	N	6
13	59	M	R	20d	22.19	1.82	N	45	12	0.6	0.7	N	6
14	85	F	R	21d	22.36	0.95	N	45	15	HM/20 cm	0.03	N	6
15	50	F	L	21d	22.52	1.42	N	44	13	LP	0.6	N	6
16	49	M	L	12d	19.87	1.79	N	40	13.2	0.3	0.6	N	4
17	60	F	L	7d	21.03	1.32	N	39	11	0.6	0.8	N	3
17	60	F	R	14d	20.84	1.38	N	41	10	0.3	0.32	N	3
18	47	F	R	10d	22.1	1.83	N	54	11.7	0.3	0.8	N	4
19	72	F	R	30d	21.91	1.38	N	50.3	13.7	HM/60 cm	HM/20 cm	N	3

IOP and VA postoperative were recorded at the final follow-up

F female, M male, L left, R right, ACD anterior chamber depth, Y yes, N no, IOP intraocular pressure, CF count finger, HM hand move, VA visual acuity

Table 2 Summary of demographics and clinical characteristics of 21 eyes in 19 AACC patients

Age (yrs)	60.05 ± 9.05
Male/female	6:13
IOP-preoperative (mmHg)	44.40 ± 8.42
IOP-postoperative (mmHg)	12.06 ± 3.07
VA -preoperative (logMAR)	1.46 ± 0.88
VA -postoperative (logMAR)	0.74 ± 0.77
Follow-up (months)	5.38 ± 1.16

IOP and VA postoperative were recorded at the final follow-up
IOP intraocular pressure, VA visual acuity

We proposed here that AACC followed a continuous pathological deterioration to protracted AACC, if not treated and resolved immediately. Initially, AACC was caused by the failure of physiological aqueous flow through the pupil leading to a pressure differential between the anterior and posterior chambers (pupillary block), with anterior bowing of the peripheral iris [2] (Fig. 4), whether a non-pupillary blockage mechanism may also be present [11]. At this stage, if the patients received adequate medical treatments within 48 h, including miosis medications, IOP-control medications and anti-inflammation medications topically or systematically, or peripheral iridectomy (PI) to break the pupillary blockage, complete recovery usually followed [12]. Additionally, the accompanying inflammation was resolved quickly once elevated IOP was well controlled. Regular phaco with or without GSL at a short wait of 1–2 weeks would lead to complete recovery.

In protracted AACC that persists for at least 7 days, the scenario was quite different. The angle in protracted AACC was usually completely closed by peripheral iris, leaving aqueous humor no path to go through trabecular meshwork, except to go posteriorly and trap within the anterior vitreous cavity. In this situation, interestingly, the iris configuration was flat under UBM (Fig. 3), indicating a balanced pressure between the front and back of iris. The accumulated aqueous trapped inside vitreous compresses and condenses the anterior vitreous, leading to an elevation in posterior segment pressure and a forward movement of lens-iris diaphragm with subsequent overall shallowing of both central and peripheral anterior chamber. With persistent IOP elevation, serious

inflammatory infiltrations fill in areas of zonula, hyaloid and within condensed anterior vitreous, forming a pathological complex that makes trapped aqueous within vitreous cavity impermeable, preventing aqueous from flowing to the anterior chamber angle (Fig. 4). This was the reason why in some cases of “protracted AACC”, IOP elevation and shallow anterior chamber could not be resolved with lens extraction and GSL. This pathology conforms to the updated definition of “malignant glaucoma” [5]. Importantly, this pathology follows a course of self-exacerbation or a vicious cycle, if not properly treated, almost always leads to significant visual loss.

Clinically, the diagnosis of malignant glaucoma was based on central and peripheral shallowness of anterior chamber, the presence of a patent iridotomy (no pupillary blockage), and the absence of choroidal effusion or hemorrhage [13, 14]. Aqueous misdirection could be secondary to various clinical scenarios including blunt trauma [15], central retinal vein occlusion [16], complete ring cysts of the ciliary body [17] and cataract surgery [18], while it most frequently occurred after surgery for angle closure glaucoma, especially post-trabeculectomy [19]. A patent iridectomy within the definition of malignant glaucoma was to clarify a patent pathway of aqueous flow from posterior chamber to anterior chamber. In a pseudophakic malignant glaucoma, there is no PI and no pupillary blockage as demonstrated with a flat peripheral iris configuration. Similarly, in this condition of protracted AACC, a flat iris configuration can also be identified under UBM in all cases (Fig. 3), indicating a balanced pressure between the posterior chamber and the anterior chamber. Therefore, there is no pupillary blockage, and there is overall flattening of central and peripheral chamber, though no PI is present. Although there were no current techniques to image trapped aqueous pockets within vitreous cavity, we did observe aqueous outflow in a majority of cases. 23G trocha was inserted through the par plana, indicating the penetration of trapped aqueous pockets within vitreous cavity.

IZHV is a simple, safe, and effective procedure in the management of pseudophakic aqueous misdirection [20], and it has been advocated by many ophthalmologists as a golden standard in the management of classical malignant glaucoma [21–27]. Up to date, this is the first report about using IZVH in the management of protracted AACC. As we have

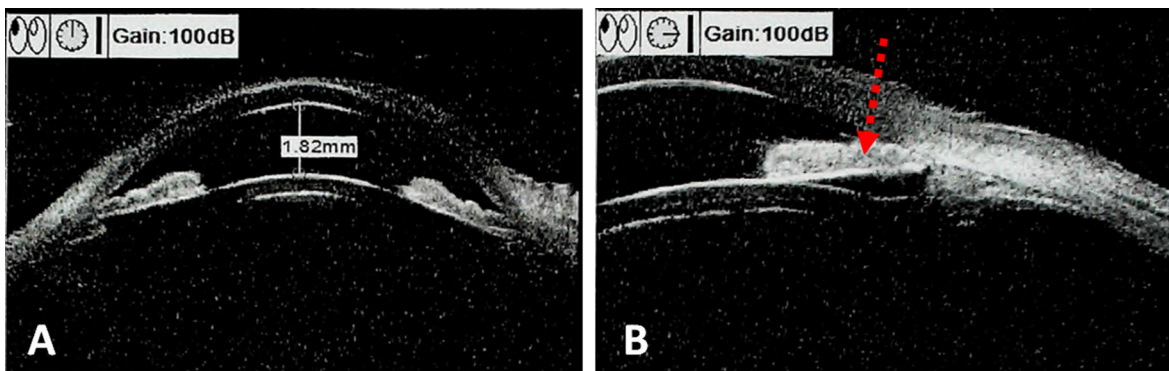


Fig. 3 An anterior segment ultrasound biomicroscope (UBM) of the right eye from patient 13. **a** Complete anterior chamber configuration. **b**: locally iris configuration. Prior to surgery,

there was a forward displacement of the iris and lens, which caused shallowing of the anterior chamber and myopization. The flat iris configuration was marked by the red arrow

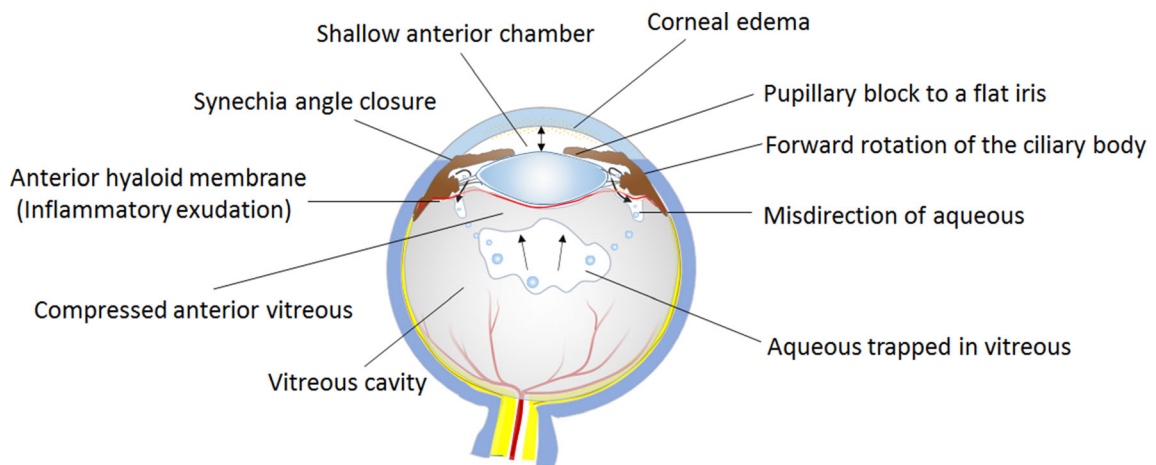


Fig. 4 Schematic of clinical characteristics in protracted acute angle closure crisis (AACC) eyes

repeatedly explained, there is preoperative malignant glaucoma in the pathophysiology of protracted AACC, which warrants the necessity of IZHV. In these “protracted AACC,” a standard IZVH, briefly a PI performed using 23G vitrector, a cut through part of zonules corresponding to the iridectomy area, and further cut through hyaloid and anterior vitreous was mandatory. In the case series by Tsai [28], either posterior capsulorrhexis or posterior capsulectomy was performed to create a communication between the anterior and the posterior segments. However, to avoid dislocation of the IOL and preserve the stability of the capsular bag, removing a few zonules was a much safer and preferred option. A full par plana vitrectomy combined with IZH was observed with no recurrence of malignant glaucoma in the study of Stalmans [26, 29]. However, total vitrectomy might be an over-

treatment if chosen in our situation, since the pathological changes happens primarily in the zonula, hyaloid and anterior vitreous. Besides, complete PPV was relatively difficult and expensive to operate, with more complications[30], while a vitreous-retina specialist is needed. With IZHV, inflammatory material accumulated within anterior vitreous cavity can be drained out completely. When IZHV is accomplished, inflammatory debris can often be observed draining out from behind the iris. These debris are aspirated completely which leads to surprisingly mild postoperative inflammatory reactions within anterior chamber comparable to that following a regular Phaco surgery. On the contrary, inflammatory infiltrates are frequently observed in regular AACC patients if the phaco surgery is not postponed for a significant period

of time or when preoperative anti-inflammatory treatment is not adequately prescribed.

In protracted AACC when all traditional medical and laser treatments fail to control IOP, there is a pathology within zonula, hyaloid and anterior vitreous [31] facilitated with inflammatory infiltrates following protracted IOP elevation. When IZHV is performed though a wide-based PI and zonula, a quite significant feel of penetration through obstacles can be felt before entrance into the hyaloid and condensed anterior vitreous. This complex pathology is in a vicious cycle of self-exacerbation, if not properly treated, with further aqueous misdirection, aqueous trapped within anterior vitreous cavity, further compression and condensing of anterior vitreous, further increase in posterior segment pressure [21], leading to further movement of lens-iris diaphragm anteriorly. This confirms the updated definition of preoperative aqueous misdirection (malignant glaucoma), while IZHV, a standard procedure for malignant glaucoma [21, 24], must be performed to establish an adequate space between the anterior and posterior ocular segments.

It is important to emphasize that a brief period of aPPV (usually in the range of around 3–5 s) should be performed before phaco, to reduce posterior segment pressure. Interestingly, we did find that in the majority of our patients, aqueous flows through trocha inserted through the pars plana, indicating penetration into cavity of trapped aqueous within anterior vitreous. If aqueous flows following trocha insertion, anterior vitrectomy is performed with finger touches over the cornea. A brief anterior vitrectomy is finalized when the IOP is around normal and anterior chamber is deepened. Following this step, phaco usually can be performed in a regular fashion.

Advanced phaco surgeons preferentially choose high IOP (bottle height), high vacuum and high aspiration (ASP) settings to obtain a very fast and smooth surgical flow and reduce ultrasound energy consumption [32, 33]. In case of protracted AACC, however, we emphasize to maintain a consistent and moderate setting of IOP around 20–30 mmHg throughout the procedure to reduce the cellular damage of retina and ensure safety throughout the surgery [34]. Additionally, OVD is injected through paracentesis whenever the phaco or I/A probe is withdrawn from within the anterior chamber to maintain a stable IOP and anterior chamber space,

which is a vital and effective tip to avoid serious surgical complications.

Although we highly recommended this modified surgical strategy to treat protracted AACC complicated with aqueous misdirection, quite many hospitals in China lack a premium vitrectomy setting or the latest mode of phaco machine equipped with high-speed 23G vitrectomy and active fluidics, such as the Alcon Centurion. For doctors in these situations, they could try vitreous tap prior to phaco. As we have mentioned previously, we observed aqueous flow from inserted trocha in a majority of our patients, indicating the penetration of trapped aqueous cavity. Theoretically, vitreous tap can achieve similar effect, although withdrawal of formed vitreous through the tap should be strictly prohibited, which proposes a very high risk of retinal breaks. All the other precautions during phaco procedure should also be followed as well.

Altogether, a sufficient and timely treatment in the early stage of AACC is critical to avoid or reverse early aqueous misdirection. When a protracted AACC develops into a stage in which all traditional medical, laser and repeated paracentesis fails to control IOP and reform the anterior chamber, we have to realize the nature of an “irreversible” aqueous misdirection is already present. A modified surgical intervention with aPPV, phaco plus IOL implantation, GSL and IZHV can achieve surprisingly good visual outcomes. It is worth emphasizing that we should not give up these “protracted AACC” cases when presented with very serious visual function conditions. These patients start with a normal eye, and they are usually treated repeated with medicine, laser or repeated paracentesis. Once the underlying pathology is corrected, many patients end up with surprisingly good prognosis.

Authors' contributions All authors contributed to the study conception and design. Material preparation, data collection and analysis were performed by Xiaowei Yu, Zhenni Zhao and Dandan Zhang. All surgeries were performed by Dr. Zhigang Fan. The first draft of the manuscript was written by Xiaowei Yu, Zhenni Zhao and Dandan Zhang, and all authors commented on previous versions of the manuscript. All authors read and approved the final manuscript.

Funding This work was supported by Guangdong Natural Science Foundation (Grant number: 2020A151501168; Guangzhou, China) and Guangzhou Science and Technology Plan Project (Grant number: 202102021099; Guangzhou, China).

Availability of data and materials All of the data, material and code in this article are available.

Code availability All of the data, material and code in this article are available.

Declarations

Conflicts of interest The authors declare that they have no conflict of interest.

Ethical approval This study was approved by the Ethics Committee of Zhongshan Ophthalmic Center. Besides, this study was performed in accordance with the ethical standards as laid down in the 1964 Declaration of Helsinki and its later amendments or comparable ethical standards.

Informed consent Informed consent was obtained from all individual participants included in the study.

Consent to publish The authors affirm that human research participants provided informed consent for publication of the images in Fig. 3. Patients signed informed consent regarding publishing their data and photographs.

References

- Collignon NJ (2005) Emergencies in glaucoma: a review. *Bull Soc Belge Ophtalmol* 296:71–81
- Ohringer G, Burke T, Shaikh A (2014) Unilateral headache and loss of vision. Acute primary angle closure glaucoma (APACG). *BMJ* 348:g1188. <https://doi.org/10.1136/bmj.g1188>
- Wang XQ, Wang XT, Zheng JJ (2012) How to end violence against doctors in China. *Lancet* 380(9842):647–648. [https://doi.org/10.1016/S0140-6736\(12\)61367-1](https://doi.org/10.1016/S0140-6736(12)61367-1)
- Prata TS, Dorairaj S, De Moraes CGV, Mehta S, Sbeity Z, Tello C, Liebmann J, Ritch R (2013) Is preoperative ciliary body and iris anatomical configuration a predictor of malignant glaucoma development? *Clin Exp Ophthalmol* 41(6):541–545. <https://doi.org/10.1111/ceo.12057>
- Luntz MH, Rosenblatt M (1987) Malignant glaucoma. *Surv Ophthalmol* 32(2):73–93
- Pathak Ray V, Gulati I, Choudhari N (2019) Intra-operative ostial irido-zonulo-hyaloido-vitreotomy with primary posterior capsulectomy for prevention of post-operative aqueous misdirection in combined phaco-trabeculectomy in primary angle closure glaucoma. *Curr Eye Res* 44(10):1087–1090. <https://doi.org/10.1080/02713683.2019.1625409>
- Carnahan MC, Platt LW (2002) Serial paracenteses in the management of acute elevations of intraocular pressure. *Ophthalmology* 109(9):1604–1606. [https://doi.org/10.1016/s0161-6420\(02\)01126-0](https://doi.org/10.1016/s0161-6420(02)01126-0)
- Schulze-Bonsel K, Feltgen N, Burau H, Hansen L, Bach M (2006) Visual acuities “hand motion” and “counting fingers” can be quantified with the freiburg visual acuity test. *Invest Ophthalmol Vis Sci* 47(3):1236–1240. <https://doi.org/10.1167/iovs.05-0981>
- Ang LP, Ang LP (2008) Current understanding of the treatment and outcome of acute primary angle-closure glaucoma: an Asian perspective. *Ann Acad Med Singap* 37(3):210–215
- Seah SK, Foster PJ, Chew PT, Jap A, Oen F, Fam HB, Lim AS (1997) Incidence of acute primary angle-closure glaucoma in Singapore. An island-wide survey. *Arch Ophthalmol* 115(11):1436–1440. <https://doi.org/10.1001/archophth.1997.01100160606014>
- Emanuel ME, Parrish RK 2nd, Gedde SJ (2014) Evidence-based management of primary angle closure glaucoma. *Curr Opin Ophthalmol* 25(2):89–92. <https://doi.org/10.1097/ICU.0000000000000028>
- Lam DS, Lai JS, Tham CC, Chua JK, Poon AS (2002) Argon laser peripheral iridoplasty versus conventional systemic medical therapy in treatment of acute primary angle-closure glaucoma: a prospective, randomized, controlled trial. *Ophthalmology* 109(9):1591–1596. [https://doi.org/10.1016/s0161-6420\(02\)01158-2](https://doi.org/10.1016/s0161-6420(02)01158-2)
- Ruben S, Tsai J, Hitchings RA (1997) Malignant glaucoma and its management. *Br J Ophthalmol* 81(2):163–167. <https://doi.org/10.1136/bjo.81.2.163>
- Kaplowitz K, Yung E, Flynn R, Tsai JC (2015) Current concepts in the treatment of vitreous block, also known as aqueous misdirection. *Surv Ophthalmol* 60(3):229–241. <https://doi.org/10.1016/j.survophthal.2014.12.004>
- Theelen T, Klevering BJ (2005) Malignant glaucoma following blunt trauma of the eye. *Ophthalmologie* 102(1):77–81. <https://doi.org/10.1007/s00347-004-1038-9>
- MA B, (1977) Transient angle-closure glaucoma in central retinal vein occlusion. *Ann Ophthalmol* 9(1):44–48
- Seki M, Fukuchi T, Yoshino T, Ueda J, Hasebe H, Ueki S, Oyama T, Fukushima A, Abe H (2014) Secondary glaucoma associated with bilateral complete ring cysts of the ciliary body. *J Glaucoma* 23(7):477–481. <https://doi.org/10.1097/IJG.0b013e31827a088c>
- Auffarth GU, Blum M, Faller U, Tetz MR, Volcker HE (2000) Relative anterior microphthalmos: morphometric analysis and its implications for cataract surgery. *Ophthalmology* 107(8):1555–1560. [https://doi.org/10.1016/s0161-6420\(00\)00240-2](https://doi.org/10.1016/s0161-6420(00)00240-2)
- Byrnes GA, Leen MM, Wong TP, Benson WE (1995) Vitrectomy for ciliary block (malignant) glaucoma. *Ophthalmology* 102(9):1308–1311. [https://doi.org/10.1016/s0161-6420\(95\)30870-6](https://doi.org/10.1016/s0161-6420(95)30870-6)
- Mohammad P, Hamed E, Nassim A, Amir V, Pooya T (2018) Mini-vitreotomy; a simple solution to a serious condition. *J Ophthal Vis Res* 13(3):231–235. https://doi.org/10.4103/jovr.jovr_192_17
- Sharma A, Sii F, Shah P, Kirkby GR (2006) Vitrectomy-phacoemulsification-vitreotomy for the management of aqueous misdirection syndromes in phakic eyes. *Ophthalmology* 113(11):1968–1973. <https://doi.org/10.1016/j.ophtha.2006.04.031>
- Lois N, Wong D, Groenewald C (2001) New surgical approach in the management of pseudophakic malignant glaucoma. *Ophthalmology* 108(4):780–783. [https://doi.org/10.1016/s0161-6420\(00\)00642-4](https://doi.org/10.1016/s0161-6420(00)00642-4)

23. Tang J, Du E, Li X (2018) Combined surgical techniques for the management of malignant glaucoma. *J Ophthalmol* 2018:9189585. <https://doi.org/10.1155/2018/9189585>
24. Basgil Pasaoglu I, Altan C, Bayraktar S, Satana B, Basarir B (2012) Surgical management of pseudophakic malignant glaucoma via anterior segment-peripheral iridectomy capsulo-hyaloidectomy and anterior vitrectomy. *Case Rep Ophthalmol Med* 2012:794938. <https://doi.org/10.1155/2012/794938>
25. Krpt L, Emaitien R, Miliauskas A (2018) Clinical characteristics and outcomes of malignant glaucoma after different procedures treated with pars plana vitrectomy: a 10-year retrospective study. *Medicina* 54(4):65. <https://doi.org/10.3390/medicina54040065>
26. Srishti R, Faisal T, Gunjan J, Natasha G, Seth S (2019) Treatment outcomes and efficacy of pars plana vitrectomy-hyaloidotomy-zonulectomy-iridotomy in malignant glaucoma. *Eur J Ophthalmol* 31(1):234–239. <https://doi.org/10.1177/1120672119877139>
27. Patel S (2019) Pars plana vitrectomy combined with iridozonulo-hyaloidectomy for aqueous misdirection. *Eur J Ophthalmol* 30(2):112067211987205
28. Tsai JC, Barton KA, Miller MH, Khaw PT, Hitchings RA (1997) Surgical results in malignant glaucoma refractory to medical or laser therapy. *Eye (Lond)* 11(Pt 5):677–681. <https://doi.org/10.1038/eye.1997.176>
29. Debrouwere V, Stalmans P, Van Calster J, Spileers W, Zeyen T, Stalmans I (2012) Outcomes of different management options for malignant glaucoma: a retrospective study. *Graefes Arch Clin Exp Ophthalmol* 250(1):131–141. <https://doi.org/10.1007/s00417-011-1763-0>
30. Zarnowski T, Rekas M (2014) Efficacy and safety of a new surgical method to treat malignant glaucoma in pseudophakia: reply. *Eye (Lond)* 28(11):1391–1392. <https://doi.org/10.1038/eye.2014.188>
31. Cashwell LF, Martin TJ (1992) Malignant glaucoma after laser iridotomy. *Ophthalmology* 99(5):651–658. [https://doi.org/10.1016/s0161-6420\(92\)31913-x](https://doi.org/10.1016/s0161-6420(92)31913-x) (discussion 658–659)
32. Schriebl SM, Stifter E, Menapace R (2014) Impact of low versus high fluidic settings on the efficacy and safety of phacoemulsification. *Acta Ophthalmol* 92(6):e454–e457. <https://doi.org/10.1111/aos.12200>
33. Ting DSJ, Rees J, Ng JY, Allen D, Steel DHW (2017) Effect of high-vacuum setting on phacoemulsification efficiency. *J Cataract Refract Surg* 43(9):1135–1139. <https://doi.org/10.1016/j.jcrs.2017.09.001>
34. Zhao Z, Yu X, Yang X, Zhang J, Zhang D, Sun N, Fan Z (2020) Elevated intraocular pressure causes cellular and molecular retinal injuries, advocating a more moderate intraocular pressure setting during phacoemulsification surgery. *Int Ophthalmol*. <https://doi.org/10.1007/s10792-020-01519-w>

Publisher's Note Springer Nature remains neutral with regard to jurisdictional claims in published maps and institutional affiliations.