

# Cavernous Sinus Angioleiomyoma: Case Report and Review of the Literature

Yu Teranishi<sup>1</sup> Michihiro Kohno<sup>1</sup> Shigeo Sora<sup>1</sup> Hiroaki Sato<sup>1</sup> Munehiro Yokoyama<sup>2</sup>

<sup>1</sup>Department of Neurosurgery and Stroke Center, Tokyo Metropolitan Police Hospital, Tokyo, Japan

<sup>2</sup>Department of Pathology, Tokyo Metropolitan Police Hospital, Tokyo, Japan

Address for correspondence Yu Teranishi, MD, Department of Neurosurgery and Stroke Center, Tokyo Metropolitan Police Hospital, 4-22-1, Nakano, Nakano-ku, Tokyo, Japan (e-mail: eugeneterra@me.com).

J Neurol Surg Rep 2014;75:e122–e128.

## Abstract

Cavernous sinus angioleiomyoma (ALM) is extremely rare. Only three cases have been reported to be cavernous sinus ALM, and very few reports described characteristic findings for intracranial ALMs in detail. We report a new case of cavernous sinus ALM, with detailed information on the clinical presentation, radiology, pathology, and surgical approach. A 52-year-old woman had a 6-month history of right eye discomfort. Magnetic resonance imaging showed a right cavernous sinus tumor with heterogenous blush enhancement. Enhanced computed tomography scans and angiography showed small nodular enhancement in the tumor. Complete tumor resection was achieved via an extradural temporopolar approach. ALM was identified based on histologic examination. Intracranial ALMs are different from the ALMs that occur in the extremities based on our review of the literature. Intracranial ALMs appear more frequently in men than women. The cavernous type was the most common pathologically, and they occur often in the epidural location. Because cavernous sinus ALM occurs in the interdural space, an epidural approach should be selected. Therefore, it is important to include cavernous sinus ALM into a differential diagnosis of a cavernous sinus tumor. The blush enhancement and nodular enhancement within this lesion may be useful to distinguish cavernous sinus ALM from other differential diagnoses.

## Keywords

- ▶ angioleiomyoma
- ▶ cavernous sinus
- ▶ hemangioma

## Introduction

Angioleiomyoma (ALM) is a soft tissue tumor that occurs most often in the skin and subcutaneous tissue in the lower extremities. Cavernous sinus ALM is extremely rare; so far only three cases have been reported as cavernous sinus ALM.<sup>1–3</sup> We present a new case of cavernous sinus ALM with an emphasis on clinical data, differential diagnosis, pathologic findings, and surgical approach. We also report new information, to the best of our knowledge, on radiologic findings.

## Case Report

### History and Examination

A 52-year-old woman visited a nearby hospital for a 6-month history of right eye discomfort. She was referred to our

hospital for further examination and treatment. Her symptom was occurred gradually, without visual field defect and diplopia. The physical examination revealed no paralysis of cranial nerves III, IV, and VI. There was also no facial paresthesia. Ophthalmology examination revealed normal visual acuity in both eyes, and no visual field defect was found by visual field test.

Contrast-enhanced magnetic resonance imaging (MRI) of the brain showed an enhancing tumor arising from the right cavernous sinus. The diameter of the tumor was 23 mm. It was isointense on axial T1-weighted MRI scan, hyperintense on axial T2-weighted scan, and heterogeneously enhanced on contrast-enhanced MRI (▶ Fig. 1A–C). The tumor eroded the superior orbital fissure, optic canal, and it deviated the optic nerve medially. This tumor was hypointense on axial diffusion-weighted images and coronal hyperintense on

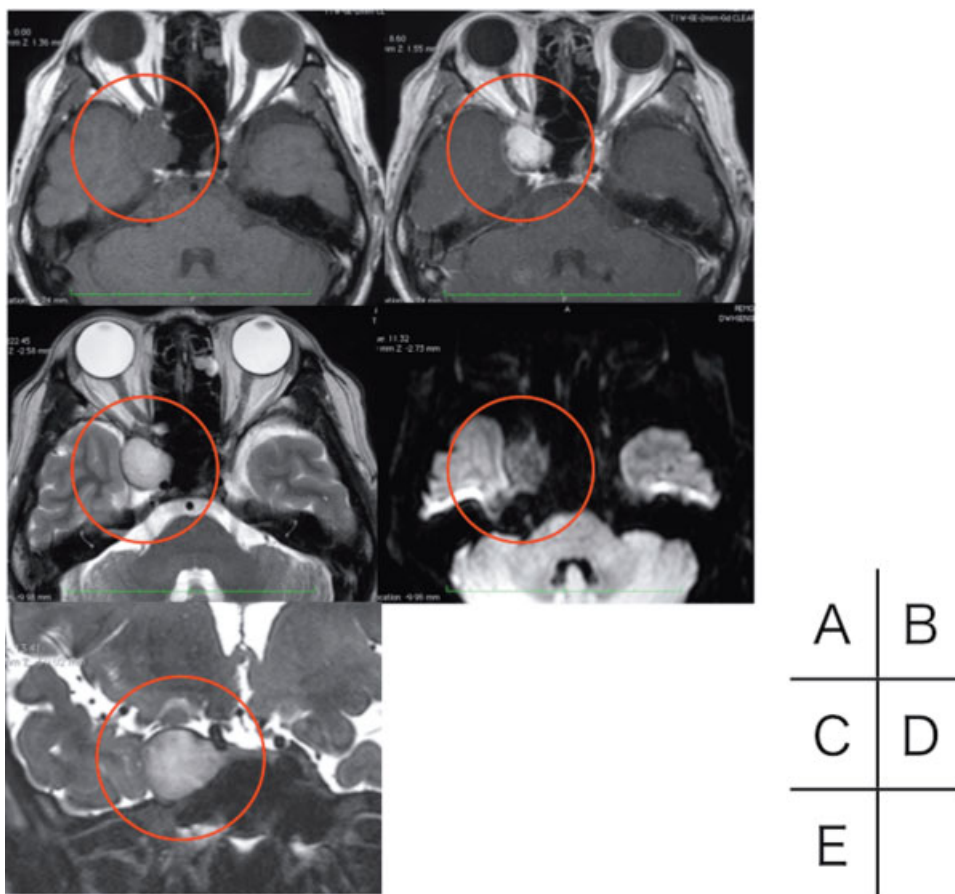
received  
October 5, 2013  
accepted after revision  
March 15, 2014  
published online  
June 4, 2014

DOI <http://dx.doi.org/10.1055/s-0034-1376425>.  
ISSN 2193-6358.

© 2014 Georg Thieme Verlag KG  
Stuttgart · New York

License terms





**Fig. 1** Preoperative magnetic resonance imaging findings. (A) Axial T1: The lesion showed isointensity. (B) Contrast-enhanced axial T1: The lesion showed heterogenous enhancement. (C) Axial T2: The lesion showed hyperintensity. (D) Axial diffusion-weighted image: The lesion showed hypointensity. (E) Coronal constructive interference in a steady state: The lesion revealed that the tumor was located between the layers of the lateral wall of the cavernous sinus. Note the tumor (circle).

constructive interference in a steady state (CISS) image (►Fig. 1D, E). CISS imaging indicated that the tumor was located between the layers of the lateral wall of the cavernous sinus. There was no tumor extension into Meckel cave. A bone computed tomography indicated no erosion of the foramen ovale or the foramen rotundum. There was no calcification in the tumor. According to these findings, the lesion was suspected to be a trigeminal schwannoma arising from V1, or an oculomotor nerve schwannoma.

### Operation

The patient underwent tumor resection via an extradural temporopolar approach with lumbar drainage. After frontotemporal craniotomy and elevation of the dura propria, we found the tumor was located between the layers of the lateral wall of the cavernous sinus. The tumor was elastic, dark red, vascularized, and bled easily. We debulked the tumor continuously using bipolar coagulation. After the tumor was resected completely, hemostatic agents were applied.

### Pathologic Findings

The tumor tissue was stained with hematoxylin and eosin (H & E) and other immunohistochemical stains. The tumor was composed of dilated vascular channels with spindle cells

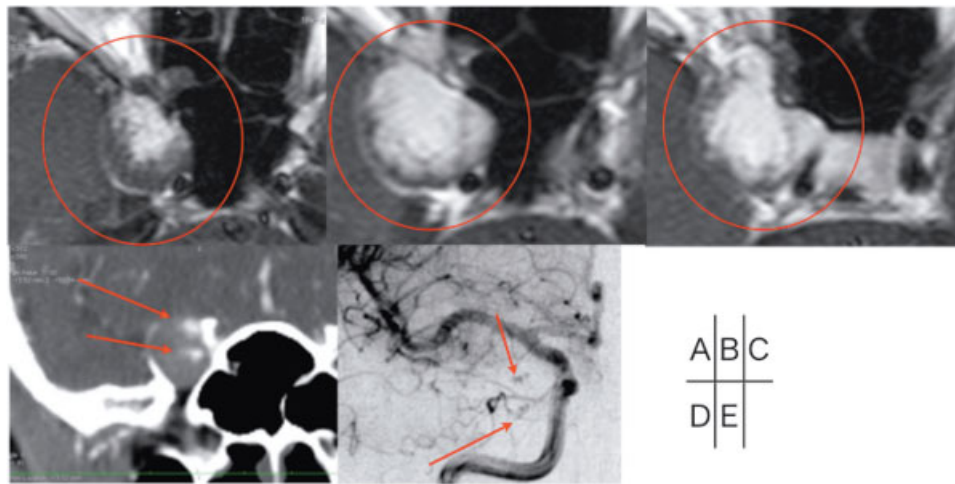
(►Fig. 2A–C). In terms of immunohistochemical studies, only endothelial cells were positive for CD34, whereas spindle cells were negative for CD34 (►Fig. 2D). These spindle cells were positive for  $\alpha$ SMA, h-Caldesmon, and calponin but were negative for EMA and S100 (►Fig. 2E–G). Based on these pathologic findings, the tumor was diagnosed as a cavernous type of ALM.

### Postoperative Course

After the operation, the patient presented with right abducens nerve palsy and diplopia. Except for these symptoms, the postoperative course was good. These symptoms improved completely in 2 weeks. Postoperative computed tomography (CT) and MRI indicated a complete tumor resection had been achieved (►Fig. 3).

### Discussion

ALMs are soft tissue tumors that occur commonly in the skin and subcutaneous tissue in the lower extremities. According to Hachisuga et al,<sup>4</sup> the tumor appears in middle-age individuals, mostly women. Cavernous sinus ALM is extremely rare; so far only three cases have been reported as cavernous sinus ALM.<sup>1–3</sup> Very few reports have described characteristic

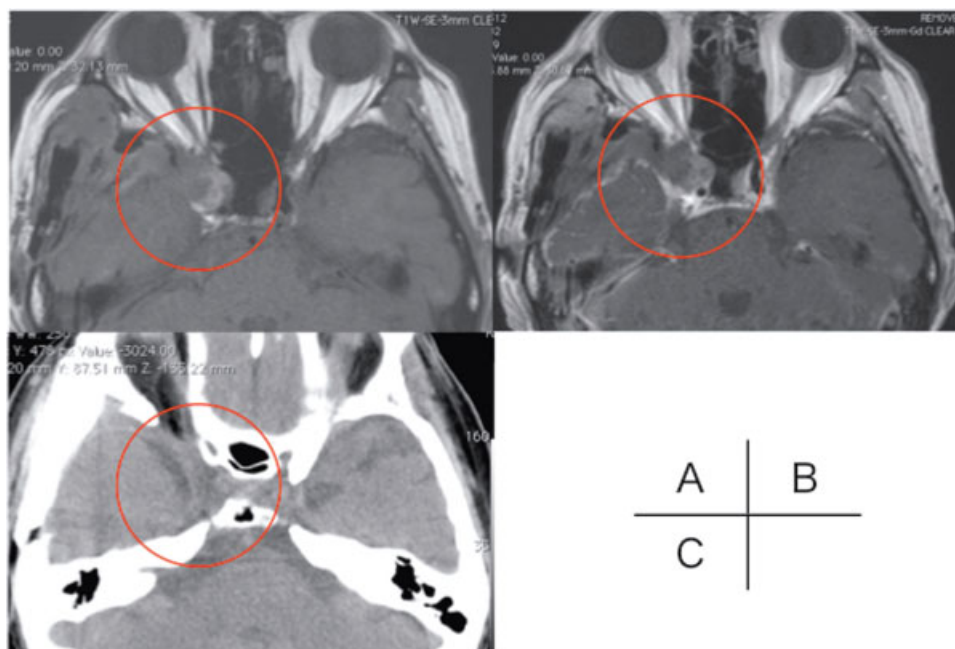


**Fig. 2** Pathologic findings. (A–C) Dilated vascular channels intermingled with smooth muscle bundles (hematoxylin and eosin,  $\times 100$ ,  $\times 400$ ). (D) Endothelial cells showing strong positivity for CD34 (immunohistochemistry,  $\times 400$ ). (E–G) Smooth muscle bundles showing strong positivity for Calponin, h-Caldesmon, and  $\alpha$ SMA (immunohistochemistry,  $\times 400$ ). (H) Ki-67 index was 2.1%.

findings for intracranial ALMs in detail. ► **Tables 1, 2, and 3** summarize the clinical, radiologic, surgical, and pathologic findings in all previous reports about intracranial ALMs including our case.<sup>1–3,5–13</sup> The data reviewed here show that intracranial ALMs were more frequently found in men (9 cases: men, 3 cases: women; 1 case: unknown) than in women in contrast to extremity ALMs (Table 1). The average age was 43.5 years (standard deviation [SD]:16). In terms of dural attachment, 11 cases were found in the extradural location or in the peridural location, and 3 cases appeared in the subdural location (Table 1). In all cases, surgical intervention was performed (12 cases: gross total resection; 1 case: subtotal resection; 1 case: biopsy). The symptom and

its duration varied, as well as its size and location. Preoperative diagnosis for cavernous sinus ALM is considered difficult, and it is especially important to distinguish cavernous sinus ALM from cavernous sinus meningioma, trigeminal schwannoma, cavernous hemangioma, or hemangioblastoma.

According to our review, typically ALMs were mostly of a solid tumor type and were isointense on a T1-weighted MRI, hyperintense on a T2-weighted MRI, and homogeneously enhanced after intravenous administrations of gadolinium. Radiologic findings in our case were similar to that of most previous reports (Table 2). Bone erosion is considered a rare radiologic finding in ALM. There is only one report of bone erosion in the literature.<sup>2</sup> We focus here on two radiologic



**Fig. 3** Postoperative neuroradiologic findings. (A) T1-weighted magnetic resonance (MR) images. (B) Contrast-enhanced T1-weighted MR images. (C) Computed tomography scans.

**Table 1** Clinical findings of previous reports

	Age, y	Sex	Location	Size, mm	Symptoms	Duration of symptoms, mo	Approach	Removal
Lach et al <sup>8</sup>	47	M	Parietal lobe	20	Gait abnormality, parkinsonism	14	NA	GTR
Ravikumar et al <sup>9</sup>	12	F	Caudate nucleus	NA	Diplopia, headache, seizure	1.5	Frontal craniotomy	GTR
Kohan et al <sup>7</sup>	NA	NA	IAM	NA	Hearing loss, tinnitus	NA	Retrosigmoid	GTR
Figueiredo et al <sup>2</sup>	52	M	Cavernous sinus	60	Diplopia, headache, facial numbness, impaired visual acuity	6	Frontotemporal	GTR
Karagama et al <sup>6</sup>	47	F	IAM	1	Sensorineural hearing loss	12	Translabyrinthine	GTR
Colnat-Coulbois et al <sup>1</sup>	50	M	Cavernous sinus	NA	Headache, diplopia	NA	Frontotemporal, intradural	GTR
Vijayaradhi et al <sup>12</sup>	10	F	Frontal intradiploic space	40	Headache	4	NA	GTR
Gasco et al <sup>5</sup>	43	M	Cerebellar lesion	44	Blurry vision, ataxia, headache	12	Suboccipital	GTR
Xu et al <sup>13</sup>	53	M	Sella	NA	Headache, visual deterioration	3	NA	GTR
Conner et al <sup>11</sup>	42	M	Tentorial incisura	10	Headache	3	Midline suboccipital	GTR
Conner et al <sup>11</sup>	36	M	Falx cerebri	25	Headache, lightheadedness	24	Interhemispheric	STR
Zhou et al <sup>3</sup>	62	M	Cavernous sinus	37	seizure	0	NA	GTR
Shinde et al <sup>10</sup>	60	M	Putamen, hippocampus	20	Headache, seizure	2	None	Biopsy
Present case	52	F	Cavernous sinus	23	Eye discomfort	6	Extradural temporopolar	GTR

Abbreviations: GTR, gross total resection; IAM, internal acoustic meatus; NA, not available; STR, subtotal resection.

**Table 2** Radiologic findings of previous reports

	Radiologic findings
Lach et al <sup>8</sup>	CT: Homogenous enhancement, no mass effect, large draining vein
Ravikumar et al <sup>9</sup>	CT: Enhanced mural nodule
Kohan et al <sup>7</sup>	NA
Figueiredo et al <sup>2</sup>	CT: Homogeneous enhancement, bone erosion; MRI: T1, isointense; T2, hyperintense; Gd, homogeneous enhancement; IC/optic chiasm displacement
Karagama et al <sup>6</sup>	MRI: T1, isointense; T2, hyperintense; Gd, homogeneous enhancement
Colnat-Coulbois et al <sup>1</sup>	MRI: T1, isointense; T2, hyperintense; Gd, heterogeneous enhancement
Vijayaradhhi et al <sup>12</sup>	NA
Gasco et al <sup>5</sup>	CT: Hyperdense; MRI: T1, isointense; T2, hyperintense; Gd, homogeneous enhancement
Xu et al <sup>13</sup>	MRI: T1, hypotense; T2, hyperintense
Conner et al <sup>11</sup>	MRI: T2, hyperintense; Gd, punctate enhancement
Conner et al <sup>11</sup>	CT: Homogeneous enhancement
Zhou et al <sup>3</sup>	MRI: T1, isointense; T2, hyperintense; Gd, heterogeneous enhancement; DWI, hypointense
Shinde et al <sup>10</sup>	MRI: T1, iso-hypointense; T2, hyperintense; Gd, homogeneous enhancement
Present case	MRI: T1, iso-hypointense; T2, hyperintense; Gd, heterogeneous enhancement; DWI, hypointense; CISS, hyperintense; enhanced CT: nodular tumor stains; angiography: nodular tumor stains

Abbreviations: CISS, constructive interference in steady state; CT, computed tomography; DWI, diffusion-weighted image; Gd, gadolinium; IC, internal capsule; MRI, magnetic resonance image; NA, not available.

**Table 3** Pathologic findings of previous reports

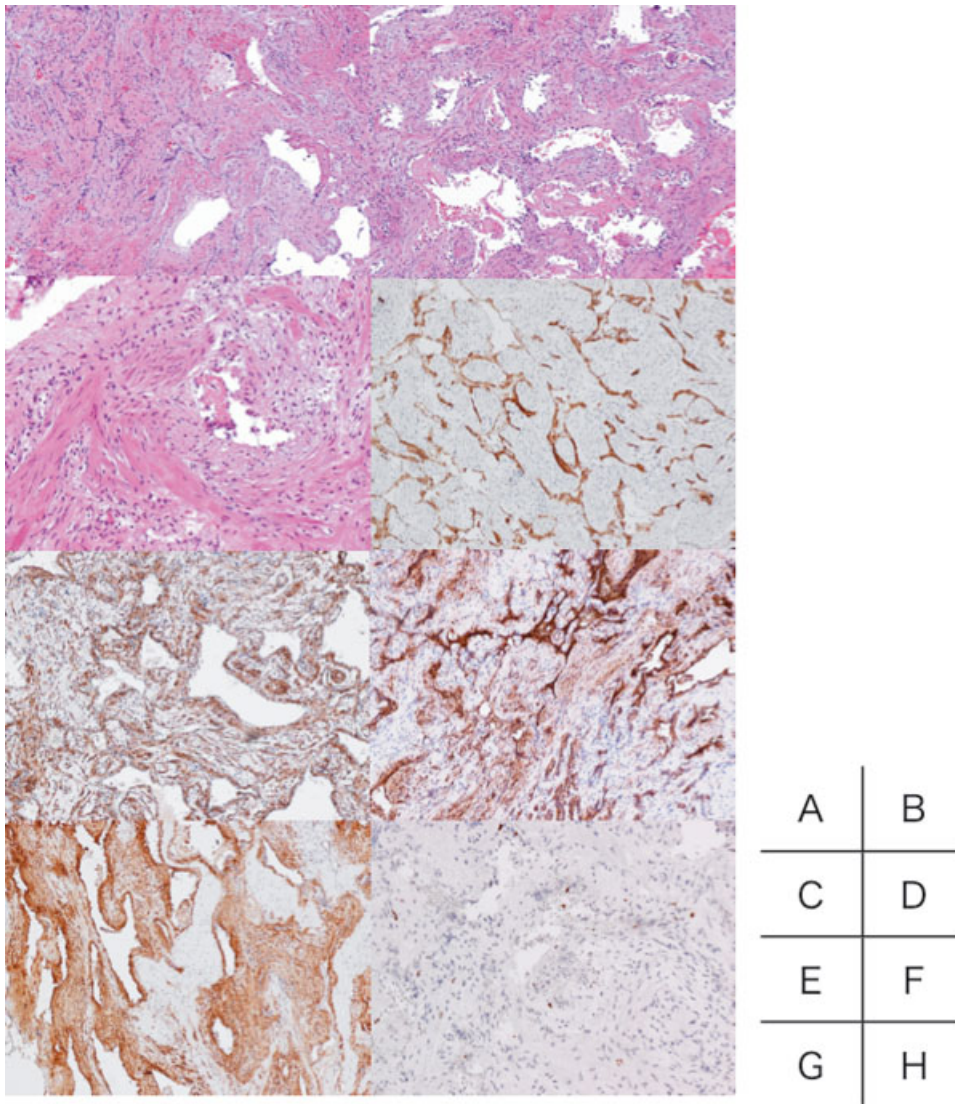
	Pathologic findings	Type of ALM
Lach et al <sup>8</sup>	Vessel walls: desmin (+), vimentin (+), SMA (+), myosin (+)	Mixed
Ravikumar et al <sup>9</sup>	Vessel walls: desmin (+), S100 (-), GFAP (-)	Solid
Kohan et al <sup>7</sup>	NA	NA
Figueiredo et al <sup>2</sup>	Vessel walls: vimentin (+), SMA (+), EMA (-), S100 (-), GFAP (-), MSA (-)	Cavernous
Karagama et al <sup>6</sup>	Vessel walls: SMA(+)	Cavernous
Colnat-Coulbois et al <sup>1</sup>	Vessel walls: vimentin (+), SMA (+), EMA (-), endothelial cells: CD31 (+), CD34 (+)	Cavernous
Vijayaradhhi et al <sup>12</sup>	Vessel walls: SMA (+), EMA (-), vimentin (-), S100 (-)	Solid
Gasco et al <sup>5</sup>	Vessel walls: SMA (+), endothelial cells only: CD34 (+), EMA (-), Ki-67 < 1%	Venous
Xu et al <sup>13</sup>	Vessel walls: desmin (+), vimentin (+), SMA (+), MSA (+), AE1/AE3 (-), S100 (-), GFAP (-), EMA (+), endothelial cells: CD31 (+), CD34 (+)	Cavernous
Conner et al <sup>11</sup>	Vessel walls: vimentin (+), SMA (+), MSA (+), endothelial cells: CD31 (+), CD34 (+), EMA (-), S100 (-)	Cavernous
Conner et al <sup>11</sup>	Vessel walls: vimentin (+), SMA (+), MSA (+), endothelial cells: CD31 (+), CD34 (+), EMA (-), S100 (-)	Cavernous
Zhou et al <sup>3</sup>	SMA (+), desmin (+), EMA (-), Ki-67 < 1%	Venous
Shinde et al <sup>10</sup>	Vimentin (+), SMA (+), desmin (+), GFAP (-), EMA (-), Ki-67 (-)	NA
Present case	Endothelial cells: CD34 (+), spindle cell: $\alpha$ SMA (+), h-Caldesmon (+), calponin (+), EMA (-), S100 (-), CD34 (-)	Cavernous

Abbreviations: AE1/AE3, antikeratin; EMA, epithelial membrane antigen; GFAP, glial fibrillary acidic protein; MSA, muscle-specific actin; NA, not available; SMA, smooth muscle actin.

findings that include blush enhancement on enhanced MR, and small nodular enhancement on angiography, and enhanced CT. In our case, the tumor heterogeneously enhanced on an MRI. This blush enhancement seemed to extend from the center of the tumor like a hemangioma (►Fig. 4A–C). Colnat-Coulbois et al previously recognized these characteristic findings. They also stated that the tumor heterogeneously enhanced in the early phase after intravenous administrations of gadolinium; however, it homogeneously enhanced in the late phase.<sup>1</sup> Second, there were small nodular enhancement in angiography and enhanced CT images (►Fig. 4D, E). These findings are new radiologic findings of intracranial angioleiomyoma, similar to that of hemangioma. This similarity to hemangioma is understandable because ALMs are considered on a spectrum between hemangioma and leiomyoma. Presently, it is considered difficult to distinguish intracranial ALMs from meningioma, schwannoma, cavernous hemangioma, and hemangioblastoma. We con-

clude that cavernous hemangioma and hemangioblastoma can be distinguished easily from intracranial ALMs. This is because typically cavernous hemangiomas are often hyperintense on a T1-weighted MRI, hyperintense on a T2-weighted MRI, and have a hemosiderin rim.<sup>3</sup> In contrast, hemangioblastomas often have cysts, flow void on a T1- and T2-weighted MRI, and angiography shows the feeding artery. Otherwise, it is difficult to distinguish intracranial ALMs from meningiomas or schwannomas. The dural relationship of ALMs tends to confuse the diagnosis compared with that of meningioma. However, blush enhancement and the small nodular enhancement such as hemangioma may differ from meningioma or schwannoma (►Fig. 4).

Histopathologically, ALMs have been subdivided into three types: solid, venous, and cavernous (►Table 3). The solid type is composed of small vessels and compacted smooth muscle. The venous type has numerous thick-walled vessels and smooth muscle bundles that are not as compact. The



**Fig. 4** Preoperative neuroradiologic findings. (A–C) Contrast-enhanced T1-weighted magnetic resonance images. (D) Enhanced computed tomography scans. (E) Preoperative cerebral angiography (right internal carotid angiography). Note the tumor (circle) with small labeled nodules within (arrow).

cavernous type is composed of dilated vessels and few intervening smooth muscle cells. According to Hachisuga et al, a total of 562 cases of ALMs were separated into 374 cases (66%) of the solid type, 127 (23%) of the venous type, and 61 (11%) of the cavernous type.<sup>4</sup> Otherwise, in the intracranial ALMs, the cavernous type was more frequently found than other types in previous reports (seven cases: cavernous type; two cases: venous type; two cases: solid type; one case: mixed type; two cases: unknown) ( $p = 0.04$ ). Ramesh et al and Tracy et al observed that the solid type and the venous type were found mostly in females, and the cavernous type was found mainly in males.<sup>11,14</sup> Therefore, because since intracranial ALMs are mainly found in males, they are often classified into the cavernous type, unlike common ALMs.

Currently, there is no stated appropriate surgical approach for intracranial ALMs. According to previous reports, the surgical approach for intracranial ALMs varies by location. The surgical approach also differs in cavernous sinus ALMs. In a previous case, Figueiredo et al selected an epidural approach, but Colnat-Coulbois et al performed a transsylvian subdural approach.<sup>1,2</sup> Zhou et al did not detail their surgical approach.<sup>3</sup> Because ALMs are considered on a spectrum of conditions between hemangioma and leiomyoma histopathologically, ALMs are expected to be differentiated from the mesoderm. Dura mater is derived from the ectomeninx, which is of mixed paraxial mesodermal and neural crest origin.<sup>15</sup> Furthermore, in the previous 14 cases, 11 cases were found in the extradural lesion or in the peridural lesion (Table 1). From the above, ALMs are often expected to be an epidural tumor. Therefore, we should select the epidural approach and need to consider the radiologic findings of the tumor carefully.

In our review of the previous reports, intracranial ALMs differ from ALMs that occur in the extremities. Intracranial ALMs appear more frequent in men than women. The cavernous type is the most common type pathologically, and they occur often in the epiperidural lesion. Because cavernous sinus ALM occurs in the interdural space, an epidural approach should be selected. In addition, it is necessary to include cavernous sinus ALM into the differential diagnosis of the cavernous sinus tumor. The blush enhancement and the small nodular enhancement in enhanced CT and angiography, such as hemangioma, are helpful radiologic findings to distinguish cavernous sinus ALM from other differential diagnoses.

#### Disclosure

The authors report no conflict of interest concerning the materials or methods used in this or the findings specified in this paper.

#### References

- Colnat-Coulbois S, Schmitt E, Klein O, Weinbreck N, Auque J, Civit T. Angioleiomyoma of the cavernous sinus: case report. *Neurosurgery* 2008;62(1):E257–E258; discussion E258
- Figueiredo EG, Gomes M, Vellutini E, Rosemberg S, Marino R Jr. Angioleiomyoma of the cavernous sinus: case report. *Neurosurgery* 2005;56(2):E411; discussion E411
- Zhou Z, Yu M, Yang S, Zhou J, Sun R, Yang G. Dural angioleiomyoma of the middle cranial fossa: a case report and review of the literature. *Brain Tumor Pathol* 2013;30(2):117–121
- Hachisuga T, Hashimoto H, Enjoji M. Angioleiomyoma. A clinicopathologic reappraisal of 562 cases. *Cancer* 1984;54(1):126–130
- Gasco J, Franklin B, Rangel-Castilla L, Campbell GA, Eltorok M, Salinas P. Infratentorial angioleiomyoma: a new location for a rare neoplastic entity. *J Neurosurg* 2009;110(4):670–674
- Karagama YG, Bridges LR, van Hille PT. Angioleiomyoma of the internal auditory meatus: a rare occurrence in the internal auditory canal. *Ear Nose Throat J* 2005;84(4):216–218
- Kohan D, Downey LL, Lim J, Cohen NL, Elowitz E. Uncommon lesions presenting as tumors of the internal auditory canal and cerebellopontine angle. *Am J Otol* 1997;18(3):386–392
- Lach B, Duncan E, Rippstein P, Benoit BG. Primary intracranial pleomorphic angioleiomyoma—a new morphologic variant. An immunohistochemical and electron microscopic study. *Cancer* 1994;74(7):1915–1920
- Ravikumar C, Veerendrakumar M, Hegde T, Nagaraja D, Jayakumar PN, Shankar SK. Basal ganglionic angioleiomyoma. *Clin Neurol Neurosurg* 1996;98(3):253–257
- Shinde SV, Shah AB, Baviskar RB, Deshpande JR. Primary intracranial multicentric angioleiomyomas. *Neurol India* 2012;60(1):115–117
- Conner TM, Waziri A, Kleinschmidt-Demasters BK. Angioleiomyomas of the dura: rare entities that lack KRIT1 mutations. *Am J Surg Pathol* 2012;36(4):526–533
- Vijayasaradhi M, Uppin SG, Sreedhar V, Sundaram C, Panigrahi MK. Frontal intradiploic angioleiomyoma. *J Neurosurg Pediatr* 2008;2(4):266–268
- Xu Y, Jing Y, Ma S, et al. Primary angioleiomyoma in the sellar region: a case report and literature review. *Clin Neuropathol* 2010;29(1):21–25
- Ramesh P, Annapureddy SR, Khan F, Sutaria PD. Angioleiomyoma: a clinical, pathological and radiological review. *Int J Clin Pract* 2004;58(6):587–591
- Huang MC, van Loveren H. Anatomy and biology of the leptomeninges. In: Al-Mefty O, ed. *Meningiomas*. New York, NY: Raven Press; 1991:Chapter 3