

CASE REPORT

Transient abnormal myelopoiesis in pediatrics with trisomy 21

Nadereh Taei¹  | Mojgan Faraji-Goodarzi¹  | Mohammad Safdari² | Amir Bajelan²

¹Department of Pediatrics, Faculty of Medicine, Lorestan University of Medical Sciences, Khorramabad, Iran

²Student of Research Committee, Lorestan University of Medical Sciences, Khorramabad, Iran

Correspondence

Mojgan Faraji-Goodarzi, Lorestan University of Medical Sciences, Khorramabad, Iran.
Email: dr.n.taei@gmail.com

Abstract

Transient abnormal myelopoiesis is common among Down syndrome patients. Although no therapeutic measures are required, close monitoring of comorbidities such as gastrointestinal bleeding is required. Long-term follow-up is promising for a healthy future and reduced requirement of unnecessary therapeutic measures including chemotherapy and remission of the pathology.

KEYWORDS

Down syndrome, transient leukemia

1 | INTRODUCTION

Down syndrome is the most common genetic disorders of chromosome 21, where patients are more susceptible to hematological disorders. One of the most common hematological problems that occurs in 10% of patients with Down syndrome is transient myelopoiesis; however, it cures itself without any treatment within 3-6 months. A 2-day-old baby girl with Down syndrome presenting respiratory distress, fever, and skin lesions was admitted, and after examination, hyperleukocytosis was diagnosed. Transient leukemia diagnosis was reviewed. At the age of 2 months without any treatment therapy, peripheral blood smear was normal. 8 years of follow-up did not provide any evidence of relapse of transient leukemia in the child.

Down syndrome (DS) affects 14 out of 10 000 live births, annually, in the United States. Although its prevalence varies geographically, it affects greater proportion of infants throughout the world.¹ Respiratory and cardiovascular comorbidities are mostly reported in these patients and require hospitalization.² Hematological abnormalities are also common in these children, particularly, with trisomy 13 and 18; nonetheless, it does not require special care or attention since these features are common in chromosomally normal children as well.³ There are two components of megakaryoblastic leukemia: transient abnormal myelopoiesis (TAM) and acute

megakaryoblastic leukemia (AMKL), both are not uncommon manifestations in children with trisomy 21.⁴ In children with Down syndrome, trisomy 21, and excessive accumulation of abnormal myeloblasts, TAM is the common condition that develops before the age of 5 in 10% patients (common is DS only). TAM and AMKL are presented as one or more somatic mutations of transcription factor gene GATA1.^{5,6} Blood samples of these patients are seen with abnormal number of blood cells (eg, basophils) and circulating blast cells. Additionally, bone marrow analysis might show dysplasia of precursor blood cells such as that of platelets and erythrocytes. Regardless of asymptomatic conditions and resolution of symptoms in early lives, some patients might present hepatomegaly and/or splenomegaly, jaundice, and liver fibrosis.^{5,7} Besides, its remission leading to TAM, in some cases, can affect several organs due to the infiltration of blast cells and can be fatal.⁸ TAM resolves within the period of three months without particular therapeutic measures. However, some patients might need a low dose of chemotherapy to increase survival period and prevent other morbidities.⁹

2 | CASE PRESENTATION

A 2-day-old baby girl having DS was presented to our center with respiratory distress, fever, and poor feeding. She was the

This is an open access article under the terms of the Creative Commons Attribution-NonCommercial-NoDerivs License, which permits use and distribution in any medium, provided the original work is properly cited, the use is non-commercial and no modifications or adaptations are made.

© 2020 The Authors. *Clinical Case Reports* published by John Wiley & Sons Ltd.

first child of the family, and parents were related by second families with no such signs and history. At the time of delivery, maternal age was 32 years with no history of infertility, abortion, stillbirth, or neonatal mortality.

Her initial examination showed the following:

BP: 60/ pulse mmHg, respiratory rate: 70/ min, pulse rate: 133 min, T axillary: 38 °

During the examination for the phenotype of Down syndrome, epicanthal fold, low set ear, simian crease, hypertelorism, and hypotonia were observed. Auscultation of heart murmur grade at II/VI in left sternal boarder was also found along with auscultation of the lungs, inspiratory strider, and laryngomalacia. In the abdominal examination, 5cm and 3cm below the costal margin for liver and spleen, respectively, were palpable. Around the baby's skin, there were patchy erythematous papules.

2.1 | In preliminary laboratory findings

WBC: 99.7×10^3 with 35% myeloid and 108×10^3 platelets was reported (Figure 1). Furthermore, bone marrow aspirate and trephine showed increased blasts.

Electrolytes, arterial blood gases, blood culture, and urine of patient were normal.

On the second day of hospitalization, the patient was suffering from gastrointestinal bleeding for which the patient responded well with fresh frozen plasma and vitamin K treatment.

On the third day of hospitalization, the skin lesions were spontaneously resolved without any treatment.

The result of chromosome, 47, xx, +21 Down syndrome is shown in Figure 2 below.

2.2 | Follow-up

The baby appeared normal in the course of therapy; antibiotics and protective measures were taken, and follow-up was performed after 10 days of partial recovery and breastfeeding. The neonate was discharged with following outpatient

laboratory findings: WBC: 116×10^3 with 31% myelocyte and 25% blast cells at the time of leaving the hospital (Figure 3).

Peripheral blood smear at the age of 1 month was WBC: 90×10^3 with blast cells (Figure 4).

At the age of 8 weeks, abdominal examination was seen to be normal. Whereas, laboratory findings, WBC: 8.8×10^3 with normal cells, are indicated in Figure 5. At the age of 12 weeks, in addition to the normal peripheral blood smear, liver and spleen were normal too. CBC, peripheral blood smear, and complete physical examination were performed after every 6 months.

The baby was healthy to the date; however, dysarthria and follow-up training underage were present. Speech therapy and checkup revealed that she was healthy with normal blood tests and peripheral blood smear.

3 | DISCUSSION

Trisomy 21 or Down syndrome is the most common genetic disorder with mental retardation, cardiovascular problems, and hematological and digestive tract-related disorders.^{2,5} The most important hematological problems in patients with Down syndrome are leukemia, which is 10-20 times more prevalent, as compared to general population.¹⁰ Although the prevalence of hematological malignancies in older children with Down syndrome is similar to that of adults, in the first three years of life, the incidence of acute myeloid leukemia is 500 times more in DS infants.³ In addition, transient leukemia is seen in 10% of Down syndrome infants (1.7%).¹¹

Transient leukemia in Down syndrome (TL-DS) is temporary and can be recovered within 3 to 6 months after birth.⁴ This recovery is spontaneously characterized by the infiltration of hematopoietic cells back to the bone marrow.¹²

At this stage, due to the increased immunity of the infant and the spontaneous apoptosis, the blast cells disappear.¹³ AMKL occurs in 30% of (TL-DS) cases till the age of 4.⁵ The presence of more than 5% blast cells in the




FIGURE 1 Slide showing peripheral blood smear of baby at birth

FIGURE 2 The result of chromosome study

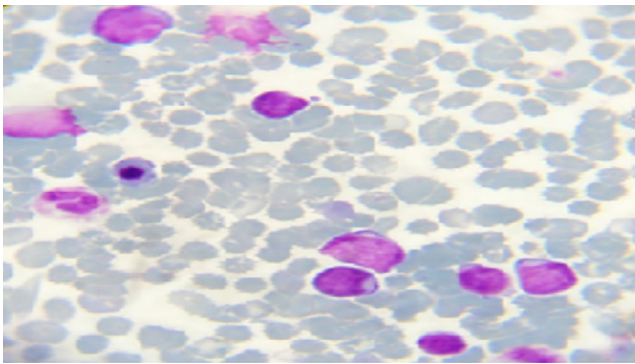
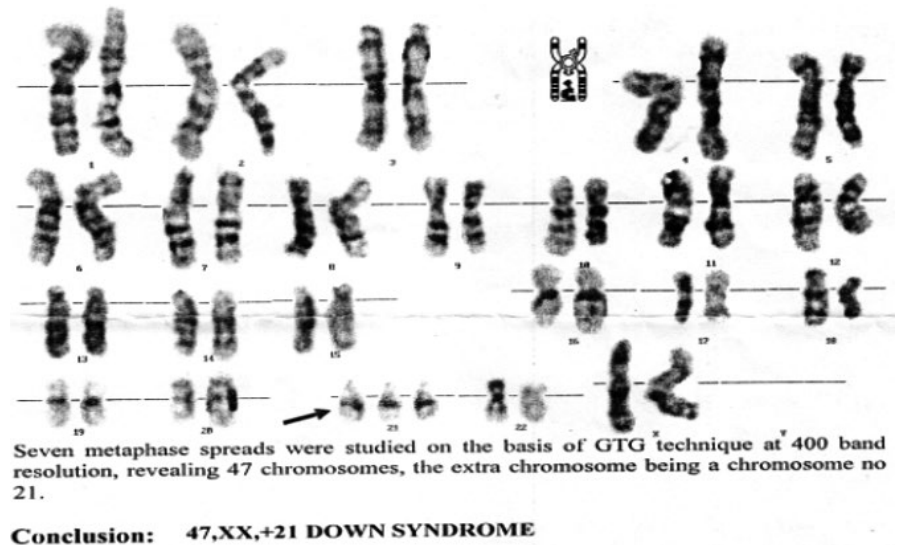


FIGURE 3 Slide showing peripheral blood smear of baby at the age of ten days

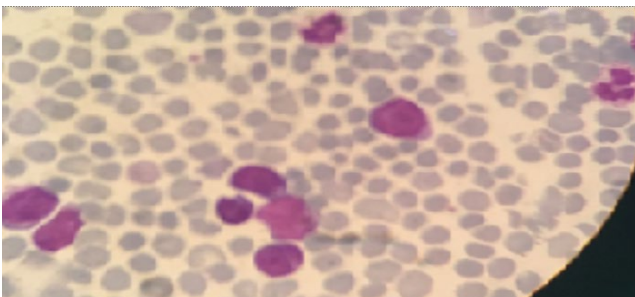


FIGURE 4 Slide showing peripheral blood smear of baby at the age of one month

peripheral blood smear at the age of less than 6 months is characterized by the diagnosis of TL-DS.¹⁴ GATA1 is the hematopoietic transcription factor that is responsible for cell differentiation. Mutations in the gene on the X chromosome have been reported to lead to the production of immature blast cells in TL-DS and AMKL-DS.^{6,7} In peripheral blood smear of TL-DS, 1%-77% blast cells have been reported.^{6,15} Hepatosplenomegaly is the most common clinical sign

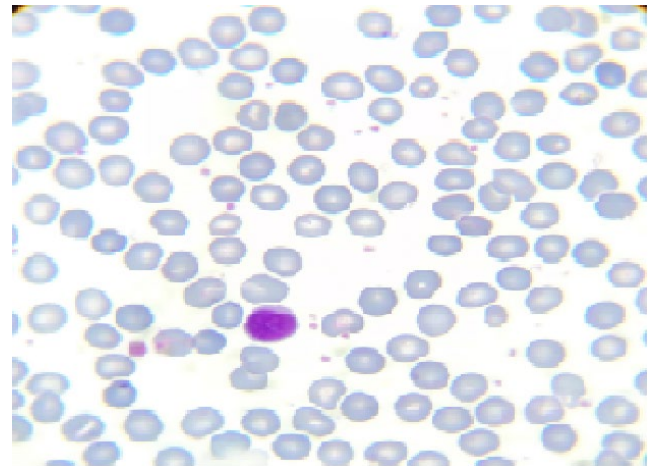


FIGURE 5 Slide showing peripheral blood smear of baby at the age of two months

with 56% prevalence. In less than 2% of cases, (pustular vesicle and papule) blast cell infiltration in the skin occurs.^{9,16}

The most important laboratory findings are hyperleukocytosis and blasts in the peripheral blood smear. In 20%-30% of cases, coagulation disorders and DIC in 10%, hyperleukocytosis in 20% with $WBC > 100 \times 10^3$, and liver function test abnormalities are seen.

4 | CONCLUSION

Without any therapeutic measures, within 3-6 months, patients recover; however, remission of disease is also seen in numerous cases. Therefore, follow-up including blood test, peripheral blood smear, and monitoring of clinical signs and symptoms and close monitoring of comorbidities is extremely significant. This can reduce the risk of further complications and the need of chemotherapy.

In this report, we present a case of DS, diagnosed with TML, which under stringent follow-up, when left untreated, showed a completed recovery.

ACKNOWLEDGMENTS

Published with written consent of the patient.

CONFLICT OF INTEREST

The authors deny any conflict of interest in any terms or by any means during the study.

AUTHOR CONTRIBUTIONS


Dr Mojgan Faraji-Goodarzi: conceptualized and designed the study, drafted the initial manuscript, and reviewed and revised the manuscript. Dr Nadereh Tae: designed the data collection instruments, collected data, carried out the initial analyses, and reviewed and revised the manuscript. Dr Fariba Tarhani: coordinated and supervised data collection, and critically reviewed the manuscript for important intellectual content. All authors approved the final manuscript as submitted and agreed to be accountable for all aspects of the work.

DATA AVAILABILITY STATEMENT

Data sharing is not applicable to this article as no datasets were generated or analyzed during the current study.

ORCID

Nadereh Tae  <https://orcid.org/0000-0002-6046-6342>

Mojgan Faraji-Goodarzi  <https://orcid.org/0000-0002-7494-2557>

REFERENCES

1. Presson AP, Partyka G, Jensen KM, et al. Current estimate of Down Syndrome population prevalence in the United States. *J Pediatr*. 2013;163(4):1163-1168.
2. Martin T, Smith A, Breatnach CR, et al. Infants born with Down syndrome: burden of disease in the early neonatal period. *J Pediatr*. 2018;193:21-26.
3. Webb D, Roberts I, Vyas P. Haematology of Down syndrome. *Arch Dis Childhood Fetal Neonatal Ed*. 2007;92(6):F503-F507.
4. Gruber TA, Downing JR. The biology of pediatric acute megakaryoblastic leukemia. *Blood*. 2015;126(8):943-949.
5. Bhatnagar N, Nizery L, Tunstall O, Vyas P, Roberts I. Transient abnormal myelopoiesis and aml in down syndrome: an update. *Curr Hematol Malig Rep*. 2016;11(5):333-341.
6. Bajwa R, Skinner R, Windebank K, Reid M. Demographic study of leukaemia presenting within the first 3 months of life in the Northern Health Region of England. *J Clin Pathol*. 2004;57(2):186-188.
7. Parker SE, Mai CT, Canfield MA, et al. Updated national birth prevalence estimates for selected birth defects in the United States, 2004–2006. *Birth Defects Res A Clin Mol Teratol*. 2010;88(12):1008-1016.
8. Gosavi AV, Murarkar PS, Lanjewar DN, Ravikar RV. Transient leukemia in Down syndrome: report of two cases with review of literature. *Indian J Hematol Blood Transfus*. 2011;27(3):172-176.
9. Watanabe K. Recent advances in the understanding of transient abnormal myelopoiesis in Down syndrome. *Pediatr Int*. 2019;61(3):222-229.
10. Zipursky A. Transient leukaemia—a benign form of leukaemia in newborn infants with trisomy 21. *Br J Haematol*. 2003;120(6):930-938.
11. Rozen L, Huybrechts S, Dedeken L, et al. Transient leukemia in a newborn without Down syndrome: case report and review of the literature. *Eur J Pediatr*. 2014;173(12):1643-1647.
12. Roberts I, Alford K, Hall G, et al. GATA1-mutant clones are frequent and often unsuspected in babies with Down syndrome: identification of a population at risk of leukemia. *Blood*. 2013;122(24):3908-3917.
13. Weiss MJ, Orkin SH. Transcription factor GATA-1 permits survival and maturation of erythroid precursors by preventing apoptosis. *Proc Natl Acad Sci*. 1995;92(21):9623-9627.
14. Klusmann J-H, Creutzig U, Zimmermann M, et al. Treatment and prognostic impact of transient leukemia in neonates with Down syndrome. *Blood*. 2008;111(6):2991-2998.
15. Narvaez-Rosales V, de-Ocariz MS, Carrasco-Daza D, et al. Neonatal vesiculopustular eruption associated with transient myeloproliferative disorder: report of four cases. *Int J Dermatol*. 2013;52(10):1202-1209.
16. Gamis AS, Smith FO. Transient myeloproliferative disorder in children with Down syndrome: clarity to this enigmatic disorder. *Br J Haematol*. 2012;159(3):277-287.

How to cite this article: Tae N, Faraji-Goodarzi M, Safdari M, Bajelan A. Transient abnormal myelopoiesis in pediatrics with trisomy 21. *Clin Case Rep*. 2021;9:605–608. <https://doi.org/10.1002/ccr3.3589>