

# Computed Tomography Angiography in Diagnosis and Treatment of Splenic Artery Aneurysm

Chun-Xi Wang<sup>1</sup>, Shu-Li Guo<sup>2</sup>, Li-Na Han<sup>3</sup>, Yang Jie<sup>4</sup>, Hai-Di Hu<sup>5</sup>, Jing-Ru Cheng<sup>1</sup>, Miao Yu<sup>4</sup>, Yue-Yong Xiao<sup>4</sup>, Tai Yin<sup>1</sup>, Fu-Tao Chu<sup>1</sup>, Fa-Qi Liang<sup>1</sup>

<sup>1</sup>Department of General Surgery, Chinese PLA General Hospital, Beijing 100853, China

<sup>2</sup>State Key Laboratory of Intelligent Control and Decision, School of Automation, Beijing Institute of Technology, Beijing 100081, China

<sup>3</sup>Department of Cardiovascular Internal Medicine, Nanlou Branch of Chinese PLA General Hospital, Beijing 100853, China

<sup>4</sup>Department of CT Radioactive Intervention, Chinese PLA General Hospital, Beijing 100853, China

<sup>5</sup>Department of Vascular Surgery, First Clinical Hospital of China Medical University, Shenyang 110001, China

Chun-Xi Wang and Shu-Li Guo contributed equally to this work.

**Key words:** Aneurysm Resection; Computed Tomography Angiography; Splenic Artery Aneurysm

Splenic artery aneurysm, without obvious symptoms, is a direct threat to the patient's life, once it ruptures as hemorrhagic shock. Imaging examinations have been the main diagnostic methods of splenic artery aneurysm, including ultrasound, computed tomography (CT), magnetic resonance imaging, and digital subtraction angiography (DSA). Although various inspective methods have their own advantages and disadvantages, abdominal CT examination is the most comprehensively applied method in clinical settings. The representative images of splenic artery aneurysm from a relatively large number of patients examined by CT are presented in this study.

A total of 327 cases with splenic artery aneurysm were enrolled from 1998 to 2014, including 142 males and 185 females, with the age ranging from 37 to 78 years and an average age of 51.8 years old. The diagnosis of splenic artery aneurysm was confirmed by ultrasonography and CT examination. There were 20 cases accompanied with cirrhosis, 13 with hypertension, 12 with systemic multiple sclerosis, 10 with diabetes, 6 with gastrointestinal tumor, and 10 with cerebral infarction. Diagnostic criteria of CT imaging were as follows.<sup>[1]</sup> The diagnostic criteria for true aneurysm were limited expansion of splenic artery with intact wall and clear boundaries from the normal splenic artery, with the maximum width of the neck more than 1.5 times greater than that of the normal vascular. The diagnostic criteria for pseudoaneurysm were one discontinuous side of damaged splenic arterial wall and aneurysm body being on one side of the artery with a high density of contrast agent in angiography at the center, but no imaging in the aneurysm

wall. The diagnostic criteria of dissecting aneurysm were eccentric expanded blood vessels with a double vascular wall of different density at cross-section in vascular reconstruction.

All of the 327 cases were diagnosed with splenic artery aneurysm, including 306 cases with single tumor and 21 with multiple 2–5 tumors. The aneurysm diameter ranged from 2 to 15 cm with an average of  $4.97 \pm 2.28$  cm. The shuttle aneurysms were found in 196 cases, approximately round in 56 cases, oval in 19 cases, hemisphere in 13 cases, and irregular in 22 cases. Aneurysm wall calcification was found in 249 cases. True aneurysms were confirmed in 288 cases, including multiple aneurysms in 21 cases, pseudoaneurysm in 31 cases, and dissecting aneurysm in 8 cases. There were 276 aneurysms in the middle and distal segment of the splenic artery, 40 adjacent to the splenic porta, and 11 adjacent to the splenic artery origin. A total of 314 aneurysms arose from the initial segment of splenic artery and in normal celiac trunk, 4 from abdominal aorta, 3 from the superior mesenteric artery, and 6 with abnormal combination of hepatic artery, splenic artery, and mesenteric artery. The representative images of splenic artery aneurysm are shown in Figure 1.

**Address for correspondence:** Prof. Li-Na Han,  
Department of Cardiovascular Internal Medicine, Nanlou Branch  
of Chinese PLA General Hospital, Beijing 100853, China  
E-Mail: hanlina3399111@sina.com

This is an open access article distributed under the terms of the Creative Commons Attribution-NonCommercial-ShareAlike 3.0 License, which allows others to remix, tweak, and build upon the work non-commercially, as long as the author is credited and the new creations are licensed under the identical terms.

**For reprints contact:** reprints@medknow.com

© 2016 Chinese Medical Journal | Produced by Wolters Kluwer - Medknow

**Received:** 02-11-2015 **Edited by:** Qiang Shi

**How to cite this article:** Wang CX, Guo SL, Han LN, Jie Y, Hu HD, Cheng JR, Yu M, Xiao YY, Yin T, Chu FT, Liang FQ. Computed Tomography Angiography in Diagnosis and Treatment of Splenic Artery Aneurysm. Chin Med J 2016;129:367-9.

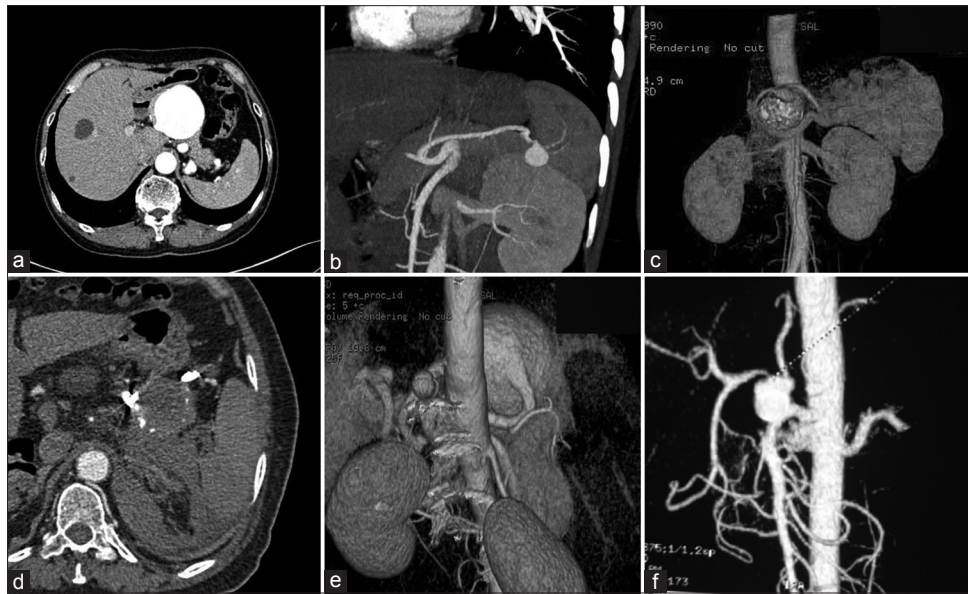
## Access this article online

### Quick Response Code:



**Website:**  
www.cmj.org

**DOI:**  
10.4103/0366-6999.174506



**Figure 1:** Representative computed tomography images of splenic artery aneurysm. (a) Splenic artery aneurysm with calcified wall and mural thrombus located in the rear of the pancreas. (b) Branching artery aneurysm of the splenic artery. (c) Aneurysm at the initial segment of the splenic artery. (d) Pseudoaneurysm from the ruptured splenic artery. (e) Multiple aneurysms. (f) Splenic artery aneurysm complicated with abnormal junction celiac trunk and superior mesenteric artery.

A total of 285 cases underwent endovascular intervention treatment, 21 cases were pseudoaneurysms, and 264 were true aneurysms located in the middle and distal segment of the splenic artery. Moreover, 41 cases underwent traditional surgery, 11 cases were at the initial segment of the splenic artery, 6 were giant aneurysms, 5 were aneurysms adjacent to splenic portal, 5 were combined with wide and irregular aneurysm neck, 5 were abnormally combined with celiac trunk and superior mesenteric artery, 4 were multiple aneurysms, and 5 were general aneurysms in the middle and distal segment of splenic porta. There was 1 case of true aneurysm in the middle segment of the splenic artery underwent laparoscopic splenic artery aneurysm resection. No life-threatening complications were observed. There were 11 of 285 cases treated with intervention, which showed mild to moderate partial splenic infarction with abdominal pain and low fever and improved after conservative treatment. Moreover, 2 of 41 cases treated with traditional operations showed mild stenosis of anastomosis. All cases satisfied the clinical cure standard and without perioperative death when they were discharged without recurrence in the 6 months to 12 years' follow-up using the CT angiography examination.

Abdominal ultrasound is widely used in clinical settings due to economical, convenient, and noninvasive character; however, obesity, gastrointestinal gas, and serious arteriosclerosis impaired its positive rate and accurate rate. Enhanced magnetic resonance angiography is often used for the diagnosis of aneurysm, but often accompanied with certain restrictions due to *in vivo* metal implants such as pacemaker or aneurysm clip and claustrophobic fear of long time examination. DSA has been considered the “gold standard” for the diagnosis of vascular diseases. However, its gold standard status was challenged by the development of noninvasive imaging

technologies, especially the development of multi slice CT angiography imaging technology. The data of abdominal CT examination in arterial phase were directly used for vascular reconstruction in the background through various reconstruction techniques to obtain aneurysm information from different angles, especially the structural characteristics of giant complex aneurysm and combined malformation of visceral artery.<sup>[2,3]</sup> From this study, CT angiography helped to determine the size, number, shape, location, and internal structure of splenic artery aneurysm, display the anatomic relationship between aneurysm and its surrounding organs, and clarify the relationship between the origin of the aneurysm and visceral artery. In recent years, vast majority of splenic aneurysm have received therapy through the vascular intervention.<sup>[4]</sup> Meanwhile, traditional surgical operation is still a reliable method for patients with complex splenic artery aneurysm who are unable to choose interventional therapy, such as splenic artery aneurysm adjacent to splenic artery or celiac artery, with proximal broad aneurysm distorted neck, with complicated arteriovenous fistula, with huge aneurysm body, and have close relationship with spleen and pancreas.<sup>[5]</sup>

Therefore, multi-slice spiral CT angiography is a relatively accurate and efficient inspective method to clearly show the structural features of splenic artery aneurysm and provide anatomical and pathological information for the clinicians, and it may be helpful in making different treatment regimens according to the clinical characteristics of the aneurysm.

### Financial support and sponsorship

This study was supported by a grant from the Hainan Provincial Research Program (No. YJJC20130009).

### Conflicts of interest

There are no conflicts of interest.

## REFERENCES

1. Lakin RO, Bena JF, Sarac TP, Shah S, Krajewski LP, Srivastava SD, *et al.* The contemporary management of splenic artery aneurysms. *J Vasc Surg* 2011;53:958-64. doi: 10.1016/j.jvs.2010.10.055.
2. Iryo Y, Ikushima I, Hirai T, Yonenaga K, Yamashita Y. Evaluation of contrast-enhanced MR angiography in the follow-up of visceral arterial aneurysms after coil embolization. *Acta Radiol* 2013;54:493-7. doi: 10.1177/0284185113475920.
3. Saba L, Anzidei M, Lucatelli P, Mallarini G. The multidetector computed tomography angiography (MDCTA) in the diagnosis of splenic artery aneurysm and pseudoaneurysm. *Acta Radiol* 2011;52:488-98. doi: 10.1258/ar.2011.100283.
4. Vaquero C, San Norberto E, Martin-Pedrosa M, Del Río L, Cenizo N, Taylor J, *et al.* Endovascular management of splenic artery aneurysms. *Rev Port Cir Cardiorac Vasc* 2013;20:97-101.
5. Wang CX, Han LN, Liang FQ, Chu FT, Jia X. Aneurysm resection and vascular reconstruction for true aneurysm at the initial segment of splenic artery. *J Huazhong Univ Sci Technolog Med Sci* 2015;35:439-44. doi: 10.1007/s11596-015-1450-1.