




Development of a Model for Plaque Induction in Rat Carotid Arteries

Akira Wakako¹ Akiyo Sadato² Motoki Oeda³ Saeko Higashiguchi¹ Motoharu Hayakawa¹
Marie Oshima⁴ Yuichi Hirose²

¹Department of Neurosurgery, Fujita Medical University Okazaki Medical Center, Okazaki, Aichi, Japan

²Department of Neurosurgery, Fujita Medical University, Toyoake, Aichi, Japan

³Department of Neurosurgery, Toyota Memorial Hospital, Toyota, Aichi, Japan

Address for correspondence Akira Wakako, MD, Department of Neurosurgery, Fujita Medical University Okazaki Medical Center, Gotanda 1Banchi, Harisakicho, Okazaki, Aichi, Japan (e-mail: akr-0614@fujita-hu.ac.jp).

⁴Institute of Industrial Science/Graduate School of Interdisciplinary Information Studies, University of Tokyo, Tokyo, Japan

Asian J Neurosurg 2023;18:499–507.

Abstract

Objective Plaque induction through intimal injury using a balloon catheter in small animals and by artificial ligation of the carotid artery in large animals have been reported. However, these reports have not yet succeeded in inducing stable plaques nor creating a high degree of intimal thickening to be used as animal models. We have previously developed a plaque induction model in rats but have failed to obtain a plaque incidence frequency that can be used as a model. Thus, in the current study, we aimed to create a versatile disease model to examine the pharmacokinetics of drug administration, determine the efficacy of treatment, and examine the process of intimal thickening. We also attempted to create an improved model with shorter, more frequent, and more severe intimal thickening.

Materials and Methods The common carotid artery of male Wistar rats was surgically exposed and completely ligated with a wire and 6–0 nylon thread. Then, the wire was removed to create a partial ligation. To create a high frequency and high degree of intimal thickening, 72 rats were divided into two groups: a single lesion group with a 0.25-mm wire and a single ligature point, and a tandem lesion group with a 0.3-mm wire and two ligature points. Each group was further divided into normal diet and high cholesterol diet groups. The presence and frequency of intimal thickening were examined for each group after 4, 8, and 16 weeks of growth.

Results In the single lesion group, intimal thickening was observed in 42% of the 4-week group and 75% of the 8-week group. In the tandem lesion group, intimal thickening was observed in 75% of the 4-week group and 50% of the 8-week group. In addition, 50% of the individuals reared for 16 weeks developed intimal thickening.

Conclusion We successfully induced intimal thickening in the carotid arteries of rats with high frequency in the single lesion and tandem lesion groups. The results also showed that the tandem lesion group tended to induce intimal thickening earlier than the single lesion group.

Keywords

- ▶ animal model
- ▶ arteriosclerotic plaque
- ▶ carotid artery
- ▶ computational fluid dynamic
- ▶ intimal thickening
- ▶ rat

article published online
July 12, 2023

DOI <https://doi.org/10.1055/s-0043-1763522>.
ISSN 2248-9614.

© 2023. Asian Congress of Neurological Surgeons. All rights reserved.

This is an open access article published by Thieme under the terms of the Creative Commons Attribution-NonDerivative-NonCommercial-License, permitting copying and reproduction so long as the original work is given appropriate credit. Contents may not be used for commercial purposes, or adapted, remixed, transformed or built upon. (<https://creativecommons.org/licenses/by-nc-nd/4.0/>)

Thieme Medical and Scientific Publishers Pvt. Ltd., A-12, 2nd Floor, Sector 2, Noida-201301 UP, India

Introduction

The clinical pathogenesis of stroke due to internal carotid artery stenosis involves plaque disruption and hemodynamic cerebral blood flow reduction, both of which are caused by atherosclerotic plaque. Treatment of plaques using statins and other drugs has been shown to inhibit the progression of intima-media complex thickening. Carotid artery stenosis models have been established in small animals,¹ but these models induce intimal thickening by causing endothelial damage using balloon catheters.² One study reported that a carotid artery stenosis model using mini pigs induced intimal thickening similar to the atherosclerotic plaque by partially ligating the carotid artery, changing the hemodynamics, and administering a high cholesterol diet.³

We thus attempted to induce plaque in rat carotid arteries, believing that it would be a highly versatile disease model if we could induce intimal thickening similar to atherosclerotic plaque. On our first attempt, we surgically exposed the carotid artery of rats, ligated it at one point with a 0.3-mm wire, and removed the wire. Carotid arteries from rats reared for the prescribed number of weeks were harvested, and 5- μ m sections of tissue were stained with hematoxylin-eosin and Elastica van Gieson. Observation of the presence of intimal thickening and the condition of the adventitia under an optical microscope confirmed the occurrence of intimal thickening in some rats. Around 25% of the rats kept for 8 weeks and fed a high cholesterol diet showed a high degree of intimal thickening.⁴ However, because the occurrence of severe intimal thickening took longer than 8 weeks and the frequency was 25% in previous studies, we considered that both the degree and frequency of intimal thickening were not sufficient as a model for plaque induction. In the current study, we aimed to create an improved versatile disease model to evaluate the pharmacokinetics of drug administration, determine the efficacy of treatment,

examine the process of intimal thickening, and increase the changes in hemodynamic stress induced by partial ligation to make the occurrence of intimal thickening shorter, more frequent, and more severe.

Materials and Methods

Surgery and Breeding

Seventy-two male Wistar rats weighing 250 to 300 g were used for the experiments. The rats were reared with free access to water and food except during experiments. The subjects were placed under inhalation anesthesia with isoflurane, and the right carotid artery was surgically exposed. The right carotid artery was completely ligated with a wire and 6-0 nylon thread, and the wound was closed with only the wire removed and partially ligated (**Fig. 1A,B**). The left carotid artery was exposed for use as a control. A single lesion group with a 0.25-mm wire and one ligature point and a tandem lesion group with a 0.3-mm wire and two ligature points were created for each of the 72 rats. The rats were divided into normal diet and high cholesterol diet groups, with 6 rats in each group grown for 4, 8, and 16 weeks. The normal diet group was given CE-2 344.9 kcal/100 g (CLEA Japan, Inc. Tokyo Japan), while the high cholesterol diet group was given HFD-60 506.2 kcal/100 g (Oriental Yeast Co., Ltd. Tokyo Japan). The rats were allowed to freely consume food during rearing. After the prescribed number of weeks of rearing, the animals were sacrificed for pathological examination. The carotid artery of the non-surgical side (left) was used as control after 16 weeks of rearing.

Pathological Examination

The samples were fixed by immersion, and 20, 5- μ m sections were cut out. All vessels collected were cut out in the direction of cutting 20, 5- μ m sections again at 100 μ m intervals. Five sections were selected at approximately equal

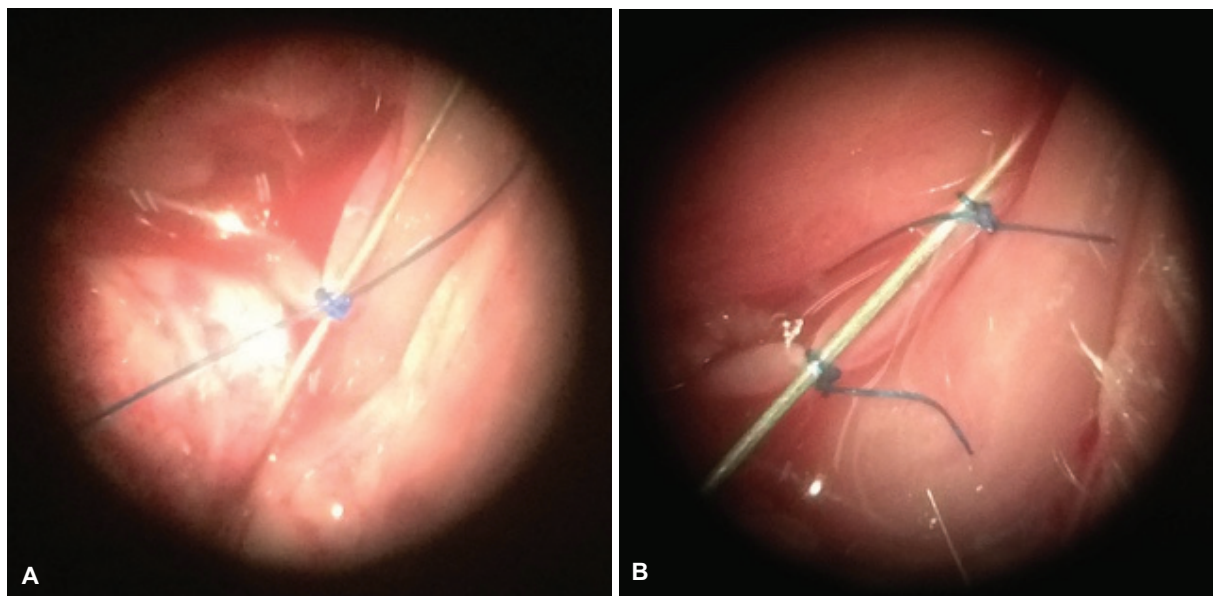


Fig. 1 (A) Single lesion. (B) Tandem lesion.

intervals from each specimen and stained with Hematoxylin–eosin. Then, samples were observed under an optical microscope for the presence of intimal thickening and the condition of the adventitia. For those that developed intimal thickening, the thickness was measured under the microscope, and the stenosis rate was calculated as the thickness of the intimal thickening relative to the vessel inner diameter using the following formula: (thickened inner membrane [μm]/vessel inner diameter [μm]) \times 100%. A stenosis rate of 70% or more was defined as severe stenosis. A stenosis rate of 100% was defined as lumen occlusion, wherein the vessel lumen could not be confirmed due to severe intimal thickening. Body weight and cholesterol levels of the rats were measured at 4, 8, and 16 weeks after the start of rearing and compared between the normal diet and high cholesterol diet groups.

Computational Fluid Dynamic Modeling

Measurements were taken based on the body weight, blood pressure, and blood flow and two rats. An analytical model was created for rat A with one ligature and rat B with two ligatures, and conditions were set accordingly. Rat A weighed 247 g, while rat B weighed 244 g. Blood pressure was $107.0 \pm 2.6/87.7 \pm 3.5$ mmHg in rat A and $110.0 \pm 3.0/85.7 \pm 4.2$ mmHg in rat B. Blood flow rates were 7.63 ± 1.0 mL/min for rat A and 9.03 ± 0.4 mL/min for rat B. Blood pressure and blood flow rates were averaged over three measurements.

Computational Grid Creation

Rat A was modeled for inlet and outlet, with introductions over five times the pipe diameter before and after the constriction. The tetra mesh size was about 1/10 of the pipe diameter and was averaged from the flow model and converted to flow velocity.

The parameters for rat B were calculated under the same conditions as those of rat A. The length between the stenoses was designed to be 5 mm. The prism mesh was used near the surface of the wall. The diameter thickness (FO) was calculated using the following formula:

$$y_p = \sqrt{\frac{vr}{2u_{max}}}$$

The dimensionless number of distances from the wall at the first grid point (FO) was obtained using the following formula:

$$y^* = \frac{u' y_p - y_p}{v} \sqrt{v \left| \frac{\partial u}{\partial r} \right|_{r=R}} \cong 1.$$

Therefore, the conditions for accurate numerical analysis are satisfied.

Parameters

The following parameters were measured for rat A: flow velocity at the entrance and exit of stenosis, mean entrance pressure, mean exit pressure, and wall shear stress (WSS). In contrast, the following parameters were measured for rat B: flow velocity at central lateral stenosis entrance and peripheral stenosis entrance, mean inlet pressure, mean outlet pressure, and WSS.

Statistical Analysis

All measurements are presented as mean \pm standard deviation. The *t*-test and chi-square test were used for comparison between the two groups. Intimal thickening and endothelial cell proliferation were measured using the AxioVision (Carl Zeiss Oberkochen Germany). A risk rate of less than 5% ($p < 0.05$) was considered statistically significant.

Results

Single Lesion Group

Normal Diet

Three rats in the 4-week group, 5 rats in the 8-week group, and 4 rats in the 16-week group showed intimal thickening (**Fig. 2A**). The incidence of intimal thickening was 66%, and among those with intimal thickening, the percentage of severe stenosis, in which the stenosis rate exceeds 70%, was 66% (**Fig. 2B**). In addition, some fibrous changes were observed within the intimal thickening in the 16-week-old rats (**Fig. 2C**).

High Cholesterol Diet

Two rats in the 4-week group, 3 rats in the 8-week group, and 4 rats in the 16-week group showed intimal thickening (**Fig. 2A**). The incidence of intimal thickening was 50%, and 5.5% of those with intimal thickening developed severe stenosis with a stenosis rate exceeding 70% (**Fig. 2D**).

Tandem Lesion Group

Normal Diet

Five rats in the 4-week group, 2 rats in the 8-week group, and 4 rats in the 16-week group showed intimal thickening (**Fig. 3A**). The incidence of intimal thickening was 61%, and among those with intimal thickening, 36% had severe stenosis with a stenosis rate exceeding 70% (**Fig. 3B**).

High Cholesterol Diet

Three rats in the 4-week group, 4 rats in the 8-week group, and 2 rats in the 16-week group showed intimal thickening (**Fig. 3A**). In addition, some rats showed circumferential intimal thickening (**Fig. 3C**). The incidence of intimal thickening was 50%, and 44% of those with intimal thickening had severe stenosis with a stenosis rate exceeding 70% (**Fig. 3D**).

Controls

The left common carotid artery, which was not involved in the surgical procedure, was examined as a control. No intimal thickening was observed in this group (**Fig. 4A,B**).

Body Weight

As shown in **Fig. 5A**, body weights of the rats that were given normal diet were as follows: 415 ± 15.8 g for the 4-week group, 487.8 ± 48.3 g for the 8-week group, and 659 ± 53.5 g for the 16-week group. In contrast, the body weights of rats that were given high cholesterol diet were as

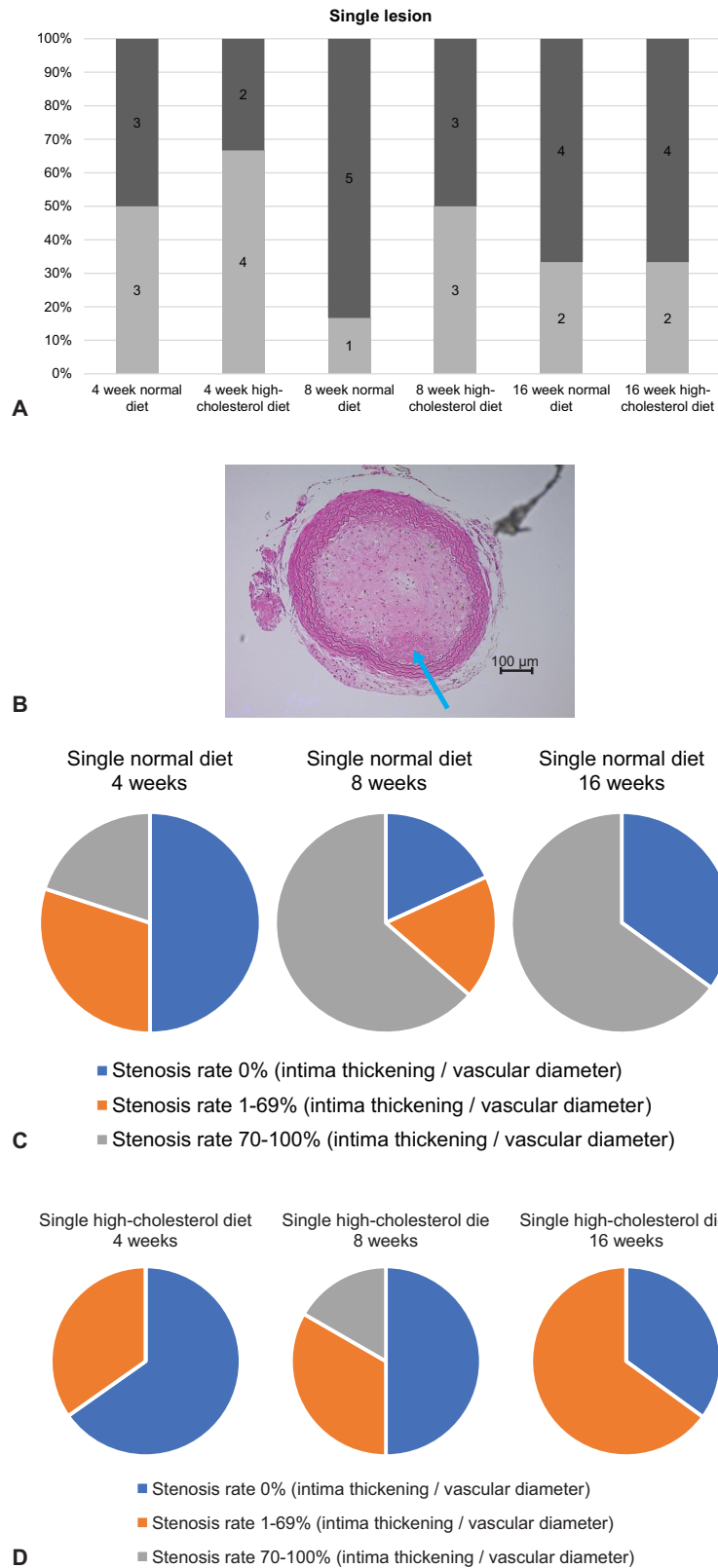


Fig. 2 (A) The number of intimal thickening events in the single lesion group according to diet and number of weeks of rearing. The frequency of intimal thickening was similar in individuals fed a normal diet and in those fed a high-cholesterol diet. (B) Hematoxylin–eosin staining of a rat from the single lesion group reared for 16 weeks on a normal diet. The lumen of the vessel is completely occluded by intimal thickening. Some of the lesions are accompanied by fibrotic changes (*blue arrows*). (C) Distribution of stenosis rate by the number of weeks of rearing on a normal diet. More than 66% of the population reared for 8 and 16 weeks had severe stenosis. (D) Distribution of stenosis rate by the number of weeks of rearing on high cholesterol diet. The incidence of intimal thickening and severe stenosis is lower in all groups than in the normal diet group.

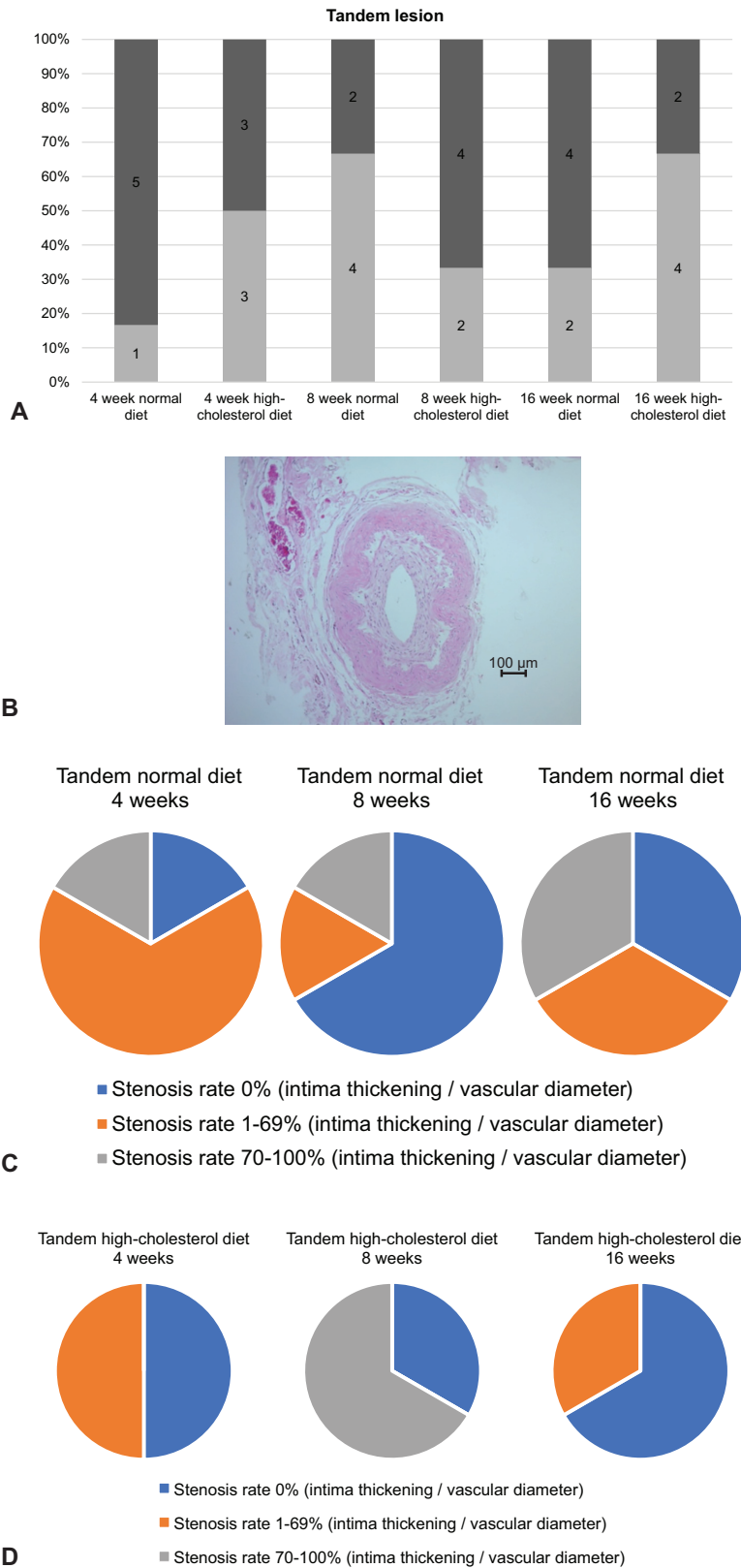


Fig. 3 (A) The number of intimal thickening occurrences in the tandem lesion group by diet and number of weeks of rearing. The frequency of intimal thickening was similar in individuals fed a normal diet and in those fed a high cholesterol diet. (B) Hematoxylin-eosin staining of a rat from the tandem lesion group raised for 16 weeks on a high cholesterol diet. Intimal thickening was observed uniformly around the entire circumference. (C) Distribution of stenosis rate by the number of weeks of rearing on a normal diet. The incidence of intimal thickening was higher in the group reared for 4 weeks, and some individuals showed severe stenosis. (D) Distribution of stenosis rate by the number of weeks of rearing on high cholesterol diet. The incidence of intimal thickening is lower than in the other groups, but the incidence of severe stenosis is higher in the group reared for 8 weeks.

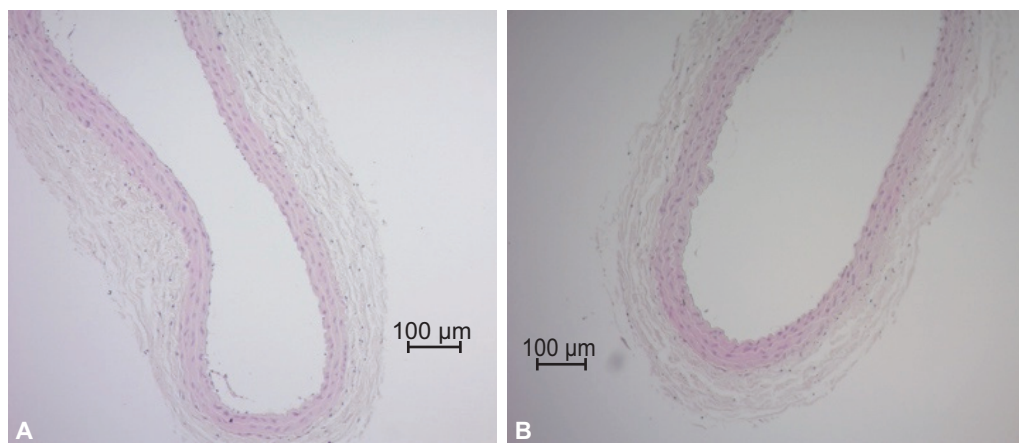


Fig. 4 (A) Hematoxylin–eosin staining of the left common carotid artery of a control rat reared for 16 weeks on a normal diet. (B) Hematoxylin–eosin staining of the left common carotid artery of a control rat reared for 16 weeks on a high cholesterol diet.

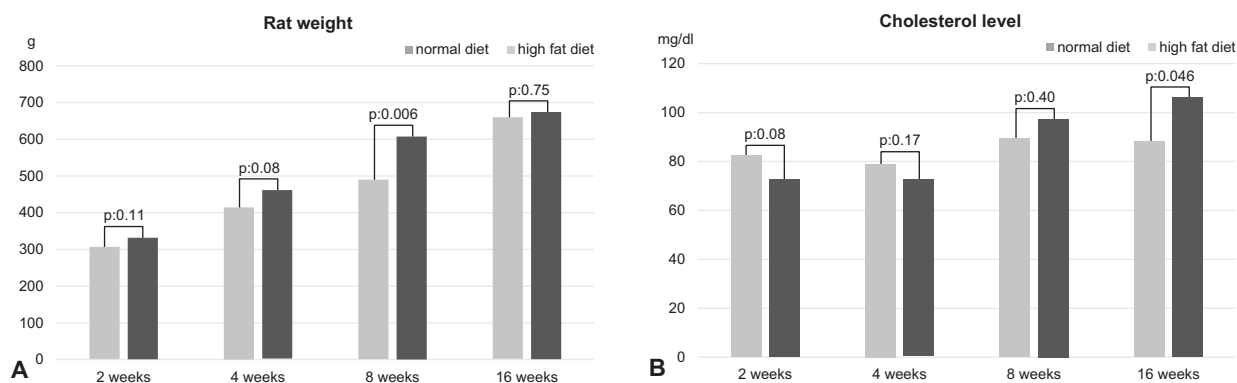


Fig. 5 (A) Comparison of body weights by the number of weeks of rearing on normal and high cholesterol diets. A significant difference in body weight was observed only in the 8-week rearing group. (B) Comparison of cholesterol levels by the number of weeks of rearing on normal and high cholesterol diets. Significant differences in cholesterol levels were observed only in the 16-week rearing group.

follows: 461 ± 40.3 g for the 4-week group, 608 ± 31.5 g for the 8-week group, and 673 ± 62.9 g for the 16-week group.

Serum Cholesterol Levels

► **Figure 5B** shows the serum cholesterol levels of the different groups. Serum cholesterol levels for the rats given normal diet were as follows: 79.25 ± 7.8 mg/dL for the 4-week group, 89.75 ± 8.5 mg/dL for the 8-week group, and 88.5 ± 4.5 mg/dL for the 16-week group. Serum cholesterol levels for the rats given high cholesterol diet were as follows: 72.5 ± 3.8 mg/dL for the 4-week group, 97.75 ± 15.6 mg/dL for the 8-week group, and 106.75 ± 13.7 mg/dL for the 16-week group.

Computational Fluid Dynamic

The model was created using the blood pressure and blood flow data of rats in the single lesion group and tandem lesion group. In the single lesion group, the axial velocity reached its maximum value at the stenosis, 3.74 m/s. The average inlet pressure was 51 mmHg, while the average outlet pressure was 0 mmHg. The maximum WSS was 1,380 Pa at the central side of the ligature (► **Fig. 6A**). However, the WSS

after the ligature is lower because the flow past the ligature is like a jet stream.

In the tandem lesion group, the axial velocity reached its maximum value at the stenosis, 3.74 m/s. The mean inlet pressure was 97.4 mmHg, while the mean outlet pressure was 0 mmHg. The maximum WSS on the central side of the central ligature was 1,530 Pa. The maximum WSS on the central side of the peripheral ligature was 1,520 Pa (► **Fig. 6B**). As in the single lesion group, the WSS after the ligature was low to almost zero, but the difference was greater in the tandem lesion group.

Discussion

The initial stage of atherosclerosis is characterized by vascular endothelial cell damage and increased permeability. This is followed by smooth muscle proliferation and endothelial deposition of low-density lipoprotein cholesterol. Then, migration of macrophages occurs leading to inflammation. This is known as the response to injury hypothesis.⁵

Computational fluid dynamic (CFD) has been performed in stenotic lesions of the carotid artery in humans and

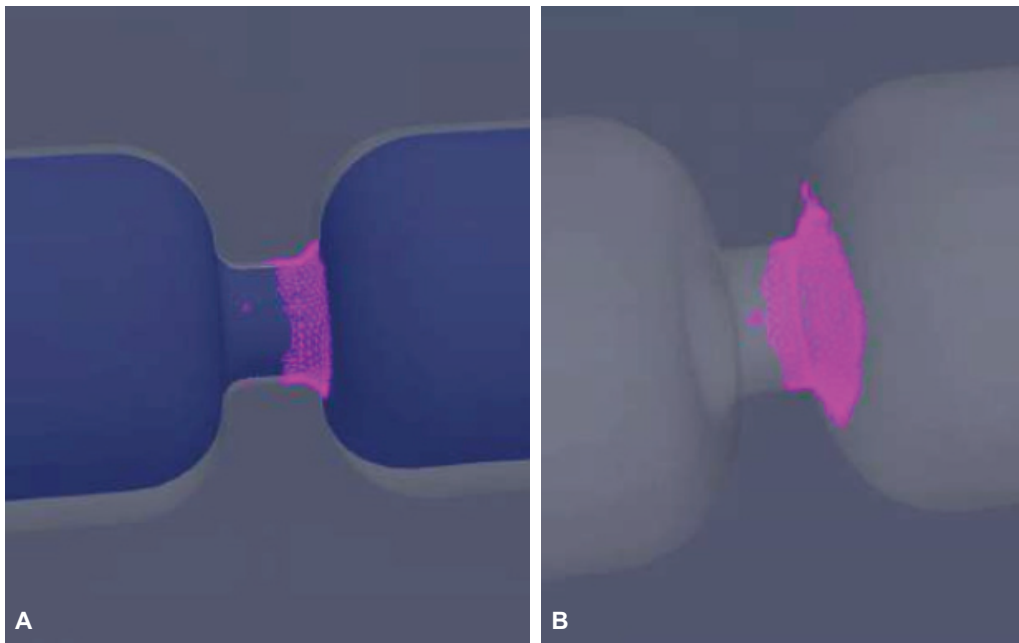


Fig. 6 (A) Wall shear stress was found to be higher on the central side of the stenosis in the single lesion group. (B) Wall shear stress was found to be higher on the central side of the central stenosis in the tandem lesion group.

healthy subjects. It has been reported that a decrease in pressure, flow velocity, and WSS changes occur in the normal internal carotid artery immediately after the stenotic lesion and immediately after the branching from the common carotid artery. Moreover, changes and disturbances in WSS lead to increased turnover of endothelial cells and intimal thickening.⁶ Based on these reports, we hypothesized that intimal thickening occurred in our initial model because WSS changes induced the initial steps in the above hypothesis, including endothelial damage and increased permeability. We then hypothesized that the intensification of WSS changes would facilitate the development of intimal thickening.

In the current study, we changed the intensity and frequency of artificial stenosis compared to our previous studies. In the single lesion group, the wire ligated with the vessel was changed from 0.3 mm to 0.25 mm in terms of stenosis intensity. The change in stenosis frequency was defined as a tandem lesion ligated with a 0.3-mm wire at two points.

In the single lesion group, the WSS is highly elevated in the artificially stenosed area, and this could be attributed to the more pronounced stagnation and turbulent blood flow at the peripheral side of the artificially stenosed area. In the tandem lesion, WSS was higher at both of the two artificial stenosis sites, suggesting that stagnation and turbulence of blood flow at the peripheral side of the artificial stenosis caused the change in WSS.

It has been reported that in areas where the wall shear velocity is low, lipids synthesized in the arterial wall diffuse out of the vessel wall in a flow-dependent manner and accumulate in the vessel wall, thereby controlling atheroma formation by local wall shear velocity.⁷ Additionally, low WSS and oscillatory shear stress promote monocyte adhesion to endothelial cells by increasing the expression of

vascular adhesion molecule-1 (VCAM-1), which binds to integrins expressed on leukocytes, thereby inducing adhesion and invasion of endothelial cells.⁸ Many other studies have reported that WSS reduction induces plaque.^{9–20} In an experiment using a template to induce changes in blood flow in the carotid artery of mice, it was reported that WSS was reduced in a wider area centrally than the stenosis area.²¹ However, intimal thickening tended to be greater around the stenosis, suggesting that low WSS is not the only trigger for intimal thickening. CFD analysis performed in the current study also showed that WSS was increased at the artificial stenosis site (►Fig. 6A,B), and intimal thickening also occurred at that site. It has been reported that not only low WSS but also directionally fluctuating WSS is an important blood flow stimulus for inducing vascular lesions.²² Thus, it can be inferred that changes in WSS direction at artificial stenoses also play an important role in inducing inflammation in the endothelium.

As shown in ►Fig. 5A, there was a significant difference in body weight between the normal diet group and the high cholesterol diet group at 8 weeks of rearing. However, no significant difference in body weight was found at 4 weeks and 16 weeks of rearing. In contrast, as shown in ►Fig. 5B, significant differences in cholesterol levels were observed only in the 16-week rearing group. However, the incidence of intimal thickening was not higher in the 8-week rearing group, which showed a significant difference in body weight, nor in the 16-week rearing group, which showed a significant difference in cholesterol levels, both in the single lesion and tandem lesion groups. In particular, in the single lesion group, more individuals on the normal diet had a stenosis rate of more than 70% despite lower cholesterol levels than those on the high cholesterol diet. Various factors contribute to the development of atherosclerosis, including abnormal

lipid metabolism, hypertension, diabetes, smoking, and chronic kidney disease in the human body.²³ According to the response to injury hypothesis, lipid accumulation occurs after endothelial cell injury followed by the subendothelial invasion of monocytes and T-lymphocytes.⁵ Considering that intimal thickening occurred regardless of cholesterol levels in this study and that the pathological findings of the sampled intimal thickening did not show lipid deposition, we may be looking at an early stage of atherosclerosis. Changes in vascular morphology and hemodynamic stress due to artificial vascular stenosis may have also been a direct cause of endothelial cell injury.

In our previous study, the incidence of intimal thickening due to carotid ligation in rats was only 25%. In contrast, the incidence of intimal thickening in both the single and tandem lesion groups in the present study was more than 50%. In addition, while it was previously reported that intimal thickening required 8 weeks to occur, more than 40% of the single lesion group showed intimal thickening even after just 4 weeks of rearing. In particular, more than 70% of the animals in the normal diet group showed severe stenosis after 4 weeks of rearing.

The frequency of intimal thickening is increased in the 8-week and 16-week rearing populations of the single lesion group, with a frequency of at least 66% in both rearing subgroups. In addition, 28% of the single lesion group as a whole had a high degree of stenosis of 70% or more (→Fig. 2). This suggests that the frequency of intimal thickening increased in individuals reared for more than 4 weeks by increasing the artificial stenosis and the number of artificial stenoses. Thus, in this study, we have succeeded in inducing intimal thickening within a shorter period compared to previous reports. In addition, while other reports have used pigs and ApoE^{-/-} mice,^{2,11} in this study, we were able to create a model using rats, which are easy to maintain.

Both the surgery to create a single lesion and the surgery to create a tandem lesion could be performed within a short period of about 10 minutes per individual to create artificial stenosis. It did not take much time to create the model compared to previous methods. Furthermore, in terms of rearing, we were able to observe the development of intimal thickening without administering an expensive high-cholesterol diet, and we were able to obtain a higher frequency of intimal thickening within a shorter period than in our previous studies.

Conclusion

The incidence of intimal thickening after artificial stenosis and the rate of vascular stenosis due to intimal thickening was higher in the current study than in previous studies. A comparison of the single lesion and tandem lesion groups showed a tendency to induce intimal thickening earlier in the latter. This may be due to the changes in hemodynamic stress, which may have triggered intimal thickening. Because this study was able to confirm intimal thickening in a relatively stable rat model, we expect to be able to confirm

changes over time in the effects of medication on intimal thickening and plaque in the future.

Authors' Contributions

Study conception and design: Akira Wakako and Akiyo Sadato. Surgical instruction: Motoki Oeda. Data collection: Akira Wakako and Saeko Higashiguchi. CFD Data analysis: Marie Oshima, Motoharu Hayakawa, and Akira Wakako. Writing of the article: Akira Wakako. Revision of the article: all authors. All co-authors have reviewed the paper and given permission for submission.

Ethics Approval

This study was conducted under the Regulations for the Management of Laboratory Animals at Fujita Health University and was submitted for approval by Institutional Animal Care and Use Committee.

Note

A part of the research was presented at The Japan Stroke Society Annual Meeting held on August 26, 2020.

Conflict of Interest

None declared.

References

- 1 Getz GS, Reardon CA. Animal models of atherosclerosis. *Arterioscler Thromb Vasc Biol* 2012;32(05):1104–1115
- 2 Orozco LD, Liu H, Chen BB, Fratkin JD, Perkins E. Angiographic evaluation of the rat carotid balloon injury model. *Exp Mol Pathol* 2011;91(02):590–595
- 3 Ishii A, Viñuela F, Murayama Y, et al. Swine model of carotid artery atherosclerosis: experimental induction by surgical partial ligation and dietary hypercholesterolemia. *Am J Neuroradiol* 2006;27(09):1893–1899
- 4 Oheda M. Preparation and histological evaluation of a carotid artery stenosis model in small animals [Ph.D. dissertation]. Toyoake, Aichi, Japan: Fujita Health University; 2016
- 5 Ross R. Atherosclerosis—an inflammatory disease. *N Engl J Med* 1999;340(02):115–126
- 6 Filardi V. Carotid artery stenosis near a bifurcation investigated by fluid dynamic analyses. *Neuroradiol J* 2013;26(04):439–453
- 7 Caro CG, Fitz-Gerald JM, Schroter RC. Atheroma and arterial wall shear. Observation, correlation and proposal of a shear dependent mass transfer mechanism for atherogenesis. *Proc R Soc Lond, B* 1971;177(1046):109–159
- 8 Berger SA, Jou LD. Flows in stenotic vessels. *Annu Rev Fluid Mech* 2000;32(01):347–382
- 9 Malek AM, Alper SL, Izumo S. Hemodynamic shear stress and its role in atherosclerosis. *JAMA* 1999;282(21):2035–2042
- 10 Dirksen MT, van der Wal AC, van den Berg FM, van der Loos CM, Becker AE. Distribution of inflammatory cells in atherosclerotic plaques relates to the direction of flow. *Circulation* 1998;98(19):2000–2003
- 11 VanderLaan PA, Reardon CA, Getz GS. Site specificity of atherosclerosis: site-selective responses to atherosclerotic modulators. *Arterioscler Thromb Vasc Biol* 2004;24(01):12–22
- 12 Stone PH, Coskun AU, Kinlay S, et al. Effect of endothelial shear stress on the progression of coronary artery disease, vascular remodeling, and in-stent restenosis in humans: in vivo 6-month follow-up study. *Circulation* 2003;108(04):438–444
- 13 Chatzizisis YS, Jonas M, Coskun AU, et al. Prediction of the localization of high-risk coronary atherosclerotic plaques on

- the basis of low endothelial shear stress: an intravascular ultrasound and histopathology natural history study. *Circulation* 2008;117(08):993–1002
- 14 Wentzel JJ, Chatzizisis YS, Gijzen FJ, Giannoglou GD, Feldman CL, Stone PH. Endothelial shear stress in the evolution of coronary atherosclerotic plaque and vascular remodelling: current understanding and remaining questions. *Cardiovasc Res* 2012;96(02):234–243
 - 15 Eshtehardi P, McDaniel MC, Suo J, et al. Association of coronary wall shear stress with atherosclerotic plaque burden, composition, and distribution in patients with coronary artery disease. *J Am Heart Assoc* 2012;1(04):e002543
 - 16 Koskinas KC, Sukhova GK, Baker AB, et al. Thin-capped atheromata with reduced collagen content in pigs develop in coronary arterial regions exposed to persistently low endothelial shear stress. *Arterioscler Thromb Vasc Biol* 2013;33(07):1494–1504
 - 17 Vergallo R, Papafaklis MI, Yonetsu T, et al. Endothelial shear stress and coronary plaque characteristics in humans: combined frequency-domain optical coherence tomography and computational fluid dynamics study. *Circ Cardiovasc Imaging* 2014;7(06):905–911
 - 18 Papafaklis MI, Takahashi S, Antoniadis AP, et al. Effect of the local hemodynamic environment on the de novo development and progression of eccentric coronary atherosclerosis in humans: insights from PREDICTION. *Atherosclerosis* 2015;240(01):205–211
 - 19 Han D, Starikov A, ÓHartaigh B et al. Relationship between endothelial wall shear stress and high-risk atherosclerotic plaque characteristics for identification of coronary lesions that cause ischemia: a direct comparison with fractional flow reserve. *J Am Heart Assoc* 2016;5(12):e004186
 - 20 Timmins LH, Molony DS, Eshtehardi P, et al. Oscillatory wall shear stress is a dominant flow characteristic affecting lesion progression patterns and plaque vulnerability in patients with coronary artery disease. *J R Soc Interface* 2017;14(127):20160972
 - 21 Xing R, Moerman AM, Ridwan Y, et al. Temporal and spatial changes in wall shear stress during atherosclerotic plaque progression in mice. *R Soc Open Sci* 2018;5(03):171447
 - 22 Ku DN, Giddens DP, Zarins CK, Glagov S. Pulsatile flow and atherosclerosis in the human carotid bifurcation. Positive correlation between plaque location and low oscillating shear stress. *Arteriosclerosis* 1985;5(03):293–302
 - 23 Nakano T, Ninomiya T, Sumiyoshi S, et al. Association of kidney function with coronary atherosclerosis and calcification in autopsy samples from Japanese elders: the Hisayama study. *Am J Kidney Dis* 2010;55(01):21–30