

Received: 2015.12.06  
Accepted: 2015.12.29  
Published: 2016.06.10

# White Matter Abnormalities in Patients with Treatment-Resistant Genetic Generalized Epilepsies

Authors' Contribution:  
Study Design A  
Data Collection B  
Statistical Analysis C  
Data Interpretation D  
Manuscript Preparation E  
Literature Search F  
Funds Collection G

ACDEF 1,2,3 **Jerzy P. Szaflarski**  
BCE 3 **Seongtaek Lee**  
CE 1 **Jane B. Allendorfer**  
BE 1,4 **Tyler E. Gaston**  
E 1,5 **Robert C. Knowlton**  
E 1 **Sandipan Pati**  
E 1,4 **Lawrence W. Ver Hoef**  
E 6 **Georg Deutsch**

1 Department of Neurology, University of Alabama at Birmingham, Birmingham, AL, U.S.A.  
2 Department of Neurobiology, University of Alabama at Birmingham, Birmingham, AL, U.S.A.  
3 Department of Biomedical Engineering, University of Alabama at Birmingham, Birmingham, AL, U.S.A.  
4 Department of Neurology, Birmingham VAMC, Birmingham, AL, U.S.A.  
5 Department of Neurology, University of California San Francisco, San Francisco, CA, U.S.A.  
6 Department of Radiology, University of Alabama at Birmingham, Birmingham, AL, U.S.A.

**Corresponding Author:** Jerzy P. Szaflarski, e-mail: [szaflaj@uab.edu](mailto:szaflaj@uab.edu)  
**Source of support:** Departmental sources

**Background:** Genetic generalized epilepsies (GGEs) are associated with microstructural brain abnormalities that can be evaluated with diffusion tensor imaging (DTI). Available studies on GGEs have conflicting results. Our primary goal was to compare the white matter structure in a cohort of patients with video/EEG-confirmed GGEs to healthy controls (HCs). Our secondary goal was to assess the potential effect of age at GGE onset on the white matter structure.





**Material/Methods:** A convenience sample of 23 patients with well-characterized treatment-resistant GGEs (13 female) was compared to 23 HCs. All participants received MRI at 3T. DTI indices, including fractional anisotropy (FA) and mean diffusivity (MD), were compared between groups using Tract-Based Spatial Statistics (TBSS).

**Results:** After controlling for differences between groups, abnormalities in DTI parameters were observed in patients with GGEs, including decreases in functional anisotropy (FA) in the hemispheric (left>right) and brain stem white matter. The examination of the effect of age at GGE onset on the white matter integrity revealed a significant negative correlation in the left parietal white matter region FA ( $R=-0.504$ ;  $p=0.017$ ); similar trends were observed in the white matter underlying left motor cortex ( $R=-0.357$ ;  $p=0.103$ ) and left posterior limb of the internal capsule ( $R=-0.319$ ;  $p=0.148$ ).

**Conclusions:** Our study confirms the presence of widespread white matter abnormalities in patients with GGEs and provides evidence that the age at GGE onset may have an important effect on white matter integrity.

**MeSH Keywords:** **Diffusion Magnetic Resonance Imaging • Diffusion Tensor Imaging • Epilepsy, Absence • Myoclonic Epilepsy, Juvenile**

**Full-text PDF:** <http://www.medscimonit.com/abstract/index/idArt/897002>

 2981  3  1  53



## Background

The most recent definition of genetic generalized epilepsies (GGEs) abandons the term “generalized onset” and the idea of the involvement of the entire cortex in seizure origination, in lieu of a new definition that purports that a portion of the bilaterally distributed seizure network generates the ictal discharge [1–3]. While seizure onset may appear to be localized, with focal clinical symptoms present in up to 64% of patients [4], based on this new definition, the localization and even lateralization of seizure onset may be changing from one seizure to another and from one individual to another. At present, the role of cortical oscillations in generating generalized spike and wave discharges (GSWDs) and the role of the thalamus in maintaining generalized discharges and seizures are emphasized [5–7].

In general, epilepsy is considered to be a disorder of abnormal structural and functional connections between neurons and/or groups of neurons [8]. In recent years, neuroimaging has allowed us to build dynamic models of brain activity and assess structural (SC) and functional connectivity (FC) in the brain. These 2 measures are considered to reflect each other: SC (measured with DTI) assesses the direct connections between various brain structures, while FC (measured with fMRI) assesses the functional interactions between regions that are not necessarily connected directly but may be connected via a third region [9]. Applying these concepts to patients with GGEs is important because in these patients the site of seizure onset and the origin of GSWDs continue to be questioned. It is clear that while at least 1 node of the network for seizure generation and maintenance needs to generate the epileptiform discharge, there is rapid involvement of the entire network in the event, which results in clinical presentation of an absence, myoclonic, or generalized seizure; the node involved in the generation of GSWDs and seizures may be different depending on, for example, the epilepsy syndrome and clinical response to antiepileptic drugs (AEDs) [1,10,11].

In addition to a number of EEG [12,13], structural [14,15], spectroscopy and EEG/fMRI [16,17], and neuropsychological studies [18–20], recent efforts in patients with GGEs have focused on the evaluation of structural and functional connectivity. One study in 10 patients with juvenile myoclonic epilepsy (JME) found the most reduced functional anisotropy (FA) in white matter tracts connecting the anterior thalamus and prefrontal cortices; the reduction in FA was proportional to the number of generalized tonic-clonic seizures experienced by participants [21]. A larger study identified reduction in structural connectivity (reduced FA and increased mean diffusivity [MD]) of the supplementary motor area in patients with JME compared to controls and patients with frontal lobe epilepsies [22]. In this, and in other studies, for example, Du et al. [23],

the differences between healthy controls and patients with GGEs were greater on the left than on the right. Other studies identified additional areas of white matter involvement, with these abnormalities associated with disease severity [24,25]. Thus, the importance of studying white matter integrity with DTI lies in the fact that identifying the underlying abnormalities in structural connectivity may help to determine the cause of the GGEs (or the reasons for treatment refractoriness) and evaluate the long-term effects of GGEs on brain function, including cognitive and behavioral disturbances.

Various approaches have been used for the evaluation of white matter structural connectivity in GGEs. Some studies have examined the integrity of specific white matter tracts [25]. Other studies have restricted their analyses to specific and predefined brain regions [26] or have utilized whole-brain white matter investigations to derive indices specific to various brain regions, including thalamo-cortical connections [21], corona radiata and corpus callosum [24], or corpus callosum underlying reductions in gray matter volume [27]. Our primary goal was to compare the white matter structure in a cohort of patients with video/EEG-confirmed GGEs to healthy controls with the hypothesis that patients with GGEs exhibit abnormalities in structural connectivity (DTI) compared to healthy controls. Our secondary goal was to assess the potential effect of age at GGE onset on the white matter structure.

## Material and Methods

### Participants

Data from 23 patients with a diagnosis of GGE (13 females, mean age: 26±11 years; Table 1) and 23 healthy controls (18 females; mean age: 50±15 years) were included. Patients with GGE were identified retrospectively through review of a prospective database maintained by the University of Alabama at Birmingham Epilepsy Center. All included patients underwent standard MRI for clinical purposes as requested by the managing epilepsy specialist and had the diagnosis of sole GGE confirmed by video/EEG monitoring based on the results of EEG (presence of GSWDs) and ictal characteristics. All patients were treatment-resistant at the time of enrollment, with frequent clinical seizures noted despite syndrome-appropriate treatment with antiepileptic drugs (AEDs); in all cases, history was confirmed by a board-certified or board-eligible epilepsy specialist. Subsequent to enrollment, several patients became seizure-free, defined as no clinical seizures for the 6 months preceding the last contact (Table 1). We excluded patients with history of definite or suspected comorbid non-epileptic seizures, focal or poorly defined/unclassified epilepsies, non-diagnostic video/EEG monitoring, or patients with significant neurological comorbidity (e.g., brain tumors, traumatic brain injury, or mental

**Table 1.** Demographics and clinical characteristics of the included patients with the diagnosis of GGE.

Patient ID	Age	Sex	Age of onset	Duration of epilepsy (years)	Seizure free at the last appointment**	Semiology classification	The number of AEDs at time of scan
P1	28	F	27	1	No	oGGE	2
P2	21	M	9	12	Yes	JAE	2
P3	25	F	-	-	No	JME	2
P4	25	M	20	5	Yes	oGGE	1
P5	18	F	17	1	Yes	oGGE	1
P6	33	F	33	0.08	Yes	oGGE	1
P7	17	M	14	3	Yes	JME	1
P8	56	M	24	32	No*	oGGE	3
P9	20	M	20	0.08	Yes	JME	1
P10	18	F	8	10	No	JS	1
P11	33	M	16	17	No	JS	2
P12	20	F	17	3	Yes	oGGE	2
P13	20	M	16	4	Yes	JME	0
P14	17	F	10	7	No	JAE	2
P15	58	M	18	40	Yes	oGGE	2
P16	36	F	17	19	No	oGGE	2
P17	18	F	12	6	Yes	oGGE	1
P18	18	F	6	12	No*	JME	1
P19	21	F	12	9	Yes	oGGE	2
P20	17	F	14	3	No	oGGE	1
P21	25	M	22	3	No	JME	1
P22	19	F	19	0.083	Yes	JAE	1
P23	25	M	0	25	No	oGGE	4

Patients were determined to be seizure if no seizures were reported for at least 6 months and in patients who ever experienced absence seizures at least a 24-hour EEG was negative for undetected absence seizures. JME – Juvenile Myoclonic Epilepsy; JAE – Juvenile Absence Epilepsy; JS – Jeavons Syndrome; oGGE – other Genetic Generalized Epilepsy; M – Male, F – Female; \*\* Seizure freedom was defined based on the eligibility to drive which is 6-months seizure free in the State of AL. No\* – data not available beyond discharge from the Epilepsy Monitoring Unit.

retardation). Based on the most recent epilepsy classification scheme, included patients were diagnosed with the following GGE syndromes: juvenile myoclonic epilepsy (JME; n=6), juvenile absence epilepsy (JAE; n=3), Jeavons syndrome (JS; n=2), and other GGEs (oGGE; n=12) [2]. The consent requirement was waived by the Institutional Review Board because of the retrospective nature of the study. Demographic and clinical data on patients with GGEs are summarized in Table 1. Healthy controls were selected from a convenience sample of subjects included

in 2 other prospective studies, and were matched as closely as possible for age with the patients with GGEs. All these subjects signed an informed consent form approved by the Institutional Review Board prior to study participation.

**Imaging protocol**

For the neuroimaging data, all diffusion tensor imaging (DTI) datasets were collected using a 3T Philips Achieva MRI scanner

**Table 2.** Diffusion Tensor Imaging (DTI) scan parameters for each subset of subjects included in the study (all subjects were scanned using Phillips Achieva 3T MRI scanner) [33].

	23 Patients	18 Controls	5 Controls
DTI			
Voxel size (mm)	1.70×1.70×2.00	1.75×1.75×2.00	1.60×1.60×2.00
FOV (mm)	244×244	224×224	256×256
TR (ms)	9939.66±282.40	11983.94±267.85	14535.13±120.06
TE (ms)	84.34±0.30	72	76.07±0.17
Slices	70	70	75
b-value (s/mm <sup>2</sup> )	800	800	1000

(Philips Medical Systems, Eindhoven, Netherlands). A 32-direction DTI scan was performed for all participants. The control datasets used for comparison with the GGE patients were obtained as part of 2 separate research studies. Due to the circumstances of the data collection, the MRI protocols used were similar but not exactly the same. DTI scanning parameters are provided in Table 2.

### Preprocessing of neuroimaging data

All structural and DTI scans were converted from DICOM (Digital Imaging and Communications in Medicine) format to the format native to the AFNI (Analysis of Functional Neuroimages) software package (<http://afni.nimh.nih.gov/>), which was used for the preprocessing of all DTI scans [28]. Specifically, the eddy current and motion corrections were carried out with AFNI “3dAllineate”, and the diffusion tensor model was calculated with AFNI “3dDWItoDT”. Finally, fractional anisotropy (FA), axial diffusivity (AD), radial diffusivity (RD), and mean diffusivity (MD) images were calculated and then converted to NIfTI (Neuroimaging Informatics Technology Initiative) format for use in Tract-Based Spatial Statistics (TBSS) analysis.

### Tract-based spatial statistics (TBSS) analysis

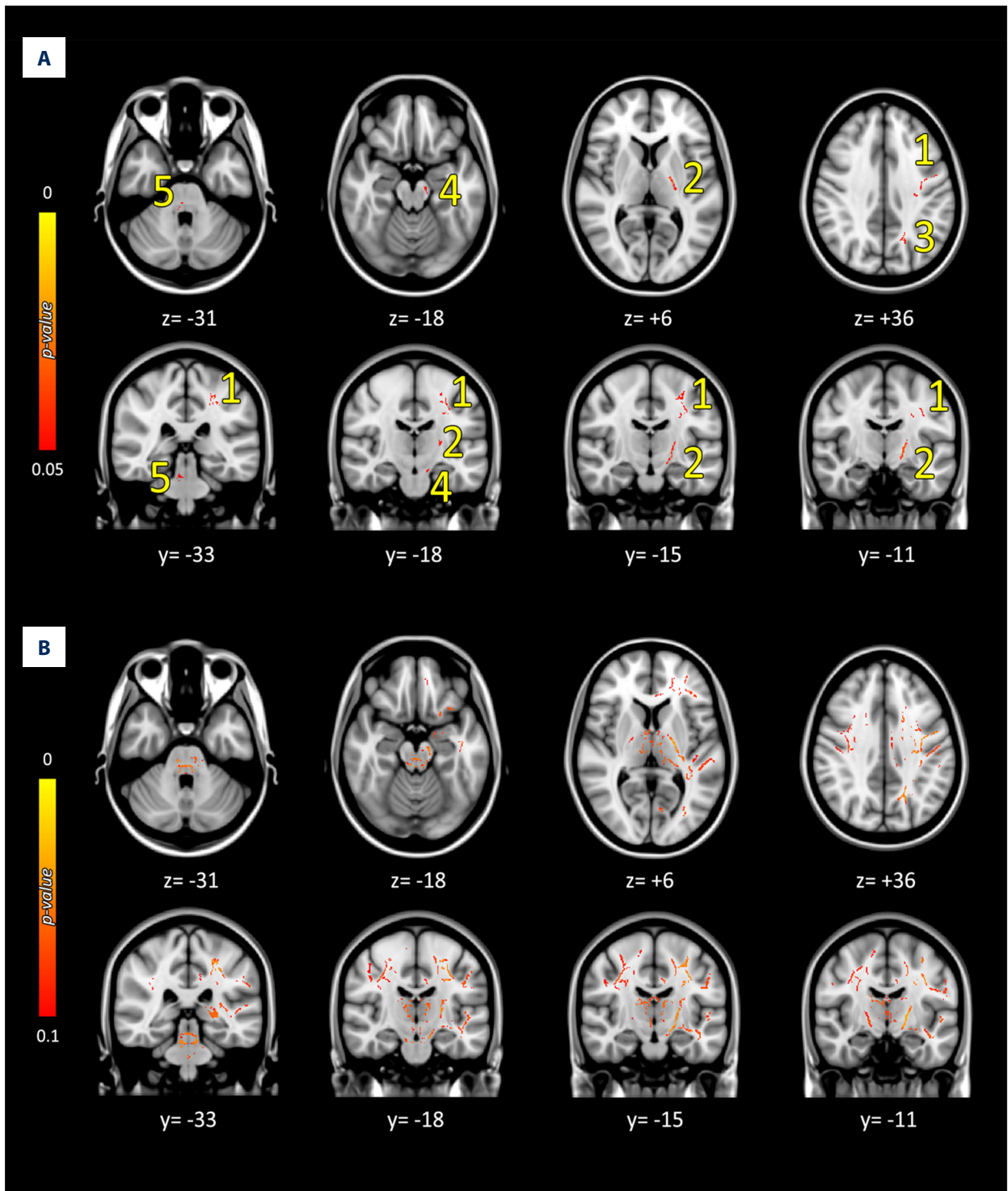
The voxelwise analysis of multi-subject DTI scans was performed using FSL TBSS following a protocol previously implemented in our laboratory [29–31]. Briefly, in the first step, every FA map was non-linearly co-registered to FMRIB58\_FA image, which is a high-resolution averaged image of well-aligned quality FA images in FSL. Next, a group mean FA image was created by averaging aligned FA images from all included participants (patients with GGEs and healthy controls). The mean FA image was thresholded at a FA value of 0.2 in order to include only the major white matter tracts and also to suppress areas of high inter-subject variability and/or partial grey matter [29]. Next, a skeletonized mean FA image was created

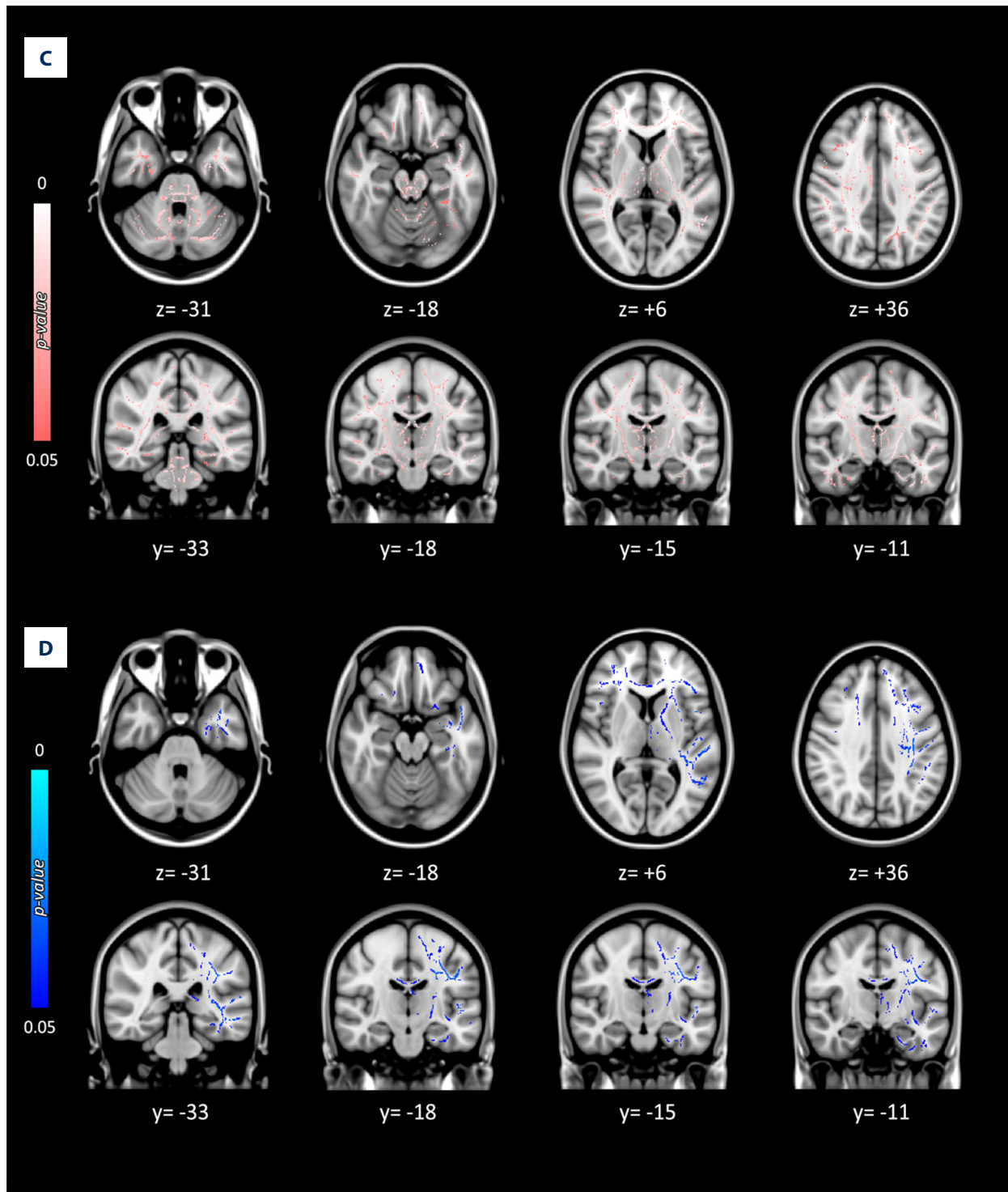
from the mean FA image. Non-parametric, independent t-tests were carried out for a group comparison of CGE patients versus healthy controls using FSL “randomise” with 5000 permutations [32]. For analyses of the other indices, such as MD, AD, and RD, the FA images were used for nonlinear registration, and, subsequently, nonlinearly aligned MD, RD, and AD were projected onto the FA skeleton image. The differences in diffusion indices between the 2 groups were considered significant at  $p < 0.05$  corrected (familywise error rate [FWE]) using threshold-free cluster enhancement (TFCE) [33]. The analyses were controlled for age and sex covariates by including them in our design matrix.

To further characterize the differences in the white matter clusters between patients with GGEs and healthy controls, we examined the relative changes in AD and RD in those regions identified to have significant differences in FA between groups. This was accomplished by applying the transformations used to derive the FA skeleton to AD and RD and then performing paired t-tests using the skeletonized AD and RD maps. In white matter clusters of interest that had significant FA differences at  $p < 0.05$  corrected for multiple comparisons, comparisons between groups of AD and RD were performed using “3dROIstats” in AFNI to determine if these indices also showed relative increases or decreases. Finally, an average diffusion index was calculated for each patient (i.e., an average FA/MD/AD for each patient) within each of the 5 regions included in Figure 1.

## Results

Demographic and clinical characteristics of our patients are presented in Table 1. Of the 23 patients with treatment-resistant GGEs, 13 were female (57%) and 18 of the 23 healthy controls were female (78%). Although the distribution of males and females was not statistically different between groups





**Figure 1.** Overview of decreased diffusion indices in GGE patients compared to healthy controls. Tract-Based Spatial Statistics (TBSS) results show representative slices of (A) decreased FA at  $p < 0.05$ , (B) decreased FA at  $p < 0.1$ , (C) decreased AD at  $p < 0.05$ , and (D) decreased MD at  $P < 0.05$ , corrected for the voxel-wise level family-wise error rate. The numbers (1–5) correspond to the clusters listed in Table 3. All the colored voxels represent decreased values in FA, AD, and MD in GGE; increases in the indices were not found in this study. The axial and coronal slices are displayed in radiological convention, where left in the image is right in the brain.

**Table 3.** Location and corresponding *t*-values for the areas showing significantly decreased fractional anisotropy (FA) in patients with GGEs when compared to healthy controls. Corresponding *t*-values reflecting relative changes in AD or MD are provided for all clusters that showed significantly different FA values between groups.

	Cluster location	Averaged <i>t</i> -values		
		FA	AD	MD
1	L Motor Cortex White Matter (Primary and Supplementary Motor Cortex)	1.7303	1.8586	1.1109
2	L Posterior Limb of Internal Capsule	1.7928	1.7716	0.7481
3	L Parietal White Matter	1.7290	1.4917	0.4409
4	L Brain Stem	1.6913	1.6434	0.7084
5	R Brain Stem	1.6914	2.0441	0.8777

The group differences in FA values were considered significant for  $p < 0.05$ , corrected for the voxel-level family-wise error rate. L – left; R – right.

( $p=0.208$ ), it could still be of clinical significance [34]. Further, healthy controls were older (mean age,  $50 \pm 15$  years; range, 24–78 years) than patients with GGEs (mean age,  $26 \pm 11$  years; range, 17–58 year); this difference was statistically significant at  $p < 0.001$ . Thus, both, sex and age were included in further analyses as co-variates.

After controlling for age and sex, several areas of decreased FA were noted in patients with GGEs (Table 3; Figure 1) when compared to healthy controls, including the corona radiata underlying primary and supplementary motor cortex in the left hemisphere extending into the posterior limb of the internal capsule and to the contralateral brain stem, left brain stem, and left subcortical parietal regions. After relaxing the *p*-value to 0.1, right hemispheric decreases in FA were also observed homologous to those observed at  $p=0.05$  in the left hemisphere (Figure 1B). Overall decreases in FA were observed in multiple other white matter regions of the left and right subcortical white matter (Figure 1B). Corresponding group differences in AD (Figure 1C) and MD (Figure 1D) were observed at  $p=0.05$ , but not for RD (data not shown).

Finally, the examination of the effect of the age at GGE onset on the white matter integrity revealed a significant correlation with the left parietal white matter region FA ( $R=-0.504$ ;  $p=0.017$ ); the FAs in other 2 regions trended towards significance (white matter underlying left motor cortex ( $R=-0.357$ ;  $p=0.103$ ) and left posterior limb of the internal capsule ( $R=-0.319$ ;  $p=0.148$ ). Other indices in these regions were not significant (all  $p > 0.2$ ). Duration of epilepsy had no association with FA (all  $p > 0.2$ ) or other indices except for the left brain stem diffusivity index (MD  $R=0.55584$ ;  $p=0.007$ ). We did not find a correlation between white matter indices and later seizure control (Table 1 – “seizure-free at the last appointment”) – all  $p > 0.1$ .

## Discussion

We compared the microstructural integrity of white matter in patients with GGEs to healthy controls. We also evaluated the effects of age at GGE onset on the white matter integrity, as this may be an important factor in the presentation and clinical characteristics of GGEs [35]. After controlling for age and sex, we found significant differences between groups that are bilateral but more pronounced on the left. Secondary analyses revealed a relationship between age at onset and the degree of FA changes. The implications of these findings are discussed below.

In general, patients with GGEs have been thought to have no detectable neuroimaging abnormalities and to have normal cognition [36]. However, with the advent of high-resolution MRI and modern analysis techniques, studies have identified subtle structural abnormalities in cortical and subcortical structures of patients with GGEs [14,23,37,38]. More recently, structural connectivity studies revealed changes in white matter structure, with some studies linking these abnormalities to cognitive deficits [24,39]. Our study adds to the growing body of evidence of the widespread structural brain abnormalities in patients with GGEs. The findings (Figure 1) of decreased FA in the white matter underlying the primary and supplementary motor cortex, posterior limb of the internal capsule, and the white matter in parietal lobe have been observed previously. We observed FA and other markers of white matter injury to be different in bilateral brain stems. This is likely the result of the subcortical white matter tracts already affected by GGE traversing the brain stem, as the cortico-spinal tracts likely result in the observed changes. In contrast, changes in the brain stem are infrequently reported, which is probably a reflection of the difficulty in imaging this area of the brain or

a focus of the imaging data analyses only on specific subcortical regions [27].

The differences we observed confirm the findings from other studies and go along with the subtle deficits observed in patients with GGEs that closely resemble those present in frontal lobe epilepsies [19,20]. In fact, the presence of cognitive difficulties in patients with GGEs is nowadays well recognized. In one study, the changes in the white matter underlying the supplementary motor cortex were associated with changes in verbal fluency score and were related to seizure control [25]. In another study, the white matter structural connectivity abnormalities were associated with worse performance on frontal function tests [24]. One study took a different approach to show that increasing cognitive load in JME resulted in increased functional coupling between the motor system and cognitive networks supporting the association sometimes observed in JME between heightened cognitive effort as a precipitant of seizures in some patients [40,41]. Finally, another study of children with recent-onset JME showed that executive dysfunction was associated with smaller thalamic and frontal lobes [39]. While cognitive performance was not specifically tested in our study, the observation of the negative relationship between the age of onset and the white matter damage in our study is in agreement with at least 1 longitudinal study in absence epilepsy in which the authors identified progression of volumetric decreases or stagnation of the development of the thalamo-cortical circuitry in children when compared to healthy controls [42].

Finding the asymmetry of the white matter injury is not unexpected and it may have certain developmental implications. There are several developmental effects that need to be taken into account when analyzing data on a disease process that starts in childhood and adolescence, which is the case in most GGEs. In one study [20], the finding of differences in white matter between hemispheres was thought to be consistent with the previously observed asymmetries in structural connectivity of the language areas [43]. However, there may be other interpretations of the asymmetries, including the effects of brain development [44], age-related changes in the distribution of language functions [44–46], or existence of left hemispheric EEG asymmetries in GGEs [47], all of which may be associated with asymmetries in the underlying brain structures and structural connectivity. In fact, the mean age of our patients at the time of GGE onset was 15 years ( $SD\pm 8$ ), indicating that white matter development was still ongoing in most participants at the time their epilepsy started [48,49]. Since there are differences in the maturation of the dominant and non-dominant hemispheres in human development with, the left hemispheric maturation process being more protracted due to the development of hemispheric specialization, it is not

surprising to observe hemispheric differences in white matter injury. Future studies may need to take this factor into account when analyzing the data, as well as to collect data on patients with early- and late-onset GGEs. Finally, a longitudinal study design may allow better characterization of these changes because they include and measure between-subject and intra-subject variability.

Certain limitations of the present study need to be considered. First, this was a retrospective and cross-sectional study in patients with treatment-resistant GGEs. Prospective and longitudinal studies are needed to assess whether the structural connectivity is affected by disease progression and whether the control of GSWDs and seizures has a positive effect on white matter development [16,50]. Second, patients with new- or recent-onset GGEs need to be enrolled and evaluated with neuroimaging biomarkers to assess not only the effects of epilepsy, but also of medications, compliance, and other factors [51,52]. Another limitation of the study is the use of data collected with somewhat different imaging sequences and of subjects who were not matched perfectly for age or sex. We attempted to control for these variables in the data analyses, but it is possible that the differences in subject characteristics and the acquisition sequences could account for some of the imaging findings in our patients; as such, we cannot exclude the possibility of subtle effects that affected our results. This could be mitigated in prospective studies. In addition, newer and more sophisticated white matter imaging sequences (e.g., HARDI) have been developed and may be used in the future to improve resolution of the white matter tracts and crossing fibers [53]. Finally, cognitive and behavioral data should be acquired (e.g., formal neuropsychological testing and functional MRI) to improve the ability to determine and interpret the specific white matter injury and the cognitive deficits that are associated with it that may be present in this population. Ultimately, studies evaluating combined structural and functional connectivity may shed more light on the specific effects of GGEs on the developing and adult brain.

## Conclusions

Our study confirms the presence of widespread white matter abnormalities in patients with GGEs and provides evidence that age at GGE onset may have an important effect on white matter integrity.

## Statement

We do not have any conflicts of interest to report in conjunction with the contents of the manuscript.



## References:

- Bai X, Vestal M, Berman R et al: Dynamic time course of typical childhood absence seizures: EEG, behavior, and functional magnetic resonance imaging. *J Neurosci*, 2010; 30(17): 5884-93
- Berg AT, Berkovic SF, Brodie MJ et al: Revised terminology and concepts for organization of seizures and epilepsies: report of the ILAE Commission on Classification and Terminology, 2005-2009. *Epilepsia*, 2010; 51(4): 676-85
- Szaflarski JP, DiFrancesco M, Hirschauer T et al: Cortical and subcortical contributions to absence seizure onset examined with EEG/fMRI. *Epilepsy Behav*, 2010; 18(4): 404-13
- Dugan P, Carlson C, Bluvstein J et al: Auras in generalized epilepsy. *Neurology*, 2014; 83(16): 1444-49
- Gloor P: Generalized cortico-reticular epilepsies. Some considerations on the pathophysiology of generalized bilaterally synchronous spike and wave discharge. *Epilepsia*, 1968; 9(3): 249-63
- Leresche N, Lambert RC, Errington AC, Crunelli V: From sleep spindles of natural sleep to spike and wave discharges of typical absence seizures: Is the hypothesis still valid? *Pflugers Arch*, 2012; 463(1): 201-12
- Szaflarski JP: Can EEG predict outcomes in genetic generalized epilepsies? *Clin Neurophysiol*, 2014; 125(2): 215-16
- Engel J Jr, Thompson PM, Stern JM et al: Connectomics and epilepsy. *Curr Opin Neurol*, 2013; 26(2): 186-94
- Damoiseaux JS, Greicius MD: Greater than the sum of its parts: a review of studies combining structural connectivity and resting-state functional connectivity. *Brain Struct Funct*, 2009; 213(6): 525-33
- Moeller F, Siebner HR, Wolff S et al: Simultaneous EEG-fMRI in drug-naive children with newly diagnosed absence epilepsy. *Epilepsia*, 2008; 49(9): 1510-19
- Szaflarski JP, Kay B, Gotman J et al: The relationship between the localization of the generalized spike and wave discharge generators and the response to valproate. *Epilepsia*, 2013; 54(3): 471-80
- Karakis I, Pathmanathan JS, Chang R et al: Prognostic value of EEG asymmetries for development of drug-resistance in drug-naive patients with genetic generalized epilepsies. *Clin Neurophysiol*, 2014; 125(2): 263-69
- Szaflarski JP, Lindsell CJ, Zakaria T et al: Seizure control in patients with idiopathic generalized epilepsies: EEG determinants of medication response. *Epilepsy Behav*, 2010; 17(4): 525-30
- Bernhardt BC, Rozen DA, Worsley KJ et al: Thalamo-cortical network pathology in idiopathic generalized epilepsy: insights from MRI-based morphometric correlation analysis. *Neuroimage*, 2009; 46(2): 373-81
- Braga AM, Fujisao EK, Verdade RC et al: Investigation of the cingulate cortex in idiopathic generalized epilepsy. *Epilepsia*, 2015; 56(11): 1803-11
- Kay BP, DiFrancesco MW, Privitera MD et al: Reduced default mode network connectivity in treatment-resistant idiopathic generalized epilepsy. *Epilepsia*, 2013; 54(3): 461-70
- Lin K, Carrete H Jr, Lin J et al: Magnetic resonance spectroscopy reveals an epileptic network in juvenile myoclonic epilepsy. *Epilepsia*, 2009; 50(5): 1191-200
- Chowdhury FA, Elwes RD, Koutroumanidis M et al: Impaired cognitive function in idiopathic generalized epilepsy and unaffected family members: An epilepsy endophenotype. *Epilepsia*, 2014; 55(6): 835-40
- Devinsky O, Gershengorn J, Brown E et al: Frontal functions in juvenile myoclonic epilepsy. *Neuropsychiatry Neuropsychol Behav Neurol*, 1997; 10(4): 243-46
- Iqbal N, Caswell HL, Hare DJ et al: Neuropsychological profiles of patients with juvenile myoclonic epilepsy and their siblings: a preliminary controlled experimental video-EEG case series. *Epilepsy Behav*, 2009; 14(3): 516-21
- Deppe M, Kellinghaus C, Duning T et al: Nerve fiber impairment of anterior thalamocortical circuitry in juvenile myoclonic epilepsy. *Neurology*, 2008; 71(24): 1981-85
- Vulliemoz S, Vollmar C, Koepp MJ et al: Connectivity of the supplementary motor area in juvenile myoclonic epilepsy and frontal lobe epilepsy. *Epilepsia*, 2011; 52(3): 507-14
- Du H, Zhang Y, Xie B et al: Regional atrophy of the basal ganglia and thalamus in idiopathic generalized epilepsy. *J Magn Reson Imaging*, 2011; 33(4): 817-21
- Kim JH, Suh SI, Park SY et al: Microstructural white matter abnormality and frontal cognitive dysfunctions in juvenile myoclonic epilepsy. *Epilepsia*, 2012; 53(8): 1371-78
- O'Muircheartaigh J, Vollmar C, Barker GJ et al: Abnormal thalamocortical structural and functional connectivity in juvenile myoclonic epilepsy. *Brain*, 2012; 135(Pt 12): 3635-44
- Vollmar C, O'Muircheartaigh J, Symms MR et al: Altered microstructural connectivity in juvenile myoclonic epilepsy: the missing link. *Neurology*, 2012; 78(20): 1555-59
- O'Muircheartaigh J, Vollmar C, Barker GJ et al: Focal structural changes and cognitive dysfunction in juvenile myoclonic epilepsy. *Neurology*, 2011; 76(1): 34-40
- Cox RW: AFNI: software for analysis and visualization of functional magnetic resonance neuroimages. *Comput Biomed Res*, 1996; 29(3): 162-73
- Allendorfer JB, Storrs JM, Szaflarski JP: Changes in white matter integrity follow excitatory rTMS treatment of post-stroke aphasia. *Restor Neurol Neurosci*, 2012; 30(2): 103-13
- Lee S, Allendorfer JB, Gaston TE et al: White matter diffusion abnormalities in patients with psychogenic non-epileptic seizures. *Brain Res*, 2015; 1620: 169-76
- Smith SM, Jenkinson M, Johansen-Berg H et al: Tract-based spatial statistics: voxelwise analysis of multi-subject diffusion data. *Neuroimage*, 2006; 31(4): 1487-505
- Winkler AM, Ridgway GR, Webster MA et al: Permutation inference for the general linear model. *Neuroimage*, 2014; 92: 381-97
- Smith SM, Nichols TE: Threshold-free cluster enhancement: addressing problems of smoothing, threshold dependence and localisation in cluster inference. *Neuroimage*, 2009; 44(1): 83-98
- Ingallhalikar M, Smith A, Parker D et al: Sex differences in the structural connectome of the human brain. *Proc Natl Acad Sci USA*, 2014; 111(2): 823-28
- Andermann F, Berkovic SF: Idiopathic generalized epilepsy with generalized and other seizures in adolescence. *Epilepsia*, 2001; 42(3): 317-20
- Proposal for revised classification of epilepsies and epileptic syndromes. Commission on Classification and Terminology of the International League Against Epilepsy. *Epilepsia*, 1989; 30(4): 389-99
- Betting LE, Mory SB, Li LM et al: Voxel-based morphometry in patients with idiopathic generalized epilepsies. *Neuroimage*, 2006; 32(2): 498-502
- Woermann FG, Sisodiya SM, Free SL, Duncan JS: Quantitative MRI in patients with idiopathic generalized epilepsy. Evidence of widespread cerebral structural changes. *Brain*, 1998; 121(Pt 9): 1661-67
- Pulsipher DT, Seidenberg M, Guidotti L et al: Thalamofrontal circuitry and executive dysfunction in recent-onset juvenile myoclonic epilepsy. *Epilepsia*, 2009; 50(5): 1210-19
- da Silva Sousa P, Lin K, Garzon E et al: Self-perception of factors that precipitate or inhibit seizures in juvenile myoclonic epilepsy. *Seizure*, 2005; 14(5): 340-46
- Vollmar C, O'Muircheartaigh J, Barker GJ et al: Motor system hyperconnectivity in juvenile myoclonic epilepsy: A cognitive functional magnetic resonance imaging study. *Brain*, 2011; 134(Pt 6): 1710-19
- Pulsipher DT, Dabbs K, Tuchsherer V et al: Thalamofrontal neurodevelopment in new-onset pediatric idiopathic generalized epilepsy. *Neurology*, 2011; 76(1): 28-33
- Powell HW, Parker GJ, Alexander DC et al: Hemispheric asymmetries in language-related pathways: A combined functional MRI and tractography study. *Neuroimage*, 2006; 32(1): 388-99
- Geschwind N, Galaburda AM: Cerebral lateralization. Biological mechanisms, associations, and pathology: I. A hypothesis and a program for research. *Arch Neurol*, 1985; 42(5): 428-59
- Szaflarski JP, Holland SK, Schmithorst VJ, Byars AW: fMRI study of language lateralization in children and adults. *Hum Brain Mapp*, 2006; 27(3): 202-12
- Szaflarski JP, Rajagopal A, Altaye M et al: Left-handedness and language lateralization in children. *Brain Res*, 2012; 1433: 85-97
- Dean AC, Solomon G, Harden C et al: Left hemispheric dominance of epileptiform discharges. *Epilepsia*, 1997; 38(4): 503-5
- Foundas AL, Leonard CM, Gilmore R et al: Planum temporale asymmetry and language dominance. *Neuropsychologia*, 1994; 32(10): 1225-31

49. Levitsky W, Geschwind N: Asymmetries of the right and left hemisphere in man. *Trans Am Neurol Assoc*, 1968; 93: 232-33
50. Kay BP, Holland SK, Privitera MD, Szaflarski JP: Differences in paracingulate connectivity associated with epileptiform discharges and uncontrolled seizures in genetic generalized epilepsy. *Epilepsia*, 2014; 55(2): 256-63
51. Szaflarski JP, Allendorfer JB: Topiramate and its effect on fMRI of language in patients with right or left temporal lobe epilepsy. *Epilepsy Behav*, 2012; 24(1): 74-80
52. Wandschneider B, Stretton J, Sidhu M et al: Levetiracetam reduces abnormal network activations in temporal lobe epilepsy. *Neurology*, 2014; 83(17): 1508-12
53. Kuhnt D, Bauer MH, Egger J et al: Fiber tractography based on diffusion tensor imaging compared with high-angular-resolution diffusion imaging with compressed sensing: initial experience. *Neurosurgery*, 2013; 72(Suppl.1): 165-75