



Posterior spine fusion in a Jehovah's Witness patient with severe rigid idiopathic scoliosis – A case report



Michele Da Broi^b, Andrea Amarossi^{b,*}, Mauro Spina^a, Torstein R. Meling^{c,d}, Massimo Balsano^a

^a Regional Spinal Department, University and Hospital Trust of Verona, Verona, Italy

^b Orthopedics and Traumatology Department, University and Hospital Trust of Verona, Verona, Italy

^c Department of Clinical Neurosciences, Division of Neurosurgery, Geneva University Hospitals, Geneva, Switzerland

^d Faculty of Medicine, University of Geneva, Geneva, Switzerland

ARTICLE INFO

Keywords:

Idiopathic scoliosis
Spine surgery
Jehovah's Witness
Posterior spine fusion
Case report

ABSTRACT

Introduction: Early onset scoliosis (EOS) represent a challenge for spine surgeons. The selection of the best treatment is complex. Some patients, such as Jehovah's Witnesses who refuse blood transfusions, are at high risk of complication when surgical treatment is required because blood loss is a major cause of morbidity and post-operative transfusion rates.

Research question: Describe blood-saving techniques that allowed an extensive and invasive surgical procedure in a Jehovah's Witness patient.

Material and method: 17-year-old Jehovah's Witness girl with severe 120° Cobb Lenke 1A idiopathic scoliosis started as EOS was prepared with 4 cycles of recombinant human erythropoietin, iron and folic acid supplementation that brought her hemoglobin level from 13.6 g/dl to 16.2 g/dl. In the first surgical time, a temporary rod was implanted. Spine dissection using bipolar sealer and a special electrocautery that operates at lower temperatures than traditional ones was performed. Facetectomies and multilevel Ponte osteotomies was performed using an ultrasonic bone scalpel. The second surgical time, the definitive rods were placed, and the correction of the deformity was achieved using the rod link reducer technique.

Results: A good correction of the main curve in the coronal plane is achieved. The Hb nadir was 7.2 g/dl four days after the second operation. The postoperative course was uneventful.

Discussion and conclusion: The integration of modern and traditional preoperative, intraoperative, and post-operative blood sparing techniques allowed us to perform an extensive and invasive surgical procedure in a Jehovah's Witness girl with a severe idiopathic scoliosis.

1. Introduction

Early-onset scoliosis (EOS) is defined as a spinal deformity in patients under 10 years of age (Hardesty et al., 2018). Over the last two decades, there has been a significant evolution in the knowledge and treatment of this pathology. Better understanding of relationship between the chest wall, the lungs, the heart, and the spine has allowed extraordinary advancements in the treatment of this challenging clinical entity. Non-surgical treatment of EOS includes derotational casting, which entails the advantage of preserving chest and delaying spine growth (Sanders et al., 2009). Otherwise, if the deformity is no longer controlled by conservative procedures, the treatment is converted to surgery (Yang et al., 2016).

The surgical options include growth-friendly techniques, such as traditional dual growing rods, vertical expandable prosthetic titanium rib, and magnetic expansion control systems. There are also growth modulation techniques, such as Shilla growth guidance system, and more modern techniques, such as vertebral body tethering (Baroncini et al., 2021). Unfortunately, most of these systems eventually result in a definitive spine fusion (Skaggs et al., 2014).

In pediatric scoliosis fusion surgery, blood loss is a major cause of morbidity, and postoperative transfusion rates reported in the literature range from 37 to 85% (Joseph et al., 2008). However, certain patients (or parents) refuse blood transfusions and acceptance of blood by a Jehovah Witness (JW), for example, would entail exclusion and excommunication from the church, resulting in social isolation by their own relatives and

* Corresponding author. Orthopedics and Traumatology Department, University and Hospital Trust of Verona, Piazzale Aristide Stefani 1, 37126, Verona, Italy.
E-mail address: andrea.amarossi@gmail.com (A. Amarossi).

friends (Lawson and Ralph, 2015). Important spine deformities in JW patients therefore represent unique challenges for spine surgeons and surgery is in many cases declined.

In this article, we present a 17-year-old JW girl with idiopathic scoliosis that started as EOS when she was 8 years old and came to our attention when she had developed a severe and rigid curve that required correction and fusion. Here we discuss the feasibility of complex scoliosis surgery in JW patients.

2. Case report

A 17-year-old female JW patient presented to our clinic with a 120° Cobb right thoracic curve from T5 to L1, with the apex at T9. Her menarche was at 12 years and 5 months of age, she was 154 cm tall and weighed 44 kg (BMI 18.6). The main curve was extremely rigid and corrected only 15% on lateral bending. The fulcrum bending radiograph showed no further correction of the deformity. Preoperative radiographs showed a right trunk shift of 54 mm and right shoulder elevation of 6°, the T1-S1 height was 35.3 cm and the Risser sign indicated complete skeletal maturity. Thoracic kyphosis was moderately augmented (61°). The curve was classified as Lenke type 1A+ (Rose and Lenke, 2007) (Fig. 1A–C). Clinically, her lower extremities were equal in length, with level iliac crests. The neurologic examination was normal. On forward-bend testing, the right rib hump was 75 mm high (Fig. 2A–C). Her medical history included an endocarditis treated with hospitalization and IV antibiotics in 2011, but she was otherwise fit and well. In her family, there was no history of scoliosis. The neuraxis was studied with a total spine MRI to rule out the presence of syrinx, tethered cord, or Chiari malformation. The patient had been diagnosed with juvenile idiopathic scoliosis when she was 7 years old and a Lyon brace treatment was initiated, with instructions to wear the brace for 18 h daily. However, due to poor patient compliance, it was suspended after only 3 months and physical therapy alone was undertaken thereafter. The patient was followed at regular intervals with serial radiographs at other orthopedics departments. The deformity gradually progressed from 28° to 56° over 3 years and after the menarche, it increased rapidly to 110° over 13 months (Fig. 3A–E). When the patient finally came to our attention, the magnitude of the curve mandated a complex corrective surgery. A surgical intervention consisting of posterior instrumented arthrodesis from T3 to L2 and multilevel Ponte osteotomies (MPO) was proposed. The risks, benefits, and alternative treatments, particularly three-column osteotomies and vertebral column resection were discussed with the family, who

consented to surgery on the condition that no blood transfusion was employed. Her parents accepted to resort to intraoperative cell-saving techniques.

The patient underwent preoperative preparation with recombinant human erythropoietin (rEPO). Preoperatively, her hemoglobin (Hgb) level was 13.6 g/dl. She was administered iron and folic acid supplementation together with rEPO 10 000 units subcutaneously weekly for a total of 4 weeks. Three days before surgery, her Hgb level was 16.2 g/dl.

The day of the operation, the patient was placed in a prone position on a Jackson table allowing the abdomen to hang free, thereby reducing the pressure on the abdomen. During surgery, 1g of tranexamic acid was administered IV and 2 mg/kg/hour was maintained; the mean arterial pressure (MAP) was lowered to 70 mmHg during the dissection to reduce intraoperative bleeding. The operation was performed through a posterior only approach. Muscles were dissected subperiosteally up to the tips of transverse vertebral processes from T3 to L2. Soft tissue dissector (PlasmaBlade®), bipolar sealer device (Aquamantys®), and warm saline-soaked gauzes were employed, thereby promoting the coagulation process and minimizing blood loss. Spinal cord monitoring was employed to record motor evoked (MEP) and somatosensory evoked potentials (SSEP) during the entire procedure. Under fluoroscopic guidance, pedicle screws were inserted unilaterally at T3, T4, L1, and L2 levels on the concave side of the curve, according to the surgical planning. Subsequently, a temporary rod was applied, and a first moderate distraction of the curve was undertaken. Posterior musculoskeletal release and facetectomies were done bilaterally within the instrumented segment. MPOs were then performed from T6 to L1 with an ultrasonic bone scalpel (Misonix®) to maximize the flexibility of the spine. The remaining pedicle screws were inserted bilaterally from T3 to L2. Finally, a second wider distraction maneuver was done to obtain a partial correction of the deformity and successively place the definitive rods. However, some minutes after the distraction, a sharp bilateral decrease of SSEPs and MEPs of inferior extremities was recorded. The temporary rod was therefore removed, the patient was heated up, and her MAP was increased. After some minutes, MEPs and SSEPs regained baseline values on the right, while a reduction of 60% persisted on the left. Due to the instability of the evoked potentials, surgery was suspended, and the patient was transferred to the intensive care unit (ICU) for strict monitoring. After extubation, she presented a mild paresis of her left inferior extremity which recovered completely 2 days later. Otherwise the postoperative course was uneventful.

The patient underwent the second surgery 15 days later. The rEPO

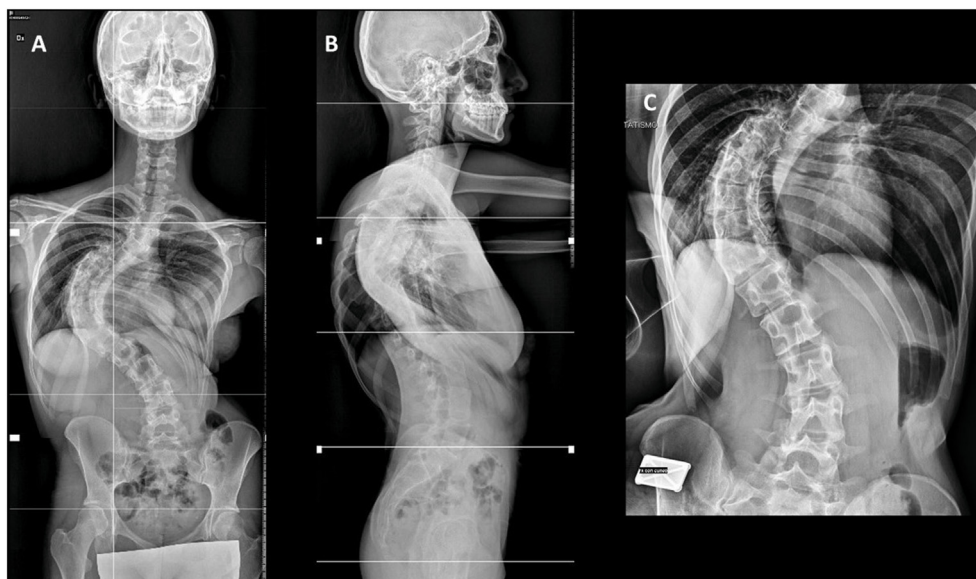


Fig. 1. Preoperative radiographs: A) AP view, B) lateral view, C) fulcrum bending test view.

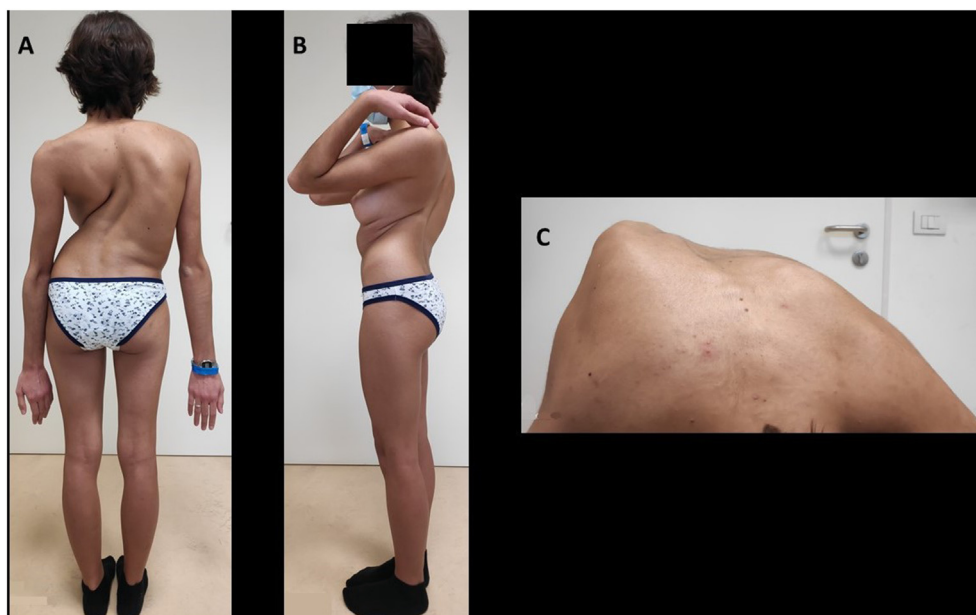


Fig. 2. Clinical examination: A) back view, B) sagittal view, C) frontal bending test view.

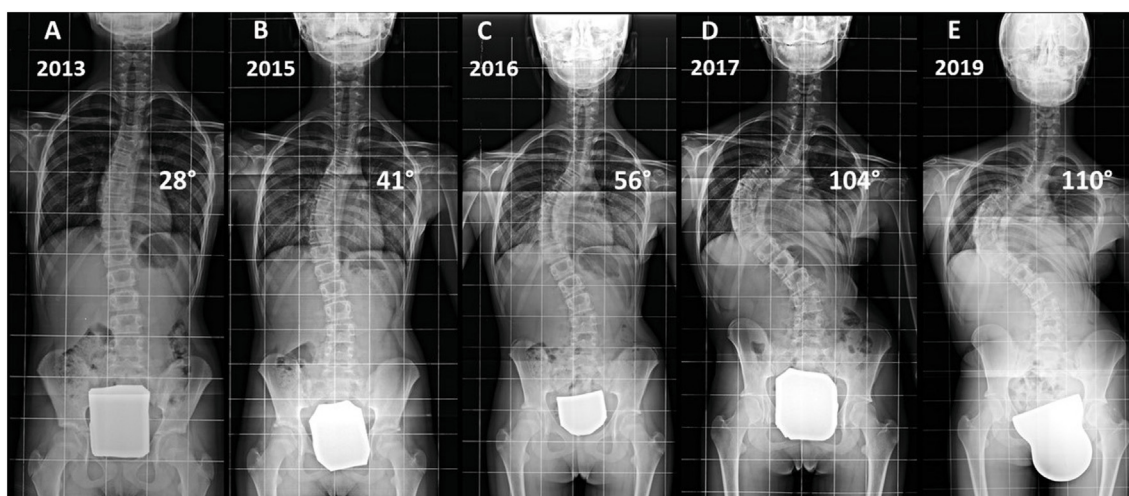


Fig. 3. Evolution of the main curves over the years.

treatment was repeated, and 2 cycles were administered, bringing Hgb level from 9.7 g/dl to 11.2 g/dl. The subperiosteal dissection was extended to L3 and two additional pedicle screws were inserted. The correction of the main curve was carried out according to the Rod-Link-Reducer (RLR), GlobusMedical® system technique. The first maneuver addressed the axial plane deformity with derotation of the spine and the rib cage. The second maneuver compressed the spine on the convexity to obtain a correction on the coronal plane. The last manipulation was done to normalize the thoracic kyphosis. A contoured cobalt chromium (CoCr) rod was implanted at the apex on the concave side of the curve and the stabilization of the concavity was completed adding laterally a titanium rod. During the whole procedure, the electrophysiologic neuro-monitoring signals were unchanged and a wake-up test confirmed intact lower extremities motor function.

On the first postoperative day, her Hgb was 8.9 g/dl and reached a nadir of 7.2 g/dl on the fourth postoperative day. She was discharged 4 days later with a Hgb of 8.6 g/dl. During the entire hospital stay, no blood transfusion was necessary and also the second postoperative course was uneventful.

Postoperative standing full-length radiographs showed a 57% correction of the main curve in the coronal plane (52°) (Fig. 4A–C). At her last follow-up at 8 months, the imaging and physical examination demonstrated an excellent correction of the deformity (Fig. 5A–D). The main curve maintained the correction, the shoulders were well balanced, the right trunk shift was reduced to 13 mm, and the T1-S1 height reached 45.1 cm.

3. Discussion

Patients with EOS always represent a great challenge for spine surgeons and the selection of the best treatment is often complex. Despite numerous advancements in this field, with less invasive approaches that have been proposed over the years, these patients eventually require definitive fusion surgery which frequently comes with a demanding cost in terms of spine mobility and perioperative blood loss.

JW patients constitute a peculiar subgroup that poses additional issues to the surgeons. JW patients' objection to receiving blood products derives from biblical passages which imply that transfusing blood is

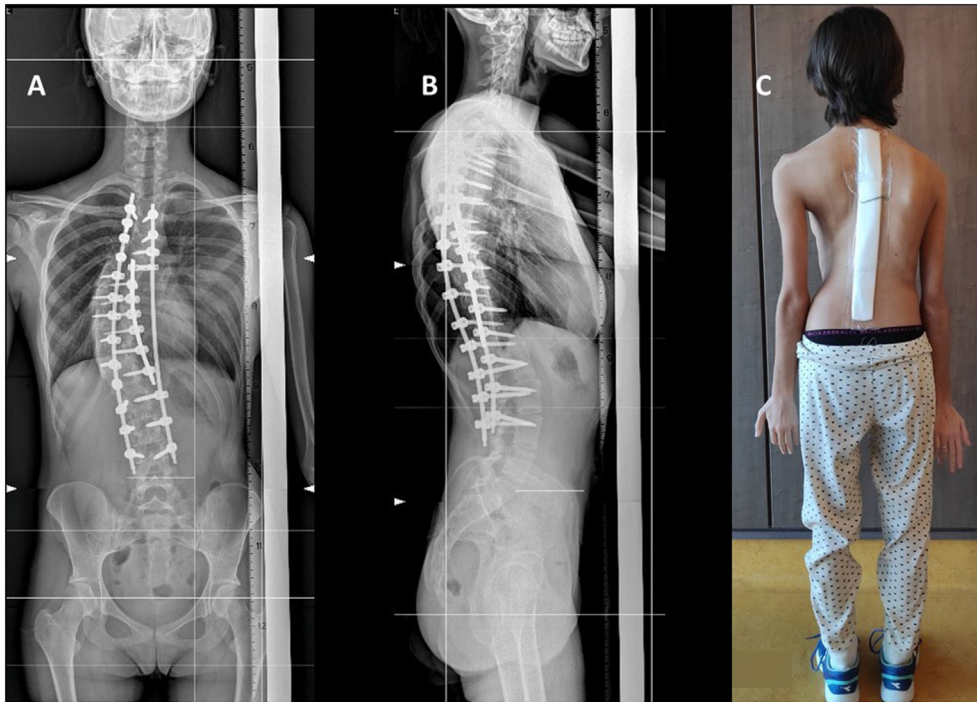


Fig. 4. One-month follow-up: A) Radiograph AP view, B) radiograph lateral view, C) clinical examination back view.

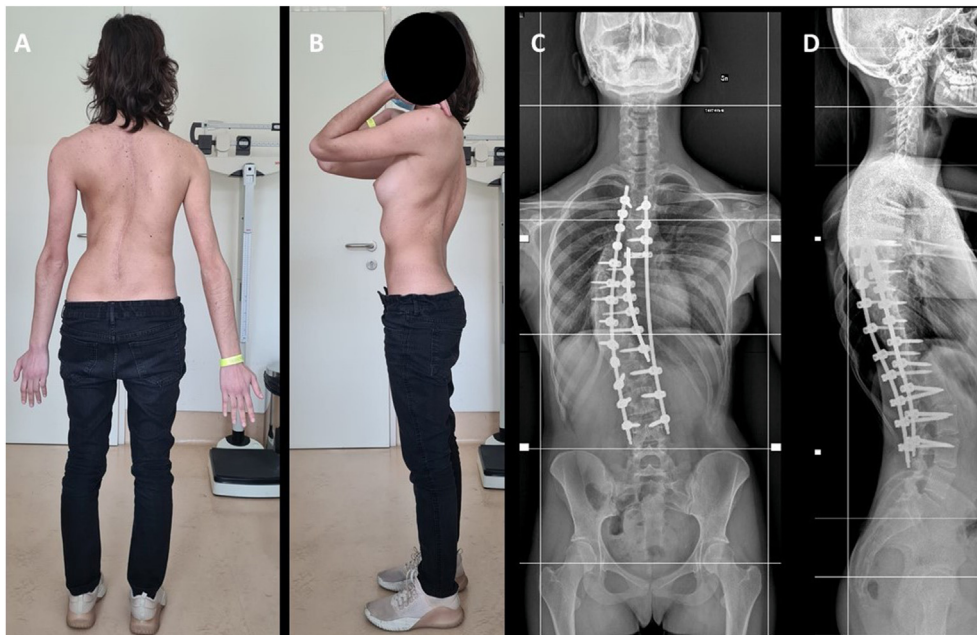


Fig. 5. Last follow-up: A) Radiograph AP view, B) radiograph lateral view, C) clinical examination back view, D) clinical examination sagittal view.

equivalent to eating it and this deed will lead to eternal damnation (Doyle, 2002). Hence, they do not accept transfusion of whole or fractions of blood. Furthermore, they do not even accept their own pre-donated blood, since this involves a temporary discontinuation from their circulation. However, there has been a constant evolution in the variety of blood conservation techniques employed for JW patients undergoing spine surgery during the past decades. A thorough description of these techniques were made by Hoashi et al. (2015) who presented a case series of 10 JW patients operated on for scoliosis. According to them, the most modern strategies include the use of anti-fibrinolytics, such as tranexamic acid, and the bipolar sealer (Aquamantis®) for intraoperative

hemostasis which has demonstrated to be effective in reducing total perioperative blood loss (Gordon et al., 2013). Cell-saver techniques were employed in 7 out of 10 patients in their cohort (Hoashi et al., 2015). Indeed, autotransfusions are accepted by some JWs since there is no discontinuation of blood from circulation. In our case, 380 ml and 270 ml were autotransfused during the first and second surgical time, respectively. Other blood saving techniques utilized by Hoashi and colleagues included electrocautery, hypotensive anesthesia, iron supplementation, erythropoietin, hemodilution, and epinephrine-soaked gauzes (Hoashi et al., 2015). Furthermore, all their patients were operated on a Jackson table to reduce the abdominal pressure.

Literature detailing the use and efficacy of rEPO with respect to reduction of blood transfusions is rather sparse. In the case series presented by Hoashi et al. (2015) rEPO was used in 2 cases operated in 2007 and in 2011, respectively. Epoetin alfa and iron supplementation were also successfully utilized by Chau et al. (2008) in a JW child with hemophilia B and anaphylactic inhibitors to factor XI who underwent scoliosis surgery. The authors reported no use of blood transfusion and no adverse event during the hospitalization. Vitale et al. (1998) recorded significantly lower rates of transfusion in the idiopathic scoliosis group. They postulated some sort of EPO-resistance in the congenital and neuromuscular groups, even though biases associated with the non-randomized design of their study cannot be ruled out. In our case, we decided to use rEPO together with iron and folic acid supplementation as we expected a significant blood loss during and after the procedure and due to the patient's religious belief, we could not resort to blood transfusion.

With respect to intraoperative techniques, we used tranexamic acid and bipolar sealer (Aquamantis®) as described by Hoashi et al. (2015) For muscles dissection, the Pulsed-Electron Avalanche Knife (PEAK) PlasmaBlade® was used. This relatively new electrosurgical device produces pulsed plasma-mediated discharges, at the edge of an insulated electrode. Due to the thermal protection shield technology, it operates at significantly lower temperatures than traditional electrocautery, thereby allowing a precise dissection and an accurate hemostasis (Piazzolla and Bizzoca, 2020).

Another problem we had to deal with was performing numerous osteotomies. Indeed, as demonstrated by Samdani et al. (2015) advanced scoliosis Lenke 1A-B require MPOs to make the spine more flexible and get a better correction of the deformity. However, osteotomies cause conspicuous bleeding and is one of the major causes of anemia in deformity surgery (Kose et al., 2017). We performed MPOs using an ultrasonic bone scalpel (Misonix®) which allows the surgeon to cut the cortical bone, cauterize the cancellous bone, that is responsible for most of bleeding, and preserve the soft tissue. According to Bartley et al. (2014), patients undergoing facetectomies and Ponte osteotomies by means of an ultrasonic bone scalpel had a blood loss reduction of 40% compared to the control group.

The use of drains in orthopedic surgery is still a matter of debate. On the one hand, they are useful to lower the risk of wound complication and hematomas, which range from 0.1 to 3.0% in spine surgery (Aono et al., 2011). On the other hand, drains are associated with prolonged hospitalization and increased resort to blood transfusions (Kochai and Erkorkmaz, 2019; Parker et al., 2007). In our department, we usually employ drains in major operations, but in this case, we preferred to avoid further potential blood loss. Neither infections nor wound complications were observed during hospital stay.

Lastly, this clinical case gives us the opportunity to discuss also the ethical aspect of performing high risk surgery on underage patients for whom his/her parents have refused blood transfusions. In this case, we were dealing with a patient whose deformity was function- and life-threatening and to whom surgery was denied several times because of religious beliefs of her family. In face of this situation, offering a surgical solution was mandatory. From a legal point of view, in case the parents or the patient's legal guardian refuses the administration of blood transfusions, the healthcare personnel face the challenge of fulfilling their duties by taking care of the health of the patient without jeopardizing patient's life for no reason while respecting the will of the patient. Since the patient's parents refused blood transfusions, the surgeon cannot resort to this therapy and if not, he or she may have to respond of this in a court of law. We believe that in such cases, it is fundamental to establish a doctor-patient relationship of trust and detailing all possible consequences of avoiding blood transfusions in such complex spine cases. Moreover, in case of emergency, if the physician is convinced that it is necessary to perform blood transfusions to save patient's life, it is always possible to refer the decision to the tutelary judge, in order to safeguard the health of the underage patient.

However, it is advisable to obtain a written legal opinion prior to execute the surgery, considering that national laws differ from one country to another.

4. Conclusions

The integration of modern and more traditional preoperative, intraoperative, and postoperative blood sparing techniques allowed us to perform an extensive and highly invasive surgical procedure in a Jehovah's Witness girl with an extremely severe idiopathic scoliosis. The postoperative course was uneventful without need of blood transfusion.

Compliance with ethical standards

Ethical approval: "All procedures performed in studies involving human participants were in accordance with the ethical standards of the institutional and/or national research committee and with the 1964 Helsinki declaration and its later amendments or comparable ethical standards."

Since the patient was underage, informed consent was acquired from the patient's parents.

The authors declare that they have no conflict of interest.

References

- Aono, H., Ohwada, T., Hosono, N., Tobimatsu, H., Ariga, K., Fuji, T., Iwasaki, M., 2011. Incidence of postoperative symptomatic epidural hematoma in spinal decompression surgery. *J. Neurosurg. Spine* 15, 202–205. <https://doi.org/10.3171/2011.3.spine10716>.
- Baroncini, A., Trobisch, P.D., Migliorini, F., 2021. Learning curve for vertebral body tethering: analysis on 90 consecutive patients. *Spine Deform.* 9, 141–147. <https://doi.org/10.1007/s43390-020-00191-5>.
- Bartley, C.E., Bastrom, T.P., Newton, P.O., 2014. Blood loss reduction during surgical correction of adolescent idiopathic scoliosis utilizing an ultrasonic bone scalpel. *Spine Deform.* 2, 285–290. <https://doi.org/10.1016/j.jspsd.2014.03.008>.
- Chau, A., Wu, J., Ansermino, M., Tredwell, S., Purdy, R., 2008. A Jehovah's Witness child with hemophilia B and factor IX inhibitors undergoing scoliosis surgery. *Can. J. Anaesthesia = J. Can. Anesthésie* 55, 47–51. <https://doi.org/10.1007/bf03017597>.
- Doyle, D.J., 2002. Blood transfusions and the Jehovah's Witness patient. *Am. J. Therapeut.* 9, 417–424. <https://doi.org/10.1097/00045391-200209000-00009>.
- Gordon, Z.L., Son-Hing, J.P., Poe-Kochert, C., Thompson, G.H., 2013. Bipolar sealer device reduces blood loss and transfusion requirements in posterior spinal fusion for adolescent idiopathic scoliosis. *J. Pediatr. Orthop.* 33, 700–706. <https://doi.org/10.1097/BPO.0b013e31829d5721>.
- Hardesty, C.K., Huang, R.P., El-Hawary, R., Samdani, A., Hermida, P.B., Bas, T., Balioglu, M.B., Gurd, D., Pawelek, J., McCarthy, R., Zhu, F., Luhmann, S., 2018. Early-onset scoliosis: updated treatment techniques and results. *Spine Deform.* 6, 467–472. <https://doi.org/10.1016/j.jspsd.2017.12.012>.
- Hoashi, J.S.B.O., Kolmodin, J., Gurd, D.P., Kuivila, T.E., et al., 2015. Surgical management of scoliosis in Jehovah's Witness patients: one institution's experience. *J. Spine* 223. <https://doi.org/10.4172/21657939.1000223>.
- Joseph Jr., S.A., Berekashvili, K., Mariller, M.M., Rivlin, M., Sharma, K., Casden, A., Bitan, F., Kuflik, P., Neuwirth, M., 2008. Blood conservation techniques in spinal deformity surgery: a retrospective review of patients refusing blood transfusion. *Spine* 33, 2310–2315. <https://doi.org/10.1097/BRS.0b013e31818047f2>.
- Kochai, A., Erkorkmaz, Ü., 2019. The role of drains in adolescent idiopathic scoliosis surgery: is it necessary? *Medicine* 98, e18061. <https://doi.org/10.1097/md.00000000000018061>.
- Kose, K.C., Bozduman, O., Yenigul, A.E., Iğrek, S., 2017. Spinal osteotomies: indications, limits and pitfalls. *EFORT Open Rev.* 2, 73–82. <https://doi.org/10.1302/2058-5241.2.160069>.
- Lawson, T., Ralph, C., 2015. Perioperative Jehovah's Witnesses: a review. *Br. J. Anaesth.* 115, 676–687. <https://doi.org/10.1093/bja/aev161>.
- Parker, M.J., Livingstone, V., Clifton, R., McKee, A., 2007. Closed suction surgical wound drainage after orthopaedic surgery. *Cochrane Database Syst. Rev.*, Cd001825 <https://doi.org/10.1002/14651858.CD001825.pub2>.
- Piazzolla, A., Bizzoca, D., 2020. Plasma Technology Reduces Blood Loss in Adolescent Idiopathic Scoliosis Surgery: A Prospective Randomized Clinical Trial. <https://doi.org/10.1177/2192568220928344>, 2192568220928344.
- Rose, P.S., Lenke, L.G., 2007. Classification of operative adolescent idiopathic scoliosis: treatment guidelines. *Orthop. Clin. N. Am.* 38, 521–529. <https://doi.org/10.1016/j.jocl.2007.06.001> vi.
- Samdani, A.F., Bennett, J.T., Singla, A.R., Marks, M.C., Pahys, J.M., Lonner, B.S., Miyajiri, F., Shah, S.A., Shufflebarger, H.L., Newton, P.O., Asghar, J., Betz, R.R., Cahill, P.J., 2015. Do Ponte osteotomies enhance correction in adolescent idiopathic scoliosis? An analysis of 191 Lenke 1A and 1B curves. *Spine Deform.* 3, 483–488. <https://doi.org/10.1016/j.jspsd.2015.03.002>.

- Sanders, J.O., D'Astous, J., Fitzgerald, M., Khoury, J.G., Kishan, S., Sturm, P.F., 2009. Derotational casting for progressive infantile scoliosis. *J. Pediatr. Orthoped.* 29, 581–587. <https://doi.org/10.1097/BPO.0b013e3181b2f8df>.
- Skaggs, D.L., Akbarnia, B.A., Flynn, J.M., Myung, K.S., Sponseller, P.D., Vitale, M.G., 2014. A classification of growth friendly spine implants. *J. Pediatr. Orthoped.* 34, 260–274. <https://doi.org/10.1097/bpo.000000000000073>.
- Vitale, M.G., Stazzone, E.J., Gelijns, A.C., Moskowitz, A.J., Roye Jr., D.P., 1998. The effectiveness of preoperative erythropoietin in averting allogenic blood transfusion among children undergoing scoliosis surgery. *J. Pediatr. Orthoped. B* 7, 203–209. <https://doi.org/10.1097/01202412-199807000-00005>.
- Yang, S., Andras, L.M., Redding, G.J., Skaggs, D.L., 2016. Early-onset scoliosis: a review of history, current treatment, and future directions. *Pediatrics* 137. <https://doi.org/10.1542/peds.2015-0709>.