

# Efficacy of Minimally Invasive Surgery on Giant Cell Tumour of the Bone: A Systematic Review

Maria Florencia Deslivia<sup>\*</sup>, Sherly Desnita Savio, Made Wahyu Dharmapradita, I Gede Eka Wiratnaya

*Orthopaedics and Traumatology Department, Faculty of Medicine Udayana University, Sanglah General Hospital, Denpasar, Indonesia*

## Abstract

**Citation:** Deslivia MF, Savio SD, Dharmapradita MW, Wiratnaya IGE. Efficacy of Minimally Invasive Surgery on Giant Cell Tumour of the Bone: A Systematic Review. Open Access Maced J Med Sci. 2019 Nov 15; 7(21):3721-3725.  
<https://doi.org/10.3889/oamjms.2019.731>

**Keywords:** Endoscopy; Osteoscopy; Giant cell tumour; benign tumour; Minimally invasive surgery

**\*Correspondence:** Maria Florencia Deslivia. Orthopaedics and Traumatology Department, Faculty of Medicine Udayana University, Sanglah General Hospital, Denpasar, Indonesia. E-mail: [mfdeslivia@gmail.com](mailto:mfdeslivia@gmail.com)

**Received:** 02-Jun-2019; **Revised:** 23-Sep-2019; **Accepted:** 24-Sep-2019; **Online first:** 12-Oct-2019

**Copyright:** © 2019 Maria Florencia Deslivia, Sherly Desnita Savio, Made Wahyu Dharmapradita, I Gede Eka Wiratnaya. This is an open-access article distributed under the terms of the Creative Commons Attribution-NonCommercial 4.0 International License (CC BY-NC 4.0)

**Funding:** This research did not receive any financial support

**Competing Interests:** The authors have declared that no competing interests exist

**Abbreviations:** GCT: Giant Cell Tumor; MIS: Minimally Invasive Surgery; CT: Computed Tomography; MRI: Magnetic Resonance Imaging

**BACKGROUND:** Although major reconstructive surgeries in the form of excision and reconstruction have been the mainstay treatment for Giant Cell Tumour (GCT) of the bone, its recurrence rate remains high and poses various morbidities such as implant failure or skin breakdown. Minimal invasive surgery (MIS) techniques, which has gained popularity mostly in other fields in orthopaedic surgery, are being introduced as an alternative to limit the surgical complications while achieving the best possible outcome. Until now, there has been no literature summarising the evidence of MIS outcome in treating GCT of the bone.

**AIM:** The purpose of this systematic review was to investigate the efficacy of this relatively new treatment.

**METHODS:** We comprehensively searched PubMed, EMBASE, and Cochrane Library to search for studies about MIS for GCT of the bone treatment up to March 1, 2019. The selection of appropriate studies was performed by two independent investigators based on PRISMA guideline. Given the limited number of studies, there was no restriction in terms of patient's demographics, the specific minimally invasive surgical method, and publication status.

**RESULTS:** We found 120 articles from the database. After evaluating full text, 5 articles (16 patients) were found to be eligible. The minimally invasive methods were curettage, cryosurgery, and argon beam coagulator. The visualisation methods include a computer-assisted navigation system, endoscope, otoscope, CT, and MRI. Location of tumours includes axial and long bones. The follow-up period ranges from 7 to 126 months. The functional and oncological outcome was found to be satisfying with no recurrence or complications.

**CONCLUSION:** In conclusion, MIS is a familiar method in orthopaedic surgery with potential expansion in tumour field. The current evidence shows that this approach for GCT results in good functional outcome, with low risk of recurrence.

## Introduction

Giant cell tumour (GCT) is a primary bone tumour with low metastatic potential, yet locally aggressive. Despite that surgery is the mainstay treatment for this entity; its recurrence rate remains high with < 20% for en block excision and 40%-50% for intralesional curettage [1]. Furthermore, radical resection of GCT has been known to result in poor functional outcome, especially in areas such as pelvis [2], [3]. Recently, minimally invasive techniques for treating GCT are being introduced to reduce the morbidity of GCT treatment while achieving treatment goals effectively. This study aims to review recent evidence concerning such treatment options systematically.

The surgical approach towards localised GCT highly relates to significant damage to the surrounding tissue, hence the poor functional outcome. Adjunctive therapies were proposed as an alternative to manage GCT while minimising side effect. The therapies include pharmacologic therapies with RANKL inhibitors or bisphosphonates for patients with bad prognostic factors and radiotherapy (RT) for non-resectable cases that are unresponsive to systemic drugs [4]. However, none of the adjunctive therapies was proven to be highly effective.

Recently, minimally invasive techniques were offered as definitive therapy, which attempts to reduce morbidity to patients, resulting in faster recovery and less hospitalisation period. Minimally invasive surgery is defined as a surgical procedure that is done using

state-of-the-art technology to reduce the damage to human tissue when performing surgery. Minimally invasive surgery uses a small incision to create small "ports" from which the surgeon inserts small instruments. A miniature camera can be placed inside to view the procedure as a magnified image on video monitors in the operating room. Other specialised small surgical instruments can then insert through the trocars based on the type of surgery. Cryoablation method, for example, utilised 4 probes and the patient underwent minimum pain relieved by basic analgesic [5]. It is usually combined with the computer navigation system to navigate the limited visual field [6]. These methods have gained popularity mostly in other fields in orthopaedic surgery, with the possibility of expanding its use in the orthopaedic oncology field.

Despite the potential of MIS, there has never been any literature summarising this latest trend of minimally invasive techniques for treating GCT. To advance it even further, a thorough analysis of previously treated cases, the specific indication, the methods used along with its advantages and disadvantages, and other lessons learned should be performed. This systematic review aims at presenting current evidence about the efficacy of this relatively new treatment for GCT.

## Materials and Methods

### Search strategy

This systematic review was conducted based on PRISMA guideline. Literature research was primarily performed using the Pubmed, EMBASE, and Cochrane Library to search for studies about MIS for GCT of the bone treatment up to March 1, 2019, with the keywords: 1. "giant cell tumour" AND "minimally invasive"; and 2. "giant cell tumour" AND "endoscopic".

We filtered the search to include only studies in human, published in the last 10 years, and ones written in English. After that, we combed through all articles cited and citing the articles so as not to miss any relevant articles.

### Inclusion criteria

Inclusion and exclusion criteria of this study were described using the method of PICO (Population, Intervention, Comparison, and Outcome) (Table 1). The inclusion criteria were GCT of bone in any location, with the intervention of minimally invasive surgery as compared to conventional open surgery, and recurrence rate and hospitalisation period as an outcome. Case reports and case series were also included. Given the limited number of

studies, there was no restriction in terms of patient's demographics, the specific minimally invasive surgical method, and publication status. We excluded all cases of GCT of soft tissue and ones located in the cranium.

### Quality evaluation

First, all authors screened eligible studies through the titles and abstracts based on inclusion criteria. Then, all authors screened the full articles of all the collected studies. The authors had a meeting and agreed on highly relevant publications to be included in this study. All authors performed an appraisal of study quality independently and any disagreement was resolved through discussion.

All inherent aspects of the studies, including study quality, variables for which data were sought, and assessment of the risk of bias, were appraised by all authors independently by filling up forms. The forms were collected by the first author and the contents were scanned for any disagreement. The authors then gathered again for discussing any contradicting points.

## Results

The electronic search resulted in 120 records, after the elimination of duplicate results. Based on titles and abstracts screening, a total of 99 records were excluded. The remaining articles were subsequently studied by two independent investigators based on the full text extracted. A list of inclusion and exclusion criteria (Table 1) previously agreed by the three authors were utilised for screening the full text. This selection process yielded 5 final articles to be included in the systematic review and was depicted in Figure 1.

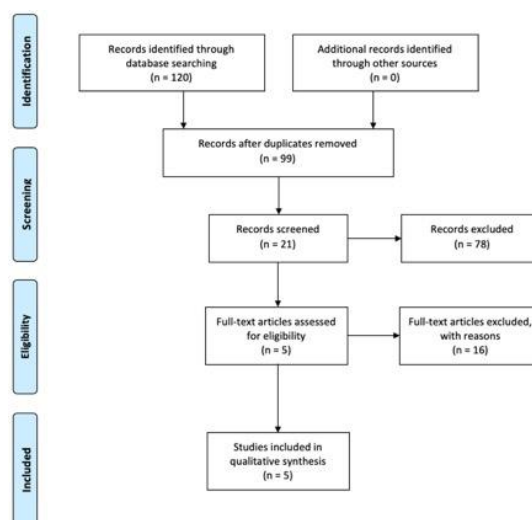


Figure 1: Article selection based on PRISMA Guidelines

In total, 16 patients were eventually included in the analysis. Among these patients, 3 patients had surgeries in the axial bones (vertebral body, sacrum, and pelvis) while the remaining 13 patients were of long bones (femur, tibia, and fibula). The axial bone group had a CT guided procedure to treat the GCT. In the long bones group, image intensifier was utilised for all 13 patients [5], [7].

**Table 1: PICO Table Describing Inclusion and Exclusion Criteria**

Study Component	Inclusion	Exclusion
Population	Any age Patients with Giant Cell Tumour of the bone in any location	Animal studies Patients with benign neoplasms other than GCT of the bone Infection or deformity
Intervention	Minimally invasive surgery as primary treatment for GCT	Adjunctive therapies for GCT Minimally invasive surgery as a treatment for GCT complication
Outcome	Functional outcome Oncological outcome	Radiological outcome
Publication	Studies published in English in peer-reviewed journals Any publication year	Abstracts, editorials, letters Duplicate publications of the same study that do not report on different outcomes Meeting presentations or proceedings
Study Design	All study design	-

Among them, 8 patients underwent the procedure with endoscope or osteoscope through a small incision, and the other 5 patients did not have additional visualisation inside the lesion [6], [8], [9]. The indication for studies of MIS of GCT in axial bones was tumours with high morbidity and failed conventional treatment [5], [7]. As for studies of long bones GCT, special attention was given to lesions around joint and one that still has cortical wall even though thin [6], [8], [9]. The summary of used methods and their indications were described in Table 2.

**Table 2: Summary of minimally invasive methods recorded in the literature**

No	Author	Method	Navigation	Indication
<b>Axial bones</b>				
1	Takeda, 2009 [7]	Curettage and argon beam coagulator	CT and MRI	Sacral and spinal GCT of bone
2	Panizza, 2015 [5]	Cryoablation	CT-guided	Extensive pelvic bone tumour. Failure of clinical treatment with denosumab and refusal of hemipelvectomy.
<b>Long bones</b>				
3	Robinson, 2004 [8]	Argon-based cryosurgery	Image intensifier	Lesions close to joint
4	Wong, 2010 [6]	Intralesional curettage and bone cement	Computer-assisted navigation and endoscope	Benign bone tumours without extraosseous extension.
5	Futani, 2018 [9]	Curettage and adjuvants of argon plasma coagulation (APC).	Osteoscopy with 30° endoscope.	GCT was developing in the proximal fibula. Tumour located inside the bone cavity surrounded by a cortical wall, even if this is thin.

The baseline characteristic of the study of Robinson (2004) was not described in details. As for the other studies, the patients were aged between 17 until 59 years old, and most were male (Table 3). The characteristic of the tumour was similar for the axial bones, a large lytic lesion in the sacrum, vertebral body, and pelvis. In the study by Panizza (2015), the pelvic tumour was described to have well-defined and sclerotic borders. While for the long bones, the tumours were of Campanacci grade 2-3 and located in

femur, tibia, and fibula.

**Table 3: Baseline Characteristics of Patients**

No	Author	Number of patients	Age	Gender	Tumour characteristics	Location
<b>Axial bones</b>						
1	Takeda, 2009 [7]	2	46	F	Large purely lytic process.	Right hemisacrum
			25	M	Large osteolytic lesion	L5 vertebral body, expanding to the spinal canal
2	Panizza, 2015 [5]	1	45	M	Large lytic, expansible, a locally aggressive lesion with well-defined and sclerotic borders.	Pelvis
<b>Long bones</b>						
3	Robinson, 2004 [8]	5	NA	NA	NA	Proximal fibula [1], NA [4]
4	Wong, 2010 [6]	3	47	M	NA	Right medial distal femur
			34	F	NA	Left proximal lateral tibia
			26	F	NA	Right lateral distal femur
5	Futani, 2018 [9]	5	17-59	All male	Campanacci grade 2-3	Proximal fibula

Abbreviations: NA, not available.

Patients of GCT in axial bones had follow-up between 60-74 months, and long bones GCT between 7-126 months. The outcome for axial bones GCT was overall satisfying, with the preserved function of lower limbs, bladder and bowel, and no recurrence or metastasis. There was however a movement impairment of hallux for pelvic tumour reconstruction case. MIS for long bones yielded an acceptable result with mean early postoperative VAS of 2.2 (range, 1-3), full ROM and unaided walking, no knee instability or decreased Tegner scores, and MSTs of 100%. The oncological outcome was good without any metastasis or recurrence except on one patient with tumour recurrence at proximal fibula (Table 4).

**Table 4: Functional outcome of each study**

No	Author	Follow up (months)	Functional Outcome	Oncological Outcome
<b>Axial bones</b>				
1	Takeda, 2009 [7]	60-74	The function of lower limbs, bladder, and bowel preserved.	No recurrence.
2	Panizza, 2015 [5]	NA	Able to walk a 10 km distance. Movement impairment of hallux.	No local or metastatic progression of tumor.
<b>Long bones</b>				
3	Robinson, 2004 [8]	24	NA	Tumour recurrence at the proximal fibula.
4	Wong, 2010 [6]	7-9	Mean early postoperative VAS 2.2 (range, 1-3). All patients had full ROM and walked unaided at 4 weeks post-surgery.	No local recurrence. Good cementation of the skeletal defect.
5	Futani, 2018 [9]	24-126	Knee instability negative in all cases. Mean MSTs rating was 100%. Tegner scores the same as before surgery.	No local recurrence. No pulmonary metastasis.

Abbreviations: NA, not available; VAS, Visual Analog Scale.

Quality of evidence was assessed with all studies categorised as level IV.

**Table 5: Characteristics of journals used in the study**

No	Reference	Journal	Study Design	Level of Evidence
1	Takeda, 2009 [7]	Journal of Orthopaedic Science	Case Series	Level IV
2	Panizza, 2015 [5]	Cardiovascular and Interventional Radiological Society of Europe	Case Report	Level IV
3	Robinson, 2004 [8]	Technology in Cancer Research & Treatment	Case Series	Level IV
4	Wong, 2010 [6]	Computer-Aided Surgery	Case Series	Level IV
5	Futani, 2018 [9]	Anticancer Research	Case Series	Level IV

Each one had the different instrument to assess the functional outcome, while the oncological outcome was assessed almost similarly according to recurrence and metastasis rate (Table 5).

## Discussion

The traditional method of managing locally aggressive bone tumour such as GCT includes intralesional curettage followed by local adjuvants. The bone is decorticated to access the tumour, which is then curetted. The osseous surface of the tumour cavity is then cleared using high-speed burr. This conventional invasive method inflicts a lot of damage to the living tissue, something that could be improved by introducing a less invasive approach. The advantage of the minimally invasive approach is particularly the decrease of morbidity in GCT of axial bones and the function preservation of periarticular lesions of long bones.

One of the problems commonly found regarding GCT treatment is a local recurrence and increased risk of pulmonary metastases. In surgically inaccessible lesions such as spine and pelvis, sometimes the lesion cannot be completely resected, further contributing to this problem. Conventional treatment using curettage with or without adjunct, burring, bone cement, H<sub>2</sub>O<sub>2</sub>, and/or sponge-bone have not proven to be satisfactory in terms of outcome, as well as wide resection procedure. Furthermore, the recurrence rate was still high ( $\pm$  30.8%), and even more in long bones (45.5-88.9%). Pulmonary metastases rate was  $\pm$  3.3%, not to mention the possible metastases in other organs, such as soft tissue, brain, and small intestine, resulting in increased mortality and hospitalisation cost [10].

In a study by van der Heiden *et al.*, (2014), en bloc resection was known to result in the lowest recurrence rate (0-16%). However, this procedure has higher complication risk, increased possibility of the subsequent need for revision surgery, and worse functional outcome compared to MIS. For GCT of axial bones, invasive surgery may result in higher morbidity, as it may increase the possibility of bleeding, infection, neurological deficits, bladder, rectal, and sexual dysfunction [2].

### **MIS for GCT of axial bones**

Sacral GCT is a rare difficult case, and there are still controversies on the optimal treatments for the lesion. Conventional methods still result in a low rate of tumour control, high rate of complications and functional outcome. It is even more challenging when the defect is significantly large that excessive bleeding

and pelvic instability might ensue after resection [11], [12], [13]. Extensive surgery might also damage neighbouring nerves and may result in cauda equina syndrome. Bladder and rectal dysfunction also lead to increased morbidity [14], [15]. The restricted use of radiotherapy for sacral GCT (as it may result in radiation-induced sarcoma) makes the conventional treatment more difficult [16].

In this study, we interpret "less invasive" as an approach which introduces less damage to tissue than mainstay treatment. This is especially true for GCT of axial bones whose conventional treatment is complete excision, including complete removal of sacral nerve roots [5], [7]. Aiming at minimal damage to surrounding tissues, the surgeons devised minimal invasive procedures using curettage and argon beam coagulator [7] or cryoablation [5] while protecting relevant nerve roots throughout procedure under direct visualisation. In one case where nerve injury still occurred despite the precautions, Panizza *et al.*, (2015) recommended the electrophysiological monitoring in addition to displacement techniques using gas or fluid to protect the nerve roots.

### **MIS for GCT near joint of long bones**

Some serious postoperative complications associated with resection of GCT of the proximal fibula are peroneal nerve palsy and local recurrence. Local recurrence rate differs depending on tumour histology and resection type, while the incidence of postoperative peroneal nerve palsy ranges from 3% to 57% [17] and closely relates to the patient's functional outcome. The fate of the peroneal nerve here also depends on preoperative chemotherapy response, which if the tumour responds well, then the amount of tissue resected can be minimalised and the peroneal nerve can be more well preserved. In patients with peroneal nerve palsy, the functional outcome is lower and peroneal braces might be needed [18]. For selected patients, MIS techniques in treating GCT of the bone in certain locations of the body have advantages such as preservation of anatomically important tissue and also the possibility of intralesional resection. Futani *et al.* (2018) used MIS to treat GCT at the proximal fibula since the area is highly important for knee stability. MIS allowed thorough tumour removal without compromising ligaments attached around that area.

The other highlight of this technique is the use of magnification with equipment which provides excellent visualisation of the bone cavity. Direct visualisation can be provided by osteoscopy or endoscopy which magnifies the inside of lesion onto large monitors, enabling surgeons to identify small residual tumours [6], [9]. Additionally, the computer navigation system can also be used to confirm whether the curettage is already as thorough as a preoperative plan [6]. A combination of these visualisation methods permits assurance of complete

curettage without compromising the tissue too much.

**Limitation of MIS:** Despite the success of the studies presented, there are still limitations. Cryoablation in the study of Panizza, 2016, was performed in 2 stages after ensuring that the first stage did not yield unwanted necrosis of adjuvant tissues, a reported complication of the surgery [19]. Cryoablation technique might also be challenging when it comes to treating a large complex bone lesion, where multiple probes and imaging might be needed to plan serial repositioning sessions [5]. Whereas in argon beam coagulator technique for treating GCT of axial bones, there is a risk of damaging neural tissue, when the tip of the nozzle is initiated before reaching at least 1 cm of the tissue surface [7]. For extraskelatal lesions, osteoscopic surgery method should also be used cautiously, where if the lesion fails to create a sclerotic wall using denosumab, then this method is no longer suitable to apply [9]. In general, MIS requires surgeons who are well-adapted to endoscopic and navigation surgeries.

Furthermore, the novelty of the system results in higher cost and the need for sophisticated supporting facilities. Wong *et al.*, (2010) also hoped that in the future, there would be an established navigation software system along with more developed special tools for endoscopic tumour surgery, to facilitate this advanced method of treatment [6]. There is a need for future studies with better study design to assess the added value of developing and utilising sophisticated equipment for treating GCT of the bone.

In conclusion, despite the limited number of studies, MIS yields satisfying functional and oncological outcome for GCT around axial bones and long bones. In axial bones, MIS has a particular role in treating GCT of spine and pelvis with high morbidity by negating the need of en bloc resection. There are also certain benefits of treating GCT of long bones with periarticular lesions. The most prominent advantage of MIS is its excellent intralesional visualisation with equipment which has been widely utilised in orthopaedics fields, thus reducing the cost of developing sophisticated new equipment. However, further cost-benefit analysis is needed to justify the addition of these sophisticated equipment.

## References

1. Siebenrock KA, Unni KK, Rock MG. Giant-cell tumour of bone metastasising to the lungs. A long-term follow-up. *J Bone Joint Surg Br.* 1998; 80:43-7. <https://doi.org/10.1302/0301-620X.80B1.0800043> PMID:9460951
2. van der Heijden L, Dijkstra PDS, van de Sande MAJ, et al. The Clinical Approach Toward Giant Cell Tumor of Bone. *Oncologist.* 2014; 19:550-561. <https://doi.org/10.1634/theoncologist.2013-0432> PMID:24718514 PMCID:PMC4012970
3. Errani C, Ruggieri P, Asenzio MAN, et al. Giant cell tumor of the extremity: A review of 349 cases from a single institution. *Cancer Treatment Reviews.* 2010. <https://doi.org/10.1016/j.ctrv.2009.09.002> PMID:19879054
4. Ellis F. Treatment of Osteoclastoma by Radiation. *J Bone Joint Surg Br.* 2018.
5. Panizza PSB, de Albuquerque Cavalcanti CF, Yamaguchi NH, et al. Percutaneous CT-Guided Cryoablation as an Alternative Treatment for an Extensive Pelvic Bone Giant Cell Tumor. *Cardiovasc Intervent Radiol.* 2016; 39:299-303. <https://doi.org/10.1007/s00270-015-1160-x> PMID:26126580
6. Wong KC, Kumta SM, Tse LF, et al. Navigation Endoscopic Assisted Tumor (NEAT) surgery for benign bone tumors of the extremities. *Comput Aided Surg.* 2010. <https://doi.org/10.3109/10929081003775881> PMID:20433316
7. Takeda N, Kobayashi T, Tandai S, et al. Treatment of giant cell tumors in the sacrum and spine with curettage and argon beam coagulator. *J Orthop Sci.* 2009; 14:210-214. <https://doi.org/10.1007/s00776-008-1299-2> PMID:19337814
8. Robinson D, Yassin M, Nevo Z. Cryotherapy of Musculoskeletal Tumors - From Basic Science to Clinical Results. *Technol Cancer Res Treat.* 2004; 3:371-375. <https://doi.org/10.1177/153303460400300407> PMID:15270588
9. Futani H, Kumanishi S, Minakawa GO, et al. Osteoscopic Surgery of Giant Cell Tumor of Bone for Preservation of Proximal Fibula. *Anticancer Res.* 2018; 38:2995-3000. <https://doi.org/10.21873/anticancer.12552>
10. Balke M, Schremper L, Gebert C, et al. Giant cell tumor of bone: Treatment and outcome of 214 cases. *J Cancer Res Clin Oncol.* 2008; 134:969-978. <https://doi.org/10.1007/s00432-008-0370-x> PMID:18322700
11. Guo W, Ji T, Tang X, et al. Outcome of conservative surgery for giant cell tumor of the sacrum. *Spine (Phila Pa 1976).* 2009. <https://doi.org/10.1097/BRS.0b013e31819d4127> PMID:19404178
12. Thangaraj R, Grimer RJ, Carter SR, et al. Giant cell tumour of the sacrum: A suggested algorithm for treatment. *Eur Spine J.* 2010. <https://doi.org/10.1007/s00586-009-1270-8> PMID:20076978 PMCID:PMC2900020
13. Martin C, McCarthy EF. Giant cell tumor of the sacrum and spine: series of 23 cases and a review of the literature. *Iowa Orthop J.* 2010; 30:69.
14. Sar C, Eralp L. Surgical treatment of primary tumors of the sacrum. *Arch Orthop Trauma Surg.* 2002. <https://doi.org/10.1007/s00402-001-0356-5> PMID:11927996
15. Wuisman P, Lieshout O, Sugihara S, et al. Total sacrectomy and reconstruction: oncologic and functional outcome. *Clin Orthop Relat Res.* 2000; 381:192-203. <https://doi.org/10.1097/00003086-200012000-00023> PMID:11127656
16. van der Heijden L, van de Sande MAJ, van der Geest ICM, et al. Giant cell tumors of the sacrum--a nationwide study on midterm results in 26 patients after intralesional excision. *Eur Spine J.* 2014; 23:1949-1962. <https://doi.org/10.1007/s00586-014-3263-5> PMID:24614982
17. Abdel MP, Papagelopoulos PJ, Morrey ME, et al. Surgical management of 121 benign proximal fibula tumors. In: *Clinical Orthopaedics and Related Research.* 2010. <https://doi.org/10.1007/s11999-010-1464-8> PMID:20625947 PMCID:PMC2947668
18. Inatani H, Yamamoto N, Hayashi K, et al. Surgical management of proximal fibular tumors: A report of 12 cases. *J Bone Oncol.* 2016; 5:163-166. <https://doi.org/10.1016/j.jbo.2016.06.001> PMID:28008377 PMCID:PMC5154704
19. Marcove RC, Sheth DS, Brien EW, et al. Conservative surgery for giant cell tumors of the sacrum. The role of cryosurgery as a supplement to curettage and partial excision. *Cancer.* 1994; 74(4):1253-60. [https://doi.org/10.1002/1097-0142\(19940815\)74:4<1253::AID-CNCR2820740412>3.0.CO;2-9](https://doi.org/10.1002/1097-0142(19940815)74:4<1253::AID-CNCR2820740412>3.0.CO;2-9)