

# A refractory arachnoid cyst presenting with tremor, expressive dysphasia, and cognitive decline

Nathan T. Zwagerman, Jamie Pardini, Seyed H. Mousavi, Robert M. Friedlander

Department of Neurological Surgery, University of Pittsburgh Medical Center, Pittsburgh, PA, USA

E-mail: Nathan T. Zwagerman - [zwagermant@upmc.edu](mailto:zwagermant@upmc.edu); Jamie Pardini - [pardinij@upmc.edu](mailto:pardinij@upmc.edu); Seyed H. Mousavi - [mousavish@upmc.edu](mailto:mousavish@upmc.edu);  
\*Robert M. Friedlander - [friedlanderr@upmc.edu](mailto:friedlanderr@upmc.edu)  
\*Corresponding author

Received: 31 October 15    Accepted: 24 February 16    Published: 03 June 16


## Abstract

**Background:** Arachnoid cysts are common incidental findings on intracranial imaging, although they are rarely symptomatic.

**Case Description:** We present a case of a 49 year-old woman with a recurrent left supraorbital arachnoid cyst who developed staring spells, expressive dysphasia, and tremor after cyst fenestration and cystoperitoneal shunting. Her symptoms resolved after removing the shunt valve and creating a valveless system. The case is discussed and the literature reviewed.

**Conclusion:** We present a case of a recurrent arachnoid cyst that developed worsening and new symptoms after cysto-peritoneal shunting with a programmable valve, which reducing the pressure in the cyst resulted in remarkable resolution of her symptoms.

**Key Words:** Arachnoid cyst, cystoperitoneal shunt, optic nerve, seizures, tremor, valve-less shunt

|   |
|---|
| <b>Access this article online</b>   |
| <b>Website:</b><br><a href="http://www.surgicalneurologyint.com">www.surgicalneurologyint.com</a> |
| <b>DOI:</b><br>10.4103/2152-7806.183541   |
| <b>Quick Response Code:</b>   |
|              |

## INTRODUCTION

The expansion of imaging capabilities has made the diagnosis of arachnoid cysts an increasingly common incidental finding on intracranial imaging. Previous studies on the topic have estimated the prevalence to be between 0.3% and 1.7% of the general population and highest in the pediatric subpopulation with a prevalence of 2.6%.<sup>[2,3,7,10,11,16,17]</sup> Of those patients who harbor cysts, 5.3% are believed to be symptomatic.<sup>[1]</sup> Cysts located in the suprasellar, cerebellopontine angle, ambient cistern, and quadrigeminal cistern are more likely to be symptomatic given their proximity to cranial nerves and propensity to cause hydrocephalus. The treatment of symptomatic cysts is centered on surgical intervention through complete removal of the entire cyst wall, cyst fenestration, or cyst shunting, often in combination.<sup>[5,8,12-15]</sup> We present a case of a 49-year-old woman who had a symptomatic arachnoid cyst reoccur after fenestration elsewhere and underwent cyst shunting with a programmable shunt valve. Despite

clear resolution of the cyst on further imaging, she developed new symptoms, which resolved both on physical examination and neuropsychological testing after removing of the shunt valve and creation of a valveless system.

## CASE REPORT

A 49-year-old right-handed woman presented with left-sided headache, double vision, and left-sided facial

This is an open access article distributed under the terms of the Creative Commons Attribution-NonCommercial-ShareAlike 3.0 License, which allows others to remix, tweak, and build upon the work non-commercially, as long as the author is credited and the new creations are licensed under the identical terms.

**For reprints contact:** [reprints@medknow.com](mailto:reprints@medknow.com)

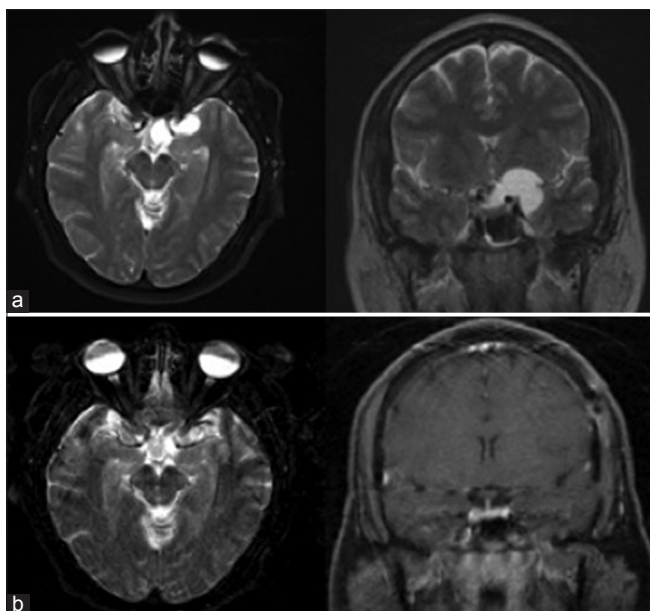
**How to cite this article:** Zwagerman NT, Pardini J, Mousavi SH, Friedlander RM. A refractory arachnoid cyst presenting with tremor, expressive dysphasia, and cognitive decline. *Surg Neurol Int* 2016;7:S431-3.  
<http://surgicalneurologyint.com/A-refractory-arachnoid-cyst-presenting-with-tremor,-expressive-dysphasia,-and-cognitive-decline/>

numbness. She was found to have a multiloculated lesion appearing to originate from the region of the left orbital apex measuring 3 cm × 2.5 cm × 1.7 cm with signal intensity consistent with cerebrospinal fluid (CSF) likely representing an arachnoid cyst. The lesion displaced the optic chiasm to the right. The left optic nerve was also displaced along with the internal carotid artery and middle cerebral artery [Figure 1a]. She underwent a left pterional craniotomy for broad cyst fenestration/resection without complications. Postoperatively, she reported total resolution of her symptoms. Postoperative imaging indicated complete resolution of her cyst [Figure 1b]. Three years later, she developed recurrence of her presenting symptoms. Follow-up imaging indicated that the cyst had recurred [Figure 2a]. She subsequently underwent a second craniotomy, cyst fenestration, and placement of a left cystoperitoneal shunt. Postoperatively, she suffered from a new tremor and underwent electroencephalogram (EEG) testing. Although no seizures were noted, the neurologist recommended treating her with Keppra. Her postoperative imaging confirmed resolution of the cyst [Figure 2b]. Although her headache and visual symptoms had improved, she began to suffer from new symptoms including staring spells, severe expressive aphasia, and right upper extremity tremor that she did not have preoperatively. Neuropsychological evaluation revealed difficulty with expressive language, cognitive flexibility, bilateral manual dexterity, psychomotor slowing, attention, and depression

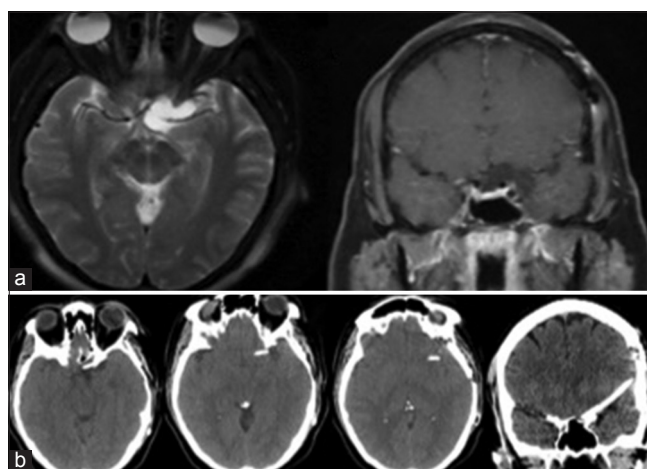
symptoms. She returned to the neurosurgery clinic 2 weeks after surgery and found to have a new left-sided pseudomeningocele. Her adjustable shunt valve was programed to the lowest setting. She returned to clinic 1 month later without change in her symptoms, imaging, or pseudomeningocele. A radiotracer shunt evaluation was performed which demonstrated proximal and distal shunt patency. She was taken back to the operative theater for dural repair and for conversion of her shunt to a valveless system. The shunt was evaluated during surgery, demonstrating complete proximal patency and proper distal drainage proximal to the valve. Postoperatively, her symptoms of aphasia, facial pain, and tremor were completely resolved. Follow-up formal neuropsychological testing indicated significant improvements in expressive speech, verbal fluency, psychomotor speed, bilateral fine motor speed, and mood. Relative to estimated premorbid function, she had continued mild difficulty with memory and verbal fluency. At her 9-month follow-up, she is almost asymptomatic.

## DISCUSSION

Arachnoid cysts are a common incidental finding on intracranial imaging and in the vast majority of cases have a benign course and do not require treatment. A recent report by Al-Holou *et al.* indicated the imaging prevalence of 1.4% in adults.<sup>[1]</sup> Arachnoid cysts are more common in men and cyst locations in decreasing order of prevalence include the middle fossa, retrocerebellar, and cerebral convexity.<sup>[1]</sup> The majority of cysts is on the left side, followed by the center, and finally those on the right. Of those harboring arachnoid cyst, 5.3% were believed to be symptomatic. The most common



**Figure 1:** (a) T2 axial and coronal weighted magnetic resonance imaging depicting the preoperative arachnoid cyst located in the left supraorbital region compressing the left optic nerve, optic chiasm, internal carotid artery, and middle cerebral artery. (b) T2-weighted axial and T1 with contrast magnetic resonance imaging taken after left pterional craniotomy following fenestration of the cyst with near complete resolution of the cyst and patient symptoms



**Figure 2:** (a) T2-weighted axial and T1 with contrast coronal magnetic resonance imaging depicting a recurrent arachnoid cyst 3 years after surgical intervention for first cyst. (b) Sequential axial computed tomography images and coronal computed tomography image indicating the location of the cystoperitoneal shunt within the now obliterated cyst. Note: The catheter is not intraparenchymal but rather traveling on the skull base

symptoms from symptomatic cysts are headache, hydrocephalus, ataxia, seizures, dizziness, visual changes, nausea, and hearing loss.<sup>[1]</sup> Rarely, speech abnormalities and symptoms associated with a cervical syrinx have been reported.<sup>[9]</sup> Symptomatic cysts are most often found suprasellar, cerebellopontine angle, ambient cistern, and quadrigeminal cistern. Cyst in the retrocerebellar and middle fossa locations were less likely to produce symptoms.<sup>[1]</sup> Symptomatic arachnoid cysts are treated surgically with fenestration into cisterns or by placement of a cystoperitoneal shunt. At our institution, most shunts are placed with programmable valves.<sup>[4,6,8,12]</sup>

Surgical complications from treatment of arachnoid cysts include postoperative intracranial hematomas, CSF leak, infection, injury to vasculature, stroke, seizure, brain injury, nerve injury, pituitary dysfunction, or complications related to general anesthesia.<sup>[4,13]</sup> Complications are specific to the location of the cyst as sellar and suprasellar cysts tend to have more endocrine abnormalities. Seizures can be a complication of intracranial surgery and may be prevented with prophylactic treatment with antiepileptics after surgery. Speech disturbance has been observed after surgical treatment of an arachnoid cyst but is often associated with other imaging abnormalities including hemorrhage.<sup>[9]</sup>

Our patient had a symptomatic cyst that underwent fenestration with complete resolution of her symptoms for 3 years. After recurrence of her symptoms, imaging demonstrated recurrence of the cyst. For recurrent arachnoid cysts, the senior author placed a cystoperitoneal shunt using a programmable valve. Despite complete resolution of the cyst after surgery, the patient developed new symptoms including concerning EEG findings that were controlled with antiepileptic medications. Our patient suffered new cognitive decline, severe expressive aphasia, and tremors without any remarkable imaging finding to explain the new symptoms. The decision to remove the valve was made because the patient's pseudomeningocele was not improving despite the fact that the shunt was functional, and the valve was programmed to the minimum pressure setting. After removing the valve, the pseudomeningocele and (to our surprise) her severe expressive aphasia and tremors were completely resolved.

We speculate that the cause of the symptomatic decline following placement of the cyst to peritoneal shunt was surgical irritation of the temporal lobe combined with the residual pressure in the cyst. Although the purpose of eliminating the valve was to treat the pseudomeningocele, clearly reducing the cyst pressure resulted in a surprising and marked improvement of her severe expressive aphasia and tremors. Reduction of cyst pressure was enough for this patient to demonstrate a remarkable improvement. This case suggests that with symptomatic arachnoid cysts, symptoms may be related to subtle compression of adjacent neural structures, which may be relieved with the use of a valveless shunt system.

## CONCLUSIONS

We present a case of a woman with a recurrent arachnoid cyst who, after cystoperitoneal shunting with a programmable valve, developed worsening and new symptoms, both on physical examination and neuropsychological testing. Reducing the pressure in the cyst resulted in remarkable resolution of her symptoms.

## Financial support and sponsorship

Nil.

## Conflicts of interest

There are no conflicts of interest.

## REFERENCES

1. Al-Holou WN, Terman S, Kilburg C, Garton HJ, Muraszko KM, Maher CO. Prevalence and natural history of arachnoid cysts in adults. *J Neurosurg* 2013;118:222-31.
2. Al-Holou WN, Yew AY, Boomsaad ZE, Garton HJ, Muraszko KM, Maher CO. Prevalence and natural history of arachnoid cysts in children. *J Neurosurg Pediatr* 2010;5:578-85.
3. Banna M. Arachnoid cysts on computed tomography. *AJR Am J Roentgenol* 1976;127:979-82.
4. Choi KY, Jung S, Kang SS, Kim IY, Jung TY, Jang WY. Technical considerations to prevent postoperative endocrine dysfunction after the fenestration of suprasellar arachnoid cyst. *J Korean Neurosurg Soc* 2011;49:262-6.
5. Ciricillo SF, Cogen PH, Harsh GR, Edwards MS. Intracranial arachnoid cysts in children. A comparison of the effects of fenestration and shunting. *J Neurosurg* 1991;74:230-5.
6. Duz B, Kaya S, Daneyemez M, Gonul E. Surgical management strategies of intracranial arachnoid cysts: A single institution experience of 75 cases. *Turk Neurosurg* 2012;22:591-8.
7. Eskandary H, Sabba M, Khajehpour F, Eskandari M. Incidental findings in brain computed tomography scans of 3000 head trauma patients. *Surg Neurol* 2005;63:550-3.
8. Gangemi M, Seneca V, Colella G, Cioffi V, Imperato A, Maiuri F. Endoscopy versus microsurgical cyst excision and shunting for treating intracranial arachnoid cysts. *J Neurosurg Pediatr* 2011;8:158-64.
9. Gündüz B, Yassa M, Ofluoglu E, Ekinci B, Erdogan U, Asiltürk M, et al. Two cases of arachnoid cyst complicated by spontaneous intracystic hemorrhage. *Neurol India* 2010;58:312-5.
10. Katzman GL, Dagher AP, Patronas NJ. Incidental findings on brain magnetic resonance imaging from 1000 asymptomatic volunteers. *JAMA* 1999;282:36-9.
11. Kim BS, Illes J, Kaplan RT, Reiss A, Atlas SW. Incidental findings on pediatric MR images of the brain. *AJNR Am J Neuroradiol* 2002;23:1674-7.
12. Levy ML, Wang M, Aryan HE, Yoo K, Meltzer H. Microsurgical keyhole approach for middle fossa arachnoid cyst fenestration. *Neurosurgery* 2003;53:1138-44.
13. Mottolese C, Szathmari A, Simon E, Ginguene C, Ricci-Franchi AC, Hermier M. The parallel use of endoscopic fenestration and a cystoperitoneal shunt with programmable valve to treat arachnoid cysts: Experience and hypothesis. *J Neurosurg Pediatr* 2010;5:408-14.
14. Rosell R, Monzó M, Pifarré A, Ariza A, Sánchez JJ, Moreno I, et al. Molecular staging of non-small cell lung cancer according to K-ras genotypes. *Clin Cancer Res* 1996;2:1083-6.
15. Shim KW, Lee YH, Park EK, Park YS, Choi JU, Kim DS. Treatment option for arachnoid cysts. *Childs Nerv Syst* 2009;25:1459-66.
16. Vernooij MW, Ikram MA, Tanghe HL, Vincent AJ, Hofman A, Krestin GP, et al. Incidental findings on brain MRI in the general population. *N Engl J Med* 2007;357:1821-8.
17. Weber F, Knopf H. Incidental findings in magnetic resonance imaging of the brains of healthy young men. *J Neurol Sci* 2006;240:81-4.