

BRIEF REPORT

Concentrations of VEGF and PlGF Decrease in Eyes After Intravitreal Conbercept Injection

Jun Zhou · Zheng Liu · Meng Chen · Zhi-Heng Luo · Yun-Qiu Li ·
Guang-Ying Qi · Tao Liu 

Received: August 4, 2018 / Published online: October 30, 2018
© The Author(s) 2018

ABSTRACT

Introduction: Conbercept is a new anti-vascular endothelial growth factor drug approved for the treatment of age-related macular degeneration by the China Food and Drug Administration (CFDA) in 2013. In this study, we for the first time evaluated the concentrations of vascular endothelial growth factor (VEGF) and placental growth factor (PlGF) after patients

with proliferative diabetic retinopathy were treated with intravitreal conbercept (IVC) injection.

Methods: Sixteen patients with proliferative diabetic retinopathy were randomly divided into two equal groups (A and B). Nine patients with rhegmatogenous retinal detachment were used as the control group. The patients in group A received 0.5 mg IVC and their aqueous humor was collected. After 7 days, all patients underwent vitrectomy, and their aqueous and vitreous humor were collected.

Results: In the aqueous humor, the concentrations of VEGF and PlGF were higher pre- than post-IVC injection in group A. Similarly, the concentrations of VEGF and PlGF in group A (pre-IVC) and group B were higher than those in the control group. In vitreous humor, the concentrations of VEGF and PlGF were higher in group B than those in the control group, and the concentrations of VEGF were lower in group A (post-IVC) than those in group B.

Conclusions: Our study proved that the concentration of VEGF and PlGF reduced after IVC injection in aqueous humor. However, the concentration of PlGF did not reduce after IVC injection in vitreous humor.

Keywords: Aqueous humor; Conbercept; Placental growth factor; Vascular endothelial growth factor; Vitreous humor

Jun Zhou and Zheng Liu contributed equally to this work.

Enhanced digital features To view enhanced digital features for this article go to <https://doi.org/10.6084/m9.figshare.7228679>.

J. Zhou · Z. Liu · M. Chen · T. Liu (✉)
Department of Ophthalmology, 3201 Hospital,
Xi'an Jiaotong University Health Science Center,
Hanzhong, Shaanxi, China
e-mail: taoliustone@hz3201.com

J. Zhou
Department of Ophthalmology, Hanzhong Central
Hospital, Hanzhong, Shaanxi, China

Z. Liu · Y.-Q. Li · G.-Y. Qi
College of Medical Laboratory Science, Guilin
Medical University, Guilin, Guangxi, China

Z.-H. Luo
Vitamin D Research Institute, Shaanxi University of
Technology, Hanzhong, Shaanxi, China

INTRODUCTION

Diabetic retinopathy (DR) is the most common cause of vision loss among people with diabetes mellitus (DM) [1]. According to the data from a global pooled analysis, the overall prevalence was 34.6% for any DR, 6.96% for proliferative DR (PDR), and 6.81% for diabetic macular edema [2]. More seriously, 20.1% of type 1 DM cases and 25.4% of type 2 DM cases experienced vision loss within 10 years [3]. Vascular endothelial growth factor (VEGF) and placental growth factor (PlGF) are known to play important roles in the pathogenesis of PDR by inducing pre-retinal neovascularization and disrupting the blood–retinal barrier [4]. Anti-VEGF drugs, such as bevacizumab, ranibizumab, and aflibercept, were developed as new approaches to treat PDR [5]. However, they still have some unsatisfactory aspects. In November 2013, the China Food and Drug Administration (CFDA) approved conbercept (KH902; Chengdu Kanghong Biotech Co., Ltd., Sichuan, China), a new drug comprising VEGFR fusion proteins, which can specifically bind to VEGF-A, VEGF-B, and PlGF, for treatment of wet age-related macular degeneration [4]. In several previous studies, intravitreal conbercept (IVC) injection was proved to be an effective and safe treatment for patients with diabetic macular edema and retinopathy of prematurity [6]. On the other hand, the anti-VEGF drugs have been proved to be beneficial to vitrectomy procedures by reducing the chances of intraoperative bleeding owing to decreased concentrations of VEGF and PlGF [7]. Therefore, determining the concentration of VEGF and PlGF is important. Low concentrations of VEGF and PlGF would reduce the risk of intraoperative hemorrhage. In this study, we for the first time evaluated the concentrations of VEGF and PlGF in the aqueous and vitreous humor after patients received an IVC injection.

METHODS

Study Subjects

Sixteen patients with PDR and nine patients with non-diabetic rhegmatogenous retinal

detachment were recruited at our hospital. All patients underwent a complete ophthalmoscopic examination, including the best corrected visual acuity, slit lamp microscope, optical coherence tomography, fundus fluorescein angiography, B-scan ultrasound, intraocular pressure, and fundus photography. The patients who met the following criteria were included: age 18 years or older, diagnosis of type 2 diabetes, clinical diagnosis of PDR, and needed pars plana vitrectomy surgery. The patients were not eligible for the study if they had extremely high blood pressure, vitreoretinal disease other than DR, markedly reduced kidney and liver function, heart disease, senile macular degeneration, high myopia, retinal vasculitis, and history of retinal laser photocoagulation or intravitreal injection or vitrectomy. Informed consent was obtained from all participants. All procedures performed in this study were in accordance with the ethical standards of the Xi'an Jiaotong University committee and the Helsinki declaration of 1975, as revised in 2008.

Intravitreal Conbercept Injection and Sample Collection

Sixteen patients with PDR were randomly divided into two equal groups A (nine eyes) and B (nine eyes). The control group included nine non-diabetic rhegmatogenous retinal detachment patients (nine eyes). As shown in Fig. 1a, the patients in group A received 0.5 mg IVC injection after 100 μ L aqueous humor was collected. After 7 days, the aqueous and vitreous humor were collected from groups A and B and the controls in the vitrectomy procedure. All patients completed follow-up at 1 week, 1 month, and 3 months.

Measurement of VEGF and PlGF Concentrations

ELISA analysis was performed using Human VEGF ELISA kit and Human PlGF ELISA kit (Boster Biological Technology, Wuhan, China) according to the manufacturer's instructions. Briefly, 20 μ L of each sample was pipetted into a

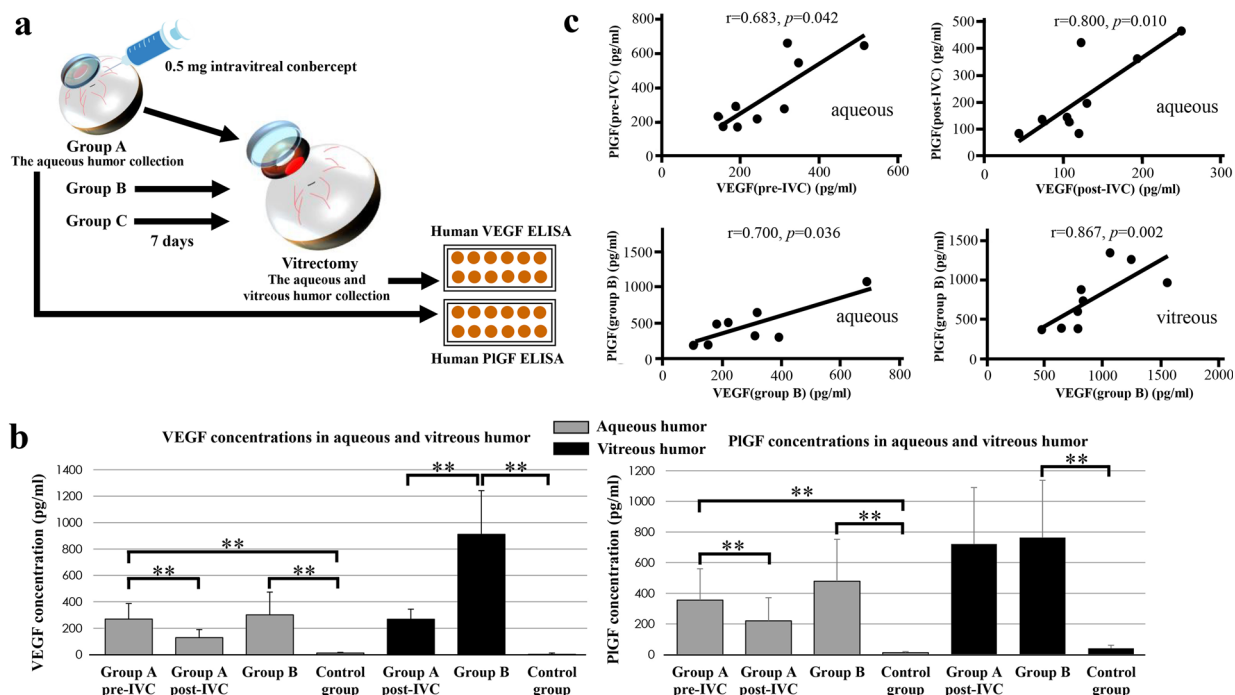


Fig. 1 Before and after the patients received the intravitreal conbercept treatment and underwent vitrectomy. **a** Schematic flow diagram of the process in this work. **b** Concentrations of VEGF and PIGF in the aqueous and

vitreous humor pre- and post-intravitreal conbercept injection. **c** Correlation between the concentrations of VEGF and PIGF in the aqueous and vitreous humor. $**p < 0.01$

96-well plate pre-coated with polyclonal anti-human VEGF or PIGF antibody. After incubation with a second antibody, the reaction was terminated by adding a stop solution. The absorbance of the resulting yellow product was measured at 450 nm on a microplate reader (BioTek Epoch). All ELISA experiments were performed in triplicate and were repeated three times.

Statistical Analysis

The data were expressed as mean \pm standard deviation. Statistical comparisons of the three groups were performed using one-way analysis of variance (ANOVA). The Wilcoxon-signed rank test was used to compare the concentrations of PIGF and VEGF between groups. Spearman correlation analysis was used to analyze the correlation between VEGF and PIGF in aqueous and vitreous humor. All statistical analyses were performed using SPSS 18.0 for Windows (SPSS Inc., Chicago, IL, USA). For all

tests, $p < 0.05$ was considered statistically significant.

RESULTS

Patients' Characteristics

In total, 27 eyes of 25 patients (11 women and 14 men) with a mean age of 51.69 ± 8.5 years (range 34–78) were recruited in the study. The mean duration of diabetes was 15.69 ± 8.73 years (range 4–31). There were no differences in sex or the mean age between these three groups (Table 1).

Concentrations of VEGF and PIGF in Aqueous Humor

As shown in Fig. 1b, the concentrations of VEGF (269.3 ± 118.1 pg/mL) and PIGF (355.5 ± 204.9 pg/mL) in group A (pre-IVC) were higher than those (VEGF, 128.7 ± 60.7 pg/mL; PIGF,

Table 1 Summary of patients (mean and standard deviation with statistical significance of the postvitrectomy vs. pre-vitrectomy, * $p < 0.05$)

Group	Number of patients (eyes)	Age (years)	Sex (M/F)	LogMAR BCVA Duration of follow-up			
				Previtrectomy	Postvitrectomy, 1 week	Postvitrectomy, 1 month	Postvitrectomy, 3 months
Group A	8 (9)	50.11 ± 13.09	5/3	2.213 ± 0.641	1.073 ± 0.591*	0.84 ± 0.556*	0.743 ± 0.487*
Group B	8 (9)	55.44 ± 9.71	2/6	2.358 ± 0.823	1.507 ± 1.017*	1.26 ± 0.95*	1.147 ± 0.95*
Control	9 (9)	50.11 ± 6.19	7/2	1.733 ± 1	0.626 ± 0.238*	0.52 ± 0.212*	0.48 ± 0.199*

LogMAR logarithm of the minimal angle of resolution, *BCVA* best-corrected visual acuity

219.6 ± 151.5 pg/mL) in group A (post-IVC) (both $Z = -2.666$, $p = 0.008$) and the control group (VEGF, 11.8 ± 5.5 pg/mL; PIGF, 12.4 ± 7.3 pg/mL) (both $Z = -3.578$, $p = 0.001$). The concentrations of VEGF (301.0 ± 173.6 pg/mL) and PIGF (478.7 ± 273.9 pg/mL) in group B was also higher than those in the control group (both $Z = -3.578$, $p = 0.001$) (Fig. 1b). However, there was no difference between group A (pre-IVC) and group B in the concentrations of VEGF ($Z = -0.221$, $p = 0.863$) and PIGF ($Z = -0.927$, $p = 0.354$).

Concentrations of VEGF and PIGF in Vitreous Humor

As shown in Fig. 1b, the concentrations of VEGF (911.8 ± 330.9 pg/mL) and PIGF (763.8 ± 373.5 pg/mL) in group B were higher than those (VEGF, 2.0 ± 10.1 pg/mL; PIGF, 40.7 ± 20.2 pg/mL) in the control group (VEGF, $Z = -3.578$, $p = 0.001$; PIGF, $Z = -3.578$, $p = 0.001$). Interestingly, the concentrations of VEGF (267.6 ± 76.1 pg/mL) in group A (post-IVC) were lower than those in group B ($Z = -3.576$, $p = 0.001$), whereas no difference in the concentration of PIGF (PIGF in group A post-IVC, 721.0 ± 369.0 pg/mL) ($Z = -0.309$, $p = 0.796$).

Correlation of Concentrations Between VEGF and PIGF

In aqueous humor, the concentrations of VEGF and PIGF have a positive correlation in group A (pre-IVC), group A (post-IVC), and group B (Fig. 1c), but not in the control group ($r = 0.075$,

$p = 0.847$). In vitreous humor, there was a positive correlation between VEGF and PIGF concentrations in group B (Fig. 1c), but not in group A (post-IVC) ($r = 0.567$, $p = 0.112$) and the control group ($r = 0.375$, $p = 0.345$).

Visual Outcome

After vitrectomy, all patients had visual improvement at 1 week, 1 month, and 3 months follow-up. The mean logMAR BCVA was improved significantly at 3 months follow-up in all three groups (Table 1).

DISCUSSION

In recent years, anti-VEGF agents considerably changed the treatment algorithms and improved prognosis of center-involving PDR [8]. As a new member of the anti-VEGF family of drugs, conbercept has been shown to be a safe and effective adjunct to vitrectomy in accelerating postoperative vitreous clear-up, and acquiring stable visual acuity restoration [9]. In comparison to ranibizumab, the first US FDA-approved medication used to treat wet age-related macular degeneration, Xu et al. reported that conbercept showed a longer treatment interval and fewer intravitreal drug injections were needed [6]. Su et al. reported that preoperative IVC injection could reduce the chances of intraoperative bleeding, which is beneficial to the management of PDR and the vitrectomy procedure [7]. Recently, Zhang et al. reported that the IVC combined with laser therapy could

improve the vision of patients with Coats' disease [10].

Conbercept consists of the VEGF-binding domains of human VEGFR-1 and VEGFR-2 combined with the Fc portion of human immunoglobulin G-1 [11]. In the rat retinal edema model, the concentrations of VEGF decreased after IVC injection [12]. However, there was no study, at least to our knowledge, to prove that the concentrations of VEGF and PlGF decreased after IVC injection in human aqueous and vitreous humor samples as a result of the difficulty in sampling the vitreous humor. In our study, we demonstrated that conbercept could significantly block the VEGF in the aqueous and vitreous humor of patients with PDR. Consistent with previous reports, the concentration of VEGF in vitreous was always higher than that in aqueous humor in diabetic patients [13]. Interestingly, we also found that the concentrations of PlGF decreased in aqueous humor 7 days after IVC injection, whereas there was no change in vitreous humor. The mechanism of this difference is unclear, but it may relate to some components in vitreous humor affecting the binding between PlGF and conbercept. Previous studies showed that conbercept could specifically bind to PlGF in vitreous humor and was critical to the development of PDR [14]. In PlGF knockout mouse strain, its genetic deletion protects the retina from diabetic damaged by inhibiting Akt activation and the HIF1 α -VEGF pathway [15]. This all suggested that PlGF could be another therapeutic target of conbercept.

CONCLUSIONS

All our results, combined with those of previous reports, consistently showed that conbercept was effective in the treatment of PDR by blocking the VEGF and PlGF, whilst showing no signs of retinal toxicity.

ACKNOWLEDGEMENTS

We thank all of the participants in the study. We would like to thank Dr. Xiao-Yan Tian, Jing

Zou, Hui-Lin Yang, and Huan Wang for their assistance in performing ophthalmological examinations. We also thank Ms. Rong Liu for her excellent technical assistance.

Funding. Sponsorship for this study and article processing charges were funded by the key research and development program of Shaanxi province (2017ZDXM-SF-067). All authors had full access to all of the data in this study and take complete responsibility for the integrity of the data and accuracy of the data analysis.

Authorship. All named authors meet the International Committee of Medical Journal Editors (ICMJE) criteria for authorship for this article, take responsibility for the integrity of the work as a whole, and have given their approval for this version to be published.

Disclosures. Jun Zhou, Zheng Liu, Meng Chen, Zhi-Heng Luo, Yun-Qiu Li, Guang-Ying Qi and Tao Liu have nothing to disclose.

Compliance with Ethics Guidelines. All procedures performed in studies involving human participants were in accordance with the ethical standards of the institutional and/or national research committee and with the 1964 Helsinki declaration and its later amendments or comparable ethical standards. Informed consent was obtained from all individual participants included in the study.

Data Availability. The datasets generated and/or analyzed during the current study are available from the corresponding author on reasonable request.

Open Access. This article is distributed under the terms of the Creative Commons Attribution-NonCommercial 4.0 International License (<http://creativecommons.org/licenses/by-nc/4.0/>), which permits any noncommercial use, distribution, and reproduction in any medium, provided you give appropriate credit to the original author(s) and the source, provide a link to the Creative Commons license, and indicate if changes were made.

REFERENCES

1. Chatziralli IP. The role of dyslipidemia control in the progression of diabetic retinopathy in patients with type 2 diabetes mellitus. *Diabetes Ther*. 2017;8:209–12.
2. Yau JW, Rogers SL, Kawasaki R, et al. Global prevalence and major risk factors of diabetic retinopathy. *Diabetes Care*. 2012;35:556–64.
3. Unsal E, Eltutar K, Sultan P, Erkul SO, Osmanbasoglu OA. Efficacy and safety of intravitreal dexamethasone implants for treatment of refractory diabetic macular edema. *Korean J Ophthalmol*. 2017;31:115–22.
4. Chen X, Li J, Li M, et al. KH902 suppresses high glucose-induced migration and sprouting of human retinal endothelial cells by blocking VEGF and PlGF. *Diabetes Obes Metab*. 2013;15:224–33.
5. Glassman AR, Liu D, Jampol LM, Sun JK. Diabetic Retinopathy Clinical Research Network. Changes in blood pressure and urine albumin-creatinine ratio in a randomized clinical trial comparing aflibercept, bevacizumab, and ranibizumab for diabetic macular edema. *Invest Ophthalmol Vis Sci*. 2018;59:1199–205.
6. Xu Y, Rong A, Xu W, Niu Y, Wang Z. Comparison of 12-month therapeutic effect of conbercept and ranibizumab for diabetic macular edema: a real-life clinical practice study. *BMC Ophthalmol*. 2017;17:158.
7. Su L, Ren X, Wei H, et al. Intravitreal conbercept (KH902) for surgical treatment of severe proliferative diabetic retinopathy. *Retina*. 2016;36:938–43.
8. Platania CB, Di Paola L, Leggio GM, et al. Molecular features of interaction between VEGFA and anti-angiogenic drugs used in retinal diseases: a computational approach. *Front Pharmacol*. 2015;6:248.
9. Yang X, Xu J, Wang R, et al. A randomized controlled trial of conbercept pretreatment before vitrectomy in proliferative diabetic retinopathy. *J Ophthalmol*. 2016;2016:2473234.
10. Zhang L, Ke Y, Wang W, Shi X, Hei K, Li X. The efficacy of conbercept or ranibizumab intravitreal injection combined with laser therapy for Coats' disease. *Graefes Arch Clin Exp Ophthalmol*. 2018;256:1339–46.
11. Wang Q, Li T, Wu Z, et al. Novel VEGF decoy receptor fusion protein conbercept targeting multiple VEGF isoforms provide remarkable anti-angiogenesis effect in vivo. *PLoS One*. 2018;8:e70544.
12. Shan L, Zheng M, Zhang Y, et al. Correlation of vascular endothelial growth factor production with photochemical reaction-induced retinal edema. *Chin Med J (Engl)*. 2016;129:2944–50.
13. Cancarini A, Costagliola C, Dell'omo R, et al. Effect of intravitreal bevacizumab on serum, aqueous, and vitreous humor levels of erythropoietin in patients with proliferative diabetic retinopathy. *Minerva Endocrinol*. 2014;39:305–11.
14. Lu X, Sun X. Profile of conbercept in the treatment of neovascular age-related macular degeneration. *Drug Des Devel Ther*. 2015;9:2311–20.
15. Huang H, He J, Johnson D, et al. Deletion of placental growth factor prevents diabetic retinopathy and is associated with Akt activation and HIF1 α -VEGF pathway inhibition. *Diabetes*. 2015;64:1067.