

Herlyn-Werner-Wunderlich syndrome presenting with infertility: Role of MRI in diagnosis

Zohra Ahmad, Ankur Goyal, Chandan J Das, Dipika Deka¹, Raju Sharma

Departments of Radiology, and ¹Obstetrics and Gynecology, All India Institute of Medical Sciences, New Delhi, India

Correspondence: Dr. Raju Sharma, Room No. 66, Department of Radiodiagnosis, AIIMS, Ansari Nagar, New Delhi - 110 029, India.
E-mail: raju152@yahoo.com

Abstract

Herlyn-Werner-Wunderlich syndrome (HWWS), characterized by uterus didelphys, obstructed hemivagina, and ipsilateral renal agenesis, is an uncommon combined Mullerian and mesonephric duct anomaly, and its presentation in adulthood is even rarer. We report here a 22-year-old female presenting with primary infertility where magnetic resonance imaging (MRI) suggested the diagnosis of HWWS with endometriosis. In a patient of infertility with endometriosis and unilateral renal agenesis, diagnosis of HWWS should be suspected and MRI is the investigation of choice for such anomalies.

Key words: Endometriosis; Herlyn-Werner-Wunderlich syndrome; infertility; magnetic resonance imaging; mullerian anomaly

Introduction

Herlyn-Werner-Wunderlich syndrome (HWWS) is often a misdiagnosed entity and high index of suspicion is required in patients with Mullerian and mesonephric duct anomalies. It usually presents at puberty with pelvic pain, but rarely can present in neonates or in adulthood in the form of pyometra, ischio-rectal swelling, urinary obstruction, and primary infertility.^[1-4] Since this condition can be treated by vaginal septum excision, and delay in diagnosis may worsen the associated endometriosis,^[5] early diagnosis is beneficial. Magnetic resonance imaging (MRI) is the modality of choice for the diagnosis of HWWS and other such anomalies because of better anatomic delineation of pelvic structures and higher sensitivity for blood products.

Case Report

A 22-year-old female, cohabiting with her husband for last 3 years, was evaluated for primary infertility in a private hospital. She attained menarche at the age of 13 years and had a normal menstrual history with no complaints of excessive dysmenorrhoea, dyspareunia, or vaginal discharge. Routine hematological laboratory tests were normal. An abdominal USG and computed tomography (CT) were performed, which revealed absent left kidney, a bicornuate uterus, bilateral cystic adnexal lesions, and left hydrosalpinx. She was taken up for laparotomy and underwent left ovarian cystectomy and adhesiolysis. Histopathology from the left adnexal lesion showed endometriotic cysts and aspirated pelvic fluid showed hemosiderin-laden macrophages. Postoperatively, she was kept on medical management for endometriosis.

She did not resume her menses for 3 months post-surgery and urine pregnancy test was negative, following which she was referred to our institute for further evaluation. MRI examination of the pelvis was performed to assess the current status of endometriosis. MRI revealed two separate uterine cavities, cervixes, and vaginas, suggestive of uterus didelphys [Figures 1-3]. The right uterine cavity, cervix, and vagina were normal. The left uterine cavity and

Access this article online

Quick Response Code:



Website:
www.ijri.org

DOI:
10.4103/0971-3026.120283

cervical canal were dilated and filled with fluid which was hyperintense on both T1W and T2W MRI [Figures 1 and 2] with few T2-hypointense areas [Figure 4] suggesting blood

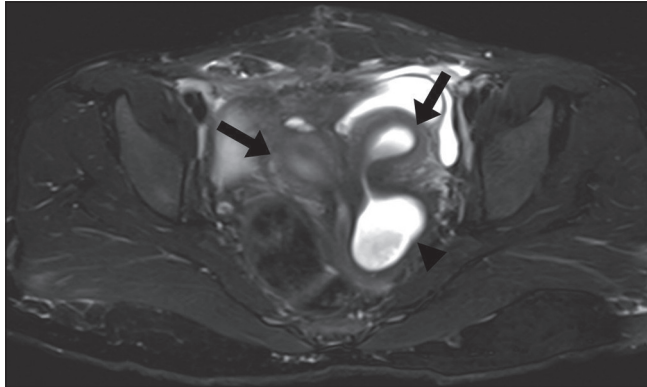


Figure 1: Axial T2W MRI shows two separate uterine cavities (black arrows) with two separate cervixes and dilatation of left hemivagina (arrowhead)

products. Left hemivagina was dilated [Figures 1, 2, and 4] with blood products within, implicating the presence of an obstructing left vaginal septum. Multiloculated left adnexal cystic lesions with blood products were seen suggestive of endometriotic cysts [Figure 5]. In addition, a tubular

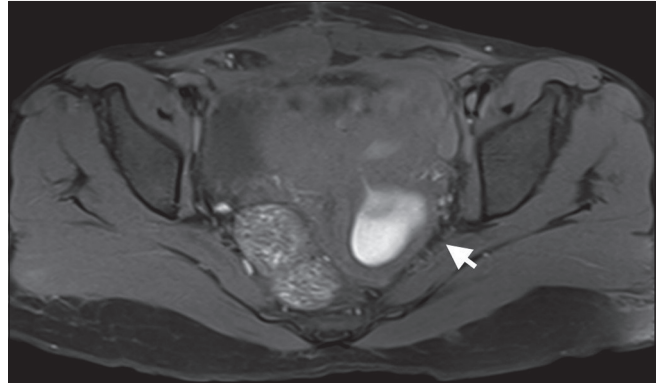


Figure 2: Axial fat-suppressed T1W MRI shows hyperintense contents of dilated left hemivagina (arrow) and uterine cavity, suggestive of blood products

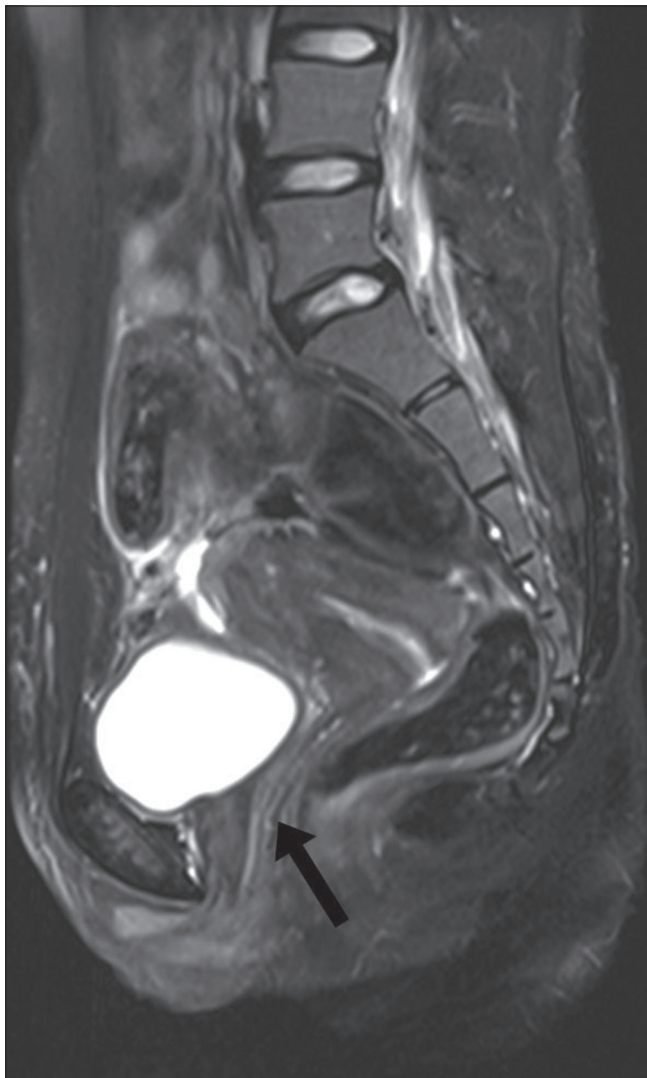


Figure 3: Sagittal T2W MRI shows right uterine cavity with normal cervix and vagina (black arrow)

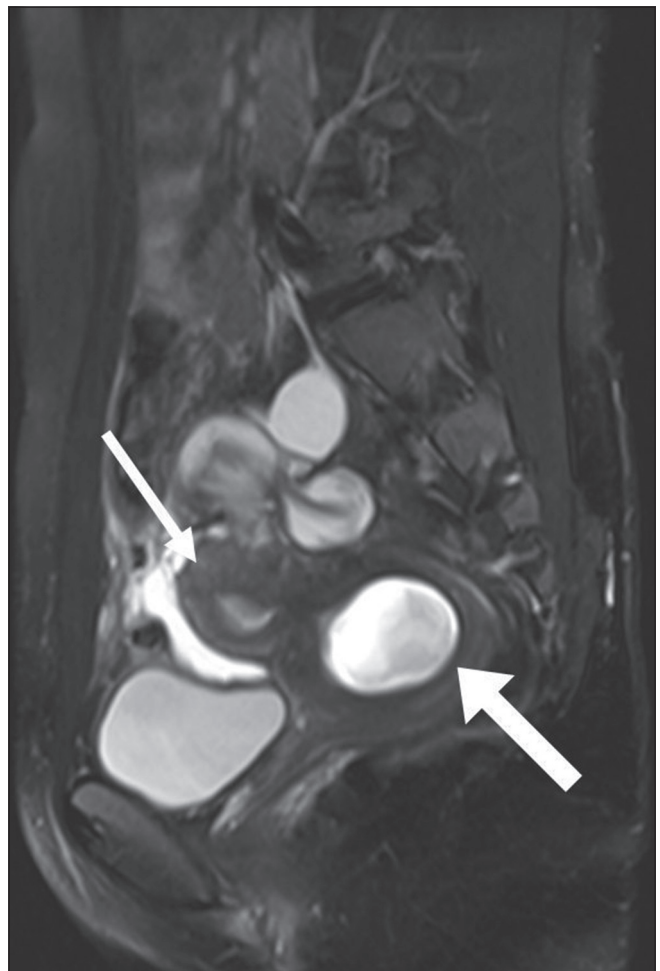


Figure 4: Sagittal T2W MRI shows left uterine cavity (thin arrow) with dilated hemivagina (thick arrow) showing hypointense signal within a background of hyperintensity (T2 shading), suggestive of blood products within (hematometra)

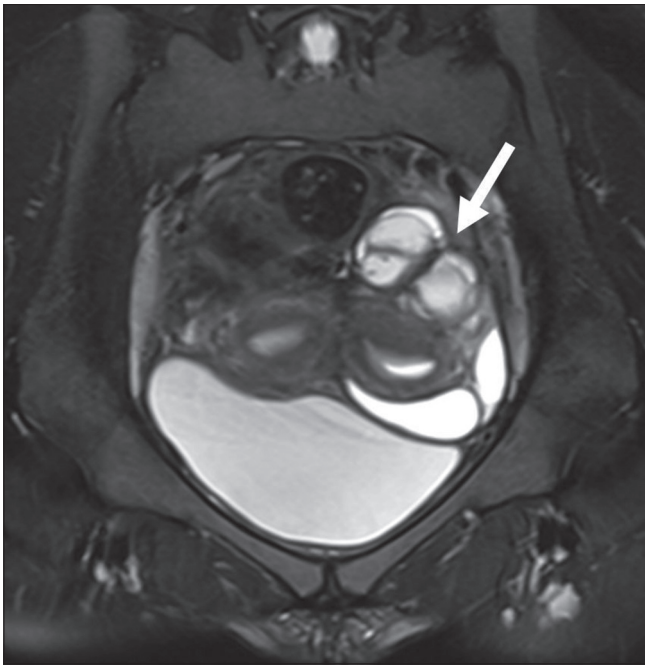


Figure 5: Coronal T2W MRI shows multiloculated cystic lesion in left adnexa with T2 shading suggestive of blood products with endometriotic cysts

structure was noted in left adnexal location extending laterally from left uterine cornu with hemorrhagic fluid within, indicative of left hematosalpinx. Right ovary was normal. In addition, there was absent left kidney [Figure 6] with loculated hemorrhagic fluid collections in bilateral paracolic gutters, suggestive of peritoneal endometriosis [Figure 7].

Hence, a diagnosis of uterus didelphys with left hematometra, hematosalpinx, hematocolpos, and left hemivaginal obstruction with adnexal and peritoneal endometriosis was made. Considering that she also had absent left kidney, a final diagnosis of HWWS or obstructed hemivagina ipsilateral renal anomaly (OHVIRA) syndrome was made. Since the patient had already undergone recent laparotomy, no further surgery was immediately performed. She has been kept on short-term conservative management with oral contraceptives to suppress menstruation and laparoscopic vaginal septal excision has been planned after 3 months.

Discussion

The most frequently used system for classification of Mullerian duct anomalies (MDAs) was proposed by Buttram and Gibbons, which classifies them into six categories^[6] [Table 1].

HWWS is a combination of Type III Mullerian anomaly with mesonephric duct anomaly with vaginal septum. The classic renal manifestation of OHVIRA syndrome is

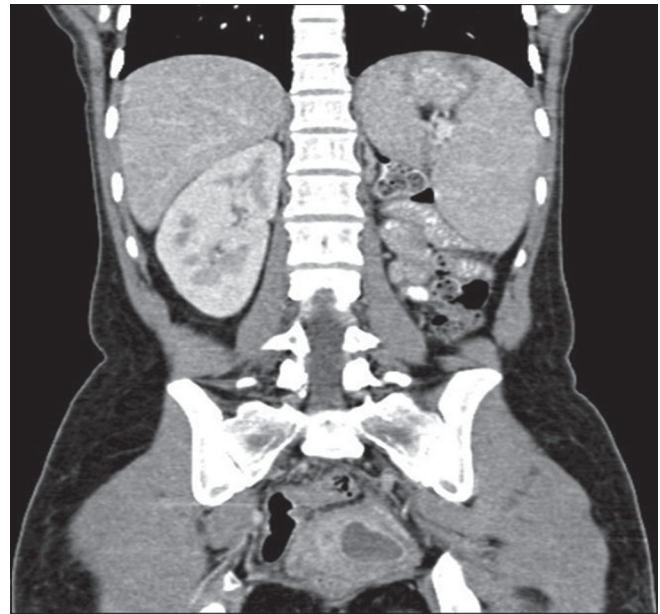


Figure 6: Coronal contrast-enhanced CT image reveals absent left kidney

Table 1: Mullerian duct anomalies classification

Class	Name	Description
I	Mayer-Rokitansky-Kuster-Hauser syndrome or Mullerian agenesis	Hypoplasia of the tubes, uterus, cervix, or vagina
II	Unicornuate uterus or unilateral Mullerian anomaly	No rudimentary horn Non-cavitary rudimentary horn Cavitary rudimentary horn (communicating or non-communicating)
III	Uterus didelphys	Two separate uterine horns and two cervixes
IV	Bicornuate uterus	Complete (septum extends to the internal or external os) Partial (septum is confined to the fundal region) Two separate uterine horns and single cervix Fundal depression separating the two horns greater than 1 cm Intercornual distance greater than 4 cm
V	Septate uterus	Complete (septum extends to the internal os) Partial (septum does not reach the internal os) Fundal depression separating the two horns is less than 1 cm Intercornual distance less than 4 cm
VI	T-shaped uterus	Results from in utero exposure to diethylstilbestrol

ipsilateral renal agenesis, but reports of duplicated kidneys, dysplastic kidneys,^[7] rectovesical bands,^[8] or crossed fused ectopia^[9] have also been described. Uterus didelphys with obstructed hemivagina is due to lateral non-fusion of the Mullerian ducts with asymmetric obstruction, and it is almost always associated with renal agenesis ipsilateral to the side of obstruction.^[7] An important point to note in patients with HWWS is that renal agenesis is located ipsilateral to the dilated uterine cavity. On the other hand, in case of unicornuate uteri, the renal anomalies are ipsilateral to the rudimentary or absent uterine horn.^[10]

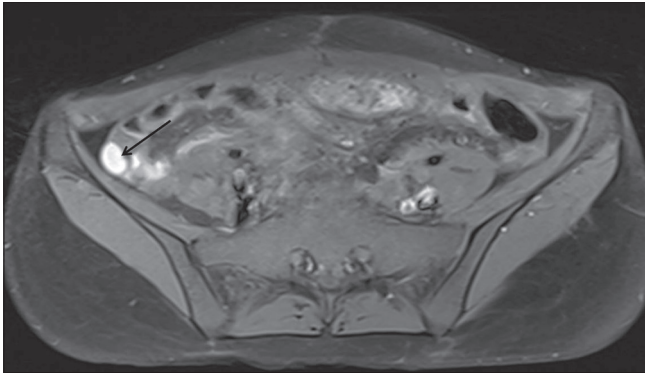


Figure 7: Axial fat-suppressed T1W MRI shows multilocular T1 hyperintense fluid collections in right paracolic gutter (arrow) consistent with peritoneal endometriosis

Embryopathogenesis of HWWS can be temporally located around 8 weeks of gestation, simultaneously affecting both Mullerian and metanephric ducts.^[11]

Haddad *et al.* studied the associations of a blind hemivagina in 42 patients and found that it was associated with renal agenesis in all but one patient. In addition, blind hemivagina with ipsilateral agenesis was generally associated with uterus didelphys; however, rare cases of septate uterus were also found.^[12]

Patients of endometriosis must be evaluated for any obstructive Mullerian lesion,^[13] and presence of concomitant unilateral renal agenesis should indicate a suspicion for HWWS. Patients of HWWS usually have normal menstruation and may or may not complain of dysmenorrhoea, explaining the delay in diagnosis in adults.^[14] Endometriosis is a frequent complication of this syndrome. This is because of obstructed outflow to part of the menstrual blood, which collects in obstructed Mullerian derivatives, leading to hematometra, hematosalpinx, and peritoneal endometriosis.

When suspecting a genitourinary anomaly, an initial screening ultrasound should be followed by MRI rather than CT, since the later involves radiation exposure and many questions remain unanswered because of its limited soft-tissue resolution. Considering the vast differential in uterovaginal anomalies, precise anatomical delineation of the uterus, tubes, cervix, and vagina is essential. Status of these reproductive organs and extent of endometriosis, pelvic inflammation, and adhesions can be well evaluated with MRI.^[9] Laparoscopy remains the gold standard diagnostic modality with the additional advantages of therapeutic drainage of hematocolpos/hematometra, vaginal septectomy, and marsupialization.^[15,16]

Laparoscopic vaginal septum excision is the treatment of choice for HWWS. A successful pregnancy is achieved

eventually in 87% patients, while 23% have the risk of abortions.^[14]

References

1. Wu TH, Wu TT, Ng YY, Ng SC, Su PH, Chen JY, *et al.* Herlyn-Werner-Wunderlich Syndrome consisting of uterine didelphys, obstructed hemivagina and ipsilateral renal agenesis in a newborn. *Pediatr Neonatol* 2012;53:68-71.
2. Jeong JH, Kim YJ, Chang CH, Choi HI. A case of Herlyn-Werner-Wunderlich syndrome with recurrent hematopyometra. *J Womens' Med* 2009;2:77-9.
3. Asha B, Manila K. An unusual presentation of uterus didelphys with obstructed hemivagina with ipsilateral renal agenesis. *Fertil Steril* 2008;849:e9-10.
4. Mandava A, Prabhakar RR, Smitha S. OHVIRA Syndrome (obstructed hemivagina and ipsilateral renal anomaly) with Uterus Didelphys, an Unusual Presentation. *J Pediatr Adolesc Gynecol* 2012;25:e23-5.
5. Adair II L, Georgiades M, Osborne R, Ng T. Uterus didelphys with unilateral distal vaginal agenesis and ipsilateral renal agenesis: Common presentation of an unusual variation. *J Radiol Case Rep* 2011;5:1-8.
6. Buttram VC Jr, Gibbons WE. Mullerian anomalies: A proposed classification (an analysis of 144 cases). *Fertil Steril* 1979;32:40-6.
7. Prada Arias M, Muguerza Vellibre R, Montero Sánchez M, Vázquez Castelo JL, Arias González M, Rodríguez Costa A. Uterus didelphys with obstructed hemivagina and multicystic dysplastic kidney. *Eur J Pediatr Surg* 2005;15:441-5.
8. Heinonen PK. Clinical implications of the didelphic uterus: Long-term follow-up of 49 cases. *Eur J Obstet Gynecol Reprod Biol* 2000;91:183-90.
9. Tanaka YO, Kurosaki Y, Kobayashi T, Eguchi N, Mori K, Satoh Y, *et al.* Uterus didelphys associated with obstructed hemivagina and ipsilateral renal agenesis: MR findings in seven cases. *Abdom Imaging* 1998;23:437-41.
10. Brody JM, Koelliker SL, Frishman GN. Unicornuate uterus: Imaging appearance, associated anomalies, and clinical implications. *AJR Am J Roentgenol* 1998;171:1341-7.
11. Singh M, Geareart JP, Rock JA. Double urethra, double bladder, left renal agenesis, persistent hymen, double vagina and uterus didelphys. *Adolesc Pediatr Gynecol* 1993;6:99.
12. Haddad B, Barranger E, Paniel BJ. Blind hemivagina: Long-term follow-up and reproductive performance in 42 cases. *Hum Reprod* 1999;14:1962-4.
13. Del Vescovo R, Battisti S, Di Paola V, Piccolo CL, Cazzato RL, Sansoni I, *et al.* Herlyn-werner-wunderlich syndrome: MRI findings, radiological guide (two cases and literature review), and differential diagnosis. *BMC Med Imaging* 2012;12:4.
14. Candiani GB, Fedele L, Candiani M. Double uterus, blind hemivagina, and ipsilateral renal agenesis: 36 cases and long term follow-up. *Obstet Gynecol* 1997;90:26-32.
15. Gholoum S, Puligandla PS, Hui T, Su W, Quiros E, Laberge JM. Management and outcome of patients with combined vaginal septum, bifid uterus and ipsilateral renal agenesis (Herlyn-Werner-Wunderlich syndrome). *J Pediatr Surg* 2006;41:987-92.
16. Park NH, Park HJ, Park CS, Park SI. Herlyn-Werner-Wunderlich Syndrome with unilateral hemivaginal obstruction, ipsilateral renal agenesis and contralateral renal thin GBM disease: A case report with radiological follow up. *J Korean Soc Radiol* 2010;62:383-8.

Cite this article as: Ahmad Z, Goyal A, Das CJ, Deka D, Sharma R. Herlyn-Werner-Wunderlich syndrome presenting with infertility: Role of MRI in diagnosis. *Indian J Radiol Imaging* 2013;23:243-6.

Source of Support: Nil, **Conflict of Interest:** None declared.