

This is an Open Access article licensed under the terms of the Creative Commons Attribution-NonCommercial-NoDerivs 3.0 License ([www.karger.com/OA-license](http://www.karger.com/OA-license)), applicable to the online version of the article only. Distribution for non-commercial purposes only.

# Cutaneous *Mycobacterium abscessus* Infection Associated with Mesotherapy Injection

Pranee Wongkitisophon Ploysyne Rattanakaemakorn  
Somsak Tanrattanakorn Vasanop Vachiramorn

Division of Dermatology, Department of Medicine, Ramathibodi Hospital, Mahidol University, Bangkok, Thailand

## Key Words

Non-tuberculous mycobacteria · *Mycobacterium abscessus* · Mesotherapy

## Abstract

Non-tuberculous mycobacterial skin infections have an increasing incidence. In immunocompetent patients, they usually follow local trauma. We present a case of cutaneous *Mycobacterium abscessus* infection following mesotherapy. The lesions were successfully treated with a combination of clarithromycin, ciprofloxacin, and doxycycline. Atypical mycobacterial infection should be suspected in patients who develop late-onset skin and soft tissue infection after cutaneous injury, injection, and surgical intervention, particularly if they do not respond to conventional antibiotic treatment.

## Introduction

Skin and soft tissue infections caused by non-tuberculous mycobacteria have been increasingly described as a complication associated with many procedures, including liposuction, illicit soft tissue augmentation, acupuncture, and contamination from medical instruments during surgery [1–5]. *Mycobacterium abscessus* is a rapid-growing atypical mycobacterium that has been reported to cause a variety of cutaneous infections. Herein, we report a case of cutaneous *M. abscessus* infection associated with mesotherapy injection.

## Case Report

A previously healthy 44-year-old woman presented with a 3-week history of tender erythematous nodules on her face. The lesions had developed 2 weeks after mesotherapy injection for facial rejuvenation, using an unknown substance administered by an uncertified aesthetician. She had no fever or other systemic symptoms. Her friends who underwent mesotherapy administered by the same practitioner developed similar lesions. The lesions did not improve after a 2-week course of oral

cephalexin. Physical examination revealed multiple, discrete, tender erythematous nodules and plaques with minimal serosanguinous discharge on both cheeks (fig. 1) and on the forehead (fig. 2). There was no lymphadenopathy. The results of the rest of the examination were normal. A skin biopsy specimen obtained from a nodule on the right cheek revealed dense inflammation predominantly consisting of neutrophils, histiocytes and multinucleated giant cells in the superficial and deep dermis (fig. 3). Gram staining, fungal and acid-fast bacilli stains were negative. Tissue culture was positive for *M. abscessus*, sensitive to clarithromycin, ciprofloxacin, doxycycline, ceftiofur, and amikacin. Bacterial and fungal cultures were negative. The patient was treated with a combination of clarithromycin 500 mg twice daily, doxycycline 100 mg twice daily, and ciprofloxacin 500 mg twice daily according to the bacterial sensitivity testing. The lesions started to improve 2 weeks after initiation of the therapy. The patient completed 6 months of treatment, which resulted in complete resolution of the lesions with minimal atrophic hyperpigmented scars. There was no recurrence at the 3-month follow-up.

## Discussion

Mesotherapy was first introduced in France in 1952, consisting of an injection of highly diluted drugs and different substances into the dermis and subcutaneous tissue. It causes both the chemical and physical stimulation of cutaneous mesoderm. Direct injection in involved sites allows lower dosages of drugs to be used. All intravenously injectable drugs may be used, except oily and alcoholic solvents. This technique was originally developed to treat localized pain, vascular and lymphatic disorders, but its use in aesthetic medicine has increased in recent years [5].

*M. abscessus* belongs to the group of rapidly growing non-tuberculous mycobacteria which is characterized by a rapid growth rate (within 7 days) on the culture. The organism is ubiquitously present in soil, decaying vegetation, and water (e.g., natural water, sewage water, drinking water tanks, and tap water). *M. abscessus* causes a wide range of clinical diseases including skin and soft-tissue infection, keratitis, osteomyelitis, pulmonary infection, and disseminated infection. In skin and soft-tissue infection, it usually follows penetrating trauma and typically occurs in immunocompetent individuals [6]. There are several reports of outbreaks of *M. abscessus* infections caused by non-sterile techniques or contaminated materials, following surgery, liposuction, foreign body implantation, mesotherapy, acupuncture, and soft tissue augmentation [1–5].

The clinical presentations of cutaneous *M. abscessus* infection ranges from asymptomatic to tender erythematous violaceous nodules and plaques, cellulitis, abscesses, ulcer, and draining sinus with serosanguinous discharge [7]. The lesions may be solitary or multiple, and localized lymphadenopathy is occasionally seen. The onset is varied from a few weeks to months after exposure [8].

Approximately 10–20% of localized cutaneous *M. abscessus* infections in immunocompetent patients resolve spontaneously without treatment in an average of 8 months [9]. Currently, there is no standard guideline for the treatment of cutaneous *M. abscessus* infection. Multiple modalities including surgery, draining of abscesses, removal of necrotic tissue, foreign body removal, and an extended course of antibiotics are recommended. The in vitro sensitivity helps guiding antimicrobial therapy. However, the in vivo efficacy against the mycobacteria is not completely reflected by in vitro sensitivity alone, but also depends on the function of local and general host defenses against the infection. *M. abscessus* is usually susceptible to clarithromycin, amikacin, linezolid, tigecycline and variably susceptible to ceftiofur and imipenem (table 1). Clarithromycin is generally the recommended drug of choice. It should be given in a combination with

other antibiotics for 4–6 months. Monotherapy is not recommended in treating *M. abscessus* infection because of the potential for emergence of antibiotic resistance, as has been reported with other mycobacteria, such as *Mycobacterium chelonae* [10].

In conclusion, we report a case of cutaneous *M. abscessus* infection associated with mesotherapy. This case emphasizes the importance of adequate sterile measures in all medical procedures and stresses the need to suspect the possibility of an atypical mycobacterium infection in patients who develop late-onset skin and soft tissue infection after cutaneous injury, injections, and surgical interventions, particularly if they do not respond to conventional antibiotic treatment.

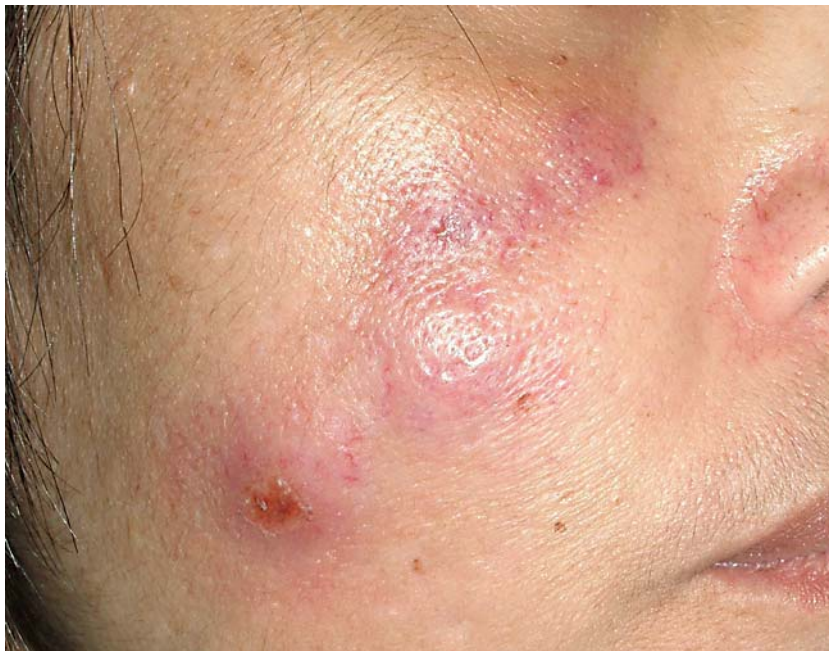### Disclosure Statement

The authors have no conflicts of interest.

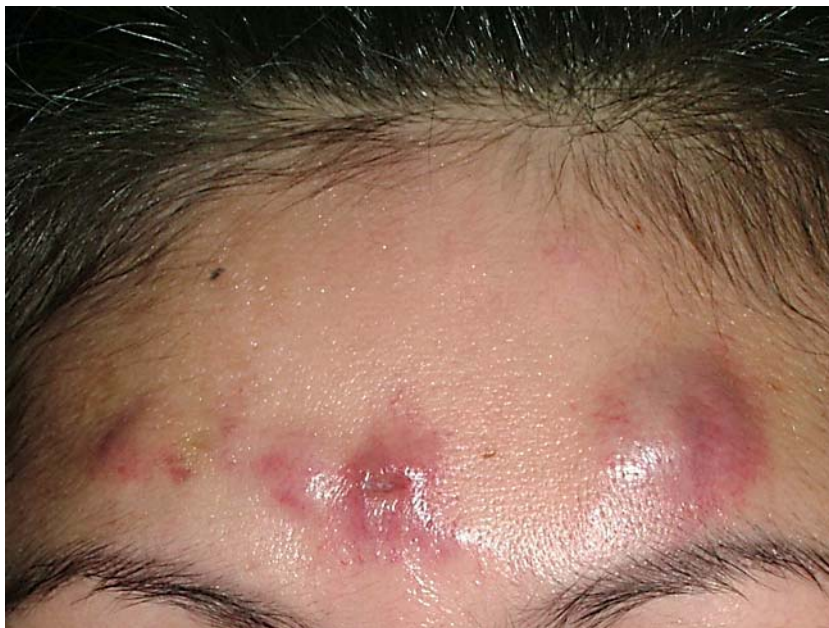**Table 1.** Antimycobacterial drugs, typical sensitivity pattern, and recommended dose for *M. abscessus* infection [6]

Drugs	Typical sensitivity pattern	Dosage* and route
Clarithromycin	S	500–1,000 mg/day PO
Azithromycin	S	500–1,000 mg/day PO
Amikacin	S	<800–1,000 mg/day IV, IM
Linezolid	S	1,200 mg/day PO
Tigecycline	S	100 mg/day IV
Cefoxitin	V	12,000 mg/day IV
Imipenem	V	25 mg/kg/day IV
Ciprofloxacin	R	1,000 mg/day PO
Sulfamethoxazole	R	3,000 mg/day PO
Doxycycline	R	200 mg/day PO

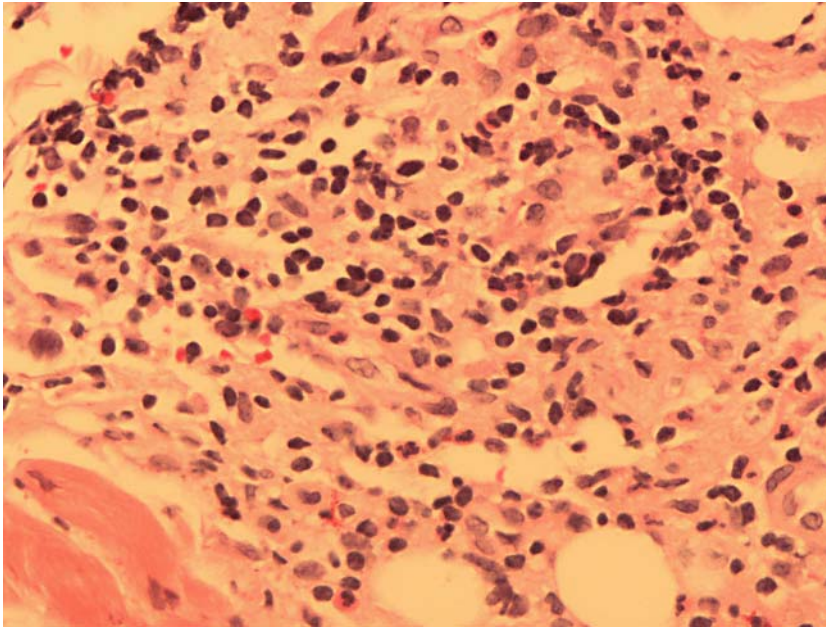
\* Dosage in adult patients with normal renal function. S = sensitive; V = variable; R = resistant; PO = per os; IV = intravenous; IM = intramuscular.



**Fig. 1.** Erythematous nodules and plaques on the right cheek.



**Fig. 2.** Erythematous nodules and plaques on the forehead.



**Fig. 3.** Hematoxylin and eosin-stained slide,  $\times 400$ . A dense inflammatory infiltrate composed of neutrophils and histiocytes in the dermis.

### References

- 1 Fisher EJ, Gloster HM Jr: Infection with *Mycobacterium abscessus* after Mohs micrographic surgery in an immunocompetent patient. *Dermatol Surg* 2005;31:790–794.
- 2 Murillo J, Torres J, Bofill L, Ríos-Fabra A, Irausquin E, Istúriz R, Guzmán M, Castro J, Rubino L, Cordido M: Skin wound infection by rapidly growing mycobacteria: an unexpected complication of liposuction and liposculpture. The Venezuelan Collaborative Infectious and Tropical Diseases Study Group. *Arch Dermatol* 2000;136:1347–1352.
- 3 Ryu HJ, Kim WJ, Oh CH, Song HJ: Iatrogenic *Mycobacterium abscessus* infection associated with acupuncture: clinical manifestations and its treatment. *Int J Dermatol* 2005;44:846–850.
- 4 Toy BR, Frank PJ: Outbreak of *Mycobacterium abscessus* infection after soft tissue augmentation. *Dermatol Surg* 2003;29:971–973.
- 5 Garcia-Navarro X, Barnadas MA, Dalmau J, Coll P, Gurguí M, Alomar A: *Mycobacterium abscessus* infection secondary to mesotherapy. *Clin Exp Dermatol* 2008;33:658–659.
- 6 Petrini B: *Mycobacterium abscessus*: an emerging rapid-growing potential pathogen. *APMIS* 2006;114:319–328.
- 7 Uslan DZ, Kowalski TJ, Wengenack NL, Virk A, Wilson JW: Skin and soft tissue infections due to rapidly growing mycobacteria: comparison of clinical features, treatment, and susceptibility. *Arch Dermatol* 2006;142:1287–1292.
- 8 Piersimoni C, Scarparo C: Extrapulmonary infections associated with nontuberculous mycobacteria in immunocompetent persons. *Emerg Infect Dis* 2009;15:1351–1358.
- 9 Weitzul S, Eichhorn PJ, Pandya AG: Nontuberculous mycobacterial infections of the skin. *Dermatol Clin* 2000;18:359–377.
- 10 Tebas P, Sultan F, Wallace RJ Jr, Fraser V: Rapid development of resistance to clarithromycin following monotherapy for disseminated *Mycobacterium chelonae* infection in a heart transplant patient. *Clin Infect Dis* 1995;20:443–444.